

Dermatology 2011;222:193–195  
DOI: 10.1159/000322842

### Brunsting-Perry Pemphigoid of the Scalp with Antibodies against Laminin 332

H. Jedlickova<sup>a</sup>, A. Niedermeier<sup>b</sup>, S. Zgařarová<sup>a</sup>, M. Hertl<sup>c</sup>

<sup>a</sup>First Department of Dermatovenereology, St. Anna Hospital, Masaryk University, Brno, Czech Republic; <sup>b</sup>Department of Dermatology and Allergology, Ludwig Maximilian University Munich, Munich, and <sup>c</sup>Department of Dermatology and Allergology, Philipps University, Marburg, Germany

#### Key Words

Auto-immune bullous diseases · Brunsting-Perry pemphigoid · Cicatricial pemphigoid · Laminin 332

A scarring disease localized to the head and neck without mucosal involvement, described by Brunsting and Perry in 1957 [1], is considered as a variant of cicatricial pemphigoid (CP), bullous pemphigoid (BP) or epidermolysis bullosa acquisita (EBA), although the target antigen has not yet been clearly established. In this report, we describe 2 patients with localized CP of the scalp and IgG auto-antibodies against laminin 332. Laminin 332 (formerly laminin 5) is a target antigen of one subset of CP affecting mucous membranes (mucous membrane pemphigoid, MMP) [2]. It is considered rather specific for this subset of MMP and is detected rarely in subepidermal bullous dermatoses affecting the skin [3].

#### Case 1

A 58-year-old man presented with a 2-year history of a scarring and crusty lesion 3 cm in diameter in the parietal scalp region. Basal cell carcinoma was suspected, and a biopsy of the lesion was performed. Histological examination showed erosion with an inflammatory infiltrate and a few yeast cells (Grocott stain). However, topical therapy with antibiotics and antimycotics was not effective. A second skin biopsy revealed subepidermal cleavage, erythrocytes in the blister and an inflammatory dermal infiltrate of lymphocytes and histiocytes suggestive of CP (fig. 1a). Direct immunofluorescence microscopy (DIF) of lesional skin showed weak linear positivity with anti-IgG antibody; indirect immunofluorescence (IIF) on monkey oesophagus was negative. A salt split skin test was not performed. Eventually, enzyme-linked immunosorbent assay (ELISA) was performed with native human laminin 332 (affinity-purified protein with  $\alpha_3\text{-}$ ,

$\beta_3$ - and  $\gamma_2$ -chains from the squamous carcinoma cell line SCC25), recombinant 230-kDa BP antigen (BP230) and 180-kDa BP antigen (BP180; baculoprotein expression system) as previously described [4]. By ELISA, there was strong IgG reactivity against laminin 332 and reactivity against a distinct BP180 epitope (mid-portion of the BP180 ectodomain, aa residues 809–1106). The lesion healed with topical corticosteroids. Three years later, the patient was in complete remission, and a control ELISA no longer showed IgG reactivity against laminin 332, BP180 or BP230 antigens.

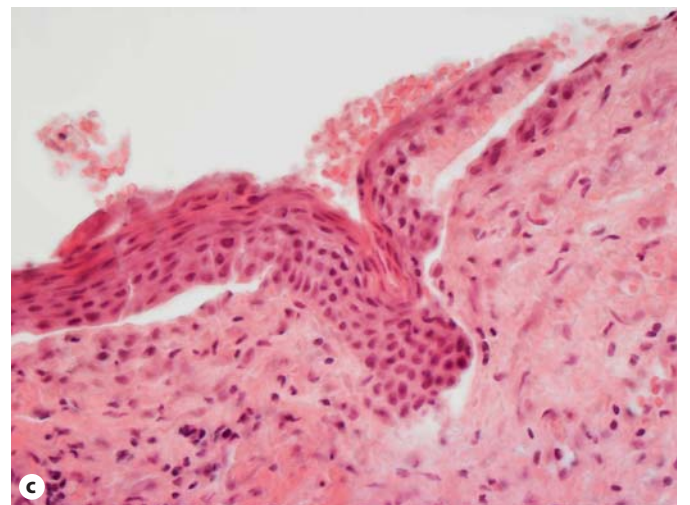
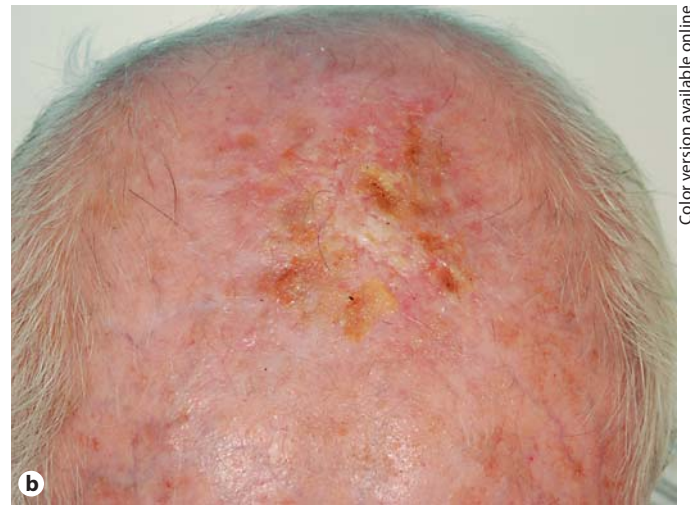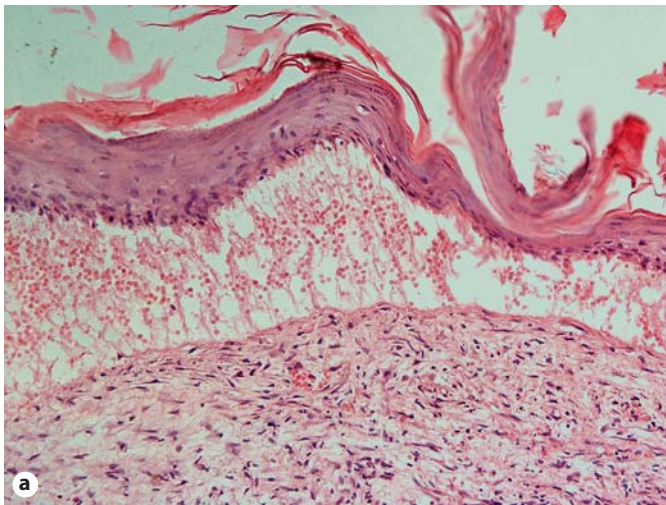
#### Case 2

A 74-year-old man had a 2-year history of erosions and crusts of the scalp. At presentation, he had an erosive and crusty lesion 10 cm in diameter on the top of his head while other parts of the body or mucous membranes were not affected (fig. 1b). The biopsy showed actinic damage of the epidermis; the diagnosis of actinic keratosis was established, and the lesion was treated with liquid nitrogen with only temporary effect. A second biopsy of lesional skin showed subepidermal cleavage and an inflammatory infiltrate composed of lymphocytes and histiocytes in the dermis suggestive of CP (fig. 1c). DIF of lesional skin was negative, IIF on monkey oesophagus showed granular antinuclear auto-antibodies at a titre of 1:80 and weak linear positivity with anti-IgG, -A and -M antibodies; salt split skin was negative. By ELISA, the patient's serum showed IgG reactivity against laminin 332. Topical treatment with corticosteroids led to a temporary healing of the lesion. Two years later, the patient still needs intermittent topical corticosteroid treatment.

#### Discussion

Brunsting-Perry pemphigoid typically affects elderly men as multiple erosive and scarring lesions in the head and neck region, rarely as a solitary plaque [5]. In case of a solitary lesion the diagnosis may be extremely difficult. These cases can be misdiagnosed as actinic keratosis, pyoderma or dermatitis artefacta. The lesion is often eroded; thus, no subepidermal blister is detected, eosinophils are usually absent, immunofluorescence studies, if done, can be negative.

A case of Brunsting-Perry pemphigoid similar to ours with a solitary lesion of the scalp was described by Poon and McGrath [6], which was negative by DIF and IIF. Monihan et al. [7] described 3 cases of CP simulating basal cell carcinoma. Murata et al. [8] detected immunoglobulin deposits between basal keratinocytes and the lamina lucida of the dermal-epidermal junction by immuno-electron microscopy in a case of Brunsting-Perry pemphigoid supporting the concept that this disorder is closely related to CP.



Color version available online

**Fig. 1. a** Subepidermal blister, case 1. Haematoxylin-eosin. Original magnification  $\times 100$ . **b** Crusts and erosion on the top of the head, case 2. **c** Denuded dermis with remnants of epidermis, subepidermal cleft, case 2. Haematoxylin-eosin. Original magnification  $\times 200$ .

Kurzahls et al. [9] described a case with clinical features of Brunsting-Perry pemphigoid with an immunofluorescence and immuno-electron microscopy pattern identical to EBA. This finding has also been reported by others [10, 11].

Daito et al. [12] have recently detected IgG auto-antibodies against the COOH terminus of BP180 by immunoblot and borderline positivity of auto-antibodies against the BP180 NC16a domain by ELISA in a woman with Brunsting-Perry pemphigoid of the scalp and upper trunk involvement. Antibodies against laminin 332 have not been reported in association with Brunsting-Perry pemphigoid, yet. ELISA is a sensitive and specific tool for the detection of anti-laminin-332 antibodies. In the study of Bekou et al. [13], ELISA with native laminin 332 in MMP had a sensitivity of 75% and a specificity of 84.3%. Bekou et al. [13] also detected anti-laminin-332 antibodies in 40% of patients with BP. Anti-laminin-332 antibodies can occur in BP and CP due to the epitope spreading phenomenon; laminin 332 is a ligand for BP180 [14], and the BP180 COOH terminus is considered as a target antigen in CP.

In conclusion, our 2 patients presented here strongly suggest that CP of the head, neck and upper trunk without mucosal involvement is a heterogeneous disorder with several target antigens. In addition to the auto-antigens of EBA and BP, IgG auto-antibodies against a major auto-antigen of MMP, laminin 332, may play an important pathogenetic role, especially in the solitary lesions of the scalp. Further studies are needed to confirm the relevance of anti-laminin-332 antibodies in Brunsting-Perry pemphigoid.

*Disclosure Statement*

The authors have no conflict of interest to declare.

## References

- 1 Brunsting LA, Perry HO: Benign pemphigoid? A report of seven cases with chronic, scarring, herpetiform plaques about the head and neck. *Arch Dermatol* 1957;75:489–501.
- 2 Chan LS, Ahmed AR, Anhalt GJ, Bernauer W, Cooper KD, Elder MJ, Fine JD, Foster CS, Ghohestani R, Hashimoto T, Hoang-Xuan T, Kirtschig G, Korman NJ, Lightman S, Lozada-Nur F, Marinkovich MP, Mondino BJ, Prost-Squarcioni C, Rogers RS 3rd, Setterfield JF, West DP, Wojnarowska F, Woodley DT, Yancey KB, Zillikens D, Zone JJ: The first international consensus on mucous membrane pemphigoid: definition, diagnostic criteria, pathogenic factors, medical treatment, and prognostic indicators. *Arch Dermatol* 2002;138:370–379.
- 3 Lazarova Z, Salato VK, Lanschuetzer CM, Janson M, Fairley JA, Yancey KB: IgG anti-laminin-332 autoantibodies are present in a subset of patients with mucous membrane, but not bullous, pemphigoid. *J Am Acad Dermatol* 2008;58:951–958.
- 4 Thoma-Uszynski S, Uter W, Schwietzke S, Schuler G, Borradori L, Hertl M: Autoreactive T and B cells from bullous pemphigoid (BP) patients recognize epitopes clustered in distinct regions of BP180 and BP230. *J Immunol* 2006;176:2015–2023.
- 5 Bruch-Gerharz D, Hertl M, Ruzicka T: Mucous membrane pemphigoid: clinical aspects, immunopathological features and therapy. *Eur J Dermatol* 2007;17:191–200.
- 6 Poon E, McGrath JA: Non-specific scalp crusting as a presenting feature of Brunsting-Perry cicatricial pemphigoid. *J Eur Acad Dermatol Venereol* 1999;12:177–178.
- 7 Monihan JM, Nguyen TH, Guill MA: Brunsting-Perry pemphigoid simulating basal cell carcinoma. *J Am Acad Dermatol* 1989;21:331–334.
- 8 Murata Y, Tani M, Kumano K: Localized chronic pemphigoid of Brunsting Perry: ultrastructural localization of IgG and complement components. *Arch Dermatol* 1983;119:921–924.
- 9 Kurzhals G, Stolz W, Meurer M, Kunze J, Braun-Falco O, Krieg T: Acquired epidermolysis bullosa with the clinical feature of Brunsting-Perry cicatricial bullous pemphigoid. *Arch Dermatol* 1991;127:391–395.
- 10 Joly P, Ruto F, Thomine E, Delpech A, Balguerie X, Tron F, Lauret P: Brunsting-Perry cicatricial bullous pemphigoid: a clinical variant of localized acquired epidermolysis bullosa? *J Am Acad Dermatol* 1993;28:89–92.
- 11 Choi GS, Lee ES, Kim SC, Lee S: Epidermolysis bullosa acquisita localized to the face. *J Dermatol* 1998;25:19–22.
- 12 Daito J, Katoh N, Asai J, Ueda E, Takenaka H, Ishii N, Hashimoto T, Kishimoto S: Brunsting-Perry cicatricial pemphigoid associated with autoantibodies to the C-terminal domain of BP180. *Br J Dermatol* 2008;159:984–986.
- 13 Bekou V, Thoma-Uszynski S, Wendler O, Uter W, Schwietzke S, Hunziker T, Zouboulis CC, Schuler G, Sorokin L, Hertl M: Detection of laminin 5-specific auto-antibodies in mucous membrane and bullous pemphigoid sera by ELISA. *J Invest Dermatol* 2005;124:732–740.
- 14 Tasanen K, Tunggal L, Chometon G, Bruckner-Tuderman L, Aumailley M: Keratinocytes from patients lacking collagen XVII display a migratory phenotype. *Am J Pathol* 2004;164:2027–2038.

H. Jedlickova  
First Department of Dermatovenereology  
St. Anna Hospital, Masaryk University  
CZ–65691 Brno (Czech Republic)  
Tel. +420 543 182 813, Fax +420 543 182 793  
E-Mail hana.jedlickova@fnusa.cz