

Original Paper

European
Surgical ResearchEur Surg Res 2004;36:198–205
DOI: 10.1159/000078853Received: December 19, 2003
Accepted after revision: January 26, 2004

Can We Continue Research in Splenectomized Dogs? *Mycoplasma haemocanis*: Old Problem – New Insight

G. Kemming^{a,b} J.B. Messick^d W. Mueller^e G. Enders^a F. Meisner^{a,c}
S. Muenzing^a H. Kisch-Wedel^{a,b} A. Schropp^a C. Wojtczyk^a K. Packert^{a,b}
K. Messmer^a E. Thein^a^aInstitute for Surgical Research and ^bClinic of Anesthesiology, Klinikum Grosshadern, Ludwig Maximilian University Munich, Munich, ^cDepartment of Vascular and Thoracic Surgery, University of Ulm, Ulm, Germany; ^dCollege of Veterinary Medicine, University of Illinois, Urbana-Champaign, Ill., USA, and ^eAlomed Veterinary Analytical Laboratories, Radolfzell, Germany

Key Words

Hemorrhagic shock, experimental · Splenectomy · Blood parasite · *Rickettsia* · Mollicute · *Haemobartonella* · *Mycoplasma haemocanis* · Anemia

Abstract

We report the appearance of a *Mycoplasma haemocanis* infection in laboratory dogs, which has been reported previously, yet, never before in Europe. Outbreak of the disease was triggered by a splenectomy intended to prepare the dogs for a hemorrhagic shock study. The clinical course of the dogs was dramatic including anorexia and hemolytic anemia. Treatment included allogeneic transfusion, prednisone, and oxytetracycline. Systematic follow-up (n = 12, blood smears, antibody testing and specific polymerase chain reaction) gives clear evidence that persistent eradication of *M. haemocanis* is unlikely. We, therefore, had to abandon the intended shock study. In the absence of effective surveillance and screening for *M. haemocanis*, the question arises whether it is prudent to continue shock research in splenectomized dogs.

Copyright © 2004 S. Karger AG, Basel

Introduction

Pathophysiology and therapy of hemorrhagic shock is – and will remain – a core field of interest in surgical research. In vivo models are performed in small rodents, but also in large mammals. The latter remains indispensable, since investigation of O₂ transport, regional peripheral perfusion and tissue oxygenation requires extensive surgical instrumentation and sufficient dimensions of the organs of interest. Traditionally, dogs are the preferred animals in the design of experimental hemorrhagic shock models. Efforts to standardize the experimental shock insult included control of volume depletion [1], control of blood pressure reduction [2], and control of accumulated O₂ debt [3, 4].

However, investigators are still confronted with considerable variability in the canine cardiovascular shock response, since the canine spleen acts as a blood reservoir and contracts during hemorrhage, expelling red cells, thus increasing hematocrit, circulating blood volume, left ventricular preload, cardiac output and arterial O₂ content [5–7], which dramatically enhances the canine cardiovascular stress response [6, 8]. Canine splenic contraction is

KARGER

Fax +41 61 306 12 34
E-Mail karger@karger.ch
www.karger.com© 2004 S. Karger AG, Basel
0014–312X/04/0364–0198\$21.00/0Accessible online at:
www.karger.com/esrDr. med. Gregor Kemming
Institute for Surgical Research, Ludwig Maximilian University Munich, Grosshadern
Marchioninistrasse 27, DE–81377 Munich (Germany)
Tel. +49 89 7095 4403, Fax +49 89 7095 8897
E-Mail Gregor.Kemming@med.uni-muenchen.de

mediated by endothelin and by norepinephrine via α_1 -adrenoceptors [9]. Of note, the splenic release of red cells is variable in dogs and negligible in humans [5]. Therefore, to allow extrapolation of results from canine experiments to the human setting, splenectomy prior to induction of hemorrhagic shock is a frequently used procedure. In 1975, Pryor and Bradbury [10] published a systematic report on 20 splenectomized beagle dogs from the US Naval Medical Field Research Laboratory and Medical Research Center suffering from a parasitemic disease that caused anemia.

Mycoplasma haemocanis (formerly *Haemobartonella canis*) is well known to veterinary physicians all over the world [11–13]. It is assumed that infection of dogs with *M. haemocanis* is not an unusual event. However, clinical outbreak of the disease requires previous immunosuppression, coexistent infection, or, most importantly, splenectomy [14–16]. The disease was infrequently recognized and thought to be of limited relevance in research – an epidemic outbreak in a European research institution has not been reported until today. We describe an impressive episode of epidemic *M. haemocanis* infection in our laboratory, complicating a large experimental study. We had to terminate our project prematurely, fearing that this infection would be a confounding factor when analyzing the experimental results. The question arises whether it is prudent to go on conducting research involving the use of splenectomized dogs in the future.

Methods

Design

The purpose-bred dogs were purchased from an established commercial breeder in Germany to be included in a hemorrhagic shock study. For prophylaxis against ectoparasites, fenthion 200 mg (Bayer, Leverkusen, Germany) was administered externally at the time of admission to our laboratory. Subsequently, the animals were allowed to recover from transportation for 48 h, and underwent routine splenectomy afterwards. Triggered by this procedure, overt disease with *M. haemocanis* was observed, diagnosed and treated as documented below (case report, n = 2). In an attempt to continue the planned project, we purchased 12 additional dogs from the same breeder. To identify whether a potential contact with *M. haemocanis* might have occurred prior to arrival at our institution, we took samples of whole blood and serum, including blood smears from all dogs within the 1st h after arrival. Animals were splenectomized. *M. haemocanis* was detected. Treatment was initiated and systematic follow-up was performed (prospective follow-up over 120 days; n = 12).

Splenectomy, Postoperative Care

Following overnight starvation, splenectomy was performed under aseptic conditions under general anesthesia (propofol, fentanyl)

and antibiotic prophylaxis (cefuroxim 750 mg), followed by daily clinical evaluations of the dogs. All animals recovered in relation to their preoperative condition. There were no postoperative events of bleeding, suture dehiscence, peritonitis, ileus or wound infection.

After at least 6 weeks of recovery the animals were to undergo the planned hemorrhagic shock experiment. This stepwise experimental procedure has been routinely performed by our group for several years [17].

Detection of Anti-*M. haemocanis* Antibodies

To give indirect evidence for the presence of *M. haemocanis*, we obtained serum samples, which were submitted for serologic testing. Since *M. haemocanis* cross-reacts with *Rickettsia conori*, sera were subjected to the indirect fluorescent antibody test in which *R. conori* was used as antigen (Rickettsia conori-Spot IF, bioMerieux, Lyon, France). FITC-labeled goat anti-dog IgM antibody and FITC-labeled goat anti-dog IgG antibody (KPL, Gaithersburg, Md., USA) were used to detect the presence of dog anti-*M. haemocanis* IgM and IgG antibodies in the dog sera using a fluorescence microscope.

Specific Polymerase Chain Reaction Assay

Identification of the microorganism was performed using standard polymerase chain reaction (PCR) testing. DNA was extracted from 2 ml of whole blood by a standard proteinase K treatment. The technique has recently been described as being able to give evidence of the presence of *M. haemocanis* (formerly *H. canis*) in dogs [18] and *Mycoplasma haemofelis* in cats [19, 20] using a specific representative gene sequence that is largely congruent with minor variations for both subspecies [21]. We chose a segment of 677 bp out of the 16S rRNA gene to identify the parasite. Referring primers were generated based on a BLAST genomic database search [22] at the National Library of Medicine (<http://www.ncbi.nlm.nih.gov>), National Center of Biotechnological Information.

To verify our method and diagnosis, we divided our blood samples and sent 8 whole blood samples for cross-checking to Prof. Dr. J. Messick (VMD, University of Illinois, Urbana-Champaign, Ill., USA), who performed simultaneous PCR. Additional cross-checking was made by a 3rd investigator (Prof. Dr. S. Shaw, Dr. S. Tasker, Acarus Unit, Department of Clinical Veterinary Science, University of Bristol, UK).

Data Analysis, Statistics

Data are presented as single observations over time in dogs 1279 and 1295. Data taken from the newly purchased and prospectively investigated group (n = 12) are depicted as means and standard deviations. Differences of measured values over time were analyzed with a repeated measurements ANOVA (SAS-System™, Cary, N.Y., USA). The α -error threshold was set to 5%.

Results

Case Report

On day 49 after splenectomy, one dog (No. 1279) presented with apathy, inappetence, and a grossly reduced physical condition. Our institutional veterinary consultant found pale conjunctivae, cachexia, and fever

(39.8°C) with no obvious external bleeding. At that time, the hemoglobin concentration was 3.8 g dl⁻¹ (day 49, repeated measurements). Several weeks later, dog 1295, a littermate of the previous dog, displayed very similar clinical symptoms and blood analysis revealed a hemoglobin concentration of 6.1 g dl⁻¹ (day 133; table 1).

While abdominal sonography and chest X-ray displayed no pathological findings in dog 1279, the peripheral blood count showed profound anemia including a prominent left shift of white blood cell distribution (table 1). A bone marrow biopsy showed reduced cellularity with a pronounced increase in erythropoiesis (65%) and, to some extent, in lymphopoiesis (20%). Granulopoiesis was displaced (15%) and megakaryopoiesis was undetectable (0%). Giemsa-stained blood smears of both dogs showed anisocytosis, poikilocytosis, hypochromasia, Jolly bodies, and basophilic or polychromatophilic epierythrocytic and erythrocytic inclusion bodies, which were later identified as resembling *M. haemocanis* (fig. 1). Due to a diagnosis of life-threatening anemia, dog 1279 immediately received 200 ml packed allogeneic red cells (centrifuged at 4,000 g over 10 min) pooled from the seemingly healthy littermates as a single transfusion; methylprednisolone 100 mg was given intravenously to prevent transfusion reactions. Prednisone 2 mg kg⁻¹ daily was continued orally for 4 days to terminate para-infectious hemolytic anemia, and was then tapered off over a period of 10 days. Dog 1295 was treated with oxytetracycline and prednisone alone. Oxytetracycline 40 mg kg⁻¹ daily was given over a period of at least 42 days in all animals. After that time, dogs 1279 and 1295 became vital with no clinical signs of acute anemia or

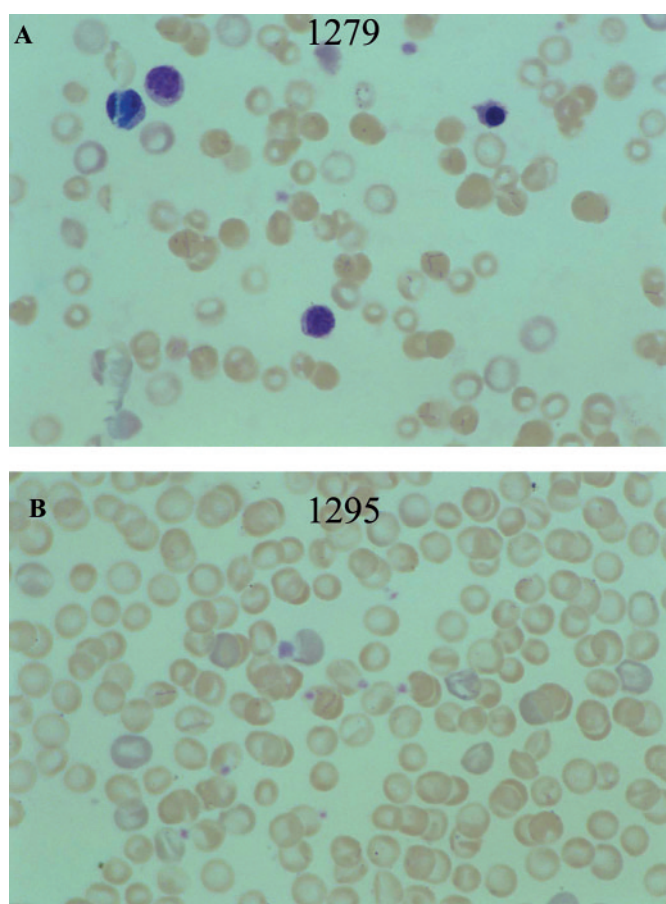


Fig. 1. Blood smears of dogs 1279 (A) and 1295 (B) at different points in time. Small basophilic inclusion bodies are seen on the red blood cells. Sometimes the inclusions were coccoïd; however, chains of organisms also split to produce Y-shaped and bow forms on the red cell surface.

Table 1. Differential blood count during infection and treatment

Animal	Clinical outbreak		During treatment		Treatment complete	
	1279	1295	1279	1295	1279	1295
Postoperative day	49	133	119	140	196	196
Hemoglobin concentration, g dl ⁻¹	3.8	6.1	14.1	8.6	14.0	13.5
Platelet count, × 10 ⁹ l ⁻¹	74	1,130	24	955	426	442
White blood cell count, × 10 ⁹ l ⁻¹	23.9	27.4	8.2	8.4	16.4	13.7
Juveniles, %	21	9	4	–	1	2
Segmented, %	41	66	37	44	68	80
Eosinophilic, %	1	5	–	16	2	3
Basophilic, %	–	–	–	–	–	–
Monocytes, %	3	2	3	4	3	1
Lymphocytes, %	29	18	56	36	26	14

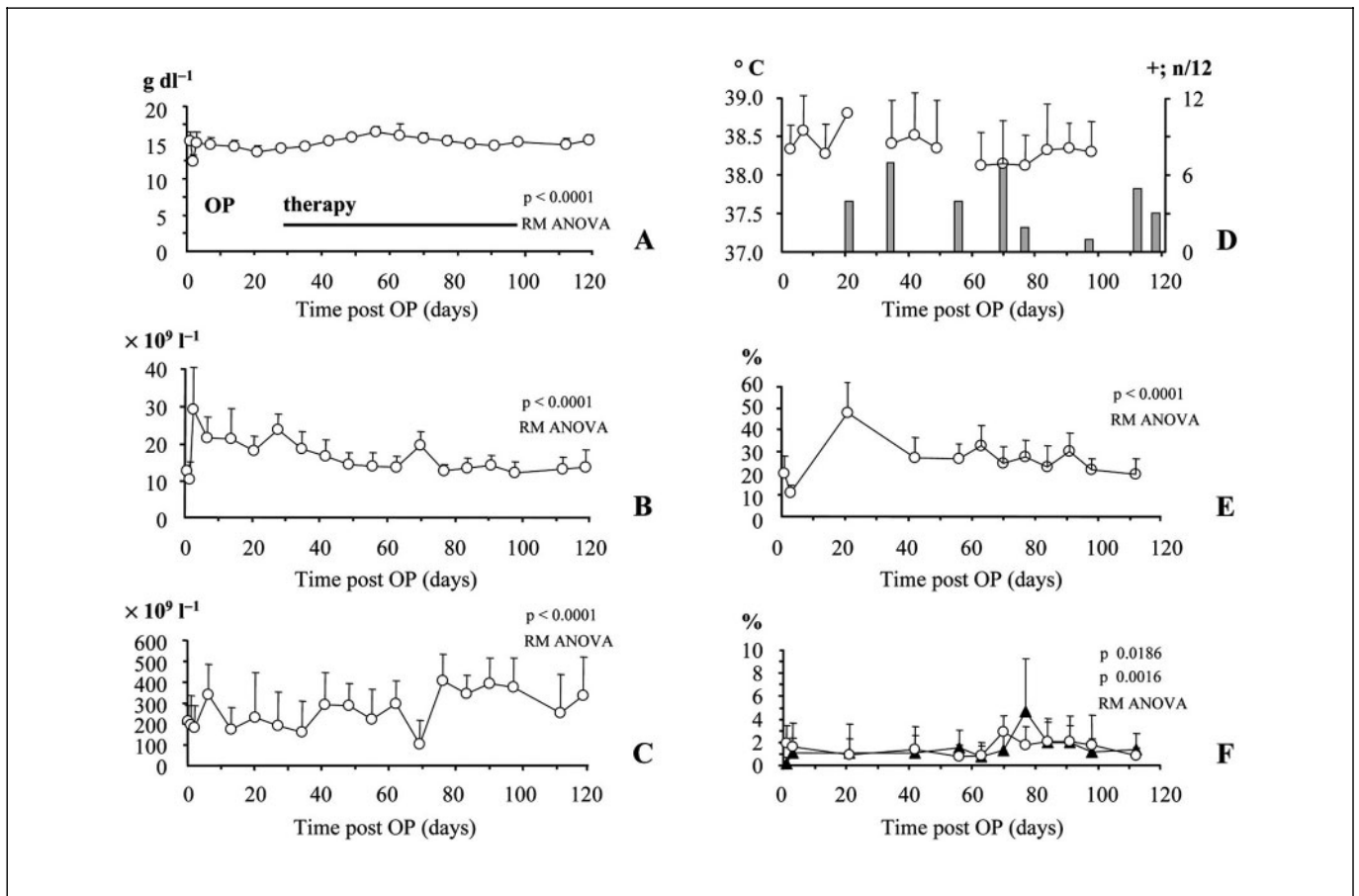


Fig. 2. Changes in hemoglobin concentration (**A**), white blood cell count (**B**), platelet count (**C**), body temperature and blood smear status (**D**), and number of white cell subspecies in the hemogram (lymphocytes, **E**; monocytes, eosinophilic, **F**) over time. Twelve dogs were followed up over a period of 120 days postoperatively. Data are depicted as mean values. The error bars indicate the standard deviation. Significant changes over time (repeated measurements

ANOVA; $p < 0.05$) are indicated. With the initial marked increase in white cell count treatment was commenced stepwise in all dogs. Prednisone $2 \text{ mg kg}^{-1} \text{ day}^{-1}$ was given for 4 days; oxytetracycline $40 \text{ mg kg}^{-1} \text{ day}^{-1}$ was terminated in all dogs on day 98. Of note, cyclic changes in white blood cell and platelet count persisted. However, there was no episode of anemia.

infection, and were included in the planned study. Hemograms (table 1) and standard O_2 transport parameters were all within reference values at that time.

Systematic Postoperative Follow-Up

All 12 animals were deemed healthy on arrival and underwent splenectomy without adverse events. On the 1st postoperative day, we noticed marked leukocytosis ($38 \times 10^9 \text{ l}^{-1}$) and left shift (15% juveniles) accompanied by a temporary drop in hemoglobin concentration by 3 g dl^{-1} . On day 21, a second peak in white blood cell count and a reduction in platelet count became evident together with a rise in rectal temperature to 38.8°C (fig. 2)

and a marked increase in lymphocyte count. We observed *M. haemocanis*-positive blood smears on day 21 (4/12) and 35 (7/12), and significant antibody titers on day 35 (12/12). Treatment was commenced and maintained until day 98. At approximately day 70 another peak in white blood cell count became evident in the presence of critical thrombocytopenia and slight eosinophilia (fig. 2). Blood smears still remained positive for *M. haemocanis* (7/12), despite prolonged antimicrobial therapy (fig. 3).

On day 119, blood smears (3/12), serum antibody status (7/12) and specific PCR testing (8/12) were still positive for *M. haemocanis* (fig. 4).

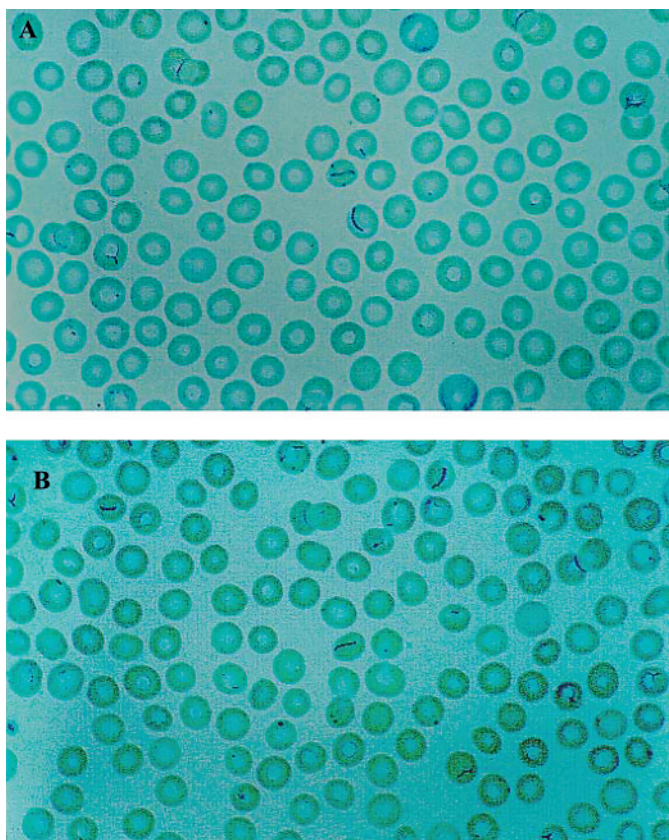


Fig. 3. Chosen blood smears from individual dogs at different points in time. Small basophilic inclusion bodies in rods and doughnut forms are seen, as well as single inclusion bodies. In 3 animals blood smears remained positive for *M. haemocanis* despite antimicrobial therapy over 42 days.

The latter was confirmed in a second PCR (University of Illinois; 7/12); all 7 positive results were confirmed by cloning of almost the entire 16S rRNA gene and subsequent sequence analysis, and by a third PCR (AY 150989 and AY 150988) [23].

Time of Infection

Eight of the 12 serum samples that had been taken within the 1st h after animal arrival at our facility were lost during overseas transport. In 2 of the remaining 4 animal serum specimens, significant titers of antibodies of the IgM type cross-reactive for *M. haemocanis* were detected in the absence of clinical disease (fig. 4).

Termination of Experimental Project

After confirmation of the diagnosis by 3 distinct laboratories and at the time when persistence of *M. haemo-*

canis was evidenced despite completed antimicrobial therapy, the institutional board for animal protection and the Bavarian Government were informed and the experimental series was terminated.

Discussion

Diagnosis of the Disease

Historically, the diagnosis of *M. haemocanis* relies on smears of peripheral blood, in which *M. haemocanis* mostly appears in coccoid form (0.2–0.4 μm), as rings, doughnut forms, or rods [24, 25], but also as streptococcal-like chains or bows [24, 26]. *M. haemocanis* is typically located in the deeply indented folds of the erythrocyte surface. The parasite is Gram-negative and can be visualized by classic Giemsa staining. Serologic testing for anti-*M. haemocanis* cross-reactive antibodies may be helpful. However, today the superior technique for obtaining unequivocal evidence of the presence of *M. haemocanis* is PCR of whole blood [18–20].

Mode of Transmission

It is generally accepted that *M. haemocanis* is transmitted by blood-feeding arthropods, especially the dog tick, *Rhipicephalus sanguineus* [12, 13]. It may, however, be transmitted by oral ingestion or directly penetrating blood inoculation [12, 13]. There is also evidence for a possible materno-fetal transplacental transmission [27].

Appearance of Clinical Disease

In principle, the disease may occur in two forms: a latent form, which may be almost void of symptoms, and an acute form, the clinical appearance of which has been reviewed in detail [13, 15] and is documented in our case report. Symptoms may occur quickly (1–2 weeks) [10, 26] or, as in this case, with a delay (4–9 weeks) [18, 28].

Like others, we observed severe anemia, leukopenia [29, 30], and also leukocytosis [15, 28] together with an initial temporary left shift of white blood cell distribution and delayed lymphocytosis [14, 30]. A reduced platelet count is a frequent observation in dogs bearing *M. haemocanis* and may be associated with bleeding disorders [15, 28].

Pathophysiological Consequences of Infection

To date, it is not clear what damage is done to red cells that are infected with *M. haemocanis*. Growth of the microorganism seems possible without destruction of the

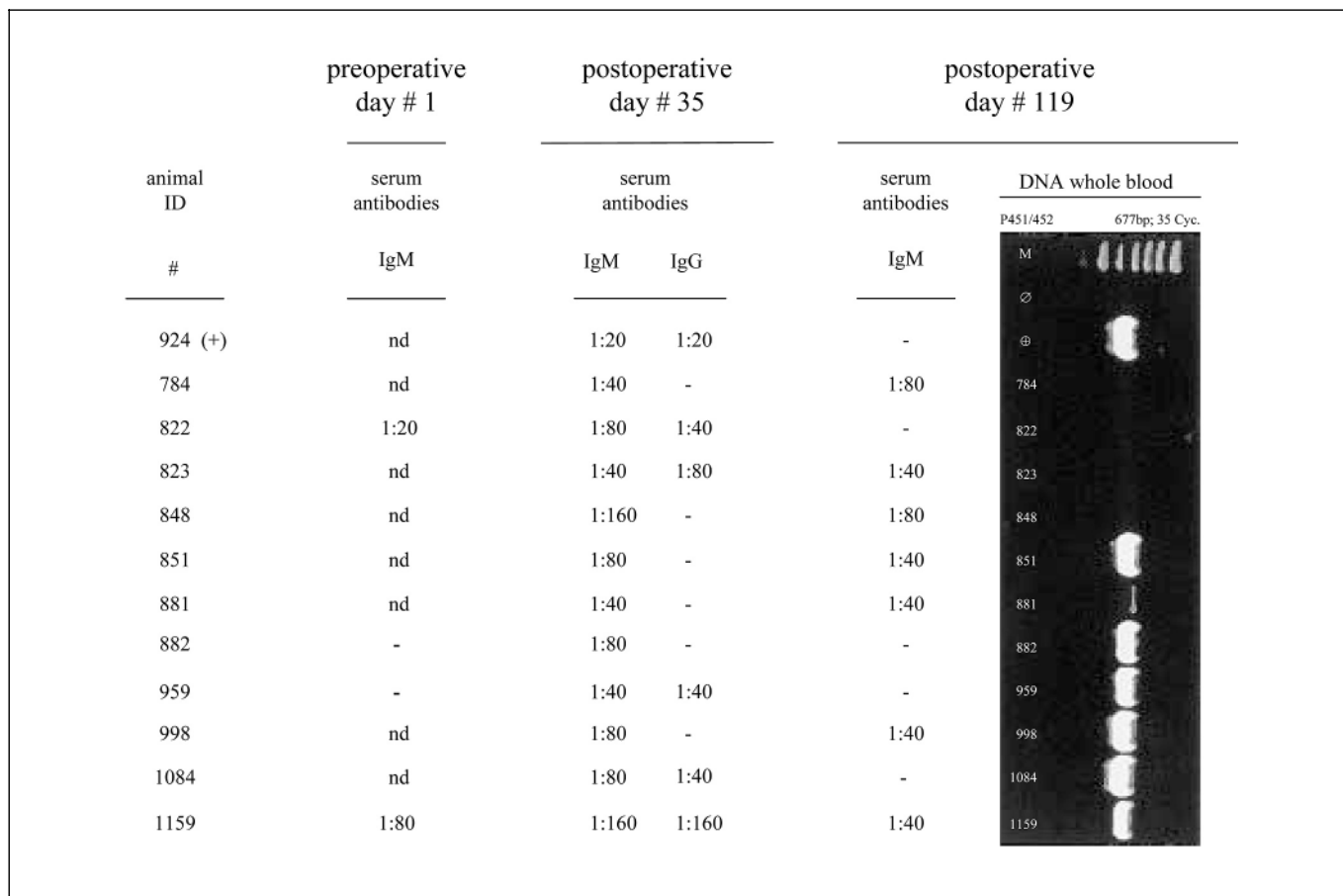


Fig. 4. An overview of the consecutive results from serologic testing and PCRs undertaken in the perioperative period. Serologic testing for *M. haemocanis* cross-reactive antibodies was performed on blood samples that had been withdrawn instantly on arrival from the breeder – prior to admission and hospitalization. Further testing was performed on days 35 and 119 postoperatively, whereas PCR was performed at the last point in time only. The right panel depicts a 1% agarose gel stained with ethidium bromide. The specific signal gives a fragment of 677 bp according to the sequence information (<http://www.ncbi.nlm.nih.gov>, AF 407208). Serologic and PCR data are

plotted on days 1, 35, and 119 (from left to right), to enable direct comparison of results obtained with the different methods. Serologic evidence of contact with *M. haemocanis* was present in these dogs at the time of admission. Over the time course, all animals showed evidence of *M. haemocanis* infection either by light microscopy, serologic testing, or the presence of specific DNA. 924, 784, 822, 823, 848, 851, 881, 882, 959, 998, 1084 and 1159 are the animal identification numbers in the left panel, as well as in the right panel. M = Molecular weight markers; + = positive control; Ø = negative control in a healthy pet dog.

erythrocyte membrane. However, the cyclic nature of the disease and apparent episodes of severe anemia suggest the possibility that red cells might simply be destroyed by the adhering microorganism at a critical point without phagocytosis, or perhaps there is hemolysis by isoagglutinins [24]. It is undeniable, however, that *M. haemocanis* severely alters the shape and deformability of affected red cells and causes anemia. It is obvious that this may interfere with tissue perfusion and oxygen unloading at the microcirculatory level.

Predisposition

The prevalence of *M. haemocanis* in the canine population remains to be determined [13]. In the laboratory setting it might be difficult to prevent the occurrence of *M. haemocanis*, since infection occurs predominantly in immunosuppressed and splenectomized dogs [13–15]. As has been tested by our group in animals from different kennels (unpublished data), and as reported herein, kennel-raised dogs may have a higher prevalence of infection than other dog populations [13]. This speculation needs to be investigated further.

Therapy

The therapy of choice is oxytetracycline at 20–40 mg kg body weight, or doxycycline 5–10 mg kg body weight/day [13, 15]. Administration of prednisone aims to limit hemolysis and erythrocyte phagocytosis. It should be restricted to several days and tapered off when hemoglobin levels start to rise [13]. Of note, systemic antimicrobial therapy may not necessarily fully eliminate *M. haemocanis* from the blood [15], as confirmed by our present results (PCR, blood smears). A relapse may occur as late as 6 months after infection [28]. Splenectomy may contribute to the difficulties in eradication. In summary, the course of the disease is largely unpredictable.

Practical Implications

At present, researchers in the field do need to establish efficacious surveillance and need to conclusively show the absence of infection with *M. haemocanis* to ensure the validity of scientific results in the future. A proposal to reduce the prevalence of *M. haemocanis* in a research laboratory should include repeated eradication of potential vectors like the dog tick *R. sanguineus*, separate housing, frequent blood sampling and evaluation of blood smears, but most importantly, PCR testing. PCR is commercially available from veterinary laboratories, though this may be costly (~40 EUR). Since PCR primers can be identified at the NCBI (see above) and can be purchased, an in-house PCR test for *M. haemocanis* may be established in any laboratory where a PCR cyler exists and expertise is at hand. The time required for cycling and reading does not exceed 6 h. Up to 96 tests might be run simultaneously, and costs for a single tests can be kept low (~2 EUR) as compared to commercial laboratories.

However, the frequency and timing of PCR testing needed to ensure detection of an infection in principle remain to be determined since parasitemia is transient,

which may prevent the detection of *M. haemocanis*. At present, there is a long way to go before a surveillance for *M. haemocanis* can become operative in everyday routine. Therefore, it is the authors' opinion that at present the conduction of experimental studies in splenectomized or potentially immunosuppressed dogs is, in general, not recommended.

Conclusion

We report on the first clinical outbreak of *M. haemocanis* in a European surgical research laboratory. Successful treatment is possible, however, full eradication of *M. haemocanis* is difficult to achieve. Reports on the cumulated outbreak of this disease in immunosuppressed and splenectomized dogs are growing. In experimental cardiovascular studies on dogs, splenectomy is a frequently used procedure which may uncover a chronic *M. haemocanis* infection. Thus, particularly with regard to animal protection issues, we need to carefully consider whether it is prudent to continue performing experiments in splenectomized or immunosuppressed dogs.

Acknowledgments

The authors gratefully acknowledge Mrs. A. Hahmann-Müller's excellent technical assistance in microscopic-morphologic diagnosis, as well as Mrs. Brigitte Blount and her team for the professional animal care. We thank Prof. Susan E. Shaw and Dr. S. Tasker (Acarus Unit, Department of Clinical Veterinary Science, University of Bristol, UK) for additional confirmation of diagnosis. We are also thankful for the listing of the sequence of two of our isolates, 127 bp and 130 bp, in the International Genebank under accession numbers AY 150989 and AY 150988, respectively. We further gratefully acknowledge that the breeder did not charge our institution for the animals included in this case report.

References

- 1 Walcott WW: Standardization of experimental hemorrhagic shock. *Am J Physiol* 1945;143: 254–261.
- 2 Wiggers CJ, Werle JM: Exploration of a method for standardizing hemorrhagic shock. *Proc Soc Exp Biol Med* 1942;49:604–606.
- 3 Crowell JW, Smith EE: Oxygen deficit and irreversible hemorrhagic shock. *Am J Physiol* 1964;206:313–316.
- 4 Dunham CM, Siegel JH, Weireter L, Fabian M, Goodarzi S, Guadalupi P, Gettings L, Linberg SE, Vary TC: Oxygen debt and metabolic acidemia as quantitative predictors of mortality and the severity of the ischemic insult in hemorrhagic shock. *Crit Care Med* 1991;19: 231–243.
- 5 Davies BN, Withrington PG: The action of drugs on the smooth muscle of the capsule and blood vessels of the spleen. *Pharmacol Rev* 1973;25:373–413.
- 6 Zweifach BW: Aspects of comparative physiology of laboratory animals relative to the problem of experimental shock. *Fed Proc* 1961;20: 18–27.
- 7 Hartwig G, Hartwig HG: Structural characteristics of the mammalian spleen indicating storage and release of red blood cells. Aspects of evolutionary and environmental demands. *Experientia* 1985;41:159–163.

- 8 Ojiri Y, Noguchi K, Shiroma N, Matsuzaki T, Sakanashi M, Sakanashi M: Uneven changes in circulating blood cell counts with adrenergic stimulation to the canine spleen. *Clin Exp Pharmacol Physiol* 2002;29:53–39.
- 9 Withrington PG, Ansari N, Croxton R, De Nucci G, Vane JR: The actions of endothelins-1 and -3 on the vascular and capsular smooth muscle of the isolated blood perfused spleen of the dog. *Br J Pharmacol* 1992;105:490–494.
- 10 Pryor WH Jr, Bradbury RP: *Haemobartonella canis* infection in research dogs. *Lab Anim Sci* 1975;25:566–569.
- 11 West HJ: *Haemobartonellosis* in the dog. *J Small Anim Pract* 1979;20:543–549.
- 12 Seneviratna P, Weerasinghe N, Ariyadasa S: Transmission of *Haemobartonella canis* by the dog tick, *Rhipicephalus sanguineus*. *Res Vet Sci* 1973;14:112–114.
- 13 Messick JB: New perspectives about hemotrophic mycoplasma (formerly, *Haemobartonella* and *Eperythrozoon* species) infections in dogs and cats. *Vet Clin North Am Small Anim Pract* 2003;33:1453–1465.
- 14 Gretillat S: *Haemobartonellosis canis* (Kikueth, 1928) in the blood of dogs with parvovirus disease. *J Small Anim Pract* 1981;22:647–653.
- 15 Hoskins JD: Canine haemobartonellosis, canine hepatozoonosis, and feline cytauxzoonosis. *Vet Clin North Am Small Anim Pract* 1991;21:129–140.
- 16 Lester SL, Hume JB, Phipps B: *Haemobartonella canis* infection following splenectomy and transfusion. *Can Vet J* 1995;36:444–445.
- 17 Habler OP, Kleen MS, Hutter JW, Podtschaske AH, Tiede M, Kemming GI, Welte MV, Corso CO, Batra S, Keipert PE, Faithfull NS, Messmer KF: Hemodilution and intravenous perflubron emulsion as an alternative to blood transfusion: Effects on tissue oxygenation during profound hemodilution in anesthetized dogs. *Transfusion* 1998;38:145–155.
- 18 Brinson J, Messick JB: Use of a polymerase chain reaction assay for detection of *Haemobartonella canis* in a dog. *J Am Vet Med Assoc* 2001;218:1943–1945.
- 19 Berent LM, Messick JB, Cooper SK: Detection of *Haemobartonella felis* in cats with experimentally induced acute and chronic infections, using a polymerase chain reaction assay. *Am J Vet Res* 1998;59:1215–1220.
- 20 Messick JB, Berent LM, Cooper SK: Development and evaluation of a PCR-based assay for detection of *Haemobartonella felis* in cats and differentiation of *H. felis* from related bacteria by restriction fragment polymorphism analysis. *J Clin Monit Comput* 1998;36:462–466.
- 21 Birkenheuer A, Breidtschwerdt EB, Alleman R, Pitulle C: Differentiation of *Haemobartonella canis* and *Mycoplasma haemofelis* on the basis of comparative analysis of gene sequences. *Am J Vet Res* 2002;63:1385–1388.
- 22 Altschul SF, Madden TL, Schäffer AA, Zhang J, Zhang Z, Miller W, Lipman DJ: Gapped BLAST and PSI BLAST: A new generation of protein database search programs. *Nucleic Acids Res* 1997;25:3389–3402.
- 23 Tasker S, Helps CR, Day MJ, Harbour DA, Shaw SE, Harrus S, Baneth G, Lobetti RG, Malik R, Beaufile CR, Belford CR, Gruffydd-Jones TJ: Phylogenetic analysis of hemoplasma species: An international study. *J Clin Microbiol* 2003;41:3877–3880.
- 24 Venable JH, Ewing SA: Fine-structure of *Haemobartonella canis* (Rickettsiales: Bartonellaceae) and its relation to the host erythrocyte. *J Parasitol* 1968;54:259–268.
- 25 Messick JB, Walker PG, Raphael W, Berent L, Shi X: '*Candidatus mycoplasma haemodidelphidis*' sp. nov., '*Candidatus mycoplasma haemolamae*' sp. nov. and *Mycoplasma haemocanis* comb. nov., haemotrophic parasites from a naturally infected opossum (*Didelphis virginiana*), alpaca (*Lama pacos*) and dog (*Canis familiaris*): Phylogenetic and secondary structural relatedness of their 16S rRNA genes to other mycoplasmas. *Int J Syst Evol Microbiol* 2002;52:693–698.
- 26 Wright IG: The isolation of *Haemobartonella canis* in association with *Babesia canis* in a splenectomized dog. *Aust Vet J* 1971;47:157–159.
- 27 Krakowka S: Transplacentally acquired microbial and parasitic diseases of dogs. *J Am Vet Med Assoc* 1977;171:750–753.
- 28 Brodey RS, Schalm OW: Hemobartonellosis and thrombocytopenic purpura in a dog. *J Am Vet Med Assoc* 1963;143:1231–1236.
- 29 Benjamin MM, Lumb WV: *Haemobartonella canis* infection in a dog. *J Am Vet Med Assoc* 1959;135:388–390.
- 30 Donovan EF, Loeb WF: Hemobartonellosis in the dog. *Vet Med* 1960;55:57–62.