

## Bladder Cancer

European  
Urology

Eur Urol 1999;36:386–392

Accepted after revision: April 13, 1999

# Transurethral Resection and Surveillance of Bladder Cancer Supported by 5-Aminolevulinic Acid-Induced Fluorescence Endoscopy

Martin Kriegmair Dirk Zaak Helmut Stepp Herbert Stepp  
Reinhold Baumgartner Ruth Knuechel Alfons Hofstetter

Department of Urology, University of Munich, and Institute of Pathology, University of Regensburg, Germany

### Key Words

5-Aminolevulinic acid · Fluorescence · Bladder neoplasm

### Abstract

**Purpose:** We determined whether neoplastic disease, which was missed under white light can be found during transurethral resection of bladder cancer by 5-aminolevulinic acid-induced porphyrin fluorescence. **Materials and Methods:** 5-Aminolevulinic acid-induced fluorescence endoscopy was carried out in 328 cases. A 3% 5-aminolevulinic acid solution was instilled intravesically in a mean time of 2.8 h before endoscopy. The fluorescence was excited by a special incoherent light source which provided blue light in addition to white light. **Results:** In 82 (25%) cases additional neoplastic lesions were found only because of their red porphyrin fluorescence which was induced by 5-aminolevulinic acid. 31% of these neoplastic foci which were found in normal and nonspecific inflamed mucosa had a poorly differentiated histology. **Conclusions:** 5-Aminolevulinic acid facilitates detection of neoplastic disease during transurethral resection of bladder cancer and increases the accuracy of diagnosis.

### Introduction

Flat transitional cell carcinoma with insignificant enhancement of the urothelium and neoplastic lesions like dysplasia or carcinoma in situ without thickening of the epithelium can easily be missed during transurethral resection [1]. Thus, methods for in vivo marking of urothelial cancer have been sought [2–5]. We have applied a method for fluorescence marking of urothelial neoplasia of the bladder, which is based on intravesical application of 5-aminolevulinic acid (5-ALA) [6]. 5-ALA is an initial substrate of the heme biosynthesis. Exogenous application of 5-ALA induces an accumulation of fluorescent porphyrins mainly protoporphyrin IX (PPIX) in tissues of epithelial origin [7].

Using a krypton ion laser ( $\lambda = 406.7$  nm) for fluorescence excitation, we have previously reported that the 5-ALA-induced fluorescence is significantly correlated with neoplastic findings [6], including a low or negative PPIX fluorescence in adjacent stromal cells, as shown by fluorescence histology of sections [8]. However, the spread of the procedure was impaired because of the large-scale laser technology and the price of 5-ALA. The krypton ion laser was replaced by a special incoherent diagnosis light system (D-light, Storz GmbH, Tuttlingen, Germany). We report on our first clinical experience with 5-ALA-induced fluorescence endoscopy (AFE) for detection of primary and recurrent bladder cancer using the D-light.

KARGER

Fax + 41 61 306 12 34  
E-Mail [karger@karger.ch](mailto:karger@karger.ch)  
[www.karger.com](http://www.karger.com)

© 1999 S. Karger AG, Basel  
0302-2838/99/0365-0386\$17.50/0

Accessible online at:  
<http://BioMedNet.com/karger>

Priv.-Doz. Dr. med. Martin Kriegmair  
Karwendelstrasse 6  
D-85604 Pöding (Germany)  
Tel. +49 8106 303 010, Fax +49 8106 303 011  
E-Mail [Kriegmair@uro.med.uni-muenchen.de](mailto:Kriegmair@uro.med.uni-muenchen.de)

## Materials and Methods

### Patients

A total of 208 patients underwent 328 5-ALA-induced fluorescence endoscopies. 72 patients were inspected for primary bladder cancer, and 136 patients were under surveillance because of prior transitional cell carcinoma of the urinary bladder. The age range of the patients (38 women and 170 men) in which fluorescence endoscopy was carried out was 16–89 years with an average age of 64.8 years. The number of AFE per patient ranged from 1 to 7 with a medium of 1.6. The average time of follow-up was 11.1 months (range 1–29 months).

The patients which were previously treated for bladder cancer had a history of multiple transurethral resections (range 1–20, average 3.5) and intravesical instillations with BCG (50 patients) or Mitomycin C (49 patients).

**5-ALA Administration.** 1.5 g of 5-aminolevulinic acid hydrochloride (Medac GmbH, Hamburg, Germany) dissolved in 50 ml 1.4% NaHCO<sub>3</sub> was instilled intravesically with a 14F catheter 2–3 h prior to endoscopy. The catheter was removed immediately after instillation. The pH value of the solution was 4.9. The solution was freshly prepared immediately before instillation and passed through a 0.2- $\mu$ m filter to eliminate pyrogens. The individual intravesical retention ranged from 0.5 to 5.5 h (average  $2.8 \pm 1.4$ ). 12 patients voided within 1 h after intravesical instillation of the 5-ALA solution and were excluded from evaluation.

**Fluorescence Excitation.** The D-light (Storz GmbH) provides blue light (375–440 nm) for fluorescence excitation of PPIX. A yellow longpass filter fit into the eyepiece of the endoscope reduces the blue excitation light and enhances the fluorescence contrast. In order to keep the transmission of the blue excitation light minimal the fiberoptic light cord was integrated into the telescope (30-degree lens). Switching between blue and white light is possible by means of a foot pedal.

### Fluorescence Endoscopy

In 288 patients, a bladder washing with 100 ml 0.9% sodium chloride solution was carried out at the beginning of endoscopy before AFE. In all cases endoscopy started with careful inspection under white light. Particular attention was paid, whether tumors detected with white light during endoscopy showed red fluorescence under blue-light excitation. The number and location of tumors under white light were recorded. The endoscopy was continued under blue excitation light and all and all fluorescing lesions were documented. Special attention was paid whether these lesions were detected under white light or not. The procedure went on with resection of all exophytic lesions by means of a 24F continuous flow endoscope (Storz GmbH). In addition, biopsies from fluorescing areas, which appeared to be normal or nonspecifically inflamed were taken, and an attempt was made to resect or coagulate these flat lesions. Also, specimens were obtained with the electrical cutting loop from suspicious areas which were fluorescence negative. The fluorescence of the lesions was judged at the extended urinary bladders which were free of folds. Resection of tumors was carried out with the naked eye or with support of a special RGB-endocamera (Telecam SL, Storz GmbH). The controller of the one-chip charge coupled device camera is equipped with a frame store, enabling target integration. 15 or 8 frames per second were used most frequently. The optical transmission to the red channel had been optimized and the sensitivity balance of the colors can be performed independently for white light and blue fluorescence excitation light.

### Evaluation of Data

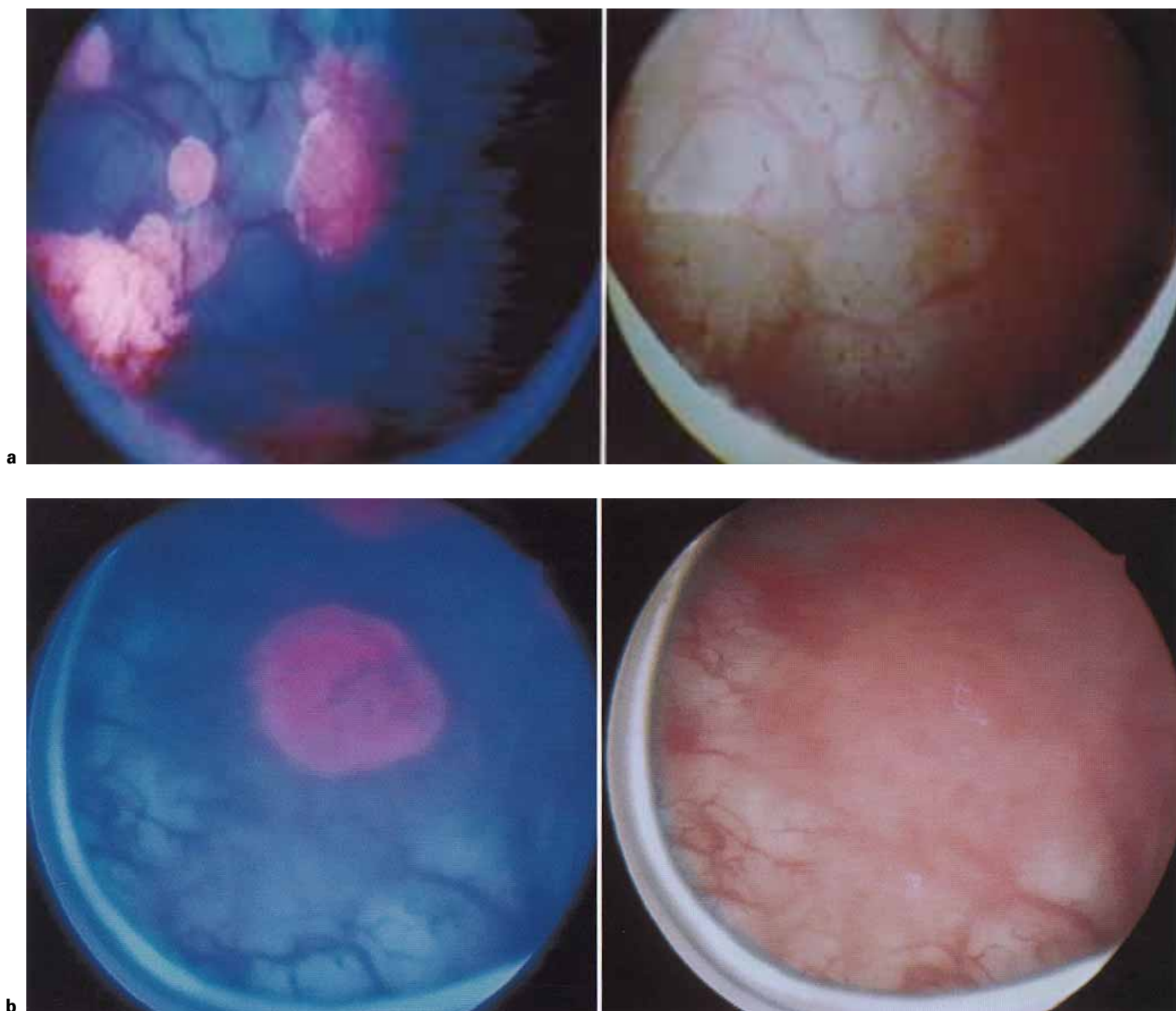
Results of AFE are described in a per patient fashion. Low-grade dysplasias were judged as benign. If lesions with different gradings were found the worst diagnosis was taken into account.

## Results

Papillary urothelial cancer and carcinoma in situ developed a brilliant red fluorescence (fig. 1). In contrast, the adjacent normal nonfluorescent urothelium appeared blue. In table 1, the results of the 328 AFE are listed. In 159 AFE, neoplastic lesions were resected or biopsied. In 82 AFE, additional dysplastic or malignant urothelium was found only because of the red PPIX fluorescence. 39 of these 82 AFE had been carried out in patients who were inspected for primary bladder cancer, whereas 43 cases had a history of bladder cancer. In 97 AFE only fluorescing benign biopsies had been taken. 48 AFE were managed without biopsies because of complete fluorescence-negative findings and normal findings in white light. In another 20 AFE without papillary tumors, the mucosa of the bladder was completely red fluorescence-negative. However, biopsies from suspicious areas under white light were taken in these. None of these biopsies revealed neoplastic disease. In 4 patients pT<sub>a</sub>G<sub>I</sub> tumors were observed under white light which did not fluoresce in AFE.

Table 2 demonstrates the cases in which only normal or nonspecific inflammatory lesions were detected at white light endoscopy. The patients reported in table 3 represent the group which showed exophytic tumors at white light endoscopy. The sole detection of tumorous lesions by red PPIX fluorescence in the two groups shown in tables 2 and 3 can be summed up with the following numbers: dysplasias were detected in 24 AFE, carcinoma in situ (CIS) in 22, high-grade papillary TCC was discovered in 4, and papillary lesions of moderate and low differentiation in 32 AFE. Of 22 patients with CIS, 16 patients had additional flat dysplastic lesions and 3 patients showed T<sub>a</sub>G<sub>I-II</sub> lesions. In none of the 4 patients with T<sub>a-1</sub> G<sub>III</sub> tumors was CIS found.

In the group of patients without exophytic tumors 29 patients presented a cytology positive or suspicious for disease. In 14 cases the cytological findings were verified by AFE detecting the precise site of malignancy within the bladder. Despite negative cytology, moderate dysplasia, CIS, high-grade superficial urothelial cancer and low-to-moderately differentiated superficial cancer were detected in 13, 4, 3 and 11 AFE, respectively, only because of their red porphyrin fluorescence. 15 patients had a positive cytology, however, no neoplastic biopsies were found



**Fig. 1. a** Endoscopic view of red fluorescing multifocal papillary tumors in contrast to their appearance under white light. Reduced from  $\times 5$ . **b** Endoscopic view of a red fluorescing lesion of carcinoma in situ in contrast to its appearance under white light. Reduced from  $\times 8$ .

within the bladder by AFE. In all these cases neoplastic disease of the upper urinary tract was excluded by a retrograde pyelography and washing cytology of the renal pelvis. Details on these findings are given in table 4. In 4 of 13 patients with a cytological diagnosis of moderate dysplasia, disease was verified histologically under further surveillance by AFE-guided biopsies. Two cases with flat T<sub>a</sub> G<sub>I-II</sub> tumors and two with CIS were found. In 2 pa-

tients cytological diagnosis was high-grade dysplasia. In 1 patient with a follow-up of 10 months, no neoplastic lesion has been localized so far. In the other patient a small moderately dysplastic lesion was found 8 months later by AFE-guided biopsies. Local or systemic side effects especially cutaneous photosensitization due to the instillation of 5-ALA and the use of blue light for fluorescence excitation were not observed.

**Table 1.** Final results of the 5-aminolevulinic acid-induced fluorescence endoscopy findings

AFE		Number of resected areas range/average	Result of AFE
n	%		
77	23	1–10/2.6	all neoplastic lesions detected were fluorescence positive but were visible under white light
82	25	1–11/4.1	neoplastic lesions were detected additionally only because of red PPIX fluorescence signal
97	30	1–7/2.2	all fluorescing lesions biopsied were benign
48	15	0/0	the complete urothelium of the bladder was fluorescence negative, no biopsies were taken
20	6	1–10/1.5	the complete urothelium of the bladder was fluorescence negative; all biopsies taken were benign
4	1	1–5/1.9	the complete urothelium of the bladder was fluorescence negative; additionally fluorescence-negative small papillary tumors were found
328	100	0–11/2.2	total

**Table 2.** Detection of additional neoplasias in flat lesions, solely due to the positive PPIX fluorescence in patients with exophytic tumors

Bladder washing cytology	Total AFE	AFE with neoplastic disease detected only because of positive fluorescence			
		Dys II	Cis	T <sub>a-1</sub> G <sub>III</sub>	T <sub>a-1</sub> G <sub>I-II</sub>
Positive	59	4	11	–	17
Negative	88	3	2	2	10
Not done	20	1	–	–	3

**Table 3.** Detection of additional neoplasias in flat lesions, solely due to the positive PPIX fluorescence in patients with normal or nonspecific inflamed mucosa

Bladder washing cytology	Total AFE	AFE with neoplastic disease detected only because of positive fluorescence			
		Dys II	Cis	T <sub>a-1</sub> G <sub>III</sub>	T <sub>a-1</sub> G <sub>I-II</sub>
Positive	29	6	6	1	1
Negative	112	10	2	1	1
Not done	20	–	1	–	–

**Table 4.** Outcome of 15 patients with complete fluorescence negative findings during the initial AFE

Bladder washing cytology	Patients	Follow-up months	Outcome of patients			
			NED	positive AFE-guided biopsies		
				Dys II	T <sub>a</sub> G <sub>I-II</sub>	Cis
Moderate dysplastic	13	5–18	9	–	2	2
High-grade dysplastic or carcinoma in situ	2	8, 10	1	1	–	–

## Discussion

The risk of overlooking neoplastic lesions of the bladder using white-light endoscopy is significant. After transurethral resection of superficial bladder cancer, tumor remnants were found in up to 43% of the cases at repeated resection 1–2 weeks later [9–11]. Even in the case of solitary superficial bladder tumors residual disease was found in 24% at a second transurethral resection 5 weeks later [11]. The authors underlined the quality of their first resection by the fact that the second resection revealed infiltrative growth in only 2% of the cases. Therefore, most of this overlooked neoplasms came from positive margins or heterotopic lesions.

Klän et al. [9] reported on a fractionated resection of T<sub>1</sub> transitional cell cancer. In 28% of the patients positive tumor margins were found while residual disease from the tumor base was not observed in any case. A routine second resection was carried out 8–14 days later and revealed residual disease in 50% of the patients despite the surgical report of complete resection. 76% of the missed lesions were found to be visible tumors at the repeated resection. The authors concluded that the extent of the lesions can easily be misjudged even by experienced surgeons. AFE was very helpful in finding residual tumor at the end of the transurethral resection. Especially the borderline of a tumor was more clearly visible than it was under white light. Neoplastic lesions in the surroundings of exophytic tumors which appeared normal or nonspecifically inflamed were marked by brightly shining red PPIX fluorescence. In the case of multiple tumors, the spots of neoplastic disease were found more easily and more promptly by AFE compared to white-light endoscopy alone.

Fitzpatrick et al. [12] reported on 414 newly diagnosed patients with pT<sub>a</sub> G<sub>I-II</sub> tumors. Patients who underwent intravesical therapy during their follow-up were excluded from this study. In one third of the patients recurrent, or more likely residual, disease was found 3 months after the initial resection. 90% of these patients had further recurrences thereafter, whereas only 21% of the patients who were free of tumor 3 months after the initial resection demonstrated recurrent tumor during further follow-up. The response to the initial treatment of superficial bladder cancer for the outcome of the patients has also been stressed as relevant by Pryor. [13]. Therefore, a complete removal of tumorous lesions from the bladder seems advisable. Especially flat lesions as CIS which may be concealed in the nonspecific inflamed or normal-appearing mucosa are of crucial effect on the rates of progression

and recurrence and require adequate intravesical immunotherapy without delay [14–16]. Random biopsies were found to be an insufficient method for detecting flat lesions [17, 18]. In a retrospective study Kiemeny et al. [17] found no correlation between patient outcome where selected mucosal biopsies were not performed or, if done, were normal. However, if dysplasia or CIS were found in patients, they had a statistically significant higher risk of tumor progression. Therefore, random biopsies seem to be inadequate since relevant early stage and precancerous lesions are often missed. Cytology of voided urine or bladder washings are valuable for the diagnosis, especially of high-grade lesions. However, recent prospective trials have resulted in a disappointingly low sensitivity of 54% for detecting CIS [19]. Using white-light endoscopy, the detection of neoplasms is limited to morphological patterns. Since the 1960s, urologists have sought for methods of *in vivo* labeling neoplastic lesions in order to decrease the risk of overlooking tumors by the help of an additional color contrast.

Methods based on detection of the fluorescence of systemically administered tetracycline, systemic porphyrin mixtures or fluorescein have only been tested in a few patients and have been abandoned. Intravesical instillation of methylene blue was also proven unsuitable, since 70% of CIS and 84% of dysplastic lesions were not stained [4].

We have been investigating 5-ALA for detection of urothelial cancer since 1991. 5-ALA is a precursor of the heme biosynthesis and induces an accumulation of fluorescent endogenous porphyrins, mainly protoporphyrin IX (PPIX) in tissues of epithelial origin [7]. Following intravesical application of 5-ALA, we could demonstrate a selective accumulation of PPIX in urothelial cancer providing an intensive color contrast between red fluorescing malignant lesions and the nonfluorescing normal blue mucosa [6]. Spectral measurements *in vivo* showed a more than 10-fold higher intensity of fluorescence of urothelial cancer in comparison to normal urothelium [20]. Due to the topical mode of administration of 5-ALA and the fast metabolism, only minor side effects such as urgency and alginuresis were observed in 7% of the cases [21, 23].

Initially, a krypton ion laser was used for fluorescence excitation. Based on a biopsy-related evaluation, we reported a significant increase in sensitivity for the diagnosis of neoplastic urothelial lesions such as dysplasia and CIS as well as for papillary tumors by the additional evaluation of the porphyrin fluorescence. In total, the procedure was marked by a sensitivity of 96% and a specificity of 65% [21].

The outstanding sensitivity of the procedure was confirmed by the investigations of Jichlinski et al. [22]. Using this method of fluorescence detection they found 47 of 97 foci of carcinoma only by fluorescence markings which were invisible under white-light observation and concluded that the sensitivity of the method appears to be twice as good as conventional white-light cystoscopy. The large-scale laser technology for excitation of the PPIX fluorescence was replaced by the D-light® which is a specially designed incoherent diagnosis light system. This equipment meets all the requirements for a daily routine procedure and can be used in combination with standard urological endoscopes. Based on a per patient fashion, we found that the patients had a benefit in 150 of 328 AFE cases (45%). In 82 cystoscopies additional neoplastic lesions were found which would have been missed under white-light observation alone. In 68 cases of complete fluorescence negative mucosa no biopsies would have been necessary due to the high sensitivity of the procedure. 31% of the malignant foci which were found only because of their positive PPIX fluorescence signal in the normal-appearing or nonspecific inflamed mucosa were high-risk lesions such as carcinoma in situ or poorly differentiated papillary tumors. In 30% of the AFE, exclusively false-positive findings were observed. This seems to be acceptable as in total the mean number of biopsies was low with 2.2 per patient. No matter how, it is obviously significantly less than the number of random biopsies carried out under white light. False-positive responses were frequently found in lesions with increased cellular proliferation due to inflammation or scarring. However, these lesions apparently showed a lower fluorescence intensity. Therefore, methods for fluorescence quantification have been established and are now under investigation in order to reduce the rate of false-positive biopsies [24]. Further,

false-positive lesions as simple hyperplasias have shown to already have genetic changes identical to those of papillary tumors of the same patient [25]. This result indicates that at least part of the false-positive lesions are tumor precursors and is investigated intensively in longitudinal and horizontal studies of patient material.

There is a bad correlation between cytology and AFE. However, cytology and AFE are not competitive methods as cytology is a noninvasive and AFE is an invasive procedure. AFE can help clarify suspicious cytological findings and therefore AFE-guided biopsies and cytology seem to be complementary methods for accurate diagnosis of bladder cancer. In 14 of 112 patients who had no exophytic tumors and had a negative cytology, a neoplastic lesion was found in fluorescing areas of the bladder wall. In 5 of 15 patients with complete negative fluorescing mucosa but positive cytology, neoplastic disease was found later due to positive AFE-guided biopsies during follow-up of these patients.

## Conclusions

5-Aminolevulinic acid-based fluorescence endoscopy facilitates detection of neoplastic lesions within the bladder during transurethral resection. In case of complete negative fluorescence findings, endoscopy can be done without biopsies due to the high sensitivity of the procedure. A decrease of the rate of overlooked tumors is expected for transurethral resection supported by 5-aminolevulinic acid-induced fluorescence endoscopy. A resulting relatively decreased number of recurrences has to be documented in prospective randomized trials.

## Acknowledgement

Supported by grants from the Deutsche Forschungsgemeinschaft (DFG No. Kr1645/1-1).

## References

- 1 Soloway MS, Murphy W, Rao MK, Cox C: Serial multiple-site biopsies in patients with bladder cancer. *J Urol* 1978;120:57-59.
- 2 Whitmore WF Jr, Bush IM: Ultraviolet cystoscopy in patients with bladder cancer. *Trans Am Assoc Genitourin Surg* 1965;57:149-155.
- 3 Jochem D, Baumgartner R, Fuchs N, Lenz H, Stepp H, Unsöld E: Fluorescence diagnosis of porphyrin-marked urothelial tumors: Status of experimental development. *Urologe [A]* 1989; 28:59-64.
- 4 Vicente J, Chechile G, Algaba F: Value of in vivo mucosa-staining test with methylene blue in the diagnosis of pretumoral and tumoral lesions of the bladder. *Eur Urol* 1987;13:15-16.
- 5 Zimmern PE, Laub D, Leach GE: Fluorescein angiography of the bladder: technique and relevance to bladder cancer and interstitial cystitis patients. *J Urol* 1995;154:62-65.
- 6 Kriegmaier M, Baumgartner R, Knuechel R, Steinbach P, Ehsan A, Lumper W, Hofstaedter F, Hofstetter A: Fluorescence photodetection of neoplastic urothelial lesions following intravesical instillation of 5-aminolevulinic acid. *Urology* 1994;44:836-841.
- 7 Kennedy JC, Pottier RH: Endogenous protoporphyrin IX; a clinically useful photosensitizer for photodynamic therapy. *J Photochem Photobiol [B]* 1992;14:275-292.

- 8 Steinbach P, Kriegmaier M, Baumgartner R, Hofstaedter F, Knuechel R: Intravesical instillation of 5-aminolevulinic acid: the fluorescent metabolite is limited to urothelial cells. *Urology* 1994;44:676–681.
- 9 Klän R, Loy V, Huland H: Residual tumor discovered in routine second transurethral resection in patients with stage T1 transitional cell carcinoma of the bladder. *J Urol* 1991;146:316–318.
- 10 Vögeli TA, Grimm MO, Ackermann R: Prospective study for quality control of TUR of bladder tumors by routine 2nd TUR. *J Urol* 1998;159(suppl):143.
- 11 Köhrmann KU, Woeste M, Kappes J, Rassweiler J, Alken P: Der Wert der transurethralen Nachresektion beim oberflächlichen Harnblasenkarzinom. *Akt Urol* 1994;25:208–213.
- 12 Fitzpatrick JM, West AB, Butler MR, Lane V, O'Flynn JD: Superficial bladder tumors (stage pTa, grades 1 and 2): The importance of recurrence pattern following initial resection. *J Urol* 1986;135:920–922.
- 13 Pryor JP: Factors influencing the survival of patients with transitional cell tumours of the urinary bladder. *Br J Urol* 1973;45:586–592.
- 14 Smith G, Elton RA, Beynon LL, Newsam JE, Chisholm GD, Hargreave TB: Prognostic significance of biopsy results of normal-looking mucosa in cases of superficial bladder cancer. *Br J Urol* 1983;55:665–669.
- 15 Heney NM, Ahmed S, Flanagan MJ, Frable W, Corder MP, Hafermann MD, Hawkins IR: Superficial bladder cancer: progression and recurrence. *J Urol* 1983;130:1083–1086.
- 16 Flamm J, Dona S: The significance of bladder quadrant biopsies in patients with primary superficial bladder carcinoma. *Eur Urol* 1989;2:81–85.
- 17 Kiemeny LA, Witjes JA, Heijbroek RP, Verbeek AL, Debryne FM: Predictability of recurrent and progressive disease in individual patients with primary superficial bladder cancer. *J Urol* 1993;150:60–64.
- 18 Kiemeny LA, Witjes JA, Heijbroek RP, Koper NP, Verbeek AL, Debruyne FM: Should random urothelial biopsies be taken from patients with primary superficial bladder cancer? A decision analysis. Members of the Dutch South-East Co-Operative Urological Group. *Br J Urol* 1994;73:164–171.
- 19 Sarosdy MF, deVere White RW, Soloway MS, Sheinfeld J, Hudson MA, Schellhammer PF, Jarowenko MV, Adams G, Blumenstein BA: Results of a multicenter trial using the BTA test to monitor for and diagnose recurrent bladder cancer. *J Urol* 1995;154:379–384.
- 20 Kriegmaier M, Stepp H, Steinbach P, Lumper W, Ehsan A, Stepp HG, Rick K, Baumgartner R, Hofstetter A: Fluorescence cystoscopy following intravesical instillation of 5-aminolevulinic acid: A new procedure with high sensitivity for detection of hardly visible urothelial neoplasias. *Urol Int* 1995;55:190–196.
- 21 Kriegmaier M, Baumgartner R, Knuchel R, Stepp H, Hofstaedter F, Hofstetter A: Detection of early bladder cancer by 5-aminolevulinic acid induced porphyrin fluorescence. *J Urol* 1996;155:105–110.
- 22 Jichlinski P, Forrer M, Mizeret J, Glanzmann T, Braichotte D, Wagnieres G, Zimmer G, Guillou L, Schmidlin F, Graber P, van den Bergh H, Leisinger HJ: Clinical evaluation of a method for detecting superficial surgical transitional cell carcinoma of the bladder by light-induced fluorescence of protoporphyrin IX following the topical application of 5-aminolevulinic acid: Preliminary results. *Lasers Surg Med* 1997;20:402–408.
- 23 Rick K, Sroka R, Stepp H, Kriegmaier M, Huber RM, Jacob K, Baumgartner R: Pharmacokinetics of 5-aminolevulinic acid induced protoporphyrin IX in skin and blood. *J Photochem Photobiol [B]* 1997;40:313–319.
- 24 Kriegmaier M, Wagner S, Stepp H, Hofstetter A: Fluoreszenzquantifizierung bei der 5-Aminolävulinsäure induzierten Fluoreszenzendoskopie des Harnblasenkarzinoms. *Urologe [A]* 1997;37:S50.
- 25 Knuechel R, Kutz H, Hofstaedter F, Hofstetter A, Kriegmaier M: Photodynamic diagnostics with 5-ALA in bladder cancer: Biology of false positive lesions. *Urol Res* 1997;25:94–95.