

# Management of Skin-Sparing Mastectomy: Results of a Survey of German Hospitals

Darius Dian<sup>a</sup> Gabriele Hemminger<sup>b</sup> Wolfgang Janni<sup>a</sup> Klaus Friese<sup>a</sup> Fritz Jänicke<sup>b</sup><sup>a</sup> University Hospital Munich,<sup>b</sup> University Hospital Hamburg-Eppendorf, Germany

## Key Words

Mastectomy, skin-sparing · Recurrence rate

## Summary

**Background:** The aim of this study was to evaluate the current management of skin-sparing mastectomy in German hospitals and to determine its oncologic safety. For this purpose, 100 surgeons were surveyed regarding their use of skin-sparing mastectomy. **Results:** Almost all surveyed hospitals performed skin-sparing mastectomy. Most of them believe that the recurrence rate is equal to that of conventional mastectomy. 95% regard inflammatory cancer as a contraindication to skin-sparing surgery. Most of the hospitals thin out the skin without leaving any macroscopic glandular tissue behind, and 73% leave the nipple-areola complex (NAC) on the basis of frozen sections. Volume replacement is most commonly done with latissimus dorsi muscle flaps and pedicled TRAM flaps. In 76% of the surveyed hospitals, reconstruction after mastectomy is performed by the gynecological department. **Conclusion:** Skin-sparing mastectomy is considered to be the best cosmetic option for breast reconstruction in selected breast cancer patients. At present, statistical proof of its oncologic safety is lacking. The surgical techniques used for skin-sparing mastectomy have not yet been standardized. In order to achieve standardization, careful discussion-making and evaluation remain important.

## Schlüsselwörter

Mastektomie, hautsparende · Rezidivrate

## Zusammenfassung

**Hintergrund:** Ziel dieser Arbeit war die Beurteilung des aktuellen Managements der hautsparenden Mastektomie an deutschen Krankenhäusern und die Hinterfragung der onkologischen Sicherheit der Methode. Dazu wurden 100 Chirurgen bezüglich Ihres Vorgehens bei hautsparender Mastektomie befragt. **Ergebnisse:** Fast alle Krankenhäuser führen hautsparende Mastektomien durch, die meisten in der Annahme, dass die Rezidivrate der der konventionellen Mastektomie entspricht. 95% der Krankenhäuser bewerten das inflammatorische Karzinom als eine Kontraindikation für die hautsparende Ablatio. Die meisten Befragten resezieren, bis makroskopisch kein Drüsengewebe mehr vorhanden ist, und 73% belassen den Mamillen-Areola-Komplex (MAK) auf der Grundlage von Schnellschnittuntersuchungen. Der Volumenersatz erfolgt meist mit einem Latissimus-dorsi-Myokutanflap oder einem gestielten TRAM-Flap. In 79% der befragten Krankenhäuser erfolgt die Rekonstruktion durch die gynäkologische Abteilung. **Schlussfolgerungen:** Die hautsparende Mastektomie wird als bestes kosmetisches Rekonstruktionsverfahren in ausgewählten Patientinnen mit Mammakarzinom angesehen. Der statistische Nachweis der onkologischen Sicherheit der Methode steht jedoch noch aus. Für die zukünftige Standardisierung der für die hautsparende Mastektomie verwendeten chirurgischen Techniken bedarf es der genauen Diskussion und Evaluation.

## Introduction

Breast cancer is the most frequent malignant disease in women in most parts of the world. Breast-conserving surgery has been shown to be an oncologically sound strategy for about 75% of patients, but more advanced stages of breast cancer still require mastectomy. In these cases, skin-sparing mastectomy, even with conservation of the nipple-areola complex (NAC), is increasingly used. Recently published studies support the use of the technique as an oncologically safe surgical procedure attaining superior cosmetic results. The aim of this study was to evaluate the management of skin-sparing mastectomy in Germany.

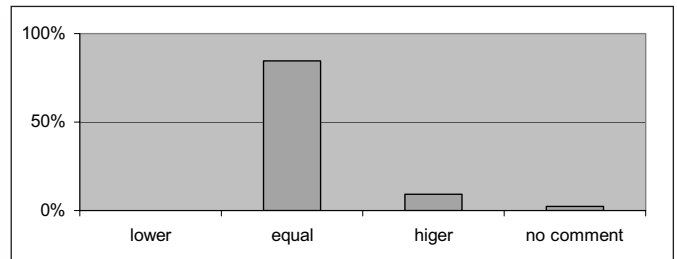
## Methods

We designed a questionnaire comprising 10 questions about skin-sparing mastectomy. This included questions concerning the quantity and modality of skin-sparing mastectomy carried out in each hospital and the estimated risk of recurrence compared to conventional mastectomy. The questionnaires were sent to 100 randomly selected hospitals all over Germany. 37 questionnaires were completed in full and sent back. 35 questionnaires were filled out in the course of an interview, 5 of them stemming from university hospitals.

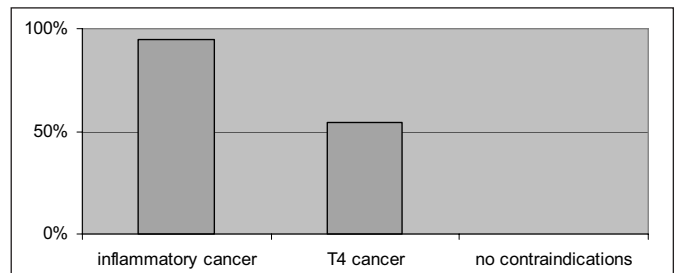
## Results

The first skin-sparing mastectomy was performed in 1980 in one of the surveyed hospitals. This is remarkable, since the method was first described in 1991 by Thoth and Lappert [1]. 3 clinics, including 2 university hospitals, share the highest frequency with 60 operations per year. Remarkably, the lowest frequency of 4 operations per year was also seen at a university unit. Most of the clinics (85%) consider the local recurrence rate of skin-sparing mastectomy to equal that of conventional mastectomy. Only 9% describe the risk of local recurrence as higher (fig. 1). 9 institutions base these statements on a review of their own data demonstrating a specified local recurrence rate between 0 and 8.3%. The median follow-up varied between 24 and 87 months, and the number of patients was a minimum of 24 and a maximum of 120. Most of the hospitals (97%) regard inflammatory cancer as a contraindication to skin-sparing mastectomy, and 58% of them extend this to T4 cancer in general. Sporadically mentioned contraindications include multicentricity (3 centers), planned radiation (2 centers), diffuse in situ components (2 centers) and central location of the tumor (2 centers) (fig. 2).

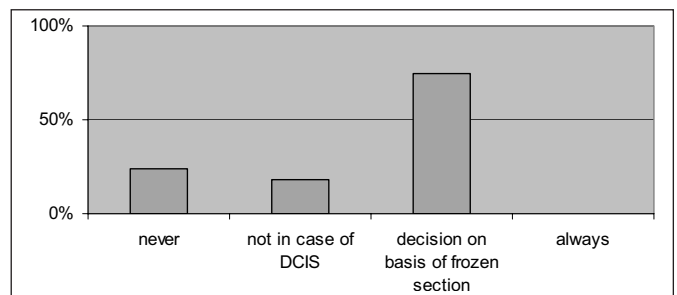
Among the surveyed German hospitals, skin areas which are being removed include at least the NAC in 59% and/or the skin covering the tumor in 52%. Nevertheless, in 60% of cases, a spindle incision around the NAC is also considered a therapeutic option. Another question concerned the thickness of the remaining skin in skin-sparing mastectomy. None of the centers entirely dissect the fatty tissue beyond the skin. 14



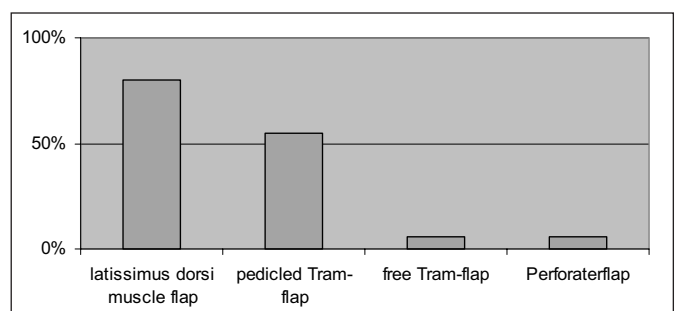
**Fig. 1.** Answers to the question: 'How do you consider the local recurrence rate of skin-sparing mastectomy compared to conventional mastectomy?'



**Fig. 2.** Answers to the question: 'What do you consider to be a contraindication for skin-sparing mastectomy?'



**Fig. 3.** Answers to the question: 'When do you preserve the nipple-areola complex?'



**Fig. 4.** Answers to the question: 'What do you use for volume replacement?'

centers stated measurement units. The average thickness was 8 mm with a range of 5–15 mm, but most of the hospitals dissect the skin according to the macroscopic appearance. Thus, 83% thin out the skin without leaving any macroscopic glandular tissue behind, while 13% require intraoperative exami-

**Table 15.** Publications concerning the local recurrence rate of skin-sparing mastectomy

Reference	Patients, n	Follow-up, months	LR, %	Conclusion
Newman et al. [6]	437	108	6.2	no significant increase
Hidalgo et al. [7]	28	27	0.0	no significant increase
Salvin et al. [8]	51	44.8	2.0	no significant increase
Kroll et al. [9]	114	>72	7.0	no significant increase
Toth et al. [10]	50	57	0.0	no significant increase
Simmons et al. [11]	77	15.6	3.9	no significant increase
Rivadeneira et al. [12]	71	49	5.6	no significant increase
Gerber et al. [13]	286	59	5.4	no significant increase
Peysen et al. [14]	71	24.1	3.0	no significant increase
Gheradini et al. [15]	31	20	0.0	no significant increase
Forster et al. [16]	67	49.2	4.0	no significant increase
Medina-Franco et al. [17]	173	73	4.5	no significant increase
Carlson et al. [18]	565	65.4	5.5	no systemic relapse

LR = Local recurrence rate.

nation of frozen sections of randomly chosen parts of the subcutis to help determine whether any microscopic breast parenchyma has been left behind.

Skin-sparing mastectomy can also be modified to preserve the NAC. 24% of the consulted hospitals never preserve the NAC, whereas none of the hospitals preserve it in all cases. Most of the clinics (75%) decide on the basis of frozen sections of the subareolar margins. 18% remove the NAC in the case of extensive ductal carcinoma in-situ (DCIS) (fig. 3). 16% of the clinics remove the NAC if the average distance to the primary tumor is less than 2.75 cm. The specified range varies between 1 and 3 cm. On the question of volume replacement, 80% of the surveyed hospitals use the latissimus dorsi muscle flap. In 72%, an additional skin area is dissected to gain more volume, whereas in 40% no skin was involved. If necessary, 70% use an implant in addition to the latissimus dorsi muscle flap. The second most commonly used muscle flap is the TRAM (transverse rectus abdominis muscle) flap, performed in 55% of hospitals. The free TRAM flap and perforator flaps are performed in only 6% of hospitals (fig. 4).

Neoadjuvant chemotherapy is common in a large number of centers, but only a few hospitals (18%) operate within the new borders of the tumor for tumor excision after chemotherapy. Most centers still try to excise within the old borders. In this case, 49% of the clinicians also use the skin-sparing mastectomy if necessary. Germany has a unique way of managing breast cancer. In 79% of the surveyed German hospitals, reconstruction after mastectomy is performed by the gynecological department, in 12% by the department of plastic surgery and in 6% in collaboration between both.

## Discussion

The loss of a breast is a traumatic event in a woman's life, and the beneficial effects of breast reconstruction on the psy-

chosocial and sexual well-being are proven [1–3]. The advantage of skin-sparing mastectomy with immediate reconstruction by autotransplantation is associated with superior cosmetic outcome. All other techniques produce more scarring. The preserved breast skin forms an envelope and enhances the esthetic results by providing nearly exact symmetry [4]. This is the reason why the technique of skin-sparing mastectomy is used by so many surgeons. Data have shown that the oncologic safety with regard to local recurrence is comparable to that of conventional mastectomy [5–17]. Table 1 shows an overview of publications concerning this subject. Nevertheless, statistical proof is still lacking. The local recurrence rate 10 years after conventional mastectomy is about 5% [18]. To prove statistically that a new technique has an 80%-disadvantage at the same level, 3,500 cases would have to be followed up. Interestingly, no publication presents follow-up of more than 565 cases. Thus, statistical evidence for oncologic reliability is still outstanding.

Another problem is that skin-sparing mastectomy is not standardized. Most surgeons (83%) excise the skin until no more glandular tissue is seen. It is evident that this does not lead to skin that is free from glandular tissue. Those centers (13%) performing intraoperative examination of frozen sections along with the mastectomy procedure to determine whether there is any glandular tissue left or not, can only make a statement about the small areas of remaining skin from which the biopsies were taken. Total glandular mastectomy and modified radical mastectomy (MRM) were compared by Barton et al. [19] with respect to the amount of breast tissue remaining after surgery. Multiple biopsies were taken from the anterior chest wall of women following total glandular mastectomy and MRM trying to detect any residual glandular tissue. Regardless of the procedure performed, breast tissue was histologically identified in 5% of all biopsy specimens. This implies that mastectomy provides a percentile reduction of the glandular tissue but never a complete removal. Excising the skin overly-

ing the tumor, which is done in 52% of the surveyed hospitals, is a way of reducing the risk of leaving behind glandular (especially malignant) tissue. A major concern involves the excision of the NAC which is removed in 59% of the clinics. However, several surgeons (60%) still remove skin around the NAC using a spindle incision to imitate an MRM. The NAC is one of the main characteristics of the female breast. Therefore, it is obvious that there is great interest in preserving it. Since all ducts end there, it is also obvious that leaving it behind means leaving ductal tissue behind. This is a problem particularly in cases of ductal and intraductal carcinomas. Our data show that 18% of the centers remove the NAC in cases of extensive DCIS. Most of the clinics (75%) base the decision to preserve the NAC on intraoperative frozen sections. The histological reliability of this method in the case of intraductal carcinomas is dubious. Another way of making the decision is to define the distance from the tumor. Nevertheless, this is also just a statistical way of reducing the chance of leaving malignant tissue behind.

For volume replacement, the latissimus dorsi flap is the most commonly used method (80%). This is due to the fact that it is one of the safest flaps with regard to flap loss. Since the muscle undergoes a certain degree of atrophy, most surgeons prefer to take additional skin (72%) rather than just the muscle (40%). The second most common flap is the TRAM flap which is used in 55%. Only 6% of the surveyed German clinics use the microsurgical option of free TRAM flap and perforator flaps. Whether this is due to the additional time or the microsurgical skills required, could not be answered by the questionnaire. But since 79% of reconstructive surgery after mastectomy are performed by the department of gynecology, the lack of microsurgical training seems to be the major problem.

## References

- Bukovic D, Fajdic J, Hrgovic Z, Kaufmann M, Hajsak I, Stanceric T: Sexual dysfunction in breast cancer survivors. *Onkologie* 2005;28:29–34.
- Deutsche Fatige Gesellschaft (DfaG): Only every second female patient with breast cancer will successfully complete occupational reintegration. *Onkologie* 2004;27:594–5.
- Heesen H, Kolecki S: Personal and psychosocial problems in mastectomy for breast cancer and the possibility of adjustment. *Onkologie* 1982;5(suppl): 56–62.
- Toth BA, Lappert P: Modified skin incisions for mastectomy: the need for plastic surgical input in preoperative planning. *Plast Reconstr Surg* 1991;87: 1048–53.
- Cocquyt VF, Blondeel PN, Depytere HT, Van De Sijpe KA: Better cosmetic results and comparable quality of life after skin-sparing mastectomy and immediate autologous breast reconstruction compared to breast conservative treatment. *Br J Plast Surg* 2003;56:462–70.
- Newman LA, Kuerer HM, Hunt KK: Presentation, treatment, and outcome of local recurrence after skin-sparing mastectomy and immediate breast reconstruction. *Ann Surg Oncol* 1998;5:620–6.
- Hidalgo DA, Borgen PJ, Petrek JA: Immediate reconstruction after complete skin-sparing mastectomy with autologous tissue. *J Am Coll Surg* 1998; 187:17–21.
- Slavin SA, Schnitt SJ, Duda RB: Skin-sparing mastectomy and immediate reconstruction: oncologic risks and aesthetic results in patients with early-stage breast cancer. *Plast Reconstr Surg* 1998;102: 49–62.
- Kroll SS, Khoo A, Singletary SE: Local recurrence risk after skin-sparing and conventional mastectomy: a 6-year follow-up. *Plast Reconstr Surg* 1999; 104:421–5.
- Toth BA, Forley BG, Calabria R: Retrospective study of the skin-sparing mastectomy in breast reconstruction. *Plast Reconstr Surg* 1999;104:77–84.
- Simmons RM, Fish SK, Gayle L: Local and distant recurrence rates in skin-sparing mastectomies compared with non-skin-sparing mastectomies. *Ann Surg Oncol* 1999;6:676–81.
- Rivadeneira DE, Simmons RM, Fish SK: Skin-sparing mastectomy with immediate breast reconstruction: a critical analysis of local recurrence. *Cancer J* 2000;6:331–5.
- Gerber B, Krause A, Reimer T, Muller H, Kuchenmeister I, Makovitzky J, Kundt G, Friese K: Skin-sparing mastectomy with conservation of the nipple-areola complex and autologous reconstruction is an oncologically safe procedure. *Ann Surg* 2003; 238:120–7.
- Peysers PM, Abel JA, Straker VF: Ultra-conservative skin-sparing 'keyhole' mastectomy and immediate breast and areola reconstruction. *Ann R Coll Surg Engl* 2000;82:227–35.
- Gherardini G, Thomas R, Basoccu G, Zaccheddu R: Immediate breast reconstruction with the transverse rectus abdominis musculocutaneous flap after skin-sparing mastectomy. *Int Surg* 2001;86:246–51.
- Foster RD, Esserman LJ, Anthony JP: Skin-sparing mastectomy and immediate breast reconstruction: a prospective cohort study for the treatment of advanced stages of breast carcinoma. *Ann Surg Oncol* 2002;9:462–6.
- Medina-Franco H, Vasconez LO, Fix RJ: Factors associated with local recurrence after skin-sparing mastectomy and immediate breast reconstruction for invasive breast cancer. *Ann Surg* 2002;235: 814–9.
- Carlson GW, Styblo TM, Lyles RH: The use of skin sparing mastectomy in the treatment of breast cancer: the Emory experience. *Surg Oncol* 2003;12: 265–9.
- Barton FE Jr, English JM, Kingsley WB: Glandular excision in total glandular mastectomy and modified radical mastectomy: a comparison. *Plast Reconstr Surg* 1991;88:389–92, discussion 393–4.

Neoadjuvant chemotherapy in breast cancer has been frequently discussed over the last years. Only 18% of the hospitals excise within the new borders of the tumor, although this was recommended by the German Breast Cancer Group (AGO) in the 2005 guidelines with an Oxford level of evidence 3b determined by individual case control studies. Most surgeons still try to excise within the old borders, but the question remains of how to find the old borders after chemotherapy. Therefore, 49% of the surveyed hospitals use skin-sparing mastectomy after neoadjuvant chemotherapy if necessary.

## Conclusion

Skin-sparing mastectomy is the best cosmetic option for immediate breast reconstruction. Statistical proof of its oncologic safety is still lacking. It has been shown that small amounts of glandular tissue are left behind by MRM. Logically, leaving behind more skin means leaving behind more glandular tissue. Keeping this in mind, it is important to examine the local recurrence rate. For this purpose, at least 3,500 cases of skin-sparing mastectomy will have to be monitored. Currently, the methods of skin-sparing mastectomy are not standardized. Hence, careful discussion and evaluation remain important to standardize the surgical techniques so that comparable results can be obtained. Questions that remain include: Which skin areas should be removed? How thick should the remaining skin be? Is it safe to thin out the skin to the point that no macroscopic glandular tissue is left or to consider the microscopic aspect by performing a frozen section? Is it oncologically safe to preserve the NAC? Overall multicenter studies are needed to answer these questions.