

Oral Vinorelbine and Cisplatin with Concomitant Radiotherapy in Stage III Non-Small Cell Lung Cancer (NSCLC): A Feasibility Study

Gabriele Beckmann^a Rainer Fietkau^b Rudolf M. Huber^c Philip Kleine^a Michael Schmidt^d
Sabine Semrau^b Delphine Aubert^e Alberto Fittipaldo^e Michael Flentje^a

^aKlinik und Poliklinik für Strahlentherapie Universität Würzburg,

^bKlinik und Poliklinik für Strahlentherapie Universität Rostock,

^cPneumologie, Klinikum der Ludwig-Maximilians-Universität München,

^dMedizinische Klinik, Abteilung Pulmologie Universität Würzburg, Germany

^eInstitut de Recherche Pierre Fabre, Castres, France

Key Words

Non-small cell lung cancer · Chemoradiotherapy · Vinorelbine, oral · Cisplatin · Consolidation chemotherapy

Summary

Background: Concurrent chemoradiotherapy has improved survival in inoperable stage III non-small cell lung cancer (NSCLC). This phase I trial was performed in order to establish a dose recommendation for oral vinorelbine in combination with cisplatin and simultaneous radiotherapy. **Patients and Methods:** Previously untreated patients with stage IIIB NSCLC received concurrent chemoradiotherapy with 66 Gy and 2 cycles of cisplatin and oral vinorelbine which was administered at 3 different levels (40, 50 and 60 mg/m²). This was to be followed by 2 cycles of cisplatin/vinorelbine oral consolidation chemotherapy. The study goal was to determine the maximal recommended dose of oral vinorelbine during concurrent treatment. **Results:** 11 stage IIIB patients were entered into the study. The median radiotherapy dose was 66 Gy. Grade 3–4 toxicity included neutropenia, esophagitis, gastritis and febrile neutropenia. The dose-limiting toxicity for concurrent chemoradiotherapy was esophagitis. 9 patients received consolidation chemotherapy, with neutropenia and anemia/thrombocytopenia grade 3 being the only toxicities. The overall response was 73%. **Conclusion:** Oral vinorelbine 50 mg/m² (days 1, 8, 15 over 4 weeks) in combination with cisplatin 20 mg/m² (days 1–4) is the recommended dose in combination with radiotherapy (66 Gy) and will be used for concurrent chemoradiotherapy in a forthcoming phase III trial testing the efficacy of consolidation chemotherapy in patients not progressing after chemoradiotherapy.

Schlüsselwörter

Nicht-kleinzelliges Bronchialkarzinom · Radiochemotherapie · Vinorelbin, oral · Cisplatin · Chemokonsolidierung

Zusammenfassung

Hintergrund: Die simultane Radiochemotherapie hat das Gesamtüberleben beim inoperablen nicht-kleinzelligen Bronchialkarzinom (NSCLC) Stadium IIIB verbessert. Die vorliegende Phase-I/II-Studie hatte das Ziel, die Dosis für orales Vinorelbin in Kombination mit Cisplatin und simultaner Radiotherapie festzulegen. **Patienten und Methoden:** Unbehandelte Patienten mit NSCLC Stadium IIIB erhielten eine simultane Radiochemotherapie mit 66 Gy und 2 Zyklen Cisplatin/Vinorelbin oral, welches in 3 Dosisstufen verabreicht wurde (40, 50 und 60 mg/m²). Im Anschluss daran waren 2 weitere Zyklen Chemotherapie zur Konsolidierung vorgesehen. Studienziel war die Festlegung der maximal tolerablen Dosis von oralem Vinorelbin in Kombinationschemotherapie simultan zur Bestrahlung. **Ergebnisse:** 11 Patienten (Stadium IIIB) wurden in die Studie eingeschlossen. Die mediane Radiotherapiedosis betrug 66 Gy. Als Grad-3/4-Nebenwirkungen traten Neutropenie, Ösophagitis, Gastritis und febrile Neutropenie auf. Dosislimitierend unter simultaner Radiochemotherapie war die Ösophagitis. 9 Patienten erhielten Chemokonsolidierung, wobei lediglich Grad-3/4-Hämatotoxizität auftrat. Die Gesamtansprechrate betrug 73%. **Schlussfolgerung:** Bei einer simultanen Radiochemotherapie mit 66 Gy ist Vinorelbin oral 50 mg/m² (Tag 1, 8, 15 für 4 Wochen) in Kombination mit Cisplatin 20 mg/m² (Tag 1–4) die empfohlene Dosierung. Dieses Schema findet Anwendung in einer Phase-III-Studie, die den Nutzen einer Konsolidierungsschemotherapie bei Patienten, die nach simultaner Radiochemotherapie nicht progredient sind, testen soll.

Introduction

Combined modality treatment including radiotherapy and chemotherapy has improved survival for patients with inoperable stage IIIA/B non-small cell lung cancer (NSCLC) in good physical condition [1–4]. Induction chemotherapy has been able to reduce distant metastasis in some trials [5] but had no influence on local control of the primary tumor. Chemotherapy given concurrently with radiotherapy has shown to prolong local control in-field [6, 7] as well as progression-free survival [8]. At present, simultaneous radiotherapy and full-dose chemotherapy is the most effective treatment which is, however, limited by increased acute toxicity [9–11].

The combination of cisplatin with 3 modern cytotoxic agents (gemcitabine, paclitaxel and vinorelbine) given as induction chemotherapy and followed by the same drugs concurrent with radiotherapy was tested in the study CALBG 9431. Cisplatin/vinorelbine was thought to show the most favorable efficacy/toxicity profile [12]. Vinorelbine is available in oral as well as intravenous form, with proven efficacy in NSCLC [13] and stable absorption from the digestive tract [14]. The administration of oral chemotherapy concurrent with radiotherapy is attractive in an outpatient setting, but the dose for oral vinorelbine in combination with cisplatin and concurrent chemoradiotherapy is not yet established. We conducted a phase I clinical trial to define the maximum tolerated dose for oral vinorelbine and establish a dose recommendation for a projected phase III trial.

Patients and Methods

Patients aged between 18 and 70 years with a good performance status (Karnofsky index $\geq 80\%$) and histologically or cytologically proven and previously untreated inoperable NSCLC stage IIIA/B (only N2) were eligible for enrolment in this study. All patients were requested to have at least 1 measurable lesion according to RECIST criteria, adequate pulmonary function, normal blood cell counts, no weight loss of $> 10\%$ during the last 3 months and a life expectancy of > 12 weeks. Required laboratory tests included total bilirubin (≤ 1.5), transaminases (≤ 2.5) and alkaline phosphatase (≤ 5 times the upper institutional limit) as well as normal creatinine and/or a creatinine clearance of ≥ 65 ml/min. Patients with superior vena cava syndrome, pre-existing pleural or pericardial effusion or ascites, severe comorbid illness, sensory neuropathy $> \text{grade I}$ and prior malignancy other than in situ cervical carcinoma or skin basal cell cancer were excluded. The protocol was performed in accordance with the Helsinki Declaration and approved by the Ethics Committee of each participating Center. All patients gave written informed consent. Pretreatment evaluation included medical history, complete physical and laboratory examination, electrocardiogram, bronchoscopy, pulmonary function, chest and abdominal computed tomography (CT) scan, brain CT or magnetic resonance imaging (MRI), bone scan and X-ray of hot spots. Hematology including differential was done before each administration of vinorelbine. Clinical examinations and serum chemistry were carried out before day 1 of each chemotherapy cycle.

Study Design

The trial was planned as a multicenter, open-label, non-randomized phase I/II study of full-dose chemotherapy with oral vinorelbine in combination

with cisplatin concurrent with radiotherapy, followed by consolidation chemotherapy with oral vinorelbine and cisplatin for inoperable, locally advanced non-metastasized NSCLC. The study flow chart is depicted in figure 1. Secondary objectives were to estimate the overall response rate and to evaluate the feasibility of an additional 2 cycles of consolidation chemotherapy with cisplatin and oral vinorelbine after concurrent chemoradiotherapy.

Simultaneous Chemoradiotherapy

2 cycles of oral vinorelbine and cisplatin were given together with radiotherapy. Oral vinorelbine was tested in 3 dose levels: 40 mg/m² in level 1, 50 mg/m² in level 2 and 60 mg/m² in level 3, administered on days 1, 8, 15 and 29, 36, 43. Cisplatin 20 mg/m² was given intravenously on days 1–4 and 29–32 after oral vinorelbine. Prophylactic antiemesis included a 5HT₃ antagonist. Radiotherapy was delivered 1–2 h after drug administration. Megavoltage radiotherapy started concomitantly with chemotherapy. CT-based treatment planning and 3D-conformal techniques were mandatory. The target volume was restricted to the primary tumor as seen in the lung window of the planning CT scan and macroscopically involved lymph node compartments (gross tumor volume, GTV). Lymph nodes were defined as involved if larger than 1.5 cm, in case of central hypodensity or if multiple nodes of > 1 cm were present in the same compartment. The planning target volume (PTV) encompassed the GTV with a lateral margin of 1 cm and a 1.5 cm margin in the cranio-caudal direction.

66 Gy specified according to ICRU 50 (International Commission on Radiation Units and Measurements) were given in 2 Gy single fractions 5 times a week. A radiotherapy dose increase of up to 10% was at the discretion of the treating radiotherapist. The PTV was reduced after 50 Gy to boost only macroscopic disease. Oral vinorelbine given concurrently with radiotherapy was escalated in 3 dose levels. At least 3 patients were treated at each dose level. The next dose level was not opened until all 3 patients entered at a specific dose level had finished simultaneous chemoradiotherapy without reaching dose-limiting toxicity. If 1 of the 3 patients experienced a dose-limiting toxicity, 3 more patients were entered at the same dose level. If a second patient experienced dose-limiting toxicity, dose escalation was stopped and the maximal recommended dose was defined as the preceding level. Toxicity was graded using National Cancer Institute (NCI) Common Toxicity Criteria, version 2.0. For pneumonitis, the Radiation Oncology Treatment Group (RTOG) scaling was used. Dose limiting toxicities were defined as grade 4 neutropenia, febrile neutropenia (Pizzo definition), grade 4 or symptomatic grade 3 thrombocytopenia, grade 3/4 esophagitis, grade 3/4 pneumonitis, neurotoxicity $> \text{grade 2}$, any organ toxicity $> \text{grade 2}$ (excluding nausea, vomiting and alopecia) and treatment interruption > 2 weeks.

Consolidation Chemotherapy

Patients without progressive disease confirmed by re-staging 4 weeks after simultaneous chemoradiotherapy received 2 3-week cycles of consolidation chemotherapy with oral vinorelbine 60 mg/m² days 1 and 8 and cisplatin 80 mg/m² day 1 for the first cycle. If no grade 3/4 neutropenia occurred during the first consolidation cycle, oral vinorelbine 80 mg/m² days 1 and 8 was given during the second cycle with the same dose of cisplatin. Response was assessed according to RECIST criteria, 4–6 weeks after the end of chemoradiotherapy and 4 weeks after end of consolidation chemotherapy by chest and abdominal CT scans. A final evaluation of toxicity was performed within 30 days of the last administration of chemotherapy.

Results

From July 2003 to June 2004, 11 patients, 7 male and 4 female, were entered into the study. 3 patients were treated in both

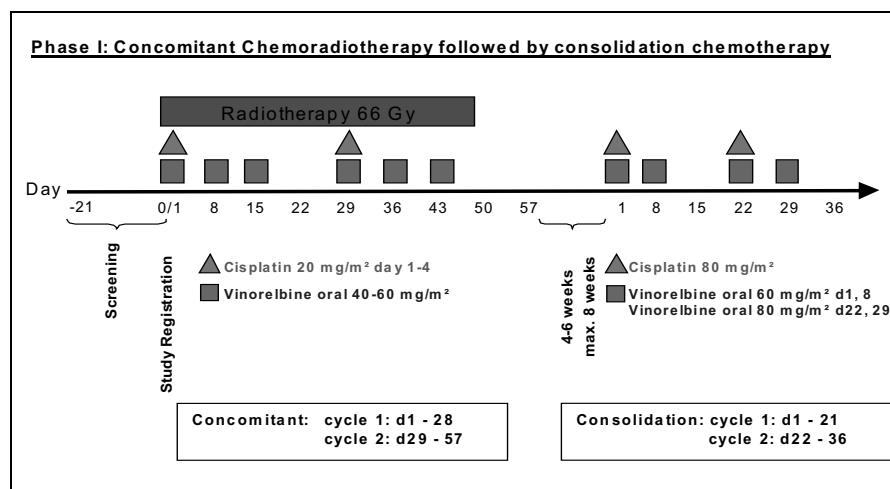


Fig. 1. Study flow chart.

level 1 and 2, and 5 patients were treated in level 3 at which dose limiting toxicity was evidenced in 4 patients. As a result, the study recruitment was closed. The mean patient age was 57 years (43–70), and the mean Karnofsky index was 90% (80–100%). All patients were NSCLC stage IIIB at inclusion. Histological subtypes included adenocarcinoma in 6 patients and squamous cell carcinoma in 5 patients. PET staging was not mandatory but was performed in 8 patients. All patients were included in the intent-to-treat analysis and analyzed for safety and toxicity.

In our protocol, esophagitis was the dose-limiting toxicity which occurred at level 3. Therefore the recommended dose has been defined as 50 mg/m² of oral vinorelbine in combination with cisplatin given concurrently with radiotherapy. 3 of 5 patients in the third dose level developed esophagitis grade 3 already during the first cycle of simultaneous chemotherapy, resulting in the entire treatment being discontinued in 1 patient and chemotherapy being stopped in another patient who was able to finish radiotherapy but required parenteral nutrition beyond the end of radiotherapy. The third patient received the second cycle of concomitant chemotherapy and again developed esophagitis grade 3 as a result, which was the same in another patient who had esophagitis grade 1 previously. One of these patients suffered from prolonged esophagitis during consolidation chemotherapy (grade 2 during the first cycle, grade 1 during the second cycle). Dysphagia was mild in dose level 1 and 2, and patients were able to eat a regular diet until the end of concomitant chemoradiotherapy. Weight loss occurred only in level 3 (2 cases, grade 1), and 1 patient at level 3 developed gastritis grade 3. Nausea and vomiting were associated predominantly with cisplatin in both level 1 and 2, given on days 1–4 of each cycle. In level 3, nausea/vomiting appeared also after oral vinorelbine. Constipation was a rare event and was managed by consumption of fiber. Nephrotoxicity grade 2 caused by application of cisplatin occurred in 1 patient during simultaneous chemoradiotherapy and persisted during consolidation chemotherapy.

3 patients experienced a non-recurring event of sudden thoracic pain without obvious correlation to drug administration, which dissolved spontaneously after a number of hours. Myocardial ischemia was ruled out. Neutropenia grade 3 was seen in 1 of 3 patients in dose level 2, only during cycle 1. In level 3, 3 out of 5 patients had neutropenia grade 3/4. No grade 3/4 anemia or thrombocytopenia occurred (table 1). One patient presented with 2 episodes of febrile neutropenia (concurrent treatment cycle 2 and during consolidation chemotherapy cycle 4).

Toxicity during consolidation chemotherapy was assessed in 9 patients receiving consolidation chemotherapy. Tolerance was influenced by the dose level of previous concurrent chemoradiotherapy. Patients treated at level 1 passed through consolidation chemotherapy without major events. Dose escalation of oral vinorelbine from 60 to 80 mg/m² was possible in all patients, except for 1 patient treated in level 1 who developed neutropenia grade 3. Hematological toxicity was more pronounced in levels 2 and 3. Following level 2, all 3 patients had neutropenia grade 3/4, with anemia and thrombocytopenia grade 3 showing in 1 patient. Following level 3, 1 of 3 patients receiving consolidation had neutropenia grade 4. Non-hematological toxicity consisted mainly of nausea grade 1/2 in all patients. Pneumonitis grade 2 developed in 1 patient (dose level 2) 3 months after the end of radiotherapy. CT scans during follow-up showed fibrotic changes in 2 other patients (level 1 and 3, respectively) who required no treatment.

Treatment Delivery

All patients entered in level 1 and 2 completed radiotherapy and the 4 scheduled cycles of chemotherapy, with a once of omission of day-15 oral vinorelbine according to protocol during concomitant treatment due to neutropenia grade 3. In level 3, chemotherapy was stopped after cycle 1 in 2 patients because of esophagitis grade 3. Both patients were continued

Table 1: Toxicity (per cycle)

Toxicity	Level 1: 40 mg/m ² ; patients, n				Level 2: 50 mg/m ² ; patients, n				Level 3: 60 mg/m ² ; patients, n			
	Concurrent CR		Consolidation C		Concurrent CR		Consolidation C		Concurrent CR		Consolidation C	
	Grade 1/2	Grade 3/4	Grade 1/2	Grade 3/4	Grade 1/2	Grade 3/4	Grade 1/2	Grade 3/4	Grade 1/2	Grade 3/4	Grade 1/2	Grade 3/4
Nausea	2/6	–	1/6	–	5/6	–	6/6	–	7/8	–	6/6	–
Vomiting	2/6	–	1/6	–	4/6	–	3/6	–	5/8	–	3/6	–
Gastritis	–	–	–	–	–	–	–	–	–	1/8	–	–
Constipation	1/6	–	–	–	2/6	–	3/6	–	2/8	–	1/6	–
Nephrotoxicity	–	–	–	–	–	–	–	–	1/8a	–	–	–
Fatigue	3/6	–	2/6	–	2/6	–	2/6	–	3/8	–	2/6	–
Weight loss	–	–	–	–	–	–	–	–	2/8	–	–	–
Esophagitis	6/6	–	–	–	6/6	–	–	–	3/8	5/8	2/6	–
Anemia ^b	–	–	–	1/6	–	–	–	2/6	–	–	–	–
Leucopenia ^b	–	–	–	–	–	1/6	–	3/6	–	3/8	–	1/6
Thrombopenia ^b	–	–	–	–	–	–	–	1/6	–	–	–	–

CR = Chemoradiotherapy, C = chemotherapy.

^aUnlikely related to vinorelbine oral.

^bOnly grade 3 and 4 given (see text).

on radiotherapy. Therefore, all patients received ≥ 66 Gy (mean dose 66.3 Gy). Oral vinorelbine on day 8 was omitted once during consolidation after concurrent chemoradiotherapy at level 3 because of increased acute-phase proteins and suspected infection.

Response evaluation was possible in 9 patients after concurrent chemoradiotherapy (2 patients in level 3 were taken off the study due to toxicity) and in 8 patients after both concurrent chemoradiotherapy and consolidation chemotherapy. After concurrent chemoradiotherapy, partial remission was achieved in 8 patients, and 1 patient had stable disease. After consolidation chemotherapy, 4 patients were in complete remission of both the primary tumor and mediastinal lymph node metastases, and 4 patients had a partial remission. The patients in the recommended dose level responded with 1 complete and 2 partial remissions. After a median follow-up of 13.4 months (4.6–19.2), 5 patients were still alive, 2 of them in stable partial and complete remission, respectively. 6 patients died, 1 because of bacterial pneumonia and 5 because of progression. 5 patients with local control in-field developed distant metastases, 3 of them in the brain and 2 of them in the lung. Only 1 patient had in-field progression.

Discussion

In locally advanced inoperable NSCLC the combination of radiotherapy with chemotherapy seems a logical step to enhance efficacy of local treatment and treat occult distant metastasis. The optimal way to deliver chemotherapy is concurrent with radiotherapy as seen in several randomized controlled trials

[9–11, 15]. The combination of cisplatin and vinorelbine showed a favorable toxicity profile when given together with radiotherapy and after 2 cycles of induction chemotherapy with the same drugs [12]. Primary chemoradiotherapy with vinorelbine and a platinum compound was feasible and well tolerated with good results in high-risk patients [16].

The dose of intravenous vinorelbine in advanced NSCLC commonly used as monotherapy or in combination with cis- or carboplatin is 25–30 mg/m² per week or administered on days 1 and 8 per 3–4-week cycle [17]. In combination with concurrent radiotherapy, lower doses are given beginning at 12.5 mg/m² in different schedules or even 4 mg/m² daily if used as radiosensitizer [18]. Oral vinorelbine is effective in NSCLC but exerts slightly higher gastrointestinal toxicity. Crossover studies assessing the bioavailability of oral and intravenous vinorelbine [19] showed that an oral dose of 80 mg/m² resulted in similar exposure as the intravenous dose of 30 mg/m² and that the oral dose of 60 mg/m² is comparable to the intravenous dose of 25 mg/m² which is the dose commonly used in combination regimens [20]. Therefore, we decided to define the highest level in this phase I trial as a dose of oral vinorelbine of 60 mg/m² and to initiate the trial with a lower dose of 40 mg/m² corresponding to approximately to 15 mg/m² of intravenous vinorelbine and escalate the dose over a total of 3 levels.

While neutropenia turned out to be the dose-limiting toxicity for vinorelbine in most dose-finding studies with chemotherapy alone, esophagitis is the common toxicity with concurrent chemoradiotherapy. In our trial, reduced radiotherapy target volumes supported by additional information from pretreatment PET scans were used and involved areas were covered

with only moderate safety margins. Nevertheless, esophagitis was the dose-limiting toxicity. 3 patients entered on level 3 had esophagitis grade 3 early during cycle 1 and 1 patient during cycle 2, compared to none of the 6 patients included in levels 1 and 2. Esophagitis grade 3 was reversible in all cases, but intensive supportive therapy was required. So far, no late toxicity, such as esophageal strictures, were seen in the patients still alive. In CALBG 9431, esophagitis grade 3/4 was 25% with vinorelbine/cisplatin, but 39% with paclitaxel/cisplatin and 52% with gemcitabine/cisplatin. In this trial, vinorelbine was given intravenously at 15 mg/m² on days 1 and 8 together with cisplatin 80 mg/m² on day 1 in a 3-week cycle during concomitant chemoradiotherapy [12], corresponding to 40 mg/m² of oral vinorelbine. Gastrointestinal toxicity was mild and did not interfere with intake of the oral drug. Nevertheless, prophylactic antiemesis with a 5HT₃ antagonist is recommended and was strictly administered in this trial. Hematotoxicity was not a major problem during concurrent chemoradiotherapy. Anemia and thrombocytopenia were rare and only reached grade 1/2. There were 2 episodes of febrile neutropenia both in the same level 3 patient.

Consolidation chemotherapy with a 4-week break after concurrent chemoradiotherapy was feasible in all patients at level 1 and 2. At level 3, only 3 out of 5 patients received consolidation chemotherapy therapy. 2 patients did not receive consolidation, as chemotherapy had been stopped earlier due to long-lasting esophagitis grade 3, and were taken off protocol. There

were 3 cases of postradiation pneumonitis with 1 patient requiring active treatment with high-dose steroids. This does not differ from conventional radiotherapy to this dose level.

The overall response to therapy was good with 8 patients reaching partial response at the end of concurrent treatment. At the end of consolidation, 4 patients were in complete response and 4 in partial response. Local progression was seen only in 1 patient during follow-up. As expected in locally advanced NSCLC, a high proportion of patients developed systemic progression. 3 patients developed metastasis to the brain. All patients had local control of the primary tumor. This observation is in line with the results of other trials [5, 9, 21, 22] and raises the question of prophylactic cranial irradiation in a subgroup of patients with NSCLC and documented complete or near complete response [23].

Conclusion

According to the results of this phase I trial, vinorelbine oral 60 mg/m² given on days 1, 8, 15 concurrently with cisplatin and conformal radiotherapy is the maximum tolerated dose, with esophagitis being the dose-limiting toxicity. Therefore, vinorelbine oral 50 mg/m² is the recommended dose for our planned phase III trial which is designed to evaluate the role of consolidation chemotherapy after concomitant chemoradiotherapy using 2 cycles of chemotherapy given at full dose.

References

- No authors listed: Chemotherapy in non-small cell lung cancer: a meta-analysis using updated data on individual patients from 52 randomised clinical trials. Non-small Cell Lung Cancer Collaborative Group. *BMJ* 1995;311:899–909.
- Marino P, Preatoni A, Cantoni A: Randomized trials of radiotherapy alone versus combined chemotherapy and radiotherapy in stages IIIa and IIIb non small cell lung cancer. A meta-analysis. *Cancer* 1995;76:593–601.
- Pignon JP, Stewart LA: Randomized trials of radiotherapy alone versus combined chemotherapy and radiotherapy in stages IIIa and IIIb non small cell lung cancer: a meta-analysis. *Cancer* 1996;77:2413–2414.
- Pritchard RS, Anthony SP: Chemotherapy plus radiotherapy compared with radiotherapy alone in the treatment of locally advanced, unresectable, non-small-cell lung cancer. A meta-analysis. *Ann Intern Med* 1996;125:723–729.
- Komaki R, Scott CB, Sause WT, Johnson DH, Taylor SG 4th, Lee JS, Emami B, Byhardt RW, Curran WJ Jr, Dar AR, Cox JD: Induction cisplatin/vinorelbine and irradiation vs. irradiation in unresectable squamous cell lung cancer: failure patterns by cell type in RTOG 88-08/ECOG 4588. Radiation Therapy Oncology Group. Eastern Cooperative Oncology Group. *Int J Radiat Oncol Biol Phys* 1997;39:537–544.
- Clamon G, Herndon J, Cooper R, Chang AY, Rosenman J, Green MR: Radiosensitization with carboplatin for patients with unresectable stage III non-small-cell lung cancer: a phase III trial of the Cancer and Leukemia Group B and the Eastern Cooperative Oncology Group. *J Clin Oncol* 1999;17:4–11.
- Komaki R, Seiferheld W, Ettinger D, Lee JS, Movsas B, Sause W: Randomized phase II chemotherapy and radiotherapy trial for patients with locally advanced inoperable non-small-cell lung cancer: long-term follow-up of RTOG 92-04. *Int J Radiat Oncol Biol Phys* 2002;53:548–557.
- Huber RM, Flentje M, Gosse H, Poellinger B, Schmidt M, Willner J, Ulm K: Induction chemotherapy and following simultaneous radiochemotherapy versus induction chemotherapy and radiotherapy alone in inoperable NSCLC (Stage IIIA/IIIB): Update of CT/RT 99/97. *Proc Am Soc Clin Oncol* 2004;22(abstr 7075):14S.
- Furuse K, Fukuoka M, Kawahara M, Nishikawa H, Takada Y, Kudoh S, Katagami N, Ariyoshi Y: Phase III study of concurrent versus sequential thoracic radiotherapy in combination with mitomycin, vindesine, and cisplatin in unresectable stage III non-small-cell lung cancer. *J Clin Oncol* 1999;17:2692–2699.
- Fournel P, Perol M, Robinet G, Thomas P, Souquet PJ, Hervé L, Vergnenegre A, Delhoume JY, Michel-MontPeyroux F, Mornex F: A randomized phase III trial of sequential chemo-radiotherapy versus concurrent chemo-radiotherapy in locally advanced non small cell lung cancer (NSCLC) (GLOT-GFPC NPC 95-01 study). *Proc Am Soc Clin Oncol* 2001;20:abstr 1246.
- Curran WJ, Scott CB, Langer CJ, Komaki R, Lee SJ, Hauser S, Movsas B, Wassermann T, Sause W, Cox JD: Long-term benefit is observed in a phase III comparison of sequential vs concurrent chemoradiation for patients with unresected stage III nscl: RTOG 9410. *Proc Am Soc Clin Oncol* 2003;22:abstr 2499.
- Vokes EE, Herndon JE 2nd, Crawford J, Leopold KA, Perry MC, Miller AA, Green MR: Randomized phase II study of cisplatin with gemcitabine or paclitaxel or vinorelbine as induction chemotherapy followed by concomitant chemoradiotherapy for stage IIIB non-small-cell lung cancer: cancer and leukemia group B study 9431. *J Clin Oncol* 2002;20:4191–4198.
- Jassem J, Ramlau R, Karnicka-Mlodkowska H, Krawczyk K, Krzakowski M, Zatloukal P, Lemarie E, Hartmann W, Novakova L, O'Brien M, Depierr A: A multicenter randomized phase II study of oral vs intravenous vinorelbine in advanced non-small cell lung cancer patients. *Ann Oncol* 2001;12:1375–1381.

- 14 Bugat R, Variol P, Roche H, Fumoleau P, Robinet G, Senac I: The effects of food on the pharmacokinetic profile of oral vinorelbine. *Cancer Chemother Pharmacol* 2002;50:285–290.
- 15 Sause W, Kolesar P, Taylor S IV, Johnson D, Livingston R, Komaki R, Emami B, Curran W Jr, Byhardt R, Dar AR, Turrisi A 3rd: Final results of phase III trial in regionally advanced unresectable non-small cell lung cancer: Radiation Therapy Oncology Group, Eastern Cooperative Oncology Group, and Southwest Oncology Group. *Chest* 2000;117:358–364.
- 16 Semrau S, Bier A, Thierbach U, Virchow C, Ketterer P, Fietkau R: Concurrent radiochemotherapy with vinorelbine plus cisplatin or carboplatin in patients with locally advanced non-small-cell lung cancer (NSCLC) and an increased risk of treatment complications. Preliminary results. *Strahlenther Onkol* 2003;179:823–831.
- 17 Gralla R, Harper P, Johnson S, Delgado FM: Vinorelbine (Navelbine®) in the treatment of non-small cell lung cancer: studies with single-agent therapy and in combination with cisplatin. *Ann Oncol* 1999;10(suppl 5):S41–S45.
- 18 Gridelli C, Guida C, Barletta E, Gatani T, Fiore F, Barzelloni ML, Rossi A, de Bellis M, D'Aniello R, Scognamiglio F: Thoracic radiotherapy and daily vinorelbine as radiosensitizer in locally advanced non small cell lung cancer: a phase I study. *Lung Cancer* 2000;29:131–137.
- 19 Marty M, Fumoleau P, Adenis A, Rousseau Y, Merrouche Y, Robinet G, Senac I, Puozzo C: Oral vinorelbine pharmacokinetics and absolute bioavailability study in patients with solid tumors. *Ann Oncol* 2001;12:1643–1649.
- 20 Nguyen L, Tranchand B, Puozzo C, Variol P: Population pharmacokinetics model and limited sampling strategy for intravenous Vinorelbine derived from phase I clinical trials. *Br J Clin Pharmacol* 2002;459–468.
- 21 Gaspar LE, Chansky K, Albain KS, Vallieres E, Rusch V, Crowley JJ, Livingston RB, Gandara DR: Time from treatment to subsequent diagnosis of brain metastases in stage III non-small-cell lung cancer: a retrospective review by the Southwest Oncology Group. *J Clin Oncol* 2005;23:2955–2961.
- 22 Mamon HJ, Yeap BY, Janne PA, Reblando J, Shrager S, Jaklitsch MT, Mentzer S, Lukanich JM, Sugarbaker DJ, Baldini EH, Berman S, Skarin A, Bueno R: High risk of brain metastases in surgically staged IIIA non-small-cell lung cancer patients treated with surgery, chemotherapy, and radiation. *J Clin Oncol* 2005;23:1530–1537.
- 23 Lester JF, Macbeth FR, Coles B: Prophylactic cranial irradiation for preventing brain metastases in patients undergoing radical treatment for non-small-cell lung cancer: A cochrane review. *Int J Radiat Oncol Biol Phys* 2005;63:690–694.