

Electrophysiological stimulation of excised rat muscle elicits a measurable change in tissue sodium concentration using ^{23}Na -MRI

Frank Riemer¹, Joshua Kaggie¹, Cormac O'Neill², Mary McLean³, James Grist¹, Myfanwy Hill³, Joe Guy³, Rolf Schulte⁴, Martin Graves^{1,2}, James Fraser⁵, and Ferdia Gallagher¹

¹Department of Radiology, University of Cambridge, Cambridge, United Kingdom, ²Cambridge University Hospitals NHS Foundation Trust, Cambridge, United Kingdom, ³Cancer Research UK Cambridge Institute, University of Cambridge, Cambridge, United Kingdom, ⁴GE Healthcare, Munich, Germany, ⁵Department of Physiology, Development and Neuroscience, University of Cambridge, Cambridge, United Kingdom

Synopsis

Changes in the tissue sodium gradient play an important role in cell signalling such as at the neuromuscular junction and as part of neuronal action potentials. ^{23}Na -MRI has the ability to measure the macroscopic sodium distribution. In this study we investigated the changes in tissue sodium in an electrically stimulated and freshly excised rat leg muscle.

Introduction

Changes in the tissue sodium gradient play an important role in cell signalling such as at the neuromuscular junction and as part of neuronal action potentials. ^{23}Na -MRI has the ability to measure the macroscopic sodium distribution. In this study we investigated the changes in tissue sodium in an electrically stimulated and freshly excised rat leg muscle.

Methods

The rat (Lister, age: 14 weeks) was sacrificed according to local ethical rules. Rat hind leg muscles were obtained within 1 hour of imaging. Muscles were placed in a container filled to 1 mm depth with buffer solution¹ (fig.1). The container was placed on top of a custom ^{23}Na T/R coil of 15 cm diameter in a clinical 3T MRI (GE MR750, GE Healthcare, Waukesha, WI). A 3D-Cones sequence² was used for ^{23}Na -imaging (resolution = $3.8 \times 3.8 \times 3.8 \text{ mm}^3$, FOV = 20 cm, TE/TR = 0.5/50 ms, flip angle = 90° , readout length = 30 ms, 197 readouts, duration of one scan = 10 seconds). A waveform generator was placed outside of the room, and the cable connected to an MRI pass panel to stimulate the muscle with prongs attached to the muscle for field excitation (20 ms pulses, 1 second between pulses). A trap circuit at 33 MHz ($>30 \text{ dB}$ attenuation) was placed on the cables to remove noise at the imaging frequency for sodium. Images were corrected for B_1 sensitivity using the double angle method (FA = 30° and 60°)³. 20 and 85 mM NaCl in 4% agar phantoms were placed in the FOV for quantification⁴. Imaging was performed in 1 minute blocks (6 volumes per block), 4 blocks in total (2 blocks of stimulation interleaved with 2 rest blocks). SPM12 (UCL, London, UK) was used to find voxels undergoing significant sodium signal changes in the FOV. No

response modelling function (such as hemodynamic response) was used due to the instantaneous nature of the sodium flux and low temporal resolution (10 s).

Results

Figure 2 shows a ^1H image of the set up. The short ^{23}Na -MRI scan (10 s per volume) yielded sufficient SNR (≈ 22 a.u. ; fig. 3). The average total sodium concentration in the muscle tissue at the beginning and end of the experiment was 37 mM. A change in sodium concentration between +1 to + 4 mM was detected during stimulation ($p < 0.001$, FWE corrected), fig.4. Muscle tetany during stimulation was confirmed visually. No signal changes were detected in the control muscle which was not stimulated.

Discussion

The results demonstrate for the first time that rapid sodium signal changes can be detected within excited skeletal muscle using ^{23}Na -MRI. In this experiment an alteration in tissue sodium was detected which corresponds to the sodium flux during activation of the neuromuscular junction. As the muscle was imaged *ex vivo*, contribution of blood flow (also a carrier of sodium ions) should not have an effect.

Conclusion

Here we have demonstrated that non-invasive ^{23}Na -MRI has the sensitivity and temporal resolution to be used to study functional changes in sodium concentration in muscle tissue during stimulation. This method could be applied in the future to investigate neuromuscular diseases where alterations in sodium transport are known to occur e.g. myopathies. This observation in muscle provides further evidence that ^{23}Na -MRI can be used as a functional measure of action potential activity within the central nervous system, which would complement traditional proton functional MRI measurements within the brain⁵.

Acknowledgements

This work was supported by CRUK [C8742/A18097]. This is a contribution from the Cancer Imaging Centre in Cambridge & Manchester, which is funded by the EPSRC and Cancer Research UK. We would like to express our gratitude to the Experimental Cancer Medicine Centres (ECMC) for continued support. JK receives funding support from GlaxoSmithKline.

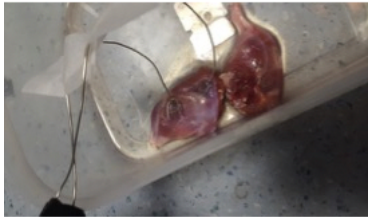References

1. Pedersen TH, de Paoli F, Nielsen OB. Increased Excitability of Acidified Skeletal Muscle: Role of Chloride Conductance. *Journ. Gen. Phys.* 2005; 125(2):237–46.
2. Gurney PT, Hargreaves BA, Nishimura DG. Design and analysis of a Practical 3D Cones Trajectory. *MRM* 2006; 55:575-582.
3. Sled JG, Pike GB. Correction for B(1) and B(0) variations in quantitative T(2) measurements using MRI. *MRM* 2000; 43:589-593.

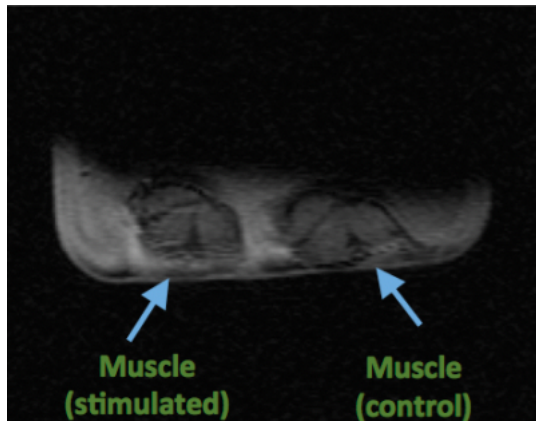
4. Christensen JD, Barrere BJ, Boada FE, Vevea JM, Thulborn KR. Quantitative Tissue Sodium Concentration Mapping of Normal Rat Brain. MRM 1996; 36:83-89.

5. Riemer F, Solanky BS, Golay X, D'Angelo EU, Wheeler-Kingshott CAM. Sodium fMRI detects grey and white matter activations: neuronal firing or blood volume change? In Proc. Int. Soc. Magn. Reson. Med. 2015, 23:3924.

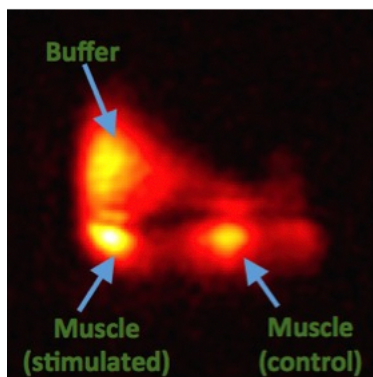
Figures



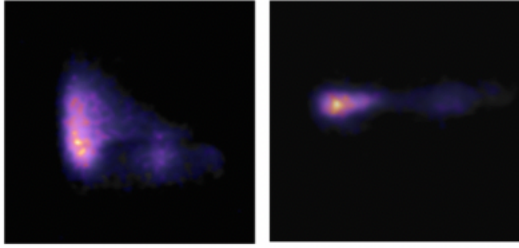
1) Photograph of the experimental set up. Rat lower limb muscle with field stimulation electrodes (left), control muscle without stimulation electrodes (right).



2) Coronal ^1H images of the muscle experiment set up.



3) One time-point coronal ^{23}Na image of the muscle experiment set up.



- 4) One time-point ^{23}Na image (purple) of the muscle experiment set up with superimposed activation clusters (yellow/orange, $p < 0.001$, corrected). Left shows the coronal image as before, right is an axial MIP.