

RES MEDICA

Journal of the Royal Medical Society



Sex Chromosome Abnormalities in the Male

Patricia A. Jacobs

Abstract

This article does not set out to give a comprehensive review of sex chromosome abnormalities in Man, nor even in phenotypic males. Its purpose is more to outline a few general principles and show how they apply to one group of individuals with one class of abnormality, namely males with abnormalities of number of either the X chromosome, or the Y chromosome or of both.

Copyright Royal Medical Society. All rights reserved. The copyright is retained by the author and the Royal Medical Society, except where explicitly otherwise stated. Scans have been produced by the Digital Imaging Unit at Edinburgh University Library. Res Medica is supported by the University of Edinburgh's Journal Hosting Service: <http://journals.ed.ac.uk>

ISSN: 2051-7580 (Online) ISSN: 0482-3206 (Print)

Res Medica is published by the Royal Medical Society, 5/5 Bristo Square, Edinburgh, EH8 9AL

Res Medica, Spring 1966, 5(2): 18-23

doi: [10.2218/resmedica.v5i2.459](https://doi.org/10.2218/resmedica.v5i2.459)

SEX CHROMOSOME ABNORMALITIES IN THE MALE

PATRICIA A. JACOBS

*Medical Research Council, Clinical Effects of Radiation
Research Unit, Western General Hospital.*

This article does not set out to give a comprehensive review of sex chromosome abnormalities in Man, nor even in phenotypic males. Its purpose is more to outline a few general principles and show how they apply to one group of individuals with one class of abnormality, namely males with abnormalities of number of either the X chromosome, or the Y chromosome or of both.

Man has 46 chromosomes consisting of 22 pairs of autosomes, which are common to both sexes, and two sex chromosomes an X and a Y. Normal females have two X chromosomes which are morphologically indistinguishable from one another, while males have one X chromosome and one Y chromosome, which are morphologically dissimilar. (Fig. 1, Fig. 2). The main two criteria used in recognition of chromosomes are their length and the position of the centromere or primary constriction. On the basis of these criteria only 4 pairs of auto-

somes can be recognised with certainty, whilst the others can only be recognised as belonging to one of a number of groups. Some of these groups contain only two pairs of chromosomes, whilst the largest group, consisting of medium sized submetacentric chromosomes, contains as many as seven pairs of autosomes. Unfortunately the X chromosome falls into this category of medium sized submetacentric chromosomes and, therefore, cannot be distinguished morphologically from autosome pairs 6-12. Normal males, therefore, have 15 chromosomes in this group — 14 autosomes and a single X chromosome, while normal females have 16 — 14 autosomes and two X chromosomes.

The Y chromosome, however, is one of the smallest chromosomes in the human complement with its centromere very near one end (acrocentric). It can usually be distinguished from the autosomes that it most closely resembles, those of pairs 21 and 22, by virtue of

the fact that it never has small satellites on its short arms, and also because the constituent chromatids of the Y chromosome tend to be close to one another and are often rather fuzzy in appearance. Little difficulty, therefore, arises when dealing with abnormalities of number of the Y chromosomes as these can be easily recognised. The X chromosome cannot, however, be distinguished morphologically from the autosome pairs 6-12. It is therefore necessary, when deciding whether or not one is dealing with an abnormal number of X chromosomes to consider, as well as the cytogenetic findings, the evidence from three other sources, namely the nuclear sex, the clinical findings and the results of autoradiography undertaken to determine the time at which the chromosomes synthesise DNA.

Nuclear Sex

In a proportion of nuclei of non-dividing cells of normal females there is a small body about 1μ in diameter attached to the nuclear membrane. Such a body is never found in similar nuclei from normal males (Fig. 3). This body was first described by Barr and Bertram in 1949¹ and is, therefore, referred to as the Barr body or sex chromatin body. Individuals having this body are said to be Barr positive or chromatin positive, whilst those in whom it is absent are said to be Barr negative or chromatin negative. There has been much speculation since the first observation of sex chromatin as to its nature, but it is now known that it represents an X chromosome which is in a different state of condensation from the other chromosomes of the cell. While the latter are uncoiled and genetically active, the sex chromatin body consists of the whole, or the greater part, of an X chromosome which is condensed and presumably relatively inactive. It appears that for normal function the cell needs only one X chromosome, and any further X chromosome present is, to a greater or lesser extent, inactive, and represented by a sex chromatin body. Thus the maximum number of sex chromatin bodies is one less than the number of X chromosomes in the cell. Sex chromatin can be seen in the cells of a great many tissues in the body, but it is often studied in cells from the buccal mucosa, because these are very easily obtained. Such studies enable large populations to be screened for their X chromosome status by means of a simple and quick technique. The sex chro-

matin status of the individual gives valuable information as to the number and, in favourable circumstances, the size of the X chromosome, as abnormalities of size of the X chromosome are reflected in abnormalities of size of the sex chromatin body. It must be emphasised, however, that it gives no information about the Y chromosome. Thus individuals who are lacking a sex chromosome, XO females, and also normal XY males are both chromatin negative, while both XXX females and males with Klinefelter's syndrome and an XXXY sex chromosome complement have two sex chromatin bodies in a proportion of their cells.

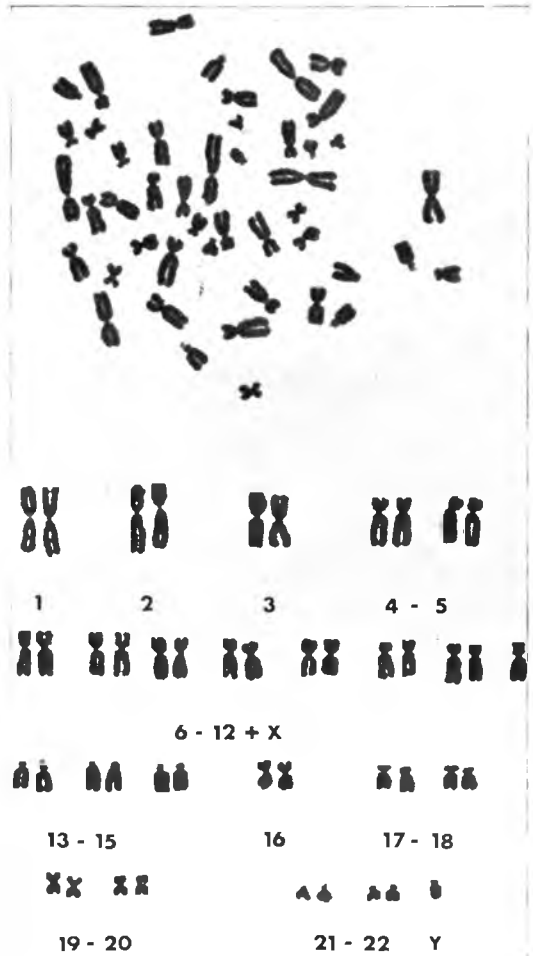


Fig. 1. Cell and Karyotype from a culture of the peripheral blood lymphocytes of a normal male.

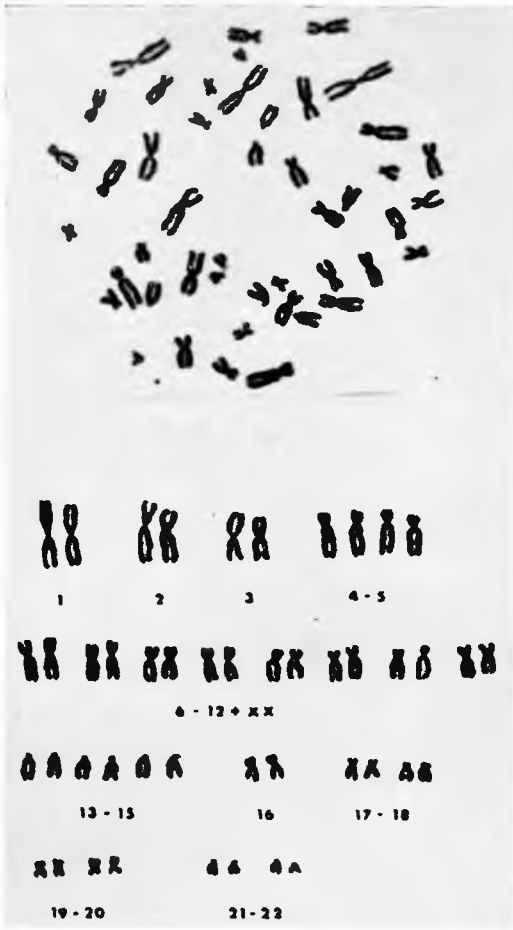

Fig. 2. Cell and Karyotype from a culture of the peripheral blood lymphocytes of a normal female.

Clinical Features

Much work remains to be done on the clinical expression of abnormalities of the chromosomes in man. Yet it is clear that in general, abnormalities of the autosomes give rise to very much more severe and widespread anomalies than abnormalities of the X and Y. Furthermore where there are clinical manifestations of abnormalities of the sex chromosomes these tend to affect mainly the primary and secondary sexual development, though they may also affect the mental development and behaviour of the affected individual. Thus the presence of an additional small autosome in

group 21-22 results in the profound disturbance of virtually every system in the body characteristic of mongolism. On the other hand the presence in an individual of an additional Y chromosome, which is of a comparable size, may be associated with no phenotypic abnormalities at all.

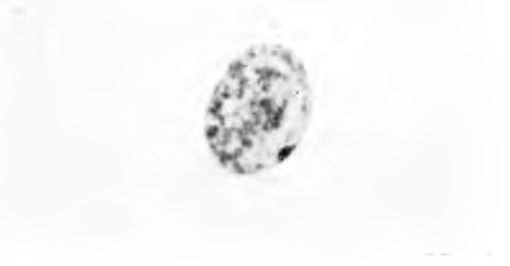

Fig. 3. Cell from the buccal mucosa of a normal female showing a single sex chromatin body (Barr body).

Autoradiography

By treating cultures of human cells with tritium labelled thymidine (a specific radioactive precursor of DNA), during the time the chromosomes are duplicating their material prior to division, it can be shown that there is a medium sized submetacentric chromosome in females. This synthesises DNA somewhat out of phase with all the other chromosomes in the cell, in that it both starts and finishes later. No such chromosome is present in cells from normal males. This chromosome is presumed to be the "inactive" X which also forms the sex chromatin body, and it has been shown that the number of late-synthesising X chromosomes is one less than the number of X chromosomes present in the cell. To determine whether such a chromosome or chromosomes are present in the cell tritium-labelled thymidine is usually added to the cultures some three to four hours before harvesting, when the majority of the chromosomes have completed or are in the final stages of synthesis. Single layers of the cells are then prepared on a microscope slide and covered by a layer of photographic emulsion which blackens when suitably exposed to a radio-active source. By this means any chromosome, or chromosome region, which is actively synthesising DNA later in the synthetic period can be recognised (Fig. 4).

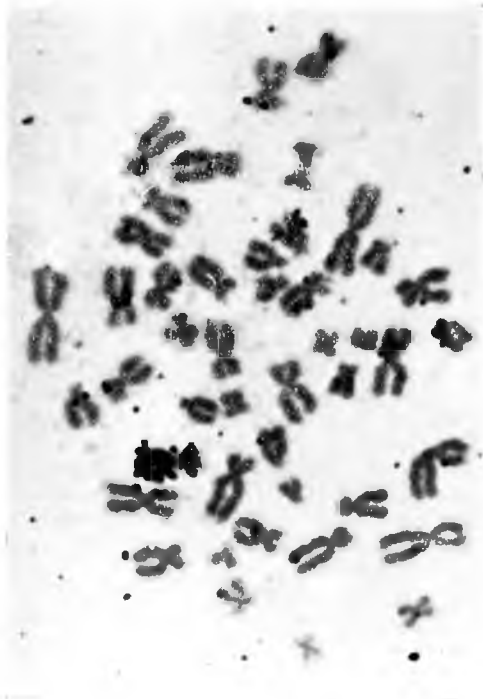


Fig. 4. A normal female cell subsequent to treatment with tritium labelled thymidine which shows one very heavily labelled medium sized submetacentric chromosome.

By way of illustration of how evidence from sex chromatin, clinical findings and autoradiography are correlated with the cytogenetic observations two cases can be considered. From cultures of both skin fibroblasts and peripheral blood leukocytes, both of these were shown to have 47 chromosomes, the additional chromosome being a medium sized submetacentric chromosome indistinguishable from the chromosomes of group 6-12 - X. The first patient was a 28 year old man who presented at a subfertility clinic, his wife having failed to conceive after 5 years of marriage. He was of average intelligence and the only clinical feature of note was the presence of small testes and azoospermia. The cells of his buccal mucosa were chromatin positive and autoradiography showed that he had a medium-sized submetacentric chromosomes which synthesised DNA late in the synthetic period. It was, therefore, concluded that the additional chromosome was an X and the patient an example of Klinefelter's syndrome with an XXY

sex chromosome constitution. The second patient was an 8 year old mentally retarded boy who was noted at birth to have a cleft soft palate and who had subsequently been hospitalised on a number of occasions for severe respiratory infections. He also had a number of congenital anomalies, including hypomandibulosis, a sinus on bridge of his nose, abnormal dentition, curious facies and a systolic murmur. Repeated observations on cells from a number of tissues showed him to be chromatin negative and autoradiography did not reveal any chromosome which synthesised DNA out of phase with the others. It was, therefore, concluded that the additional chromosome was not an X chromosome, but was an autosome belonging to group 6-12 and that the patient was trisomic for one of these autosomes.

Abnormalities of the Sex Chromosomes

The more commonly encountered numerical abnormalities of the sex chromosome in males are listed in Table 1, together with the sex chromatin and autoradiographical observations in these individuals. While these are the only abnormalities which will be considered in the

TABLE 1

Chromosome Constitution	Sex Chromatin	No. of Late Synthesising Medium Sized Chromosomes
XXY	+ve	1
XXX	++ve	2
XXXXY	+++ve	3
XXYY	+ve	1
XYY	-ve	0

present article it must be remembered that abnormalities of structure of both the X and Y chromosomes are encountered which may replace a normal sex chromosome or be additional to them. Furthermore it is very common to find, especially in individuals with abnormalities of the sex chromosomes, that not all the cells of the body have a uniform constitution, but that there are two or more cell lines present which can be distinguished cytogenetically, usually because they differ in their number of chromosomes. One of the cell lines may be normal or all may be abnormal, and the resulting clinical picture depends on the constitution of the constituent cell lines and their relative frequency and distrib-

ution in the body, especially in the gonads. Thus an individual who has two cell lines, one with 46 chromosomes and an XXY sex chromosome complement may, if his gonad is largely comprised of XY cells, be clinically indistinguishable from a normal male. Conversely, if his gonad is largely comprised of XXY cells he may be clinically indistinguishable from a "pure" XXY individual.

XXY Males

The presence of a single extra X chromosome is by far the commonest abnormality of the sex chromosome complement found in man. This is associated with the features of seminiferous tubule dysgenesis or Klinefelter's syndrome. These features are somewhat variable but hypogonadism is always present. Before puberty, however, regressive changes take place characterised by marked degeneration and hyalinization of the seminiferous tubules, unusual numbers of Leydig cells and the absence of spermatogenesis. These features may be accompanied by abnormalities of development of the secondary sex characters such as sparse growth of facial hair, female head or body hair distribution and development of breast tissue. Furthermore XXY males tend to be rather tall and eunoichoid in proportion, their leg length being long in relation to their height. The I.Q. of males with an extra X chromosome is on average lower than that of the normal population, such males being found significantly more often in institutions for the mentally defective than in the general population.

XXXXY

Males with two additional X chromosomes are much less common than males with a single additional X chromosome. They also exhibit the features of Klinefelter's syndrome but they are much more severely affected. Their testes are very small and the abnormalities of development of the secondary sex characteristics are usually very marked. Furthermore all XXXY individuals so far described have been mentally retarded — the majority of them being found amongst lower grade mental defectives.

XXXXY

Males with three additional X chromosomes are, as expected, even more uncommon

and more severely affected than those with two additional X chromosomes. They also show a number of additional congenital abnormalities. Their testes are usually extremely small and often cannot be defined clinically. Some underdevelopment of the penis or scrotum is usually found, sometimes linked with hypospadias, and the degree of underdevelopment of the secondary sex characters is often very marked. There are usually marked skeletal abnormalities present, among them some degree of fusion or synostosis of the ulna and radius. All XXXXY individuals described have been low grade mental defectives.

XXYY

Males with an additional X and an additional Y chromosome are clinically similar to the XXY male. They have small testes and show a similar range of abnormalities of development of the secondary sex characters. They are fairly uncommon, and all those so far described have been mentally defective. There is also some suggestion that they are taller than the XXY males and that they are unusually prone to the development of acromegaly. XXYY males were also found to comprise one third of all chromatin positive males in an institution for criminal and hard to manage mental defectives — a proportion far higher than that found in ordinary mental defective institutions. It has therefore been suggested that the presence of an additional Y chromosome may be a predisposing factor to criminal behaviour².

XYY

Until recently relatively little was known about males with one additional Y chromosome. Such individuals seem to be rare and the few cases described in the literature ranged from a normal fertile male examined because one of his children was a mongol, to a number of mentally retarded children with undescended testes. However, no clear picture of the XYY male had emerged, partly because they are indeed rather uncommon and partly because there is no easy way such as nuclear sexing, of recognising them in the population. Recently, however, a chromosome survey of the inmates of a hospital for psychopathic criminals and for criminal and hard to manage mental defectives has been completed

and it was shown that 9 of the 314 men examined had an XYY sex chromosome constitution³. Clinical examination of the 9 XYY males showed them to be unremarkable, with apparently normal testes and genitalia.¹ However, they were significantly taller than the other males in the institution — in fact in this particular institution one in three of the males 6 ft. and over in height had an additional Y chromosome. While the frequency of XYY males in the general population is not known there is no doubt that their frequency in this particular group of patients is very much greater than could be expected by chance. This data suggests that the XYY male is a clinically unremarkable tall male, who is unusually predisposed to aggressive and criminal behaviour.

In conclusion it must be remembered that, while some of the more bizarre abnormalities of the sex chromosomes which have been described in this article are extremely rare, chromatin positive males are common. Their incidence at birth is about 2 per thousand, which, if we assume there is no differential mortality, means that there are about 100,000 such individuals in the population of Britain at present. They form about 1% of all male mental defectives and have been shown to comprise over 10% of all azospermic and oligospermic

males attending a subfertility clinic⁵. Furthermore there is growing evidence that the presence of an additional Y chromosome may contribute to psychopathic and criminal behaviour. It is, therefore, evident that males with abnormalities of the sex chromosome complement contribute very significantly to human pathology.

REFERENCES

1. Barr, M. L. and Bertram, E. G. A morphological distinction between neurones of the male and female, and the behaviour of the nucleolar satellite during accelerated nucleoprotein synthesis, *Nature (Lond.)* 163, 676, 1949.
2. Casey, M. D., Segall, L. J., Street, D. R. K. and Blank, C. E. Sex chromosome abnormalities in two state hospitals for patients requiring special security, *Nature* 209, 641, 1966.
3. Jacobs, P. A., Brunton, M., Melville, M. M., Brittain, R. P. and McClellmont, W. F. Aggressive behaviour, mental subnormality and the XYY male, *Nature* 208, 1351, 1965.
4. Price, W. H., Strong, J. A., Whatmore, P. B., and McClellmont, W. F. Criminal patients with XYY sex-chromosome complement, *Lancet* i, 565, 1966.
5. Ferguson-Smith, M. A., Lennox, B., Mack, W. S. and Stewart, J. S. S. Klinefelter's syndrome: Frequency and testicular morphology in relation to nuclear sex, *Lancet* 2, 167, 1957.

MEDICAL and DENTAL DEFENCE UNION OF SCOTLAND LTD.

BENEFITS OFFERED BY THE UNION :

Defence of claims for alleged negligence in professional work and of actions for slander arising out of professional acts and relations, and indemnity for damages and legal costs arising from such claims.

Defence of claims against a principal in respect of acts by an assistant or locum. Advice on difficulties arising out of professional practice.

All benefits available to members in Scotland, England, Wales, Northern Ireland, Isle of Man, and Channel Islands, and to Short Service Officers with I.I.M. Forces in any part of the world, provided the Total Commissioned Service does not exceed five years.

Benefits of Membership for new graduates available from date of application provided duly registered at that date.

The subscription for new graduates £3 for the first three years after qualifying, thereafter normal subscription of £6 for members practising medicine and £4 for members practising dentistry.

An entrance fee is not payable by those who are elected to membership within twelve months of their first registration.

Full particulars and Forms of Application for Membership can be obtained from the Secretary.

C. C. MILLAR, T.D., C.A.

105 ST. VINCENT STREET, GLASGOW, C.2