

RES MEDICA

Journal of the Royal Medical Society



Abdominal Crises II

I. S. R. Sinclair
F.R.C.S.

Abstract

With national concern critically focussed upon the increasing problem of accidents it is well to remember that although the vast majority of injuries affect the extremities and although these injuries are a cause of great morbidity it is injuries to the head, the chest and the abdomen which kill. The closed head injury of civilian life is more misleading and often more rapidly fatal than many open wounds where the brain is exposed. So with abdominal injuries the intact abdomen may make diagnosis difficult and encourage a false sense of security. If the abdominal contents are damaged, two disasters may befall. First—and most urgent—is internal haemorrhage from lacerations of the solid viscera, especially spleen or liver, or from tearing of vessels. Later, if hollow organs have been damaged, the escape of their contents will lead to peritonitis.

Copyright Royal Medical Society. All rights reserved. The copyright is retained by the author and the Royal Medical Society, except where explicitly otherwise stated. Scans have been produced by the Digital Imaging Unit at Edinburgh University Library. Res Medica is supported by the University of Edinburgh's Journal Hosting Service: <http://journals.ed.ac.uk>

ISSN: 2051-7580 (Online) ISSN: 0482-3206 (Print)

Res Medica is published by the Royal Medical Society, 5/5 Bristo Square, Edinburgh, EH8 9AL

Res Medica, Spring 1962, 3(2): 7-17

doi: [10.2218/resmedica.v3i2.383](https://doi.org/10.2218/resmedica.v3i2.383)

ABDOMINAL CRISES

II.

By I. S. R. SINCLAIR F.R.C.S.

The second of three articles written by the Author for *Res Medica*.

ABDOMINAL TRAUMA

With national concern critically focussed upon the increasing problem of accidents it is well to remember that although the vast majority of injuries affect the extremities and although these injuries are a cause of great morbidity it is injuries to the head, the chest and the abdomen which kill. The closed head injury of civilian life is more misleading and often more rapidly fatal than many open wounds where the brain is exposed. So with abdominal injuries the intact abdomen may make diagnosis difficult and encourage a false sense of security. If the abdominal contents are damaged, two disasters may befall. First—and most urgent—is internal haemorrhage from lacerations of the solid viscera, especially spleen or liver, or from tearing of vessels. Later, if hollow organs have been damaged, the escape of their contents will lead to peritonitis.

MULTIPLE INJURIES

Early assessment is most difficult in the patient with multiple injuries who is also unconscious. In the conscious patient a complaint of abdominal pain will usually focus attention on the possibility of intraperitoneal injury and where bleeding is severe, spasm or even rigidity of the abdominal muscles is the rule. In the unconscious there is no such complaint and muscle tone may not be demonstrably increased, but tenderness, the great localiser, often helps. Firm palpation of the abdomen evinces a response by cry or grimace or movement which suggests strongly that all is not well. But in the most urgent cases the problem is the diagnosis and treatment of a severely shocked patient. Management is simplified when we remember that head injuries do not in themselves cause shock and that the presence of a head injury in a shocked patient is never a contra-indication to transfusion. Indeed, the level of consciousness often improves when the circulation is restored.

If the rapid transfusion of blood or plasma expanders in the order of 1 litre in ten or fifteen minutes fails to restore the circulation then either uncontrollable internal bleeding is continuing or there is some other cause for the circulatory collapse. Central (cardiac) failure will be shown by distended neck veins; cardiorespiratory failure is a likely explanation of continued shock

if there is a chest injury with paradoxical respiration and this must be controlled immediately by positive pressure respiration coupled with underwater drainage of the pleural cavity on the injured side or even bilaterally; the possibility of adrenocortical failure will be suggested by a knowledge of previous adrenalectomy or steroid therapy and confirmed by the dramatic response to intravenous steroids.

If shock persists despite these measures then internal bleeding is the presumptive cause and this is even more certain if initial response to rapid transfusion is followed by deterioration when the rate of transfusion is slowed down. Under these circumstances the abdomen must be opened forthwith, unless profuse bleeding from a pleural drain or cardiac tamponade in a case of chest injury dictates that thoracotomy be carried out first. When laparotomy is carried out for intraperitoneal haemorrhage it must never be forgotten that the induction of anaesthesia which abolishes vasoconstriction and relaxes the abdominal muscles may destroy circulatory compensation and allow further torrential bleeding. The surgeon must, therefore, be ready in the theatre and a full bottle of blood in place on the transfusion set before the anaesthetic begins.

Controllable major bleeding following trauma comes most often from upper abdominal injuries where liver or spleen are torn. In the case of the spleen the treatment is always splenectomy. The liver, on the other hand, must be sutured—a matter of considerable difficulty in many cases due to the consistence of the organ and the frequency with which lacerations involve the superior surface necessitating a thoraco-abdominal approach. Rarely, a week or two after apparently successful suture of the liver, the patient develops melaena or haematemesis due to the discharge of a deep-seated intrahepatic haematoma through the biliary passages. This form of internal secondary haemorrhage is always fatal unless further surgery with full exposure and drainage of the central hepatic cavity is undertaken.

When severe intraperitoneal bleeding follows major injuries of the lower abdomen or pelvis it very often arises from tears of major vessels such as the iliac veins and is nearly always fatal before effective treatment is available. Profound shock does not follow uncomplicated fractures of the pelvis and is an indication for immediate laparotomy.

INJURIES OF THE ABDOMINAL WALL

The diagnosis of underlying visceral damage is often confused by the presence of tenderness due to parietal injury. This is well recognised in relation to *RUPTURES OF THE SPLEEN* where there is often no more than tenderness and bruising over the lower rib for many days. The possibility of a sub-capsular tear of the splenic pulp must be foremost in the doctor's mind in all such cases and the patient kept within easy reach of medical aid for at least two weeks lest disastrous bleeding suddenly occurs. *BOWEL*, like the spleen, may be the site of a delayed rupture following an intramural haematoma and a blow sufficient to produce obvious bruising of the abdominal wall is always an indication for careful observation over the following two weeks.

When examining a patient who has sustained a blow on the abdomen it is important to note whether an *EXTERNAL HERNIA* is present. When the

intra-abdominal pressure suddenly rises, bowel within the intact peritoneal cavity is subjected to a uniform increase in pressure on all sides, but if a loop of bowel lies across or in a hernial sac the localised lack of support in relation to the defect in the abdominal wall greatly increases the chance of rupture at that point.

Of course, the injury may after all be confined to the abdominal wall. Contusion of the abdominal muscles is very common and rarely actual rupture may occur, as in the rupture of the lower part of the rectus abdominis which is classically associated with the spasms of tetanus or with sudden contraction of a muscle weakened by pregnancy or obesity. I have seen one case where the rupture occurred after trivial strain in an apparently fit young man. The diagnosis of leukaemia was confirmed from the blood aspirated from the haematoma which, as usual, tracked up behind the muscle to give a palpable hypogastric swelling. The diagnosis was suspected because of previous experience with leukaemia presenting as a partial rupture in other muscles.

THE DIAPHRAGM may suffer a peripheral detachment by coughing or vomiting or by crushing injuries which spring the chest wall. In minor cases the pain is similar to that of fractured ribs, but corresponds to the attachments of the diaphragm, is not associated with superficial tenderness and is not greatly relieved by strapping of the chest wall or infiltration with local anaesthetic. The symptoms subside spontaneously over two to three weeks. When the dome of the diaphragm is torn there may be immediate haemothorax and haemoperitoneum. The injury is usually a severe crush and laparotomy or thoracotomy is often indicated regardless of the suspicion of diaphragmatic damage. An additional complication is herniation of the stomach or, less often, the colon into the left hemithorax with acute gastric obstruction and severe cardiorespiratory embarrassment. Such herniation may be suspected from the history and clinical picture, especially when bowel sounds or gastric succussion are heard in the left side of the chest. Immediate operation is required.

Stab Wounds

Carrying the same diagnostic and therapeutic difficulties as the closed abdominal injury is the apparently trivial stab wound. A Wolf Cub was brought to hospital one evening. On his abdomen was a tiny cut, 5 mm. long, just to the right of the umbilicus. He had been whittling wood the wrong way and when the knife slipped the blade—the small blade of a boys' penknife—pierced his clothes and entered the abdominal wall. There were neither symptoms nor signs to indicate intraperitoneal damage. Six hours later I opened his abdomen because of signs of spreading peritoneal irritation and found bleeding from an artery in his transverse mesocolon. The 3 cm. blade had not only penetrated his clothes and his abdominal wall, but had passed through the mesocolon to nick the anterior longitudinal ligament between aorta and vena cava! Any stab wound, however small, between clavicle and groin must be assumed to have penetrated the thoracic or abdominal cavities and demands admission to hospital.

PANCREATIC INJURIES

The pancreas is rarely injured alone although it may be contused—or even severed—by crushing injuries as it lies across the front of the vertebral column. Early diagnosis can be no more than conjecture and every surgeon knows to search the area of the pancreas and retroperitoneal duodenum when exploring the abdomen after crushing injuries. If found to be severed, the distal part

of the gland may be excised or an attempt made to repair the damage. The former course is probably the safer but whatever is done the area must be drained as fistula formation is common.

Pancreatic injury, like any other retroperitoneal injury, will cause a severe paralytic ileus. Acute pancreatitis is a rare complication of injury but not uncommonly a pseudo cyst of the pancreas forms slowly over two or three weeks. This may be a self-limiting collection of blood and exudate in the lesser peritoneal sac or its contents may be replenished by a tiny fistula from an injured pancreatic duct. The patient will complain of slowly increasing, continuous, boring upper abdominal pain often radiating to the back and sometimes accompanied by recurrent vomiting. There is a tender upper abdominal fullness and characteristic forward displacement of the stomach in the lateral x-ray. Simple external drainage will cure the peripancreatic haematoma but where a fistulous communication exists between the cyst and the pancreatic duct system an external fistula is avoided by draining the cyst internally into the stomach or small bowel.

Injuries to the Renal Tract

RENAL INJURIES seldom present as abdominal crises although the diseased kidney which is especially liable to rupture, may occasionally cause intraperitoneal bleeding simulating an acute abdominal emergency. Contusion of the kidney may accompany a ruptured spleen and the urine should always be carefully watched in such cases. The management of renal injuries is essentially conservative. Only if haematuria is excessive or an increasing retroperitoneal haematoma is present will surgery be undertaken. It is, of course, essential to confirm the presence of a functioning kidney on the uninjured side and this is most simply done by an intravenous pyelogram which is part of the emergency investigation of any case of renal injury. It must be remembered that a shadow will not be obtained on either side in the shocked patient—the investigation must be delayed until a reasonable blood pressure has restored glomerular filtration.

RUPTURE OF THE BLADDER may occur as an isolated injury from a blow on the full bladder but typically it accompanies a factured pelvis. Indeed, the immediate danger of pelvic fractures lies only in their association with damage to the bladder, rectum or great vessels. Ruptured bladder should always be suspected if the patient cannot pass urine, if he passes blood-stained urine, if he has strangury or if there is lower abdominal swelling or tenderness. Intraperitoneal rupture will quickly produce signs of general peritonitis but extraperitoneal rupture will give a slowly progressive pelvic cellulitis which spreads to the anterior abdominal wall and the inguinal regions. A catheter is passed into the bladder and, if the clinical picture is in doubt, an x-ray is taken after the injection of a small amount of contrast medium. The bladder should never be filled with fluid to test for suspected rupture as this merely increases the spillage. With either type of rupture immediate suture of the rent with continuous bladder drainage is required.

Injuries of Hollow Viscera

Apart from penetrating wounds rupture of the stomach is very rare. The colon, especially the caecum, may occasionally be ruptured in a closed injury, as was seen in underwater blast injuries during the war, and the possibility of delayed rupture of the caecum must be remembered after any blow in the right iliac fossa.

Wounds which involve the COLON are particularly dangerous. When the retroperitoneal portions of the bowel are involved a fulminating retroperitoneal clostridial infection is apt to follow. This type of injury is of some historical interest to Edinburgh University for it was in 1915 that Captain Fraser, later

Professor Sir John Fraser, first reported from France the use of Edinburgh University Solution (Eusol), developed a few months previously by Professor Lorraine Smith, in the treatment of gunshot wounds of the colon with retro-peritoneal gas gangrene.

The SMALL BOWEL is most vulnerable at its fixed points where it cannot move away from a sudden impact. Ruptures from closed injuries are thus most common in the third part of the duodenum, near the duodenojejunal flexure, or where the gut is anchored by adhesions. The dangerous role of external hernias in this connection has already been mentioned. The ruptured bowel may show prolonged tonic spasm of its muscular wall so that peritoneal soiling is sometimes delayed for many hours.

Perforations from Within

Swallowed razor blades and other sharp objects may occasionally perforate the stomach while fish bones and, in some countries, toothpicks (as much part of the American way of life as the Martini and the Club Sandwich which they accompany) may penetrate the small intestine but perforations have been more commonly recorded in the large intestine after such diagnostic procedures as sigmoidoscopy or barium enema, or following the insertion of foreign bodies into the rectum.

On occasion, intraperitoneal perforation of the BLADDER has followed the injudicious use of a catheter with a rigid or semi-rigid tip (such as a Tieman's catheter) for continuous bladder drainage. Only a soft, blunt tipped catheter should ever be left for long in an empty bladder.

ACUTE INTESTINAL OBSTRUCTION

PATHOLOGY OF ACUTE OBSTRUCTION

Obstruction to the passage of food through the alimentary canal may be primarily mechanical, vascular or neurogenic.

Intestinal obstruction of purely vascular origin is generally the result of thrombosis or embolism within the mesenteric vessels and is due to ischaemic paralysis of the intestinal muscle.

In mechanical obstruction the blood supply may be primarily compromised by the same mechanism which obstructs the bowel lumen, as in volvulus, or secondary strangulation may develop later due to increasing tension within the bowel. This latter mechanism is most commonly seen in the obstructed loop of small bowel within a hernial sac but occurs also in large bowel obstruction when a competent ileocaecal valve prevents decompression into the ileum. In this circumstance a "closed loop obstruction" is formed even in the absence of twisting or misplacement of the colon and, because the tension on the wall of a tube of varying diameter varies with the diameter, the risk of intramural strangulation of this kind is greatest in the caecum. In neurogenic ileus the muscular paralysis allows a much greater degree of generalised distension without the danger of intramural strangulation.

In the small intestine distension is mainly due to fluid. The greater part of the fluid is retained gastro-intestinal secretions. Although lymphatic absorption from distended bowel is increased, venous absorption is reduced by up to 80 per cent so that a vicious circle of fluid loss becomes established, and the importance of this fluid loss is obvious when one remembers that the

secretion of digestive juices amounts to some 8 litres in 24 hours, or rather more than twice the plasma volume. Generally speaking the jejunum decompresses itself proximally into the stomach and the colon often decompresses proximally into the ileum. Therefore it is in the ileum that retention of fluid is usually greatest and the reduction of venous absorption most serious.

The gas present is mostly derived from swallowed air and only a small part is due to diffusion into the bowel or bacterial fermentation. Because of differential diffusion rates the oxygen of swallowed air is absorbed so that the residue is chiefly nitrogen. Reduction in the proportion of nitrogen in the inspired air by the administration of oxygen will reduce the nitrogen tension in the blood and so facilitate the diffusion of nitrogen from the lumen of the bowel. This method of therapy may occasionally relieve distension but is usually disappointing owing to the preponderance of fluid in distended small bowel. Colonic distension is largely gaseous but most of this results from bacterial activity.

Distension at first increases tonic muscle activity in the bowel so that obstructed bowel becomes shortened by as much as one-third of its normal length and its wall becomes thick and oedematous. Apart from the local effects, gross intestinal distension may cause serious cardiorespiratory embarrassment especially in obese or emphysematous patients.

When secondary strangulation is present the vascular obstruction is initially venous and the rate and amount of exudate and distension are therefore increased, but in primary strangulation when arterial inflow alone is cut off—as in mesenteric arterial thrombosis or when both arterial and venous flow cease simultaneously, as a volvulus—there is little distension and no gas in the affected loop making diagnosis exceptionally difficult.

Once the circulation has stopped in a segment of bowel there is a marked tendency for venous thrombosis to extend proximally. Because of this, apparently normal bowel proximal to a strangulated segment may later necrose as a result of venous infarction and this sequence of events explains some distressing failures after resection of strangulated bowel.

The time taken for strangulation to produce necrosis of the bowel wall is so variable that a short history must never permit a sense of security. Such factors as local mechanical pressure will hasten the onset of necrosis—the constriction ring at the neck of a strangulated hernia is the first part of the bowel to become non-viable. The role of infection has been the subject of much experiment and there is no doubt that once viability is impaired infection can hasten the onset of necrosis and that, at least in dogs, the survival of strangulated bowel is greatly prolonged by prior administration of antibiotics. There is, however, little evidence that systemic absorption of bacterial toxins is important until necrosis of the bowel wall has taken place.

When the obstruction has been relieved it must not be assumed that all danger is past. The risk of retrograde venous thrombosis has already been mentioned. The released bowel elongates and relaxes providing a large cavity into which fluid passes at a dangerous rate through the walls of capillaries damaged by anoxia. This explains the more rapid death of animals after release of a long loop of strangulated ileum as compared to a control group in which the strangulation was not released.

DIAGNOSIS OF OBSTRUCTION

Three questions must be answered in every case where the diagnosis is considered. Is mechanical obstruction present? What is the site and degree of the obstruction? Is it strangulated?

The cardinal symptom of mechanical obstruction is *INTESTINAL COLIC*, felt usually as waves of non-radiating pain in the central abdomen. Auscultation will reveal that the waves of pain coincide with spasms of increased intestinal activity. Vomiting first of gastric and later of intestinal contents is characteristic but may be delayed in low obstructions while in high obstructions the vomitus will never become "faecal." Similarly, distension will be absent in the early stages of obstruction and will never appear at all in really high obstruction.

These facts are not sufficiently appreciated. After a jeep accident a young airman was admitted to my unit in the Middle East with a fractured 2nd lumbar vertebra. Despite a ravenous appetite he vomited all his food a few minutes after ingestion. For several days I foolishly insisted that a scaphoid abdomen, normal bowel sounds, a normal gas pattern on abdominal x-ray (see below) and the fact that the vomitus remained dark green all indicated a neurogenic obstruction. In fact, this clinical picture was pathognomonic of a very high mechanical block and at laparotomy the first loop of his jejunum lay trapped and necrotic between the 2nd and 3rd lumbar vertebrae. For once the anterior longitudinal ligament had given way and allowed the vertebral bodies to open and close like a vice, catching a loop of bowel in the process. That this bizarre mechanism of obstruction had not been previously recorded was no excuse for failure to recognise that mechanical obstruction of some kind was present and the confusion of thought which led to this young man's death has been on my conscience ever since.

Absolute constipation is a confirmatory symptom but, like "faecal" vomiting, comes too late to help in timely diagnosis. Undoubtedly, the most valuable aid to diagnosis is the plain x-ray of the abdomen. The presence of *GAS SHADOWS* in the small bowel is almost always pathological and this is the basis of radiological diagnosis. On this criterion it will be appreciated that x-rays will not give confirmatory evidence in cases of very high small bowel obstruction or in those primary strangulations of small bowel where no gas is trapped. Therefore, a negative x-ray in a patient with severe intestinal colic and vomiting is an indication for urgent laparotomy. In all other types of obstruction the combination of distended loops of bowel seen on the film taken with the patient supine and fluid levels seen in the film taken with the patient erect or in the lateral position will provide evidence not only of the presence of obstruction but of its site.

The presence of strangulation can be surmised from various signs—continuous pain is superimposed upon the original colic; local tenderness and rebound tenderness indicate spreading peritoneal inflammation; if a neoplastic or inflammatory mass can be excluded a palpable tender mass is highly suggestive of strangulation. What is much more important from the practical point of view is that the presence of strangulation can rarely be excluded with certainty.

MANAGEMENT OF INTESTINAL OBSTRUCTION

The introduction of a simple method of *INTESTINAL DECOMPRESSION* by continuous suction was a major advance in the management of intestinal

obstruction. Ideally a tube carrying an inflatable balloon near its tip should be passed through the stomach and carried by peristalsis progressively down the bowel until the point of obstruction has been reached. In this way the whole bowel above the obstruction will be effectively decompressed. Unfortunately, with the reversed peristaltic gradient found in acute obstructions it is rarely possible to induce the balloon to pass beyond the pylorus and in practice suction is applied to an indwelling gastric tube which must be of large bore—a Ryle's or similar fine tube cannot possibly cope with the large volumes of fluid which accumulate in the stomach and only creates a false sense of security. Suction should at first be continuous and applied with a negative pressure of about 75 cm. of water.

It must be appreciated that, except in obstructions due to neurogenic ileus or extensive adhesions (which make strangulation by herniation or volvulus virtually impossible) suction is not in itself a treatment for the obstruction. Successful suction will quickly relieve the patient of vomiting and colicky pain and the abdominal girth will diminish progressively as judged by repeated measurement. The intestine will recover its tone making surgery easier and safer—but operation remains necessary to deal with the mechanical problem. Wherever strangulation seems possible, and this includes the vast majority of cases, suction is to be regarded as no more than a necessary pre-operative measure and operation will be carried out as soon as the patient's condition permits.

In those few cases where suction is continued as the definitive form of treatment success will be indicated by the appearance of gas in the colon on x-ray examination and later by the passage of flatus. The amount of fluid obtained by suction will diminish progressively and its colour will revert to the pale green or colourless fluid of normal gastric aspirate. Continuing dark green aspirate should suggest the possibility of an unrelieved high jejunal obstruction (as in the case described above). During the period of gastric or intestinal suction it is a common error to allow patients a limited intake of water by mouth in an attempt to assuage their thirst. Swallowed water is quickly aspirated with its added quota of salts. The patient's fluid and electrolyte imbalance is increased while thirst is not relieved. Careful mouth toilet and ice to suck will keep the patient tolerably comfortable until thirst is relieved by correct intravenous replacement.

The fluid aspirated by suction is fluid which has long since been lost from the tissues and INTRAVENOUS REPLACEMENT is urgently needed. It is impossible to correct at once the disturbances of electrolyte balance which may have developed over many hours or even days and to delay operation while such an attempt is made is unnecessary and unwise. In the acute obstruction of less than two days' duration electrolyte disturbances are not in themselves likely to add any risk to operation, therefore their correction will not make operation safer. The danger is that of acute peripheral circulatory failure and this is avoided by immediate transfusion of plasma or blood to restore the depleted blood volume. Operation is now safe and the long term restoration of the body's water and electrolyte pattern can proceed at leisure during and after surgery.

The use of enemata is confined to cases of large bowel obstruction especially in the left colon, where impaction of a scyballous mass in a malignant stricture is often the precipitating factor. If this is the case, an enema may tide over the emergency and allow later elective surgery under optimum conditions.

SPECIAL TYPES OF OBSTRUCTION

INTRALUMINAL OBSTRUCTION is relatively uncommon. In meconium ileus the infant's small intestine is blocked by inspissated meconium. The local

condition is due to an absence of normal pancreatic secretions and is part of a more general secretory defect known as mucoviscidosis. The defect, which is hereditary, is characterised by an excessively high salt content in sweat, saliva and sputum. This peculiarity is used in diagnosis and helps to explain the electrolyte difficulties into which these children may run in hot climates and the susceptibility to pulmonary infections which is such a common cause of death (staphylococci thrive in the high salt concentration of the bronchial secretions). Other anomalies such as bronchiectasis or cystic disease of the lungs are often present.

IMPACTION OF FAECES in the rectum may lead to a subacute obstruction in the elderly and bed ridden but more usually causes spurious diarrhoea. The wedging of a faecal mass within the stricture of a colonic carcinoma has already been mentioned. A more exotic type of obturation obstruction is **GALL-STONE ILEUS** due to ulceration of a gall-stone into the small bowel where it usually becomes impacted toward the lower end of the ileum. Occurring typically in elderly women with a long history of biliary dyspepsia the shadow of the stone may be seen on a straight x-ray which may also show gas from the intestine outlining the biliary tree. Less well known is obstruction due to a bolus of vegetable matter. This is found almost exclusively after gastrectomy or gastroenterostomy and is nearly always due to orange pith.

INTRAMURAL OBSTRUCTION may be due to congenital stenosis or atresias. Stenosis is usually at duodenal level and usually presents early with severe vomiting though an occasional case has first come to hospital in adult life. Atresias are most common in the ileum and are often multiple. They always present as acute obstruction in infancy. Imperforate anus might be included in this group.

Acquired strictures as sequelae of trauma, ischaemia or infection are unlikely to present as abdominal crises, but Crohn's Disease occasionally produces acute obstruction. In the large intestine diverticulitis and segmental colitis may both cause acute obstruction and in people who have been abroad an amoeboma may do likewise.

The majority of intramural obstructions are due to tumours. In the colon carcinoma is by far the commonest tumour but in the small bowel benign tumours causing obstruction by intussusception are relatively common whereas malignant tumours cause obstruction very late if at all. An unusual "tumour" which may obstruct the small bowel is a haematoma arising in patients with purpura or an anti-coagulant therapy.

EXTRINSIC OBSTRUCTIONS are most commonly due to hernias but obstruction by adhesions and bands comes a close second. The liability of every obstructed hernia to become strangulated makes early operation imperative. The diagnosis should be easy yet the absence of intestinal obstruction in a Richter's hernia, where only part of the circumference of the bowel is trapped, and the concealment of the femoral hernia in a fold of fat in obese female patients still give rise to disastrous errors in management. Conversely it must be remembered that a painful, tender inguinal hernia is strangulated only if irreducible. I have seen a perforated peptic ulcer diagnosed as a strangulated inguinal hernia because of the tenderness produced by an accumulation of peritoneal fluid within the wide-necked hernial sac.

Although bands and adhesions may be congenital, for example the band connecting a Meckel's diverticulum to the umbilicus or the adhesions between an undescended caecum and the right side of the abdomen which obstruct the duodenum in infants with malrotation of the gut, they are most commonly post-operative. Adhesive obstruction may develop very early after an operation and the distinction between post-operative neurogenic ileus and a mechanical

obstruction can be extremely difficult. The risk of strangulation is much greater with narrow bands than with broad adhesions. Such bands take time to form and it is therefore in the obstruction arising months or years after an abdominal operation that operation is most urgent, but even in the early post-operative period it is never wise to assume that ileus alone can explain distension and vomiting for more than a week especially after any operation in which loops of bowel have been anastomosed or exteriorised. Exploration usually reveals an internal hernia or a loop of bowel adherent to the operation wound.

VOLVULUS. Congenital errors in rotation and fixation of the gut are responsible for volvulus of the whole small intestine which is a common type of obstruction in the newborn and for volvulus of the caecum which may occur in adults. Abnormal fixation of the apex of an intestinal loop by a Meckel's diverticulum or an adhesion is responsible for volvulus of an isolated loop of small bowel. Volvulus of the pelvic colon, the commonest type encountered in adult practice, is much rarer in this country than in poorer communities due to the increased length and bulk of the pelvic colon which results from a vegetarian type of diet. The patient is usually elderly and the clinical picture is dominated by the rapid development of enormous gaseous distension. The radiological appearance is diagnostic. Except in the very early stages the twist is too tight to permit passage of a rectal tube into the obstructed segment and operation is urgently required if gangrene is to be forestalled.

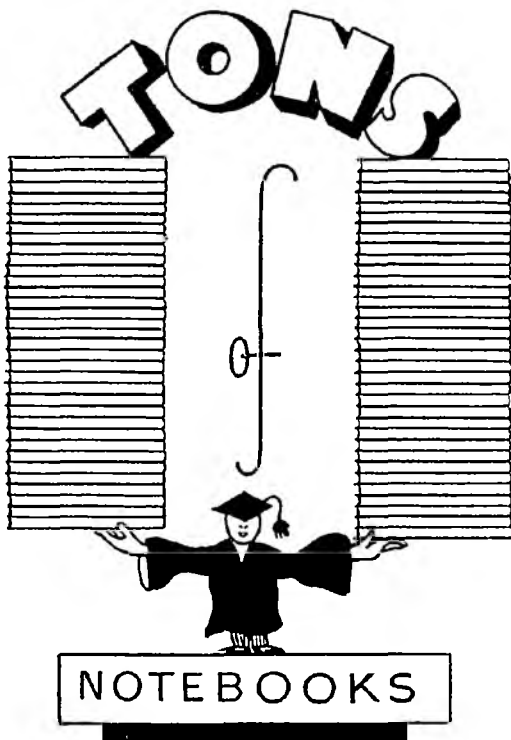
INTUSSUSCEPTION in infancy nearly always arises in the ileocaecal region in a healthy baby without any underlying pathology in the bowel. The recurring spasms of severe colic and reflex vomiting with intervening periods of complete relaxation during which a mass is usually palpable and the presence of blood and mucus on the rectal finger are diagnostic of this type of strangulation. An opaque enema will not only confirm the diagnosis but will in many cases produce complete or partial reduction. When operative treatment is considered necessary, as it is in most cases, it is a matter of urgency but must always wait until shock has been corrected and lost fluid at least partially restored because infants tolerate dehydration very badly.

In adults intussusception is generally induced by some primary bowel pathology, and a simple tumour of the ileum is the commonest cause. Adult cases are therefore usually of the ileo-ileal type

VASCULAR OBSTRUCTIONS. Occlusions of small mesenteric vessels by embolus or thrombus are not uncommon in obliterative arterial disease. They may be silent or result in episodes of abdominal colic and distension. Tests for occult blood in the stool are positive. Such episodes usually resolve spontaneously although rarely a late result may be the development of a fibrous stricture in the involved segment of bowel. When major mesenteric occlusion occurs necrosis of the ischaemic bowel will usually follow. While resection of many feet of gangrenous small bowel is compatible with survival the surgeon will often find the entire small intestine to be involved. In a few such cases embolectomy or disobliteration has been undertaken with success and in one or two others immediate heparinization has resulted in survival of the involved bowel by preventing a spreading thrombosis. However, the mortality in this group of patients remains very high.

NEUROGENIC ILEUS. Autonomic dysfunction may result in increased tone in the gut. Thus in achalasia of the oesophagus or Hirschsprung's disease of the colon the aganglionic segment remains contracted and the colic of lead poisoning was referred to in the first article of this series. More commonly decreased muscle tone and diminished peristalsis are found and the condition is then known as paralytic ileus. This condition may follow trauma,

both intraperitoneal and retroperitoneal. It is a common complication of fractures of the spine or pelvis, and of operations on the abdominal aorta or lumbar sympathetic chains. Infection in the peritoneal cavity always results in decreased activity of the intestine in the inflamed area—Nature's splint, as it were, to prevent the spread of infection and allow rest to the inflamed part. Uraemia and severe cellular potassium deficiencies such as may develop in patients after long periods of gastric suction without potassium replacement, likewise cause paralytic ileus. Generally speaking surgery has nothing to offer in such cases and conservative treatment by intestinal suction and correction of fluid and metabolic disturbances is successful.



BROWN

OF THE

MOUNDSTATIONERS
and PRINTERS**NORTH BANK STREET
EDINBURGH**Telephone CAL 5960
