

## Original article

# Hypoxia imaging with [<sup>18</sup>F]HX4 PET in squamous cell head and neck cancers: a pilot study for integration into treatment planning

Helen M. Betts<sup>a,d</sup>, Richard A. O'Connor<sup>b</sup>, Judith A. Christian<sup>c</sup>, Vidhiya Vinayakamoorthy<sup>b</sup>, Karen Foweraker<sup>c</sup>, Abigail C. Pascoe<sup>c</sup> and Alan C. Perkins<sup>a,d</sup>

**Background** Radical chemoradiotherapy is the primary treatment for head and neck cancers in many hospitals. Tumour hypoxia causes radiotherapy resistance and is an indicator of poor prognosis for patients. Identifying hypoxia to select patients for intensified or hypoxia-modified treatment regimens is therefore of high clinical importance.

**Patients and methods** We evaluated hypoxia in a group of patients with newly diagnosed squamous cell head and neck cancer using the hypoxia-selective radiotracer [<sup>18</sup>F]HX4. Patients underwent a single [<sup>18</sup>F]HX4 PET/computed tomography scan prior to beginning chemoradiotherapy.

**Results** Three out of eight patients recruited were scanned with [<sup>18</sup>F]HX4. Two out of three had pretreatment [<sup>18</sup>F]FDG PET/computed tomography scans available for review. [<sup>18</sup>F]HX4 tumour uptake varied between patients, with tumour to mediastinal ratios ranging from 1 to 3.5.

**Conclusion** The spectrum of [<sup>18</sup>F]HX4 uptake in this small series of patients exemplifies the difference in oxygenation profiles between histologically similar tumours. Performing

an additional PET scan with [<sup>18</sup>F]HX4 prior to chemoradiotherapy treatment was logistically challenging in a routine setting, and therefore validation of its clinical impact should be the focus of future studies [EudraCT number 2013-003563-58]. *Nucl Med Commun* 00:000–000 Copyright © 2018 The Author(s). Published by Wolters Kluwer Health, Inc.

Nuclear Medicine Communications 2018, 00:000–000

**Keywords:** chemoradiotherapy, [<sup>18</sup>F]HX4, head and neck cancer, hypoxia, PET/CT, radiotherapy planning, squamous cell carcinoma

<sup>a</sup>Department of Medical Physics and Clinical Engineering, <sup>b</sup>Department of Radiology, <sup>c</sup>Department of Oncology and Radiotherapy, Nottingham University Hospitals NHS Trust and <sup>d</sup>Department of Radiological Sciences, School of Medicine, University of Nottingham, Queen's Medical Centre, Nottingham, UK

Correspondence to Helen M. Betts, DPhil, Department of Medical Physics and Clinical Engineering, Nottingham University Hospitals NHS Trust, PET/CT Centre, Nottingham City Hospital, Nottingham, NG5 1PB, UK  
Tel: +44 011 5970 9172; e-mail: helen.betts@nottingham.ac.uk

Received 4 April 2018 Revised 6 September 2018 Accepted 5 October 2018

## Introduction

Radical radiotherapy with curative intent has become the standard of care for patients with head and neck cancers in many institutions, particularly for patients with advanced tumours where disease is difficult to resect surgically. Recent advances in chemoradiotherapy mean that overall survival after chemoradiation and surgery are equivalent. Treatment selection is now based on patient preference and the potential complications of each treatment modality for an individual tumour [1].

In cases where chemoradiotherapy is being considered, its planning could be refined to account for the low oxygen concentration (hypoxia) found in some, but not all, head and neck squamous cell carcinomas (HNSCC). Hypoxia contributes to radiotherapy resistance and patients who have hypoxic tumours have a poorer prognosis [2–4]. Accurate

evaluation of hypoxia before chemoradiotherapy could help clinicians to divert patients to more suitable treatments like surgery, or to justify radiotherapy dose escalation, radiosensitising agents, or in the future, hypoxia-activated cytotoxins [5,6].

Hypoxia specific radiotracers for PET imaging offer practical advantages for routine clinical use over the invasive oxygen-sensitive electrode [7,8]. [<sup>18</sup>F]HX4, (3-[<sup>18</sup>F]fluoro-2-[4-[(2-nitro-1H-imidazol-1-yl)methyl]-1H-1,2,3-triazol-1-yl]propan-1-ol) is a hydrophilic variant of the 2-nitroimidazole class of radiotracers that includes [<sup>18</sup>F]FMISO, and is proposed to have faster clearance from normally oxygenated sites than structurally related compounds [9,10]. Achieving optimum tumour-to-background ratios rapidly is desirable to reduce the scan appointment times for these often very unwell patients. Furthermore, a short radiotracer uptake time improves throughput in busy PET/computed tomography (CT) departments with limited patient accommodation. Our aim was to perform a preliminary evaluation of [<sup>18</sup>F]HX4 PET in the diagnostic pathway of HNSCC

This is an open-access article distributed under the terms of the Creative Commons Attribution-Non Commercial-No Derivatives License 4.0 (CCBY-NC-ND), where it is permissible to download and share the work provided it is properly cited. The work cannot be changed in any way or used commercially without permission from the journal.

patients, who were being prepared for radical radiotherapy with curative intent.

## Patients and methods

### Ethics approval and consent

The Nottingham OXPET trial (EudraCT 2013-003563-58), in which [<sup>18</sup>F]HX4 was defined as an Investigational Medicinal Product, was reviewed and approved by the UK Medicines and Healthcare products Regulatory Agency and the Northampton Research Ethics Committee (reference 13/EM/0377). [<sup>18</sup>F]HX4 is an investigational radiotracer that does not have approval for routine clinical use. Administration of Radioactive Substances Advisory Committee approval and local National Health Service permission were granted prior to study commencement. All participants gave written informed consent prior to taking part.

### Participants

Inclusion criteria for the study were biopsy-proven HNSCC without distant metastases (primary tumour and loco-regional lymph nodes only) and a treatment plan of radical chemoradiotherapy with curative intent. Eight participants were recruited between July 2015 and April 2017. Only three participants were eventually scanned with [<sup>18</sup>F]HX4 due to logistical constraints. Two participants were male and one female. Their age range was 53–71 years.

### [<sup>18</sup>F]HX4 and scanning protocols

All three patients underwent pretreatment staging with a CT scan of the neck and chest, MR scan of the neck, and in two cases [<sup>18</sup>F]FDG PET/CT. [<sup>18</sup>F]HX4 PET/CT was performed between completion of staging and the start of treatment.

[<sup>18</sup>F]HX4 was prepared according to good manufacturing practice at the Nottingham PET/CT centre, using our previously reported method [11]. The radiosynthesis followed a one-pot, nucleophilic <sup>18</sup>F-fluorination-deprotection sequence on a GE TracerLab MX-FDG automated module (GE Healthcare, Little Chalfont, Buckinghamshire, UK). [<sup>18</sup>F]HX4 was purified by high-performance liquid chromatography and passed through sterilising filters prior to quality control and Qualified Person release.

Without prior fasting, patients were administered with 312–383 MBq, with a planned uptake period of 180 min. Whole-body imaging was performed using a GE Discovery 710 PET/CT scanner (GE Healthcare, Little Chalfont, Buckinghamshire, UK). The estimated average effective dose for the [<sup>18</sup>F]HX4 component of the scan was 11 mSv based on literature values [12]. Due to the Investigational Medicinal Product classification of [<sup>18</sup>F]HX4 and no prior clinical experience of [<sup>18</sup>F]HX4 at our institution, participants were asked to remain within the PET centre between injection and scan, to monitor for adverse events. Patients were given a contact number in case of feeling unwell after leaving the PET/CT centre, and their general practitioner notified of trial participation to assist in collecting adverse

**Table 1 Participant characteristics and PET scan parameters**

	Patient		
	1	2	3
Sex	Male	Female	Male
Weight (kg)	49	69	68
Primary tumour site	Tongue base	Oropharynx	Right tonsil
TNM staging	T4N2cM0	T2N2bM0	T2N2cM0
Site evaluated	Left neck nodal mass	Right neck nodal mass	Right neck nodal mass
Gross tumour volume of evaluated site/cm <sup>3</sup>	134	83	60
[ <sup>18</sup> F]HX4			
SUV <sub>max</sub> primary tumour region	0.9	2.5	1.4
SUV <sub>mean</sub> nodal disease	1.0	5.2	2.0
SUV <sub>max</sub> mediastinal activity	1.0	1.5	1.1
SUV <sub>max</sub> liver activity	1.5	2.4	1.4
Tumour to mediastinal ratio	1.0	3.5	1.8
Injection to scan time (target 180 min) (min)	211	182	175
[ <sup>18</sup> F]FDG			
SUV <sub>max</sub> nodal disease	NA	15	10
Clinical follow-up (months)	15	6	20

NA, not available; SUV<sub>max</sub>, maximum standardised uptake value.

event data ( $\leq 72$  h postadministration). Hospital admission systems were checked for unplanned attendances.

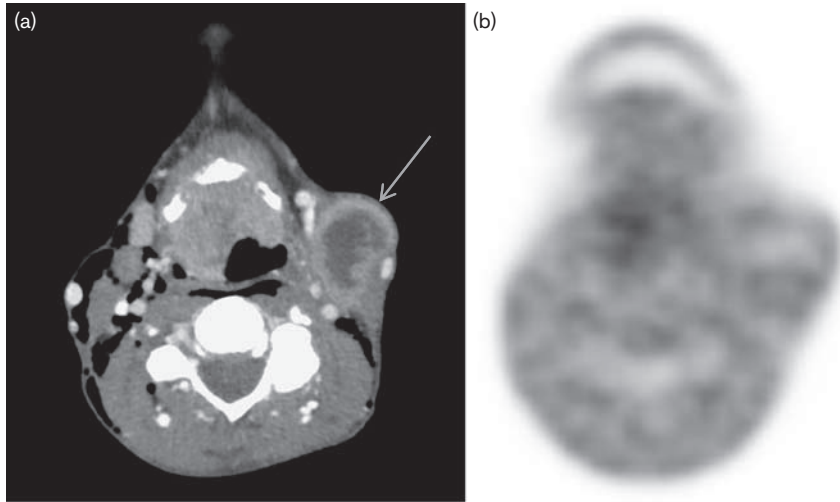
Image analysis was performed on a Hermes workstation. Maximum standardised uptake value (SUV<sub>max</sub>) of the most active site of tumour was recorded in addition to the mediastinal and hepatic SUV<sub>max</sub> values. The tumour to mediastinal activity ratio was calculated. In each patient, the volume of the recorded tumour site was measured from the staging contrast-enhanced CT scan. Due to the exploratory nature of this study, hypoxia-guided treatment modifications based on the [<sup>18</sup>F]HX4 PET/CT results were not permitted in the Protocol.

## Results

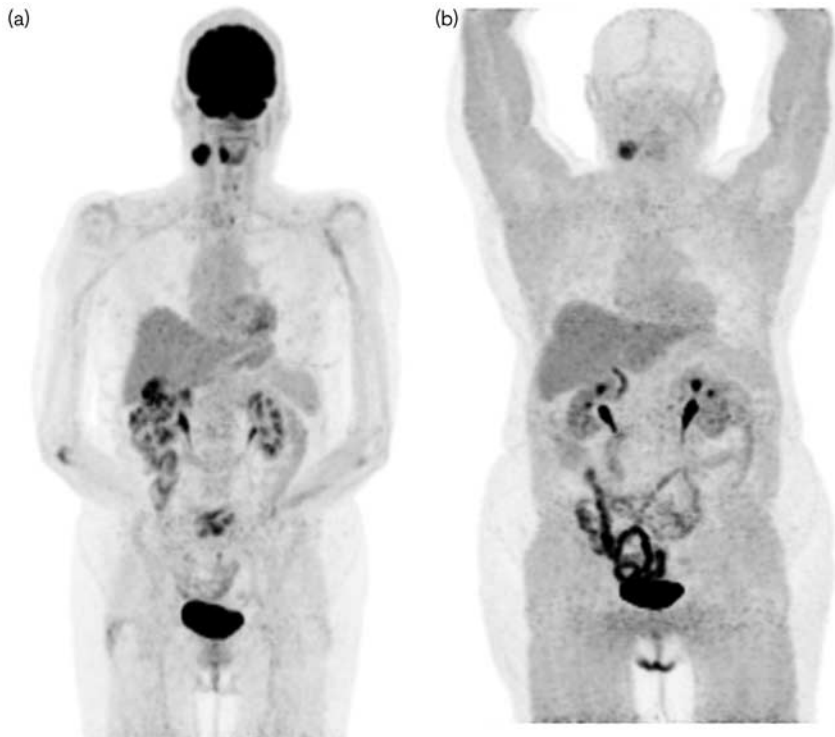
All patients underwent [<sup>18</sup>F]HX4 PET/CT scanning without adverse events. The uptake period ranged from 175 to 211 min. Patient characteristics and [<sup>18</sup>F]HX4 SUV<sub>max</sub> measurements are presented in Table 1.

In line with previous reports, and in contrast with the [<sup>18</sup>F]FDG scans, [<sup>18</sup>F]HX4 had low uptake in the brain (Figs 1–4) and myocardium (Figs 2 and 3) [12]. Excretion was primarily through the urinary bladder. In one patient [<sup>18</sup>F]HX4 uptake was observed in the gall bladder, indicating some biliary excretion of the radiotracer (Fig. 3b).

Patient 1 demonstrated a large nodal mass in the left neck at the staging CT scan. This might have been expected to be hypoxic due to disorganised internal vasculature (as manifested by the heterogeneous contrast enhancement) but the mass was negative for hypoxia by [<sup>18</sup>F]HX4 PET, with

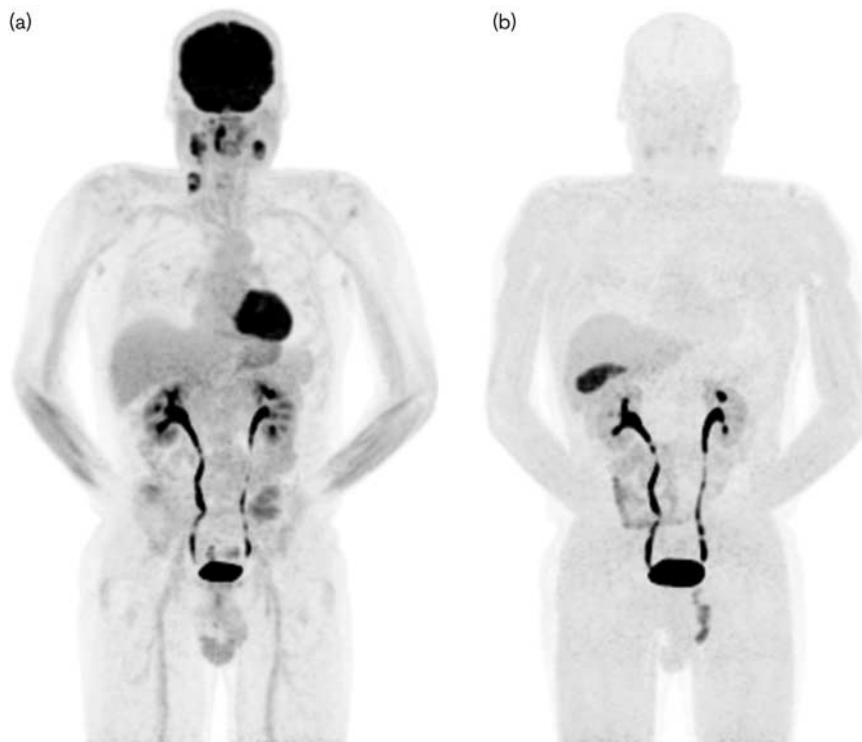
**Fig. 1**

(a) Axial contrast-enhanced computed tomography scan of Patient 1 at diagnosis. A large tumour mass in the anterior oropharynx was observed which extended from a primary lesion in the tongue base. There was a large left neck nodal mass with internal low attenuation and peripheral enhancement (arrow), thought to represent necrosis. Air in the soft tissues is iatrogenic following an emergency tracheostomy to relieve airway obstruction by the tumour. (b) Axial [<sup>18</sup>F]HX4 PET image at the same level shows no particular accumulation of activity above background tissues. A photopenic region was noted in the anterior aspect of the mass which could be due to nonperfused necrotic tissue.

**Fig. 2**

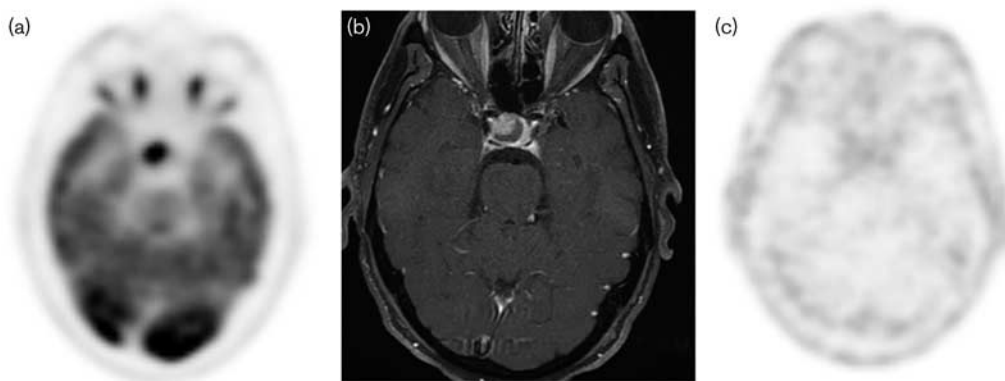(a) Maximum intensity projection (MIP) image of pretreatment [<sup>18</sup>F]FDG PET scan of Patient 2. Increased activity was observed in the right oropharyngeal primary tumour and right neck nodal mass. (b) [<sup>18</sup>F]HX4 PET MIP, showing marked accumulation of radiotracer in the right neck lymph nodal mass, in keeping with a localised area of hypoxia. There was no significant accumulation of [<sup>18</sup>F]HX4 in the primary tumour.

Fig. 3



(a) Maximum intensity projection (MIP) of pretreatment [<sup>18</sup>F]FDG PET scan in Patient 3. Markedly increased activity was observed in the right oropharyngeal primary tumour and extensive bilateral neck lymphadenopathy. (b) [<sup>18</sup>F]HX4 PET MIP in Patient 3, showing low-grade activity at these sites.

Fig. 4



(a) Axial [<sup>18</sup>F]FDG PET; (b) contrast-enhanced T1-weighted MRI scan; (c) [<sup>18</sup>F]HX4 PET in Patient 3. In the pretreatment [<sup>18</sup>F]FDG staging scan, a focal area of uptake was found in the sellar region. MRI showed appearances much more in keeping with an incidental pituitary macroadenoma than tumour spread to the cavernous sinus. [<sup>18</sup>F]HX4 imaging showed no significant uptake in this position. After 20 months of clinical follow-up the patient had not developed any neurological symptoms, suggesting that the diagnosis was correct.

a tumour to mediastinum  $SUV_{max}$  ratio of 1 (Fig. 1 and Table 1). This patient demonstrated a photopenic region in the anterior aspect of the mass which might have been due to necrosis. It should be noted that 2-nitroimidazole radiotracers are not retained in regions of necrosis as they require

active reductase enzymes to activate the hypoxia trapping mechanism [13]. While necrotic-hypoxic regions can therefore, give rise to false negative scans for hypoxia, the ability to differentiate viable-hypoxic from necrotic-hypoxic cells is considered an advantage for this class of radiotracer [13].

The [<sup>18</sup>F]HX4 scan for Patient 2 was clearly positive for hypoxia with a tumour to mediastinal SUV<sub>max</sub> ratio of 3.5 (Fig. 2b and Table 1). The patient had an oropharyngeal primary tumour and right jugular nodal mass clearly visible on the [<sup>18</sup>F]FDG PET scan. Only the nodal mass showed significant [<sup>18</sup>F]HX4 uptake which was heterogeneous. This scan exemplifies how hypoxia may not be uniformly distributed throughout a tumour and consequently it may be beneficial to tailor treatment to different sites of disease within the same patient.

Patient 3 showed [<sup>18</sup>F]HX4 uptake of intermediate intensity (Fig. 3b). Visual assessment was more subjective in this case because selective windowing could make the lesion appear clearly positive or negative. The tumour to mediastinal ratio was 1.8 which other studies of [<sup>18</sup>F]HX4 have interpreted as positive for hypoxia [9,14–16]. Patient 3 was incidentally noted to have a metabolically active mass in the sellar region by [<sup>18</sup>F]FDG PET. Initially, this was feared to be tumour spread into the cavernous sinus. However, MRI examination showed a pituitary mass in keeping with a macroadenoma (Fig. 4). On the [<sup>18</sup>F]HX4 scan this area was negative for hypoxia.

## Discussion

Diagnostic quality [<sup>18</sup>F]HX4 PET images were acquired 3 h after administration for all patients, although previous studies have indicated that contrast continues to improve up to 4 h after injection [17]. Limited capacity in the PET centre uptake rooms prevented us from scanning more than one [<sup>18</sup>F]HX4 patient per day. A 3 h, rather than 4 h uptake period thus helped to maintain capacity for routine PET scans. In the future, when additional safety data is available it may not be necessary for patients to wait in the PET centre during the [<sup>18</sup>F]HX4 uptake period, which would facilitate routine use.

It was a practical challenge to scan participants with [<sup>18</sup>F]HX4 in the short window between completion of staging and start of their treatment. These patients were often emaciated at diagnosis and had a rapidly deteriorating clinical condition, and it was imperative to begin treatment urgently. In preparation for chemoradiotherapy, patients had a busy schedule of priority appointments which included dental examination and gastrostomy placement, which are routine for HNSCC patients in our institution. Competing demands at the cyclotron and radiosynthesis facility presented a further limitation, meaning [<sup>18</sup>F]HX4 was not available daily. Combined, these constraints resulted in five out of eight consented patients being unable to participate.

Despite the limited size of the study, the findings show how [<sup>18</sup>F]HX4 uptake was variable between three patients with histologically similar HNSCC, and heterogeneous between disease sites within the same patient. These observations highlight a key benefit of whole disease

hypoxia evaluation by PET compared with single site sampling methods. Advances in genomic tumour analysis are providing new ways to characterise tumours, including their hypoxia signatures [18–20] however these techniques cannot provide the same comprehensive oxygenation map between sites of disease within the same patient.

Further work is needed to establish the clinical impact of [<sup>18</sup>F]HX4 imaging in patients with HNSCC. Routine evaluation of tumour hypoxia is only likely to happen when complementary hypoxia-modified treatment schedules demonstrate a significant survival advantage. Hypoxia imaging has a role to play in stratifying patients for clinical trials of these treatments.

## Conclusion

This article describes the first clinical study of [<sup>18</sup>F]HX4 based in the UK. [<sup>18</sup>F]HX4 imaging identified a spectrum of hypoxia in patients with HNSCC. Routine hypoxia imaging in HNSCC treatment planning would require investment, efficient scheduling, and a flexible radiotracer supply. Until a clinically significant therapeutic modification is validated and adopted for treating hypoxic lesions, it seems likely that radiotracers for hypoxia including [<sup>18</sup>F]HX4 will remain a research tool.

## Acknowledgements

The authors thank the study participants for their generosity and willingness to take part in the project. They also acknowledge Dr S. Morgan, Dr C.P. Esler, Professor P.M. Patel, Dr J.D. Birchall, Dr R.H. Ganatra and K. Leach for helpful discussions and support of the trial. We acknowledge Nottingham University Hospitals National Health Service Trust Research and Innovation Department for acting as Sponsor, and in particular the contributions of Dr N. McGregor and H. Driver to study set up.

This study was funded by Nottingham Hospitals Charity. The authors acknowledge Threshold Pharmaceuticals for provision of precursor and reference material for HX4, PETNET Nottingham for manufacture of [<sup>18</sup>F]HX4 and Nottingham In Health for PET/CT scanning. Threshold Pharmaceuticals and Siemens Healthcare provided the Investigator Brochure.

## Conflicts of interest

There are no conflicts of interest.

## References

- 1 Kelly JR, Park HS, An Y, Contessa JN, Yarbrough WG, Burtness BA, *et al.* Comparison of survival outcomes among human papillomavirus-negative cT1-2 N1-2b patients with oropharyngeal squamous cell cancer treated with upfront surgery vs definitive chemoradiation therapy: an observational study. *JAMA Oncol* 2017; **3**:1107–1111.
- 2 Nordmark M, Bentzen SM, Rudat V, Brizel D, Lartigau E, Stadler P, *et al.* Prognostic value of tumor oxygenation in 397 head and neck tumors after primary radiation therapy. An international multi-center study. *Radiother Oncol* 2005; **77**:18–24.
- 3 Gray LH, Conger AD, Ebert M, Hornsey S, Scott OC. The concentration of oxygen dissolved in tissues at the time of irradiation as a factor in radiotherapy. *Br J Radiol* 1953; **26**:638–648.

- 4 Bredell MG, Ernst J, El-Kochairi I, Dahlem Y, Ikenberg K, Schumann DM. Current relevance of hypoxia in head and neck cancer. *Oncotarget* 2016; **7**:50781–50804.
- 5 Mistry IN, Thomas M, Calder EDD, Conway SJ, Hammond EM. Clinical advances of hypoxia-activated prodrugs in combination with radiation therapy. *Int J Radiat Oncol Biol Phys* 2017; **98**:1183–1196.
- 6 Troost EGC, Koi L, Yaromina A, Krause M. Therapeutic options to overcome tumor hypoxia in radiation oncology. *Clin Transl Imaging* 2017; **5**:455–464.
- 7 Horsman MR, Sasko Mortensen L, Petersen JB, Busk M, Overgaard J. Imaging hypoxia to improve radiotherapy outcome. *Nat Rev Clin Oncol* 2012; **9**:674–687.
- 8 Evans CE, Mattock K, Humphries J, Saha P, Ahmad A, Waltham M, et al. Techniques of assessing hypoxia at the bench and bedside. *Angiogenesis* 2011; **14**:119–124.
- 9 Chen L, Zhang Z, Kolb HC, Walsh JC, Zhang J, Guan Y. 18F-HX4 hypoxia imaging with PET/CT in head and neck cancer: a comparison with 18F-FMISO. *Nucl Med Commun* 2012; **33**:1096–1102.
- 10 Dubois LJ, Lieuwes NG, Janssen MHN, Peeters WJ, Windhorst AD, Walsh JC, et al. Preclinical evaluation and validation of [<sup>18</sup>F]HX4, a promising hypoxia marker for PET imaging. *Proc Natl Acad Sci USA* 2011; **108**:14620–14625.
- 11 Turton DR, Betts HM, Dutton D, Perkins AC. Automated radiosynthesis of GMP quality [<sup>18</sup>F]HX4 for PET imaging of hypoxia. *Nucl Med Biol* 2015; **42**:494–498.
- 12 Doss M, Zhang JJ, Bélanger M-J, Stubbs JB, Hostetler ED, Alpaugh RK, et al. Biodistribution and radiation dosimetry of the hypoxia marker 18F-HX4 in monkeys and humans determined from whole-body PET/CT. *Nucl Med Commun* 2010; **31**:1016–1024.
- 13 Fleming IN, Manavaki R, Blower PJ, West C, Williams KJ, Harris AL, et al. Imaging tumour hypoxia with positron emission tomography. *Br J Cancer* 2015; **112**:238–250.
- 14 Zegers CM, van Elmpt W, Wierts R, Reymen B, Sharifi H, Öllers MC, et al. Hypoxia imaging with [<sup>18</sup>F]HX4 PET in NSCLC: defining optimal imaging parameters. *Radiother Oncol* 2013; **109**:58–64.
- 15 Zegers CM, van Elmpt W, Szardenings K, Kolb H, Waxman A, Subramaniam RM, et al. Repeatability of hypoxia PET imaging using [<sup>18</sup>F]HX4 in lung and head and neck cancer patients: a prospective multicenter trial. *Eur J Nucl Med Mol Imaging* 2015; **42**:1840–1849.
- 16 Zegers CM, van Elmpt W, Hoebbers FJ, Troost EG, Öllers MC, Mottaghy FM, et al. Imaging of tumour hypoxia and metabolism in patients with head and neck squamous cell carcinoma. *Acta Oncol* 2015; **54**:1378–1384.
- 17 Zegers CM, Hoebbers FJ, van Elmpt W, Bons JA, Öllers MC, Troost EG, et al. Evaluation of tumour hypoxia during radiotherapy using [<sup>18</sup>F]HX4 PET imaging and blood biomarkers in patients with head and neck cancer. *Eur J Nucl Med Mol Imaging* 2016; **43**:2139–2146.
- 18 The Cancer Genome Atlas Network. Comprehensive genomic characterization of head and neck squamous cell carcinomas. *Nature* 2015; **517**:576–582.
- 19 Perakis S, Speicher MR. Emerging concepts in liquid biopsies. *BMC Med* 2017; **15**:75.
- 20 Caudell JJ, Torres-Roca JF, Gillies RJ, Enderling H, Kim S, Rishi A, et al. The future of personalised radiotherapy for head and neck cancer. *Lancet Oncol* 2017; **18**:e266–e273.