

EFFECT OF STRESS ON PRESENCE OF DEVELOPING NEPHRONS OF COMMON CARP REARED IN SEMIINTENSIVE SYSTEM

BOŽIDAR RAŠKOVIĆ¹, DALIBOR VUKOJEVIĆ¹, MILAN SPASIĆ¹, IVANA ŽIVIĆ², MARKO STANKOVIĆ¹, ZORAN MARKOVIĆ¹, VESNA POLEKSIĆ¹

¹University of Belgrade, Faculty of Agriculture, Nemanjina 6, 11080 Belgrade, Serbia

²University of Belgrade, Faculty of Biology, Studentski trg 16, 11000 Belgrade, Serbia

EFEKAT STRESA NA REGENERACIJU NEFRONA ŠARANA GAJENOG U POLUINTENZIVNOM SISTEMU

Apstrakt

Regenerišući nefroni (RN) u bubregu se često koriste kao indikator zdravstvenog stanja riba. U ovom radu je evaluiran efekat stresa koji šarani doživljavaju na početku sezone gajenja na bubregu koristeći broj RN. Ribe su hranjene različitim tipovima do-date hrane i gajene tokom dve sezone u vodi različitog kvaliteta, ali nijedan od ovih faktora nije uticao na pojavu RN. Međutim, ukoliko se prati vremenski tok sezone gajenja, broj RN se smanjuje. Njihov broj je najviši u maju i junu, dok na kraju sezone gajenja uopšte nisu bili prisutni u bubregu riba.

Ključne reči: histologija, regenerišući nefroni, šaran, indikatori

Keywords: histology, developing nephrons, common carp, indicators

INTRODUCTION

Handling and transport of fish is a risk for their health. At the start of the growing season, in semiintensive system, fish is either transported to fish farm or from winter pond to rearing pond. These activities are source of stress to fish (Iversen et al., 1998; Acerete et al., 2004). Effects of these activities and stress intensity could be monitored using different methods: biochemistry, gene expression, or histology. While biochemical parameters and gene expression are methods of choice in short-term monitoring, histology is important for long-term monitoring of fish health. Frequently used histological changes in kidney, after stress period, include presence of necrosis, eosinophilic granule cells, rodlet cells, neoplasia, and increased number of melanomacrophage centers. Aim of this manuscript is to evaluate presence of developing nephrons (DN) in common carp

(*Cyprinus carpio* L., 1758) during growing season, after experiencing stress at the start of the growing season.

MATERIALS AND METHODS

Detailed experimental design is already published elsewhere (Rašković et al., 2011; Rašković et al., 2013). Briefly, at the start of the growing season fish is transported from fish farm Neuzina to the Center for Fishery and Applied Hydrobiology in a plastic bags, filled with oxygen. Distance from fish farm to CEFAH is 95 km, while the trip lasted 90 minutes. After a one-month period of adaptation to new ponds, fish were placed in three earthen ponds, each measuring (L x W) 36 x 25 m. Different water supply was applied each of the two study years: in first year (Y1), water supply was from the nearby stream, while in second year (Y2) water from a tube well, 125 m deep, was used. In each of the three ponds, fish were fed with feed supplements: raw cereals (CF; 1:1:1 ratio mixture of wheat, corn and barley grains), pelleted (PF) and extruded (EF) compound feed. Water quality parameters were measured regularly and their values are reported in Rašković et al. (2013). From each of the ponds, three fish were sampled each month and five at the end of experiment, a total of 20 fish per pond. Specimens were sacrificed with a quick blow to the head, and kidney samples were quickly removed, fixed in 4% formaldehyde, and processed using a standard histological technique: dehydration in an ethanol series, embedding in paraffin, and serially sectioning at 5mm. Sections were stained with hematoxylin and eosin (H/E) (Humason, 1979). Microphotographs were taken with a Leica DM LS microscope with the Leica DC 300 camera. Scoring system proposed by Bernet et al. (1999) was applied for the assessment of appearance of DN. Minimum values of appearance were 0, while maximum were 6. Comparisons of number of regenerative nephrons between ponds were performed by non-parametric Kruskal-Wallis test. The difference between years was compared using Mann-Whitney U test.

RESULTS

DN are easily distinguished from normal nephrons in fish kidney (**Figure 1a** and **1b**). The main characteristic of developing tubules and glomeruli were intensive basophilic staining and smaller dimensions compared to normal nephrons. Beside basophilia, developing cells have large and euchromatic nuclei (**Figure 1b**).

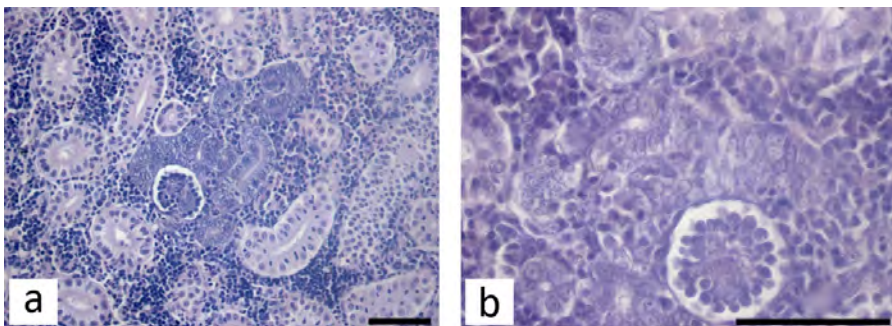


Figure 1. Developing tubules and glomerulus; a) H/E x400; b) H/E x1000; bar = 50 μm

Number of DN was higher during the first year of experiment, but that difference was not significant ($p=0.210$; **Figure 2**). Their number was not different between groups, neither in first year of experiment ($p=0.871$), nor in the second year of experiment ($p=0.422$).

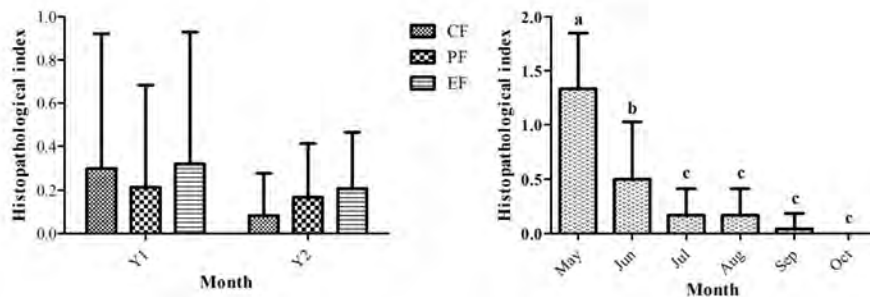


Figure 2 (left). DN number during Y1 and Y2 in different feeding groups; **Figure 3 (right).** Frequency of developing nephrons during both growing seasons; different letters denounce significant difference between months ($P < 0.05$) ($p < 0.05$)

The presence of DN was higher during first two months of the growing season ($p < 0.05$; **Figure 3**), with values reported in May higher than those in June ($P < 0.05$). This trend was characteristic for both years in all three feeding groups. During last month of experiment presence of DN was not observed.

DISCUSSION

In this study the presence of DN was confirmed at the start of experiment. Fish kidney has an ability of a new nephron development throughout life, in contrast to mammals, although they are more frequently present in young fish (Reimschuessel, 2001). DN are good markers of chronic toxicity, because time for their full development is estimated to 9 weeks (Salice et al., 2001). The presence of DN is reported in fish recovery from application of gentamicin (Watanabe et al., 2009), and in polluted freshwater ecosystems (Camargo and Martinez, 2007; Lukin et al., 2011). Increased number of DN found during first two months of the growing season in both study years point at probable effect of stress during fish transport. Lower number of DN in subsequent months confirms acceptable water quality for common carp culture. We also confirmed that different water supply and different feed applied do not influence kidney regeneration in fish, in contrast to other histopathological changes observed in this study (Rašković et al., 2013).

ACKNOWLEDGEMENTS

The present study was supported by the Serbian Ministry of Education, Science and Technological Development (project No. TR 31075).

REFERENCES

Acerete, L., Balasch, J.C., Espinosa, E., Josa, A., Tort, L. (2004): Physiological responses in Eurasian perch (*Perca fluviatilis*, L.) subjected to stress by transport and handling. *Aquaculture*, 237, 167-178.

Bernet, D., Schmidt, H., Meier, W., Burkhardt-Holm, P., Wahli, T. (1999). Histopathology in fish: proposal for a protocol to assess aquatic pollution. *Journal of Fish Diseases*, 22: 25-34.

Camargo, M.M.P., Martinez, C.B.R. (2007): Histopathology of gills, kidney and liver of a Neotropical fish caged in an urban stream. *Neotropical Ichthyology*, 5, 327-336.

Humason, G.L. (1979): *Animal tissue techniques*. W.H. Freeman. San Francisco. 661 pp.

Iversen, M., Finstad, B., Nilssen, K.J. (1998): Recovery from loading and transport stress in Atlantic salmon (*Salmo salar* L.) smolts. *Aquaculture*, 168, 387-394.

Lukin, A., Sharova, J., Belicheva, L., Camus, L. (2011): Assessment of fish health status in the Pechora River: Effects of contamination. *Ecotoxicology and Environmental Safety*, 74, 355-365.

Rašković, B., Ćirić, M., Dulić, Z., Grubišić, M., Spasić, M., Koko, V., Poleksić, V. (2011): Morphometrical study of intestinal folds of carp fed different added feed in semi-intensive system. V International Conference "Aquaculture & Fishery", Conference Proceedings, 491-496.

Rašković, B., Jarić I., Koko, V., Spasić M., Dulić, Z., Marković, Z., Poleksić, V. (2013): Histopathological indicators: a useful fish health monitoring tool in common carp (*Cyprinus carpio* Linnaeus, 1758) aquaculture. *Central European Journal of Biology* (*in press*)

Reimschuessel, R. (2001): A fish model of renal regeneration and development. *ILAR Journal*, 42, 285-291.

Salice, C.J., Rokous, J.S., Kane, A.S., Reimschuessel, R. (2001): New nephron development in goldfish (*Carassius auratus*) kidneys following repeated gentamicin-induced nephrotoxicosis. *Comparative Medicine*, 51, 56-59.

Watanabe, N., Kato, M., Suzuki, N., Inoue, C., Fedorova, S., Hashimoto, H., Maruyama, S., Matsuo, S., Wakamatsu, Y. (2009): Kidney regeneration through nephron neogenesis in medaka. *Development, Growth and Differentiation*, 51, 135-143.