

## **DETERMINATION OF VHS VIRUS TITER IN EXPERIMENTALLY INFECTED RAINBOW TROUT, *ONCORHYNCHUS MYKISS***

GHIASI, F. RIZBANDI, T.

*Department of Fisheries Sciences, Faculty of Natural Resources,  
University of Kurdistan, Sanandaj, 416, Iran*

### **ODREĐIVANJE TITRA VIRUSA VHS U EKSPERIMENTALNO INFICIRANIM PASTRMKAMA, *ONCORHYNCHUS MYKISS***

#### *Apstrakt*

U radu se opisuje infekcija različitih tkiva kalifornijske pastrmke virusnom hemoragične septikemije i poređenje titra VHS virusa u različitim tkivima inficirane pastrmke u cilju određivanja najboljeg organa za izolaciju virusa i identifikaciju faze bolesti. Rezultati pokazuju da je mozak dobar organ za izolaciju VHS virusa u fazi bolesti kao i tokom inkubacije i da je značajan koliko i bubrezi i srce za detekciju virusa. Srce i bubrezi su organi koji su imali najviši titar virusa, jetra, škrge, pilorus i koža najmanji, dok su mozak i slezina između te dve grupe.

*Ključne reči: VHS virus, virus titar, kalifornijska pastrmka, *Oncorhynchus mykiss*  
Keywords: VHS virus, virus titer, rainbow trout, *Oncorhynchus mykiss**

#### **INTRODUCTION**

Viral haemorrhagic septicaemia (VHS) is a serious viral disease affecting a range of fish species (Wolf, 1988). The organs affected during an infection with both VHS and IHN viruses are usually kidney and spleen, though most organs and tissues are affected in later stages of the disease. Hematopoietic tissue in kidney and white pulp of the spleen are the most frequently tissues affected, but there are cases in which the virus was isolated from the brain only (Yasutak & Amend, 1972; Kinkelin et al., 1979; Wolf, 1988). Leukocytes and endothelial cells are anticipated to be important sites for virus replication (Yamamoto et al., 1989; Yamamoto & Clermont, 1990). It has been demonstrated that VHS virus effectively infects by waterborne challenge. Both gills and intestine are suggested as a primary site of infection (Neukirch, 1986; Yamamoto et al., 1989). Yamamoto et al. (1992) showed that epithelial cells from skin and gills are capable of supporting

early VHS virus and IHN virus replication. Kidney and spleen have the highest titers in the acute or chronic phase. Brain should also be sampled in fish in the convalescent stage (Noga, 1996). Kidney and spleen are the organs recommended for isolation of VHS virus from epizootic specimens. Brain is suggested if survivors are to be assayed (Wolf, 1988). A confirmed diagnosis of VHS can be made only by isolating and serologically identifying the causative virus in an appropriate cell culture system (Jørgensen 1974). Most of the studies referred that immunohistochemical techniques reveal fewer positive samples than virus cultivation. Cultivation is more sensitive than immuno-histochemistry for detection of VHS virus (Øystein et.al 1994). **The purpose of the present investigation was to compare VHS virus titer in different tissues in experimentally infected rainbow trout in order to find the best organ for virus isolation and identification in disease phase of viral haemorrhagic septicemia in rainbow trout.**

## MATERIALS AND METHODS

140 apparently healthy fish average weight 75 g were collected from a local rainbow trout farm. The farm is approved VHS, IHN and IPN free. During the study the fish were fed once daily with commercial feed. The fish were divided in to two equal groups (I, II) in 120 liter tanks supplied with dechlorinated tap water. The water temperature was  $10 \pm 2$  °C. Tanks were aerated to maintain sufficient  $O_2$  concentration during infection.

A VHS virus isolate (DK – 3592 B) with two passage in BF-2 cells, serologically similar to the reference strain  $F_1$  and with proven high pathogenicity in rainbow trout was used.

Isolation of VHS virus in cultures of a number of fish cell lines is well documented by Olesen and Jørgensen (1992), Lorenzen et al. (1999). The fish cell line BF-2 and RTG-2 are recommended. Alternatively, EPC or FHM cells may be used, but are in general less susceptible than BF-2 and RTG-2.

The access infection was through a room with in and out path. Group II, containing 70 fish, was infected by bathing in the concentration of  $10^{-3}$  TCID<sub>50</sub> VHSV ml<sup>-1</sup> of water. 0.5 ml of virus suspension was mixed with 49.5 ml of Eagle's medium without fetal calf serum and added to a tank with no water renewal for two hours at 12°C to achieve desired virus concentration per ml in the tank. Fish from group I, considered as control, were exposed to an equal volume (50 ml) of virus free medium and handled as the infected fish. Before the water was discharged from the facility, it received a heat treatment in a pasteurization unit at 120°C during 2 minutes. Shoes and laboratory coats were changed before entering to the fish laboratory. Disposable gloves were worn during the work. Dead fish were removed daily from each tank. The number of dead fish and clinical signs of VHS were recorded every day. One week after the mortality initiation, at the days 12, 13 and 14 post infection, dead fish were collected. They were opened aseptically and 0.1g of each organ including brain, gills, heart, kidneys, liver, pyloric caeca, spleen and skin from five fish were measured and placed in 8 eppendorf tubes (8 pool), diluted to a ratio of 1:10 in a dilution medium. Samples were homogenized with the tissue mixer, treated with Gentamicin and stored in refrigerator 4°C over night. Half of samples were used for virus titration and remaining was stored in -20°C for virological examinations. During the sampling a piece of aluminum foil, new gloves and a new sterile pair of scissors have been used for every new sample to avoid contamination.

Samples were diluted in a dilution plate from  $10^{-1}$  -  $10^{-4}$  and subsequently added to the 24-hour old monolayer of BF- 2 cell line. The inoculated tissue culture plates were

incubates at 15°C and monitored for viral cytopathic effect (CPE). When CPE was completed, virus titers were calculated in different organ (Tab 1). Tubes were placed in cold tap water and when thawed. 100µl from each tissue was collected in a eppendorf tube and inoculated on BF-2 cell in 24-well plate as described previously (Mortensen et al. 1999). The 8 fold dilution from undiluted to 10<sup>-7</sup> were incubated at 15°C and inspected regularly with microscope for the occurrence of cytopathic effect (CPE). When CPE was evident, supernatants were tested by *ELISA to confirm the presence of VHS virus*.

The ELISA test used to detect VHS virus was performed according to general principles of direct ELISA described by (Olesen & Jørgensen 1991). Virus is trapped by rabbit anti-VHSV antiserum which is coated on to the wells of an ELISA plate. The virus is identified by a monoclonal antibody against the VHSV N- protein (Mab IP5B11) coupled to the biotine / streptavidine - horseradish peroxidase system. Culture media from cells cultures showing evidence of CPE were analyzed with direct ELISA.

#### *Statistical analyses*

Significant difference between the data obtain from tissues were analyzed using Duncan mean comparing test. The data were significant at  $p \leq 0.05$ .

## **RESULTS**

No mortality or presence of virus was observed in the control fish group. 6 days following the challenge experiment mortality was reported. The number of dead fish at beginning was high but a decreasing in mortality was noticeable after five days. Few mortality cases were observed during day 11 to 21 with no death reported after that. The Elisa test confirmed that VHS virus was the cause of death in experimental fish. The clinical signs in dead fish were dark color, pettechial haemorrhages at thebase of the fin, peduncle, skeletal muscles, adipose tissues, anal region, swim bladder, eyes and brain and also hyperemia of kidneys and paleness in liver and gills. The present study revealed that there was a significant difference between the virus tropism in various organs ( $p \leq 5\%$ ). Heart and kidney showed the highest amount of virus, liver, gills, pyloric caeca and skin showed the lowest quantities while brain and spleen were in between (Table 1 and fig.1).

## **DISCUSSION**

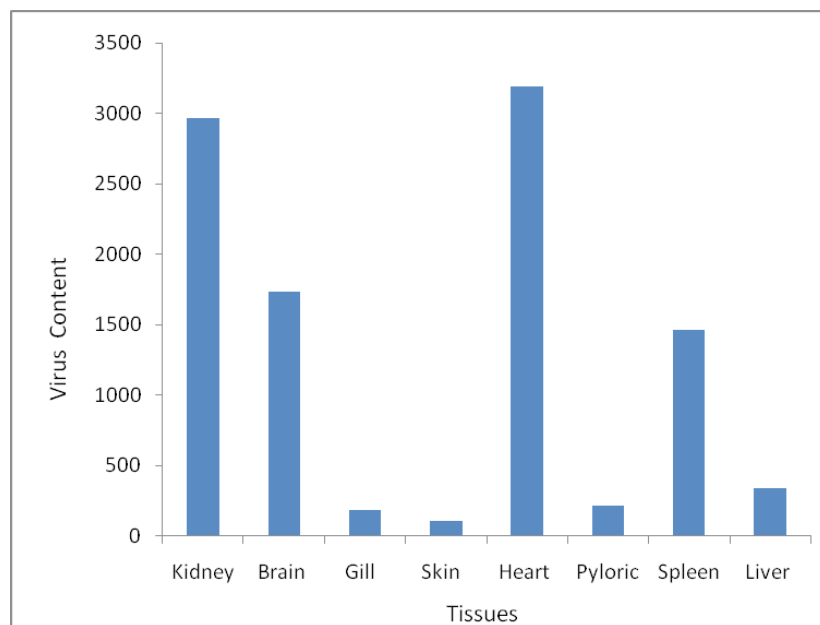
The titration results for each organ are summarized in Table 1. In the end stage of disease phase (12,13 and 14 d p.i.), virus was detectable in all samples but heart and kidney showed the highest viral titres. The present observation shows that brain samples are valuable for VHS virus isolation in disease phase and carrier stage. However, brain samples are almost equal to kidney and heart for virus detection (fig1). Previously brain was suggested as an organ for virus detection in convalescent phase of VHS disease by Wolf (1988) and Noga (1996). Our finding are in contrast with Øystein et al. (1994) who reported that virus is not detected in the brain section at any stage of the disease. The interaction of rhabdovirus with a cell depends on the presence of a receptor(s) molecule(s) on the cell and of a binding molecule (G) on the virion (Col, 1995).

The rate of virus titer about two weeks post infection was in the order kidney= heart > brain> spleen > liver > pyloric caeca > skin > gill (Table 1 and fig.1). The general opinion is that the gills are the prime portal of entry when virus is transmitted in water (Wolf 1988), although one report has focused on the epidermis and epidermal tissues as

a possible site for entry and early virus replication (Yamamoto et al. 1992). It seems that virus elimination in skin and gills is faster than in other organs but this still needs better characterization of virus target cell in VHSV virus infections and virus elimination during the disease and convalescence phase of viral haemorrhagic septicaemia.

**Table 1.** *Oncorhynchus mykiss*. TCID<sub>50</sub>/ml in different organs about 2 weeks after challenge by bathing in concentration 10<sup>-3</sup> TCID<sub>50</sub> VHSV ml<sup>-1</sup> of water

Organs Mean ± SD	Range of virus titers	
Heart	2.8-4.4	3.5 ± 0.86
Kidney	2.9-4.6	3.47±0.66
Brain	2.6-4.1	3.24±0.60
Spleen	2.4-3.9	3.17±1.07
Liver	1.4-3.1	2.54±0.67
Pyloric caeca	<1.3-2.9	2.33±0.73
Gill	1.3-2.8	2.27±1.01
Skin	<1.3-2.6	2.30±0.7



**Figure 1.** *Oncorhynchus mykiss*, Comparison of VHSV titer in different organs about 2 weeks after challenge by bathing in concentration 10<sup>-3</sup> TCID<sub>50</sub> VHSV ml<sup>-1</sup> of water.

## REFERENCES

- Coll, J.M., (1995): The glycoprotein G of rhabdoviruses. Arch virol. 140:627-851.
- Kinkelin, P., de Chilmoczyk, S.; Dorson, M.; le Berre, M.; Baudouy, A.M. (1979): Some pathogenic facets of rhabdoviral infection of salmonid fish. In: Symposium on Microbiology: Mechanisms of Viral Pathogenesis and Virulence (Bachman PA, Ed.),

pp. 357-375, WHO Collaborating Centre for Collection and Education of Data on Comparative Virology, Munich, Germany

Jensen, M.H., (1965): Research on the virus of Egtved disease. *Ann.N.Y.Acad. Sci.*126,422-426

Jørgensen, P. E. V. (1974): A study on viral diseases in Danish rainbow trout, their diagnosis and control. Ph.D. thesis, Royal Veterinary and Agricultural University, Copenhagen.

Lorenzen, E.; Carestensen, B. ; Olesen, N.J. (1999): Inter-laboratory comparison of cell line for susceptibility to three virus : VHSV, IHNV and IPNV. *Dis. Aquat. Org.* 37, 81-88

Neukirch, M. (1986): Demonstration of persistent viral haemorrhagic septicaemia (VHS) virus in rainbow trout after experimental waterborne infection. *J Vet Med.* 33:471-476

Noga, E.J.(1996): Fish disease diagnostic and treatment. ( Iowa state university press/Amsterdam ), pp. 214-215

Mortensen, H.F., Heuer O., Lorenzen N., Otte L. & Olesen N.J.(1999): Isolation of viral haemorrhagic septicaemia virus (VHS) from wild marine fish in the Baltic Sea, Kattegat, Skaggrak and the North the North Sea. *Virus Research* 63, 95-106.

Øystein E., Willy, M., Wahli T., Olesen, N.J., Jørgensen, P.E.V. & Hastein T.(1994): Comparison of immunohistochemistry and virus cultivation for detection of viral haemorrhagic septicaemia virus in experimentally infected rainbow trout *Oncorhynchus mykiss*. *Dis.aquat.org.*, 20,101-109.

Olesen, N.J. & Jørgensen, P.E.V. (1992): Comparative susceptibility of three fish cell lines to Egtved virus, the virus of haemorrhagic septicaemia (VHS). *Dis.Aquat.Org.*, 12, 235-237.

Olesen, N.J., Jørgensen, P.E.V. (1991): Rapid detection of viral haemorrhagic septicaemia virus in fish by ELISA. *J Appl Ichthyology* 7,185-186

Wolf, K. (1988): Viral hemorrhagic septicemia. *In: Fish Viruses and Fish Viral Diseases* (Cornell University Press, Ithaca, NY), pp.217-249

Wolf, K. (1988): Viral hemorrhagic septicemia. *In Fish Viruses and Fish Viral Diseases*. Edited by: Wolf K. Ithaca and London, Comstock Publishing Associates, Cornell University Press; 1988:217-249. .

Yamamoto, T., Batts, W.N., Winton, J.R.(1992): In vitro infection of salmonid epidermal tissues by infectious hematopoietic necrosis virus and viral hemorrhagic septicemia virus. *J Aquat Animal Health* 4:231-239

Yamamoto, T. & Clermont, T.J.(1990): Multiplication of infectious hematopoietic necrosis virus in rainbow trout following immersion infection: organ assay and electron microscopy. *J Aquat Animal Health* 2:261-270

Yamamoto, T., Batts, W.N., Arakawa, C.K. & Winton, JR (1989): Comparison of infectious hematopoietic necrosis in natural and experimental infections of spawning salmonids by infectivity and immunohistochemistry. *In: Vir Lower Vertebrates.* (ed. Ahne W, Kurstak E, Ed.), pp 411-429, Springer-Verlag, Heidelberg, Germany

Yasutake, W.T. & Amend, D.F. (1972): Some aspects of pathogenesis of infectious hematopoietic necrosis (IHN). *J Fish Biol* 4,261-264.