

Memory reorganization following anterior temporal lobe resection: a longitudinal functional MRI study

Silvia B. Bonelli,^{1,2,3} Pamela J. Thompson,^{1,2} Mahinda Yogarajah,^{1,2} Robert H. W. Powell,^{1,2} Rebecca S. Samson,^{1,2} Andrew W. McEvoy,⁴ Mark R. Symms,^{1,2} Matthias J. Koepp^{1,2} and John S. Duncan^{1,2}

1 Epilepsy Society MRI Unit, Epilepsy Society, Chalfont St Peter, SL9 0RJ, UK

2 Department of Clinical and Experimental Epilepsy, UCL Institute of Neurology, Queen Square, London WC1N 3BG, UK

3 Department of Neurology, Medical University of Vienna, Austria

4 Department of Neurosurgery, National Hospital for Neurology and Neurosurgery, Queen Square, London WC1N 3BG, UK

Correspondence to: Professor John S Duncan,
Department of Clinical and Experimental Epilepsy,
UCL Institute of Neurology,
Queen Square,
London,
WC1N 3BG, UK
E-mail: j.duncan@ucl.ac.uk

Anterior temporal lobe resection controls seizures in 50–60% of patients with intractable temporal lobe epilepsy but may impair memory function, typically verbal memory following left, and visual memory following right anterior temporal lobe resection. Functional reorganization can occur within the ipsilateral and contralateral hemispheres. We investigated the reorganization of memory function in patients with temporal lobe epilepsy before and after left or right anterior temporal lobe resection and the efficiency of postoperative memory networks. We studied 46 patients with unilateral medial temporal lobe epilepsy (25/26 left hippocampal sclerosis, 16/20 right hippocampal sclerosis) before and after anterior temporal lobe resection on a 3 T General Electric magnetic resonance imaging scanner. All subjects had neuropsychological testing and performed a functional magnetic resonance imaging memory encoding paradigm for words, pictures and faces, testing verbal and visual memory in a single scanning session, preoperatively and again 4 months after surgery. Event-related analysis revealed that patients with left temporal lobe epilepsy had greater activation in the left posterior medial temporal lobe when successfully encoding words postoperatively than preoperatively. Greater pre- than postoperative activation in the ipsilateral posterior medial temporal lobe for encoding words correlated with better verbal memory outcome after left anterior temporal lobe resection. In contrast, greater postoperative than preoperative activation in the ipsilateral posterior medial temporal lobe correlated with worse postoperative verbal memory performance. These postoperative effects were not observed for visual memory function after right anterior temporal lobe resection. Our findings provide evidence for effective preoperative reorganization of verbal memory function to the ipsilateral posterior medial temporal lobe due to the underlying disease, suggesting that it is the capacity of the posterior remnant of the ipsilateral hippocampus rather than the functional reserve of the contralateral hippocampus that is important for maintaining verbal memory function after anterior temporal lobe resection. Early postoperative reorganization to ipsilateral posterior or contralateral medial temporal lobe structures does not underpin better performance. Additionally our results suggest that visual memory function in right temporal lobe epilepsy is affected differently by right anterior temporal lobe resection than verbal memory in left temporal lobe epilepsy.

Received August 15, 2012. Revised February 27, 2013. Accepted March 3, 2013

© The Author (2013). Published by Oxford University Press on behalf of the Guarantors of Brain.

This is an Open Access article distributed under the terms of the Creative Commons Attribution Non-Commercial License (<http://creativecommons.org/licenses/by-nc/3.0/>), which permits non-commercial re-use, distribution, and reproduction in any medium, provided the original work is properly cited. For commercial re-use, please contact journals.permissions@oup.com

Keywords: temporal lobe epilepsy; functional MRI; verbal memory; visual memory; anterior temporal lobe resection

Abbreviations: ATR = anterior temporal lobe resection; TLE = temporal lobe epilepsy

Introduction

Anterior temporal lobe resection (ATLR) has proven a successful treatment for patients with medically intractable temporal lobe epilepsy (TLE) (Wiebe *et al.*, 2001) rendering 50–60% seizure-free at 10 years (de Tisi *et al.*, 2011). Neuropsychological follow-up studies, however, have shown that this procedure can be complicated by cognitive decline that is usually material specific to the side of resection; verbal memory decline typically occurs after left (Hermann *et al.*, 1995; Sabsevitz *et al.*, 2001; Gleissner *et al.*, 2002, 2004) and visual memory decline after right ATLR (Gleissner *et al.*, 1998; Lee *et al.*, 2002). Decline in verbal memory function has a greater impact on everyday memory functioning for individual patients, whereas a decline in visual memory is usually less relevant (Gleissner *et al.*, 2004).

Functional MRI allows evaluation of cognitive function non-invasively and has proven to be a useful tool to investigate underlying neural mechanisms. Many functional MRI studies in the past concentrated on preoperative memory processing and how this changes in the course of the underlying disease and in particular the prediction of postoperative deficits (Rabin *et al.*, 2004; Richardson *et al.*, 2004; Janszky *et al.*, 2005; Binder *et al.*, 2008; Bonelli *et al.*, 2010). Functional MRI may also be used to investigate the extent to which the brain may functionally reorganize following epilepsy surgery. Functional reorganization, pre- and post surgery, can occur within the unaffected ipsilateral or contralateral hemisphere, but under which circumstances reorganization becomes effective is poorly understood.

In a recent study we investigated verbal and visual memory function using a material-specific memory encoding paradigm before ATLR. We demonstrated that memory functional MRI was the strongest predictor of verbal and visual memory decline compared to other previously suggested predictors. Greater ipsilateral anterior medial temporal activation was associated with greater decline of verbal or visual memory function. We also found evidence that activation in the ipsilateral posterior medial temporal lobe, which is usually preserved during ATLR, was associated with better preservation of memory function after surgery (Bonelli *et al.*, 2010). There is increasing evidence that in patients with TLE, memory outcome depends on the extent of the removal of non-lesional functional tissues (Helmstaedter *et al.*, 2003, 2008; Alpherts *et al.*, 2008; Schramm, 2008). Postoperative functional MRI follow-up studies are needed to determine the role of the posterior hippocampal remnant in memory function. This could lead to re-evaluation of more selective surgery in order to optimize risks of postoperative memory impairment in addition to seizure control.

To date, there is only one functional MRI study apart from a few case studies (Korsnes *et al.*, 2009), in which memory function was systematically investigated before and after surgery. Postoperative memory function was assessed using a complex visual scene encoding task and was significantly associated with

functional activation contralateral to the side of resection in nine patients with left TLE and eight with right TLE and therefore suggested a role for the contralateral medial temporal lobe in supporting postoperative memory (Cheung *et al.*, 2009).

The present study represents the postoperative follow-up study of our preoperative series (Bonelli *et al.*, 2010). We used a material-specific memory encoding paradigm: (i) to investigate postoperative recovery and reorganization of successful verbal and visual memory encoding in patients with left and right TLE before and 4 months after ATLR; and (ii) to investigate the efficiency of postoperative memory networks.

Materials and methods

Subjects

We studied 46 patients with medically refractory TLE [26 left (14 females); median age 41.5 years, range 17–63; 20 right (13 females); median age 34.5 years, range 23–52]. All underwent left or right ATLR at the National Hospital for Neurology and Neurosurgery, London. Preoperatively, all patients had undergone detailed presurgical evaluation including structural MRI at 3 T with qualitative assessment and quantification of hippocampal volumes and T₂ relaxation times by expert neuroradiologists (Woermann *et al.*, 1998; Bartlett *et al.*, 2007), prolonged interictal and ictal video-EEG monitoring and standardized neuropsychological and psychiatric assessment. Structural MRI showed unilateral hippocampal sclerosis in 25 patients with left TLE and 16 patients with right TLE; one patient had a left and one patient a right medial dysembryoplastic neuroepithelial tumour, one had a right anterior temporal cavernoma, one had right anterior temporal focal cortical dysplasia and one patient showed a right anterior temporal ganglioglioma. All patients had normal contralateral medial temporal lobe structures on qualitative and quantitative MRI. Video-EEG confirmed ipsilateral seizure onset in all patients. All patients' first language was English; handedness was determined using a standardized questionnaire (Oldfield, 1971). All patients underwent language and memory functional MRI and standard neuropsychological assessment preoperatively and again 4 months after ATLR. Language dominance was assessed using a range of functional MRI tasks (Bonelli *et al.*, 2011) revealing left hemisphere dominance in 20 patients with left TLE and 13 patients with right TLE, and atypical (bilateral or right) language representation in six left and seven right patients with TLE. As described previously (Bonelli *et al.*, 2010), we additionally calculated pre- and postoperative lateralization indices for the contrast 'verbal fluency' using the Bootstrap method of the SPM toolbox (Wilke and Lidzba, 2007) for each subject in the middle and inferior frontal gyri, which were used as covariates for the second level analysis. Mean verbal IQ as measured using the Wechsler Adult Intelligence Scale–III was 91.62 (SD 13.4) in left TLE and 93.7 (SD 14.7) in right TLE. Mean performance IQ was 97.9 (SD 13.4) in left and 92.0 (SD 13.0) in right TLE. As memory may be affected by anxiety and depression, all patients in this study were tested for comorbid anxiety and depression preoperatively and again at the time of their postoperative assessment (4 months after ATLR) using the

Hospital Anxiety and Depression Scale (HADS) as a measure of self-reported symptoms of anxiety and depression (Zigmond and Snaitch, 1983).

The scale is a user-friendly, compact questionnaire comprising 14 items that assess current levels of anxiety and depression. The score is derived from responses on a four-point Likert-type scale. A score of 7 or above is considered positive. A clinically significant change was defined by a change in category; the different categories are defined as follows: normal (0–6), mild (7–10), moderate (11–13), severe (14 and above).

Preoperatively (data missing in two cases), there was no significant difference in anxiety scores between left and right TLE patients, but a significant difference in depression scores with patients with left TLE showing higher scores (anxiety median: left TLE, 7; range, 1–18; right TLE, 7.5; range, 4–15; depression median: left TLE, 5.5; range, 0–10; right TLE, 4.5; range, 0–15; $P = 0.03$). In right TLE, scores were within the pathological range in 11 patients for anxiety (eight mild, two moderate, one severe), and in two patients for depression (one mild, one moderate); in left TLE, scores were considered as positive in 13 patients for anxiety (five mild, five moderate, three severe) and eight patients for depression (eight mild).

Postoperatively, there was no significant difference in anxiety and depression scores between left and right TLE patients (anxiety median: left TLE, 6; range, 0–19; right TLE, 6.5; range, 0–16; depression median: left TLE, 3; range, 0–15; right TLE, 3; range, 0–13). In right TLE, postoperative scores were within the pathological range in 10 patients for anxiety (five mild, one moderate, four severe) and in five patients for depression (four mild, one severe); in left TLE, scores were considered as positive in 10 patients for anxiety (five mild, two moderate, three severe) and six patients for depression (five mild, one severe).

In right TLE there was no significant difference between pre- and postoperative anxiety or depression scores; in left TLE depression scores improved significantly after left ATLR compared to preoperatively (paired t -test; $P = 0.0023$), whereas there was no significant difference between pre- and postoperative anxiety scores.

There were no statistically significant correlations between pre- and postoperative anxiety or depression ratings and pre- and postoperative performance on verbal and visual memory tests (verbal learning and design learning) in left or right TLE patients and therefore pre- and postoperative anxiety and depression scores were not considered a factor in performance of verbal and visual memory tests in our patients and therefore not included as additional covariates.

All patients were treated with anti-epileptic medication, which mostly remained unchanged at the time of their postoperative assessment. The standard neurosurgical procedure was removal of the temporal pole, opening of the temporal horn, followed by *en bloc* resection of the hippocampus with a posterior resection margin at the mid brainstem level. Postoperative seizure outcome was classified according to the International League Against Epilepsy classification (Wieser *et al.*, 2001) showing a seizure outcome grade 1 or 2 in 21 patients with left and 14 with right TLE and a seizure outcome grade 3 to 5 in five patients with left and six patients with right TLE. Seizure outcome is given at 1 year following surgery for all subjects.

The study was approved by the National Hospital for Neurology and Neurosurgery and the Institute of Neurology Joint Research Ethics Committee, and written informed consent was obtained from all subjects.

Neuropsychological tests

As described previously (Bonelli *et al.*, 2010) two learning tests, one verbal and one visual, which have been demonstrated to be good

indicators of postoperative memory decline/performance (Baxendale *et al.*, 2006) were selected from our standard memory tests and were repeated 4 months after left or right ATLR.

In brief, subjects are read a list of 15 words five times during the verbal learning task and on each presentation they recall as many words as possible with the total number of correct words expressed as a percentage. Similarly, for the design learning test, patients are presented with a design five times with recall being tested after each presentation. Again, percentage of correct responses over the five trials was used as the measure of performance.

Patients completed neuropsychological tests before and 4 months after ATLR. Measures of change in verbal and design learning following surgery were calculated as postoperative – preoperative scores. Changes in scores and postoperative scores alone were correlated with pre- versus postoperative change in/ postoperative functional MRI activation patterns for left and right TLE patients. At the second level of analysis, patients were additionally divided into groups who suffered a clinically significant decline in verbal or visual memory using reliable change indices (Baxendale and Thompson, 2005). These were defined as a change of 16% for verbal learning and 28% change for design learning (90% confidence interval).

Magnetic resonance data acquisition

MRI data acquisition was the same for all pre- and postoperative MRI studies, which were performed on a 3 T General Electric Excite HD_x scanner. Standard imaging gradients with a maximum strength of 40 mT/m and slew rate 150 Tm/s were used. All data were acquired using an 8-channel array head coil for reception and the body coil for transmission. In addition to the functional MRI data, we acquired a high resolution echo planar image covering the whole brain with the following parameters for each subject: two shots, echo time 30 ms, repetition time 4500 ms, matrix 256 × 256, 88 contiguous 1.5 mm slices; the geometric distortions were matched by introducing an additional delay to increase the echo spacing (Boulby *et al.*, 2005).

For the functional MRI task, gradient-echo planar T_2^* -weighted images were acquired, providing blood oxygenation level-dependent contrast. Each volume comprised 44 contiguous 1.5 mm oblique axial slices through the temporal and frontal lobes, with a 24 cm field of view, 128 × 128 matrix and in-plane resolution of 1.88 × 1.88 mm. Echo time was 30 ms and repetition time 4.5 s. The field of view was positioned to cover the temporal lobe with the anterior–posterior axis aligned with the long axis of the hippocampus on sagittal views, and with the body of the hippocampus in the centre.

Memory functional magnetic resonance imaging paradigm and data analysis

Memory paradigm

In this postoperative follow-up study we applied the same memory paradigm as preoperatively (Bonelli *et al.*, 2010) using a parallel set of stimuli containing three different material types [Pictures (P), black and white nameable line drawn objects; Words (W), single concrete nouns; and Faces (F), partly black and white, partly coloured photographs unfamiliar to the subjects] in order to investigate postoperative verbal and visual memory encoding. In brief, a total of 210 stimuli were visually presented to the subjects during a single scanning session, one every 4 s in seven cycles. Each cycle consisted of a block of 10 pictures, 10 words and 10 faces (each lasting 40 s) followed by 20 s of crosshair fixation as a resting period. Subjects performed a deep encoding task which involved making a judgement on whether a

stimulus was pleasant or unpleasant in order to encourage stimulus encoding, but the response type was not used in any subsequent parts of the functional MRI analysis. Sixty minutes after scanning subjects performed a recognition test outside the scanner comprising three blocks, one for each of the three material types. During the recognition tests the 70 stimuli for each material type were randomly mixed with additional 35 foils each and presented in a manner identical to that used during scanning. Subjects were instructed to indicate whether they could remember seeing each stimulus during scanning (R response) or whether it was new (N response).

The 210 encoding stimuli that had been presented during scanning were then classified according to the responses made during the recognition test. A correct (R) response indicated the stimulus was subsequently remembered while an incorrect (N) response indicated the stimulus was subsequently forgotten. For each of the three stimulus types (P, W, F), R and N responses were identified, giving a total of six event types: PR, PF, WR, WF, FR and FF. These were then entered as regressors in the design matrix.

Data analysis

Imaging data were analysed using Statistical Parametric Mapping (SPM5) (Friston *et al.*, 1995) (Wellcome Trust Centre for Imaging Neuroscience; <http://www.fil.ion.ucl.ac.uk/spm>). The postoperative imaging time series of each subject was realigned using the mean image as a reference. Rigid body coregistration was used to coregister postoperative scans to the preoperative mean image; scans were then spatially normalized into standard space applying each subject's preoperative spatial normalization parameters to the subject's postoperative realigned and coregistered scans. Preoperatively, a scanner specific template created from 30 healthy control subjects, 15 patients with left and 15 patients with right hippocampal sclerosis was used for normalization. All scans were then smoothed with a Gaussian kernel of 10 mm full-width at half-maximum. Coregistration of postoperative scans was checked visually for each subject, three patients with unsatisfactory coregistration were excluded from further analysis.

Event-related analysis

To test for subsequent memory effects, an event-related analysis was used to compare encoding-related responses to individual stimuli that were subsequently remembered versus stimuli that were forgotten (Friston *et al.*, 1998; Mechelli *et al.*, 2003; Richardson *et al.*, 2004; Powell *et al.*, 2005; Seghier *et al.*, 2012). A two-level event-related random-effect analysis was employed. At the first level, for each subject trial-specific responses were modelled by convolving a delta function that indicated each event onset with the canonical haemodynamic response function to create regressors of interest, one for each of the six event types (PR, PF, WR, WF, FR and FF). Each subject's movement parameters were included as confounds and parameter estimates pertaining to the height of the haemodynamic response function for each regressor of interest were calculated for each voxel. Three contrast images were created for each subject corresponding to the subsequent memory effect for each material type (picture encoding defined by PR-PF, word encoding defined by WR-WF and face encoding defined by FR-FF). Recognition accuracy for each event type was calculated in all our patients as follows: Stimuli seen in the recognition test were classified as 'hits' (stimuli correctly remembered) and 'false alarms' (foils incorrectly tagged as remembered). Recognition accuracy was then calculated for each stimulus type as: hit rate minus false alarm rate. All subjects with rates of <20% or >80% for the two possible responses 'remembered' and 'forgotten' were not included in this study as there were not enough responses in the different

categories to ensure sufficient contrast. These contrast images were used for the second-level analysis.

At the second level of the random effects analysis, subjects were divided into two groups, patients with left and right TLE. Each subject's contrast images were entered into a second level one sample *t*-test, which modelled the group effect (left and right TLE patients, pre- and postoperatively) on the various contrasts. In order to test for correlations between areas of postoperative functional MRI activation and subjects' performance on postoperative verbal learning and design learning, simple and multiple regression analyses were performed over the whole brain. For each subject verbal learning and design learning scores were entered as covariates separately for patients with left TLE and patients with right TLE. Encoding pictures usually gave more bilateral activations and was not considered for further postoperative correlational analyses. The language lateralization index derived from postoperative language functional MRI was used as an additional covariate.

Difference image analysis

In order to investigate the relationship between pre- and postoperative change in memory functional MRI activation and change in scores for verbal and visual memory from before to 4 months after ATR, we created 'difference images' by subtracting the coregistered, normalized postoperative contrast images from the original preoperative contrast images and vice versa. The created images represent activation changes for each contrast, highlighting areas of greater/lesser pre- than postoperative activation for the contrasts 'word and face encoding' over the whole brain. At the second level of the random effects analysis, we looked for brain regions showing correlations between greater/lesser pre- than postoperative or post- than preoperative activation and change (postoperative minus preoperative) scores for verbal and visual memory after ATR.

Second level of analysis

At the second level we investigated: (i) effects of ATR on the functional anatomy of verbal and visual memory encoding by comparing pre- versus postoperative main effects in patients with left and patients with right TLE; and (ii) efficiency of reorganization of postoperative verbal and visual memory functions by correlating postoperative activations on encoding words and faces with postoperative verbal learning and design learning scores in patients with left and right TLE.

Unless otherwise stated we report all medial temporal lobe activations at a threshold of $P < 0.01$, corrected for multiple comparisons [family-wise error (FWE) in a small volume of interest]. In view of our *a priori* hypothesis we performed the small volume correction using a sphere of 10 mm diameter for the left and right hippocampi based on the group peak activation.

Results

Memory test

Verbal learning

The left TLE group had a significant reduction in verbal learning scores postoperatively (mean = 44.8, SD = 16.4) compared with preoperatively (mean = 56.4, SD = 10.3; $P < 0.0001$). No significant changes for verbal learning were observed for the right TLE group.

Design learning

There was no significant difference between pre- and postoperative design learning scores in patients with right TLE or patients with left TLE.

Postoperative memory change

Twenty-two of 26 patients with left TLE had a decline in verbal learning scores after left ATLR, in seven this was classified as clinically significant; 3 of 26 patients had a postoperative improvement in verbal learning, one patient's score remained unchanged; the mean change between pre- and postoperative verbal learning scores was -9 , ranging from -48 to $+10$.

Ten of 20 patients with right TLE showed a decline in design learning scores after right ATLR, in one patient this was classified as clinically significant; 10 of 20 patients' design learning scores improved; the mean change between pre- and postoperative design learning scores was $+0.5$, ranging from -38 to $+26$.

Hippocampal volumes

Preoperatively, left and right hippocampal volumes were significantly different in both left and right TLE patients. Left TLE group: mean (SD) right hippocampal volume was 2.82 (0.28) cm^3 , mean left hippocampal volume 1.93 (0.63) cm^3 (paired t -test $P < 0.0001$, 2-tailed). Right TLE group: mean (SD) right hippocampal volume was 1.77 (0.44) cm^3 , mean left hippocampal volume 2.53 (0.28) cm^3 (paired t -test $P < 0.0001$, two-tailed). There was no significant difference between left hippocampal volume in the left TLE group and right hippocampal volume in the right TLE group.

Postoperatively there was no significant difference between postoperative volumes of the residual left or right hippocampi. Left TLE group: mean (SD) residual of left hippocampus 0.57 (0.56), range 0.07 – 2.9 cm^3 . Right TLE group: mean (SD) residual of right hippocampus was 0.62 (0.71), range 0.12 – 2.64 cm^3 . In three left and two right patients with TLE it was not possible to measure postoperative hippocampal volumes because of technical problems or because remnants were too small.

Functional magnetic resonance imaging results: verbal and visual memory

In patients with left TLE the mean recognition rates for 'pictures' were 0.7 preoperatively and 0.6 postoperatively, for 'words', 0.5 preoperatively and 0.45 postoperatively, and 0.3 for 'faces' pre- and postoperatively. There was no significant difference between pre- and postoperative recognition rates for 'pictures' and 'faces'. Words were less well remembered postoperatively in the left TLE group (paired t -test: $P = 0.02$).

In patients with right TLE the mean recognition rates were 0.7 for 'pictures' pre- and postoperatively, 0.5 for 'words' pre- and postoperatively and 0.2 for 'faces' preoperatively and 0.1 for 'faces' postoperatively. There was no significant difference between pre- and postoperative recognition accuracy for 'pictures' or 'words' but a trend for 'faces' to be less well remembered in patients with right TLE postoperatively (paired t -test: $P = 0.07$).

Main effects for encoding pictures, words and faces

Preoperatively, in the left TLE group there was weak right hippocampal activation for encoding faces ($P = 0.07$, FWE corrected in small volume of interest) but no significant hippocampal activation for encoding pictures or words.

In right TLE, there was significant left hippocampal activation for encoding words ($P = 0.029$, FWE corrected in small volume of interest), but no significant activation for encoding pictures or faces.

Postoperatively, patients with left TLE had significant left posterior hippocampal activation for encoding words ($P = 0.001$, FWE corrected in small volume of interest) and significant right ($P = 0.033$, FWE corrected in small volume of interest) hippocampal activation for encoding faces at the group level (Fig. 1).

In right TLE, there was weak left hippocampal activation for encoding words ($P = 0.073$, FWE corrected in small volume of interest) postoperatively, and no effect was seen for encoding pictures or faces (Table 1).

Comparison of pre- and postoperative main effects for encoding words and faces: difference – image analysis

We determined significant activation changes following ATLR using difference images representing greater pre- than postoperative activation and vice versa for the single subjects for the contrasts of interests (word encoding for left TLE, face encoding for right TLE) (Table 2).

Patients with left TLE showed significantly greater postoperative than preoperative activation in the posterior remnant of the left hippocampus for encoding words ($P = 0.042$, FWE corrected in small volume of interest), while no areas showed greater pre- than postoperative activation (Fig. 2 and Supplementary Fig. 1). There was no significant main effect (either greater pre- than postoperative activation or vice versa) for face encoding in right TLE.

Efficiency of preoperative reorganization of verbal and visual memory

One aim of this postoperative follow-up study was to test the functional integrity of the ipsilateral posterior hippocampus after ATLR.

We examined subgroups of patients with left TLE according to whether they suffered a clinically significant decline in verbal learning ($n = 7$) or whether their postoperative verbal learning scores were improved/remained stable ($n = 19$). A similar subgroup analysis was not possible in patients with right TLE as only one suffered a clinically significant decline in design learning scores.

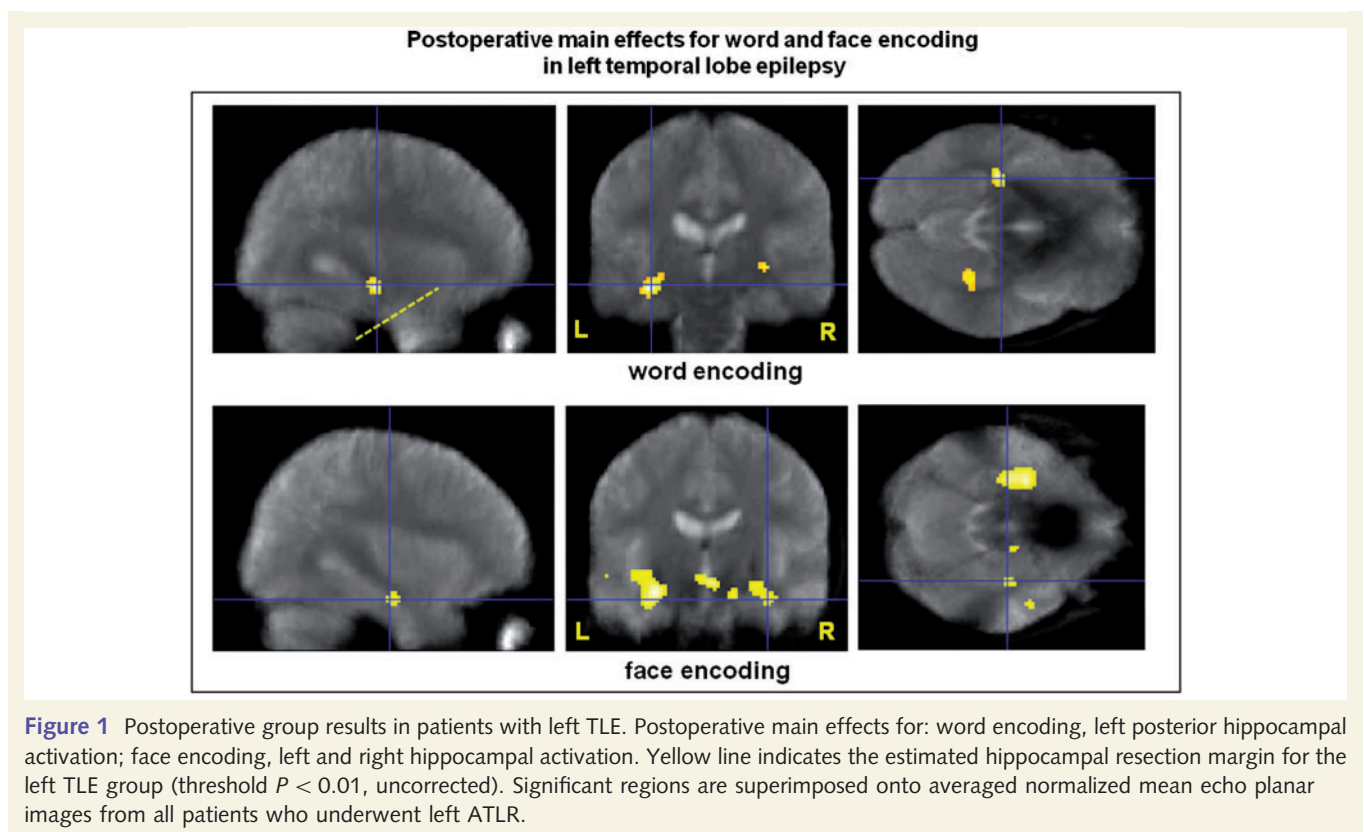
Correlation between change in functional MRI activation for encoding words and faces (pre- minus postoperative) and change in verbal and visual memory scores

In order to evaluate in which areas of the brain, change in functional MRI activation for encoding words or faces from pre- to postoperative were correlated with change in memory scores, we performed a voxel by voxel analysis over the entire temporal lobe field of view (Table 3).

Table 1 Pre- and postoperative functional MRI activation peaks in the hippocampus for the main effects of encoding words and faces

Subjects	Functional MRI contrast	Z-score	Corrected P-value (family-wise error)	Coordinates (x, y, z) in MNI space	Hippocampal activation
Left TLE preoperative	Word encoding	–	ns	–	–
	Face encoding	2.28	0.070	–	Right
Left TLE postoperative	Word encoding	3.86	0.001	–32, –22, –12	Left posterior
	Face encoding	2.61	0.033	34, –14, –22	Right
Right TLE preoperative	Word encoding	2.86	0.029	–34, –20, –22	Left
	Face encoding	–	ns	–	–
Right TLE postoperative	Word encoding	2.30	0.073	–34, –12, –18	Left
	Face encoding	–	ns	–	–

MNI space, coordinates related to a standard brain defined by the Montreal Neurological Institute (MNI); ns = not significant.

**Table 2** Difference image analysis: main effects of greater pre- than postoperative and greater post- than preoperative memory functional MRI activation for encoding words and faces

Subjects	Change in functional MRI contrast	Z-score	Corrected P-value (family-wise error)	Coordinates (x, y, z) in MNI space	Hippocampal activation
Left TLE	Word encoding (pre > postoperative)	–	ns	–	–
Left TLE	Word encoding (post > preoperative)	2.52	0.042	–34, –24, –12	Left posterior
Right TLE	Face encoding (pre > postoperative)	–	ns	–	–
Right TLE	Face encoding (post > preoperative)	–	ns	–	–

MNI space, coordinates related to a standard brain defined by the Montreal Neurological Institute (MNI); ns = not significant.

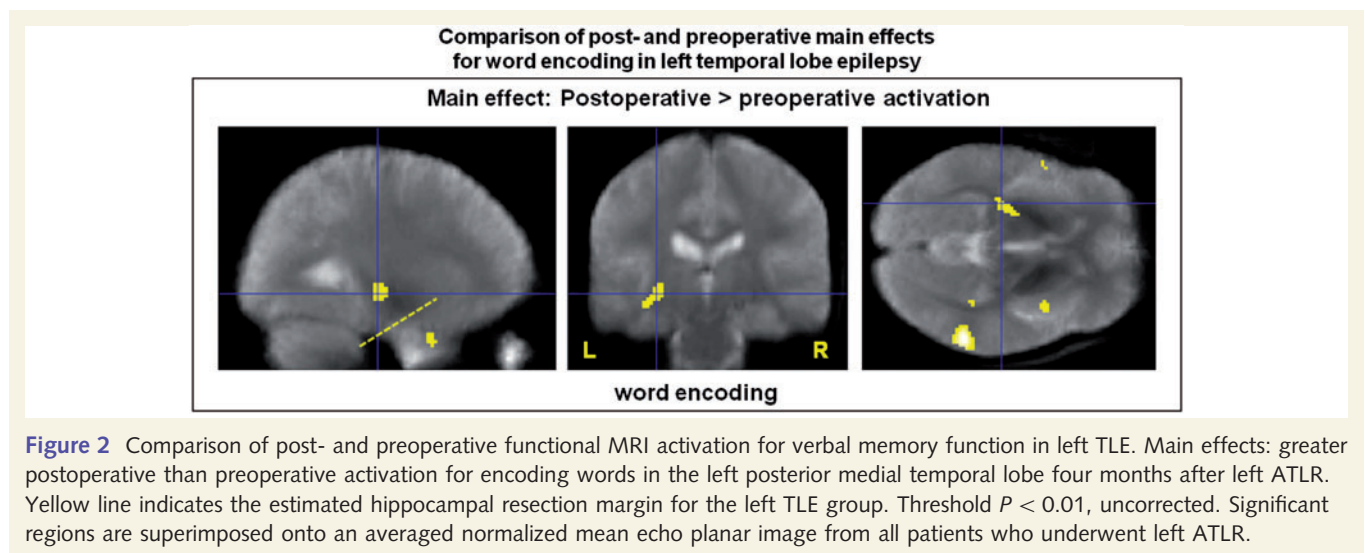


Table 3 Association of change of memory functional MRI activation for encoding words and faces (preoperative minus postoperative) with change of verbal learning/ design learning scores

Subjects	Change in functional MRI contrast – change in neuropsychology task	Z-score	Corrected P-value (family-wise error)	Coordinates (x, y, z) in MNI space	Hippocampal activation
Left TLE	Word encoding – VL	2.47	0.047	–30, –28, –12	left posterior
Left TLE	Word encoding – 1/VL	–	ns	–	–
Left TLE with decline	Word encoding – VL	–	ns	–	–
	Word encoding – 1/VL	–	–	–	–
Left TLE without decline	Word encoding – VL	3.60	0.002	–30, –20, –16	left posterior
Left TLE without decline	Word encoding – 1/VL	–	ns	–	–
Left TLE	Face encoding – DL	–	ns	–	–
	Face encoding – 1/DL	–	–	–	–
Right TLE	Face encoding – DL	–	ns	–	–
	Face encoding – 1/DL	–	–	–	–
Right TLE	Word encoding – VL	–	ns	–	–
	Word encoding – 1/VL	–	–	–	–

DL = design learning; MNI space, coordinates related to a standard brain defined by the Montreal Neurological Institute (MNI); ns = not significant; VL = verbal learning.

In patients with left TLE there was a significant positive correlation in the left posterior hippocampus ($P = 0.05$ corrected in small volume of interest), characterized by greater pre- than postoperative activation for encoding words in this area being correlated with better postoperative verbal memory (Fig. 3). Subgroup analysis showed that this result was mainly driven by patients with no significant verbal memory decline: patients with left TLE with stable or improved verbal memory test scores had a significant positive correlation between change in functional MRI activation for word encoding and change in verbal learning scores in the left posterior hippocampus ($P = 0.002$ corrected in small volume of interest), characterized by greater pre- than postoperative activation being associated with better postoperative verbal memory outcome. No correlation was observed for patients with a clinically significant memory decline.

In patients with right TLE there was no significant correlation between change in functional MRI activation for encoding faces and change in visual memory scores.

Efficiency of postoperative reorganization of verbal and visual memory

Data for the correlation between postoperative functional MRI activation for word or face encoding and postoperative neuropsychological performance is presented in Table 4

In the left TLE group, there was a significant negative correlation between postoperative functional MRI activation for encoding words and postoperative verbal learning scores ($P = 0.014$, FWE corrected in small volume of interest) in the left posterior hippocampus. This was characterized by greater postoperative functional MRI activation being associated with worse postoperative verbal memory performance. Subgroup analysis showed that this negative correlation in the left posterior hippocampus ($P = 0.001$) was driven by patients with left TLE with no clinically significant decline and this negative correlation was also seen in the right hippocampus ($P < 0.001$) and the right superior temporal gyrus ($P = 0.03$, all FWE corrected in SVI). There was no significant correlation for left TLE with clinically significant decline.

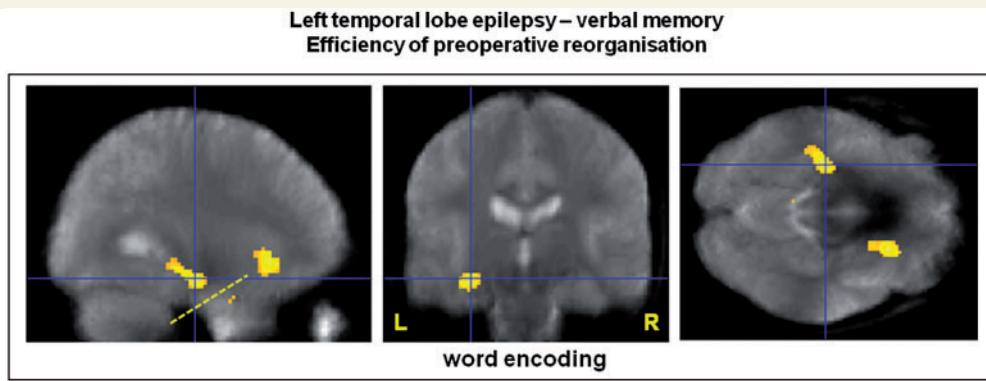


Figure 3 Efficiency of preoperative reorganization of verbal memory function in left TLE. Correlational analysis: greater pre- than postoperative activation on encoding words in the left posterior medial temporal lobe is associated with better verbal learning outcome. Yellow line indicates the estimated hippocampal resection margin for the left TLE group (threshold $P < 0.01$, uncorrected). Significant regions are superimposed onto averaged normalized mean echo planar images from all patients who underwent left ATL. R.

Table 4 Association of postoperative verbal learning/design learning scores with postoperative memory functional MRI activation

Subjects	Functional MRI contrast – neuropsychology task	Z-score	Corrected P-value (family-wise error)	Coordinates (x, y, z) in MNI space	Hippocampal activation
Left TLE	Word encoding – VL	–	ns	–	–
Left TLE	Word encoding – 1/VL	2.99	0.014	–30, –30, –14	Left posterior
Left TLE with decline	Word encoding – VL	–	ns	–	–
	Word encoding – 1/VL	–	–	–	–
Left TLE without decline	Word encoding – VL	–	ns	–	–
Left TLE without decline	Word encoding – 1/VL	3.95	0.001	–26, –30, –14	Left posterior
		4.16	$P < 0.001$	32, 2, –32	Right
Right TLE	Face encoding – DL	–	ns	–	–
	Face encoding – 1/DL	–	–	–	–

DL = design learning; ns = not significant; MNI space, coordinates related to a standard brain defined by the Montreal Neurological Institute (MNI); VL = verbal learning.

In the right TLE group there was a negative correlation in the right posterior hippocampus ($Z = 2.42$, $P = 0.047$, FWE corrected in small volume of interest, TH $P < 0.05$), characterized by greater postoperative functional MRI activation for face encoding being correlated with worse postoperative design learning scores.

Data for the correlation between change in functional MRI activation for word or face encoding (postoperative minus preoperative) and postoperative neuropsychological performance is shown in Table 5.

To further characterize these results and to investigate the efficiency of early postoperative reorganization/compensation we correlated postoperative minus preoperative functional MRI activations with postoperative memory scores.

In patients with left TLE we found a significant negative correlation with postoperative verbal learning scores in the left posterior hippocampus ($P = 0.02$), characterized by greater post- than preoperative functional MRI activation in this area being correlated with worse verbal memory performance (Fig. 4).

There was no significant correlation between postoperative volumes of the residual hippocampi and postoperative memory scores.

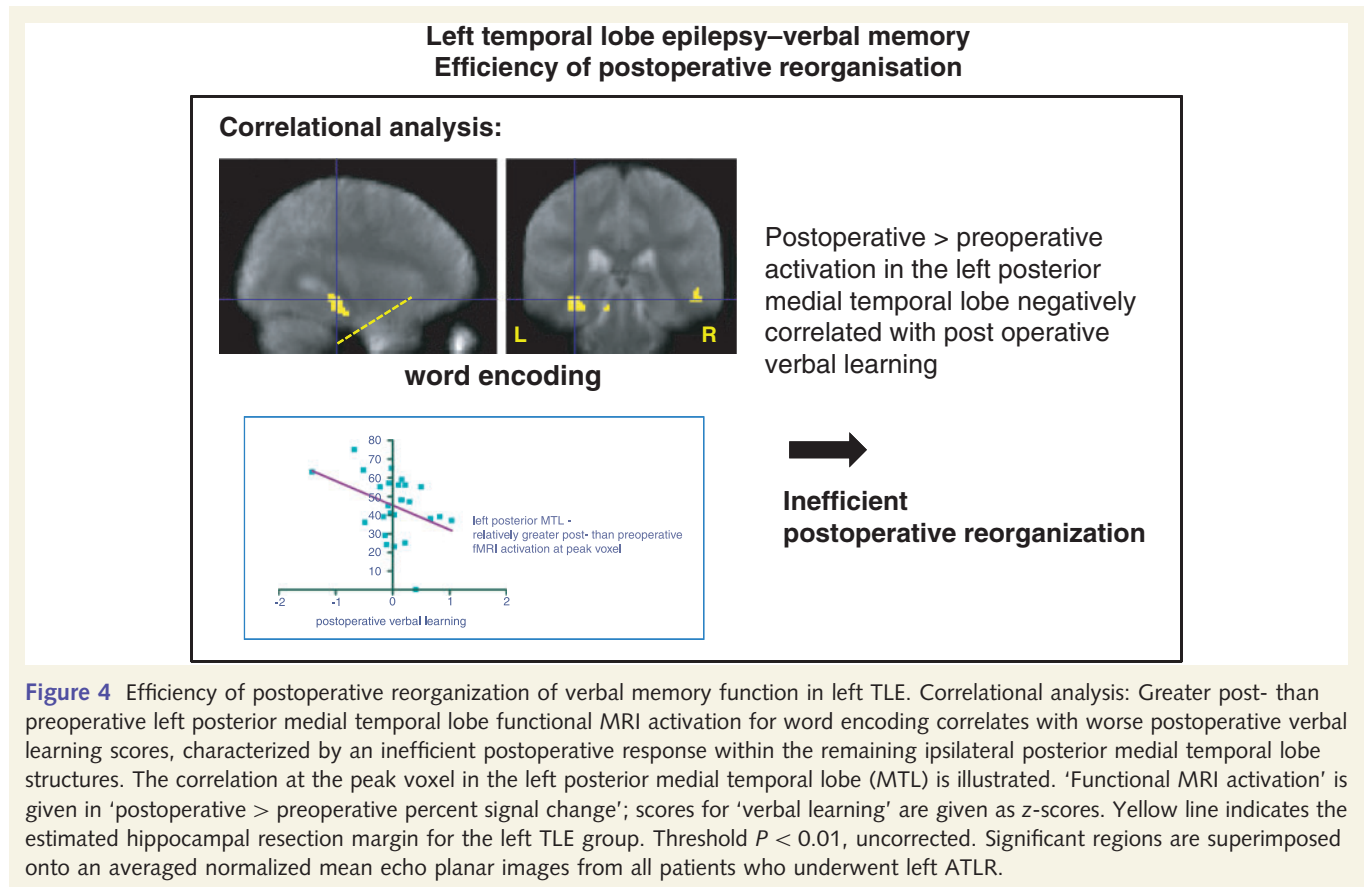
Discussion

This longitudinal functional MRI study examined how material specific memory function is reorganized in patients with TLE after left or right anterior temporal lobe resection and explored the effectiveness of these postoperative memory networks. In our previous preoperative study we demonstrated that preoperative ipsilateral activation within the anterior medial temporal lobe predicted greater verbal and visual memory decline whereas greater ipsilateral posterior medial temporal lobe activation was predictive of better verbal and visual memory outcome after ATL. (Bonelli *et al.*, 2010). The current postoperative follow-up study was concordant with these findings as greater pre- than postoperative activation within the ipsilateral posterior hippocampus correlated with better verbal memory outcome in patients with left TLE. In contrast, early postoperative reorganization within the ipsilateral hippocampus or to homologous areas in the contralateral hemisphere was not efficient. Only one patient with right TLE suffered a clinically significant decline in visual memory. Therefore it was not surprising that we found a similar, albeit weaker activation pattern for visual memory in patients with right TLE.

Table 5 Association of change in memory functional MRI activation (postoperative minus preoperative) for words and faces with postoperative verbal learning and design learning scores

Subjects	Change in functional MRI contrast – postoperative neuropsychology task	Z-score	Corrected P-value (family-wise error)	Coordinates (x,y,z) in MNI space	Hippocampal activation
Left TLE	Encoding words – VL	–	ns	–	–
Left TLE	Encoding words – 1/VL	2.82	0.021	–32, –32, –12	Left posterior
Right TLE	Face encoding – DL	–	ns	–	–
	Face encoding – 1/DL				

DL = design learning; ns = not significant; MNI space, coordinates related to a standard brain defined by the Montreal Neurological Institute (MNI); VL = verbal learning.



Postoperative memory processing

Previous neuropsychological and functional MRI studies have shown that left and right TLE patients may have impaired memory function, which is usually material-specific, due to the underlying pathology and ongoing disease (Helmstaedter *et al.*, 1997, 2003; Gleissner *et al.*, 1998; Golby *et al.*, 2002; Powell *et al.*, 2005). More recently this model of material-specificity has been challenged by several post-resection studies (Saling, 2009; Helmstaedter *et al.*, 2011b). Memory impairment can be worsened by anterior temporal lobe resection (Gleissner *et al.*, 2002, 2004; Helmstaedter *et al.*, 2003) and there is evidence that postoperative verbal memory processing in left TLE is affected differently by temporal lobe surgery than visual memory

processing in right TLE. This was also true in the current study in which preoperatively both left and right TLE patients showed impairment in verbal and visual memory function that was correlated to left/right medial temporal lobe memory functional MRI activation. Postoperatively, only one patient with right TLE suffered a clinically significant decline in visual memory compared with seven patients with left TLE with significant verbal memory decline after left ATLR. This finding parallels several previous studies suggesting a differential effect of temporal lobe resection on verbal and visual memory function (Lee *et al.*, 2002; Helmstaedter *et al.*, 2008) in left and right TLE patients (Wong *et al.*, 2009) with verbal memory being more vulnerable (Cheung *et al.*, 2009). Previous studies also suggest that visual-spatial memory is a more bilateral task than verbal memory and for

which verbalization may play a significant role (van Asselen *et al.*, 2006). This would be compatible with our results in right TLE.

Many functional MRI studies focused on the evaluation of preoperative memory processing and the prediction of postoperative memory decline (Rabin *et al.*, 2004; Richardson *et al.*, 2004; Janszky *et al.*, 2005; Binder *et al.*, 2008; Powell *et al.*, 2008) as did our previous preoperative study, which demonstrated that stronger ipsilateral memory encoding activation within the anterior medial temporal lobe was associated with greater postoperative verbal or visual memory decline, whereas greater ipsilateral posterior functional MRI activation in the medial temporal lobe before surgery was predictive of better verbal and visual memory outcome (Bonelli *et al.*, 2010). The underlying mechanism of postoperative reorganization and processing of memory function is poorly understood. Apart from a few case studies there is only one functional MRI study in which patients with TLE were systematically followed up 1 year after surgery (Cheung *et al.*, 2009). In this study a complex visual scene-encoding task was used to show that postoperative memory performance at 12 months after surgery was significantly associated with functional activation contralateral to the side of resection and therefore suggested that memory function in the contralateral medial temporal lobe might be necessary for supporting memory after ATR. This study, however, was limited by including only nine patients with left and eight patients with right with TLE, and heterogeneous pathologies. In contrast, we used a material-specific memory encoding paradigm for words and faces in a large and homogenous group of patients with medial TLE and showed that postoperative verbal memory function was still clearly lateralized with the main activation in the posterior remnant of the left medial temporal lobe, which is usually spared during ATR. Comparison with preoperative data showed that postoperatively there was no significant reduction in posterior medial temporal lobe activation for word or face encoding in left or right TLE patients, but a significant increase in activation for word encoding in the posterior remnant of the left medial temporal lobe.

Postoperative correlational analysis showed a significant but negative correlation between this activation and postoperative verbal learning scores in patients with left TLE, who did not have a significant postoperative verbal memory decline, characterized by greater postoperative activation being associated with worse performance on neuropsychological tests. We believe that the absence of a significant correlation between ipsilateral posterior medial temporal lobe activation and postoperative memory performance in patients with left TLE with clinically significant decline is because patients without decline have already reorganized memory function to their ipsilateral posterior medial temporal lobe over years before surgery, which protects them from declining significantly after ATR, whereas patients with significant verbal memory decline had failed to effectively reorganize memory function to the posterior medial temporal lobe before surgery, but showed stronger activation in the anterior part of the ipsilateral medial temporal lobe, which was shown to be predictive of greater postoperative decline (Bonelli *et al.*, 2010). At an early postoperative stage, patients with left TLE without decline activated this posterior part of the hippocampal remnant more strongly (probably as a compensatory response) but this additional

activation did not result in any further memory improvement. Those who declined, on the other hand, still did not show any activation in this part of the hippocampal remnant.

We interpret this result as reflecting an inefficient additional compensatory response within structures of the ipsi- and partly contralateral medial temporal lobe involved in postoperative memory processing in the early postoperative phase. These findings are consistent with the suggestion that preoperative reorganization within the ipsilateral medial temporal lobe and engagement of the posterior hippocampus in memory encoding before surgery is efficient and helps to maintain verbal memory postoperatively, whereas early postoperative reorganization is an inefficient process.

As for the patients with right TLE, there is evidence that memory function is affected differently in left and right TLE patients (Lee *et al.*, 2002; Helmstaedter *et al.*, 2008). There is an ongoing discussion regarding possible reasons for this: from a clinical perspective verbal memory seems much more vulnerable to surgery compared with visual memory, which was also the case in our patient sample with seven patients showing a clinically significant verbal memory decline, whereas only one patient had a significant visual memory decline.

Another reason might be that visual memory is less material-specific than verbal memory as patients tend to use verbal strategies in order to memorize visual (spatial) material. Finally, the weaker correlation in our patients with right TLE might also be due to the smaller sample size of 20 patients.

Neurobiological and clinical implications

Two models have been discussed to explain memory deficits after ATR: the hippocampal reserve theory suggests that it is the capacity of the contralateral hippocampus which preserves postoperative memory function whereas the functional adequacy model suggests the functional reserve of the ipsilateral hippocampus as the key structure to support memory function after surgery (Chelune *et al.*, 1991). In their pre- and postoperative follow-up study, Cheung *et al.* (2009) provided support for the hippocampal reserve theory by suggesting that it was the function of the contralateral medial temporal lobe that supports ipsilateral memory function after surgery.

The present study supports the functional adequacy model, in concordance with other neuropsychological and functional imaging studies, in particular for verbal memory (Baxendale *et al.*, 2000; Bonelli *et al.*, 2010; Helmstaedter *et al.*, 2011a, b). By directly comparing pre- and postoperative functional MRI data sets we demonstrated that functional reorganization to the ipsilateral posterior medial temporal lobe earlier in the epileptic history, before surgery, and to structures spared during ATR was essential for better postoperative verbal memory outcome.

More selective compared to extended temporal resections do not necessarily result in poor seizure outcome and may carry less risk of clinically significant deterioration of memory (Morino *et al.*, 2006; Alpherts *et al.*, 2008; Helmstaedter *et al.*, 2008). Recently Helmstaedter *et al.* (2011a) confirmed the negative

impact of the resection of non-lesional functional tissue for cognitive surgical outcome in a cohort of MRI and histopathologically negative patients with TLE whereas selective versus extended surgery appeared to result in similar seizure outcomes. The same authors postulated that neither medial resection length nor resected hippocampal volumes influenced postoperative seizure outcome whereas resection of larger hippocampal volumes resulted in poorer verbal memory outcome in patients with TLE who underwent selective amygdalo-hippocampectomy (Helmstaedter *et al.*, 2011b).

Our finding that functional tissue within the to be resected area is crucial to preserve verbal and visual memory encoding function after ATR emphasizes the need to re-evaluate the role of more restricted hippocampal surgery to minimize clinically relevant memory impairment in patients with TLE. We infer that the posterior hippocampus has an important role in the maintenance of verbal memory, and that tailored hippocampal resection, taking this into account, with the extent of hippocampal sclerosis, may optimize seizure and memory outcomes.

Methodology and future work

This study has the advantage of comparing memory functional MRI data and neuropsychological assessment before and 4 months after left or right ATR in a large and homogenous cohort of patients with TLE. Language dominance, which is in turn affected by age of disease onset, may influence results of material specific memory lateralization (Griffin and Tranel, 2007). A language lateralization index as assessed by language functional MRI pre- and postoperatively was used as a covariate to control for this possibility. This allowed us to explicitly study the effects of ATR with respect to pre- and postoperative reorganization of material specific memory function.

There are several strengths and limitations regarding methodology such as the advantages and disadvantages of using an event-related design, as well as the usual technical difficulties in the temporal lobes such as signal dropout and low resolution. Imaging parameters were optimized for capturing activation within the temporal lobes and adjacent structures (Bonelli *et al.*, 2010). More work is needed to optimize these parameters including field of view so that activation in other areas of the brain than the medial temporal lobe such as the orbito-frontal cortex, can be identified, to be able to comment on possible compensatory mechanisms. Furthermore, our results may be influenced by the effect of volume averaging on the extent and magnitude of hippocampal (remnant) signal, given that (i) most of the patients had hippocampal sclerosis; and (ii) all patients underwent left or right ATR.

Postoperatively, memory was reassessed at an early postoperative stage of 4 months after ATR. Four months might be too early for compensatory responses (such as in the contralateral medial temporal lobe) to become fully functional, which could account for our divergence from Cheung *et al.*'s (2009) results. Memory function (decline and recovery) has been found to stabilize within 2 years after surgery (Alpherts *et al.*, 2006). We are now carrying out further longitudinal follow-up studies of memory organization at 3 months and 12 months after surgery to further

investigate how this activation changes over a longer period of time in patients with TLE, having temporal lobe resection, and with a healthy control group also studied longitudinally, which will give us important further insights into postoperative recovery and plasticity.

In conclusion, engagement of the posterior left medial temporal lobe in verbal memory encoding before surgery was efficient and preserved verbal memory function after surgery, whereas early postoperative reorganization within the ipsilateral or to the contralateral medial temporal lobe was inefficient. Our results strengthen the view that functional tissue needs to be preserved by more selective and restricted surgical approaches with the ultimate goal of achieving maximum seizure control at a minimum of cognitive costs.

Acknowledgements

We are grateful to the radiographers at the Epilepsy Society MRI Unit, Philippa Bartlett, Jane Burdett and Elaine Williams, who scanned the subjects, to all our subjects and our colleagues for their enthusiastic cooperation, particularly to Dr Sallie Baxendale for her neuropsychological expertise, and for devising the epilepsy surgery neuropsychology database.

Funding

This work was supported by The Wellcome Trust (programme grant numbers 067176, 083148); The Wolfson Trust and Epilepsy Society support the Epilepsy Society MRI scanner; and the Austrian Section of the ILAE supported S.B. by a fellowship, Vienna 2006. This work was undertaken at UCLH/UCL who received a proportion of funding from the Department of Health's NIHR Biomedical Research Centres funding scheme.

Supplementary material

Supplementary material is available at *Brain* online.

References

- Alpherts WC, Vermeulen J, van Rijen PC, da Silva FH, van Veelen CW. Verbal memory decline after temporal epilepsy surgery? A 6-year multiple assessments follow-up study. *Neurology* 2006; 67: 626–31.
- Alpherts WC, Vermeulen J, van Rijen PC, da Silva FH, van Veelen CW. Standard versus tailored left temporal lobe resections: differences in cognitive outcome? *Neuropsychologia* 2008; 46: 455–60.
- Bartlett PA, Symms MR, Free SL, Duncan JS. T2 relaxometry of the hippocampus at 3T. *AJNR Am J Neuroradiol* 2007; 28: 1095–8.
- Baxendale S, Thompson P. Defining meaningful postoperative change in epilepsy surgery patients: measuring the unmeasurable? *Epilepsy Behav* 2005; 6: 207–11.
- Baxendale S, Thompson P, Harkness W, Duncan J. Predicting memory decline following epilepsy surgery: a multivariate approach. *Epilepsia* 2006; 47: 1887–94.
- Baxendale SA, Thompson PJ, Kitchen ND. Postoperative hippocampal remnant shrinkage and memory decline: a dynamic process. *Neurology* 2000; 55: 243–9.

- Binder JR, Sabsevitz DS, Swanson SJ, Hammeke TA, Raghavan M, Mueller WM. Use of preoperative functional MRI to predict verbal memory decline after temporal lobe epilepsy surgery. *Epilepsia* 2008; 49: 1377–94.
- Bonelli SB, Powell R, Thompson PJ, Yogarajah M, Focke NK, Stretton J, et al. Hippocampal activation correlates with visual confrontation naming: fMRI findings in controls and patients with temporal lobe epilepsy. *Epilepsy Res* 2011; 95: 246–54.
- Bonelli SB, Powell RH, Yogarajah M, Samson RS, Symms MR, Thompson PJ, et al. Imaging memory in temporal lobe epilepsy: predicting the effects of temporal lobe resection. *Brain* 2010; 133: 1186–99.
- Boulby PA, Symms MR, Barker GJ. Distortion matching echo planar images at different field strengths. In: *Proceedings of the International Society for Magnetic Resonance in Medicine*, Miami, FL, 2005. p. 2274.
- Chelune GJ, Naugle RI, Luders H, Awad IA. Prediction of cognitive change as a function of preoperative ability status among temporal lobectomy patients seen at 6-month follow-up. *Neurology* 1991; 41: 399–404.
- Cheung MC, Chan AS, Lam JM, Chan YL. Pre- and postoperative fMRI and clinical memory performance in temporal lobe epilepsy. *J Neurol Neurosurg Psychiatry* 2009; 80: 1099–106.
- de Tisi J, Bell GS, Peacock JL, McEvoy AW, Harkness WF, Sander JW, et al. The long-term outcome of adult epilepsy surgery, patterns of seizure remission, and relapse: a cohort study. *Lancet* 2011; 378: 1388–95.
- Friston KJ, Fletcher P, Josephs O, Holmes A, Rugg MD, Turner R. Event-related fMRI: characterizing differential responses. *Neuroimage* 1998; 7: 30–40.
- Friston KJ, Holmes AP, Worsley KJ, Poline JB, Frith CD, Frackowiak RS. Statistical parametric maps in functional imaging: a general linear approach. *Hum Brain Mapp* 1995; 2: 189–210.
- Gleissner U, Helmstaedter C, Elger CE. Right hippocampal contribution to visual memory: a presurgical and postsurgical study in patients with temporal lobe epilepsy. *J Neurol Neurosurg Psychiatry* 1998; 65: 665–9.
- Gleissner U, Helmstaedter C, Schramm J, Elger CE. Memory outcome after selective amygdalohippocampectomy: a study in 140 patients with temporal lobe epilepsy. *Epilepsia* 2002; 43: 87–95.
- Gleissner U, Helmstaedter C, Schramm J, Elger CE. Memory outcome after selective amygdalohippocampectomy in patients with temporal lobe epilepsy: one-year follow-up. *Epilepsia* 2004; 45: 960–2.
- Golby AJ, Poldrack RA, Illes J, Chen D, Desmond JE, Gabrieli JD. Memory lateralization in medial temporal lobe epilepsy assessed by functional MRI. *Epilepsia* 2002; 43: 855–63.
- Griffin S, Tranel D. Age of seizure onset, functional reorganization, and neuropsychological outcome in temporal lobectomy. *J Clin Exp Neuropsychol* 2007; 29: 13–24.
- Helmstaedter C, Grunwald T, Lehnertz K, Gleissner U, Elger CE. Differential involvement of left temporolateral and temporomesial structures in verbal declarative learning and memory: evidence from temporal lobe epilepsy. *Brain Cogn* 1997; 35: 110–31.
- Helmstaedter C, Kurthen M, Lux S, Reuber M, Elger CE. Chronic epilepsy and cognition: a longitudinal study in temporal lobe epilepsy. *Ann Neurol* 2003; 54: 425–32.
- Helmstaedter C, Petzold I, Bien CG. The cognitive consequence of resecting nonlesional tissues in epilepsy surgery—results from MRI- and histopathology-negative patients with temporal lobe epilepsy. *Epilepsia* 2011a; 52: 1402–8.
- Helmstaedter C, Richter S, Roske S, Oltmanns F, Schramm J, Lehmann TN. Differential effects of temporal pole resection with amygdalohippocampectomy versus selective amygdalohippocampectomy on material-specific memory in patients with mesial temporal lobe epilepsy. *Epilepsia* 2008; 49: 88–97.
- Helmstaedter C, Roeske S, Kaaden S, Elger CE, Schramm J. Hippocampal resection length and memory outcome in selective epilepsy surgery. *J Neurol Neurosurg Psychiatry* 2011b; 82: 1375–81.
- Hermann BP, Seidenberg M, Haltiner A, Wyler AR. Relationship of age at onset, chronologic age, and adequacy of preoperative performance to verbal memory change after anterior temporal lobectomy. *Epilepsia* 1995; 36: 137–45.
- Janszky J, Jokeit H, Kontopoulou K, Mertens M, Ebner A, Pohlmann-Eden B, et al. Functional MRI predicts memory performance after right mesiotemporal epilepsy surgery. *Epilepsia* 2005; 46: 244–50.
- Korsnes MS, Hugdahl K, Bjornæs H. An fMRI case study of visual memory in a patient with epilepsy: comparison before and after temporal lobe surgery. *Brain Struct Funct* 2009; 213: 457–62.
- Lee TM, Yip JT, Jones-Gotman M. Memory deficits after resection from left or right anterior temporal lobe in humans: a meta-analytic review. *Epilepsia* 2002; 43: 283–91.
- Mechelli A, Henson RN, Price CJ, Friston KJ. Comparing event-related and epoch analysis in blocked design fMRI. *Neuroimage* 2003; 18: 806–10.
- Morino M, Uda T, Naito K, Yoshimura M, Ishibashi K, Goto T, et al. Comparison of neuropsychological outcomes after selective amygdalohippocampectomy versus anterior temporal lobectomy. *Epilepsy Behav* 2006; 9: 95–100.
- Oldfield RC. The assessment and analysis of handedness: the Edinburgh inventory. *Neuropsychologia* 1971; 9: 97–113.
- Powell HW, Koepp MJ, Symms MR, Boulby PA, Salek-Haddadi A, Thompson PJ, et al. Material-specific lateralization of memory encoding in the medial temporal lobe: blocked versus event-related design. *Neuroimage* 2005; 27: 231–9.
- Powell HW, Richardson MP, Symms MR, Boulby PA, Thompson PJ, Duncan JS, et al. Preoperative fMRI predicts memory decline following anterior temporal lobe resection. *J Neurol Neurosurg Psychiatry* 2008; 79: 686–93.
- Rabin ML, Narayan VM, Kimberg DY, Casasanto DJ, Glosser G, Tracy JJ, et al. Functional MRI predicts post-surgical memory following temporal lobectomy. *Brain* 2004; 127: 2286–98.
- Richardson MP, Strange BA, Thompson PJ, Baxendale SA, Duncan JS, Dolan RJ. Pre-operative verbal memory fMRI predicts post-operative memory decline after left temporal lobe resection. *Brain* 2004; 127: 2419–26.
- Sabsevitz DS, Swanson SJ, Morris GL, Mueller WM, Seidenberg M. Memory outcome after left anterior temporal lobectomy in patients with expected and reversed Wada memory asymmetry scores. *Epilepsia* 2001; 42: 1408–15.
- Saling MM. Verbal memory in mesial temporal lobe epilepsy: beyond material specificity. *Brain* 2009; 132: 570–82.
- Schramm J. Temporal lobe epilepsy surgery and the quest for optimal extent of resection: a review. *Epilepsia* 2008; 49: 1296–307.
- Seghier ML, Neufeld NH, Zeidman P, Leff AP, Mechelli A, Nagendran A, et al. Reading without the left ventral occipito-temporal cortex. *Neuropsychologia* 2012; 50: 3621–35.
- van Asselen M, Kessels RP, Neggers SF, Kappelle LJ, Frijns CJ, Postma A. Brain areas involved in spatial working memory. *Neuropsychologia* 2006; 44: 1185–94.
- Wiebe S, Blume WT, Girvin JP, Eliasziw M. A randomized, controlled trial of surgery for temporal-lobe epilepsy. *N Engl J Med* 2001; 345: 311–18.
- Wieser HG, Blume WT, Fish D, Goldensohn E, Hufnagel A, King D, et al. ILAE Commission Report. Proposal for a new classification of outcome with respect to epileptic seizures following epilepsy surgery. *Epilepsia* 2001; 42: 282–6.
- Wilke M, Lidzba K. LI-tool: a new toolbox to assess lateralization in functional MR-data. *J Neurosci Methods* 2007; 163: 128–36.
- Woermann FG, Barker GJ, Birnie KD, Meencke HJ, Duncan JS. Regional changes in hippocampal T2 relaxation and volume: a quantitative magnetic resonance imaging study of hippocampal sclerosis. *J Neurol Neurosurg Psychiatry* 1998; 65: 656–64.
- Wong SW, Jong L, Bandur D, Bihari F, Yen YF, Takahashi AM, et al. Cortical reorganization following anterior temporal lobectomy in patients with temporal lobe epilepsy. *Neurology* 2009; 73: 518–25.
- Zigmond AS, Snaith RP. The hospital anxiety and depression scale. *Acta Psychiatr Scand* 1983; 67: 361–70.