

Yamagata Med J (ISSN 0288-030X) 2018 ; 36(2) : 121-127  
DOI 10.15022/00004449

## Evaluating erythema of the throat using a thin USB camera in children with group A beta-hemolytic streptococcal pharyngitis

Takahiro Abiko<sup>\*,\*\*</sup>, Toshihiro Sato<sup>\*</sup>, Tetsuo Mitsui<sup>\*\*</sup>

<sup>\*</sup>Internal Medicine of Mogami Municipal Hospital

<sup>\*\*</sup>Department of Pediatrics, Yamagata University, Faculty of Medicine

(Accepted May 31, 2018)

### ABSTRACT

**Background:** The Centor criteria and a rapid antigen detection test (RADT) are commonly used to diagnose streptococcal pharyngitis. We evaluated the relationships between specific erythema of the throat, Centor criteria, and positive RADT results to clarify the usefulness of direct observation with a thin USB camera.

**Methods:** We observed the pharynx of 161 patients aged 0–15 years using a thin USB camera. We also evaluated the Centor criteria and presence of specific erythema. We performed an RADT as pathological proof. Fisher's exact tests were conducted to assess the differences in the findings between RADT-positive and RADT-negative patients.

**Results:** Of the 87 patients who underwent RADT, specific erythema was present in 23 (26.4%), and 8 (9.2%) met three Centor criteria and had specific erythema. The RADT results were positive for 17 of the 23 with specific erythema (73.9%;  $p < 0.001$ ) and for 7 of the 8 who met three Centor criteria and had specific erythema (87.5%;  $p < 0.001$ ).

**Conclusion:** A high proportion of the patients with specific erythema of the throat had positive RADT results for streptococcal pharyngitis. A thin USB camera can provide exact clinical findings for both evaluators and patients with a low-cost and simple technique.

**Key words:** Centor criteria, pharyngitis, streptococcal infections, *Streptococcus pyogenes*

### Introduction

Pharyngitis caused by *Streptococcus pyogenes*, specifically group A  $\beta$ -hemolytic *Streptococcus* (GABHS), is a common upper respiratory tract infection in children. GABHS pharyngitis is typically evaluated using the standard criteria first reported by Centor et al. approximately 30 years ago<sup>1)</sup>: fever, swollen or tender anterior cervical lymph nodes, tonsillar exudate, and absence of a cough. The sensitivity of the presence of >3 criteria to diagnose GABHS pharyngitis exceeds 32%; however, false-positive results do occur, and initiation of antibiotic

treatment based solely on these criteria might result in excess use of antibiotics.

The existence of an inflamed throat reportedly increases diagnostic sensitivity using the Centor criteria<sup>2)</sup>. Although patients with GABHS pharyngitis typically have remarkable and blood-tinged throat erythema<sup>3)</sup>, so-called "specific erythema," to the best of our knowledge, no study has investigated the relationship between throat erythema and GABHS pharyngitis with a focus on their morphological characteristics.

Although the gold standard for pathological proof of GABHS is a throat swab culture, a rapid antigen diagnostic test (RADT) is used widely in the

outpatient setting for diagnosis. The sensitivity of RADT for GABHS pharyngitis is 83%–88%<sup>4)</sup>, and this test is useful for diagnosing GABHS pharyngitis. Appropriate treatment can be started early without waiting for a throat culture result; however, the medical cost prohibits the use of RADT for all patients with pharyngitis, and it is necessary to appropriately select the patients who should undergo an RADT.

In the present study, we aimed to evaluate the morphology and rate of positive RADT results in patients with GABHS pharyngitis using a low-cost, small diametral USB camera that can be easily used in an outpatient clinic; we also aimed to determine the reliability of the Centor criteria and to identify the patients suspected of having GABHS pharyngitis who should undergo an RADT. Then, we discussed about the importance of observing and recording using a thin USB camera in an outpatient clinic.

### Methods

Using a thin USB camera, we observed and recorded the throats of 161 patients aged 0–15 years who complained of a sore throat (for babies and toddlers, a sore throat was regarded present with similar symptoms) and were outpatients at Mogami Municipal Hospital during the 18-month study period from July 2014 to January 2016. The research was reviewed and approved by the Mogami Municipal Hospital ethics committee. Before observation, recording, or swabbing the throat, the patient or parents provided an informed consent.

We evaluated the following four Centor criteria: fever  $\geq 38.0^{\circ}\text{C}$ , absence of a cough, swollen cervical lymph nodes, and tonsillar exudates. Further, we assessed the existence of “specific erythema” of the pharynx. “Specific erythema” means remarkable redness of the pharynx with blood-tinged appearance<sup>3)</sup>.

We performed an RADT to obtain a pathological proof of GABHS pharyngitis in all patients with specific erythema or who met  $\geq 3$  Centor criteria. In addition, we performed an RADT in patients suspected with GABHS infection from a family and/or epidemic condition. An RADT were

performed using throat swabs and the *Quick chaser DipSTREP-A*<sup>®</sup> (Mizuho Medy Co., Ltd. Japan). Additional rapid tests were performed in patients suspected of having other infectious diseases, such as viral (influenza) or mycoplasma pharyngitis.

The *clip-formed scope* (Sanko Co., Ltd. Japan) was the thin USB device used for the recording. The apical part of the device contains a camera and LED light inside. Because this device is not considered an official equipment for medical use in Japan, we did not insert this device in the oral cavity and, instead, used it as an external penlight only. We recorded a video of the procedure using a personal computer (*VAIO*<sup>®</sup> *Tap 21* SVT2121A1J1; SONY Co., Ltd.) with a *Windows*<sup>®</sup> 8.1 (64 bit) operating system and an *AMCAP-Direct show video capture sample* system (version 8.1.2; Microsoft Co., Ltd.). We replayed the video to determine the existence of specific erythema and/or tonsillar exudate. We repeatedly informed the patients or parents of the recording and provided the results as feedback to the patients who underwent an RADT.

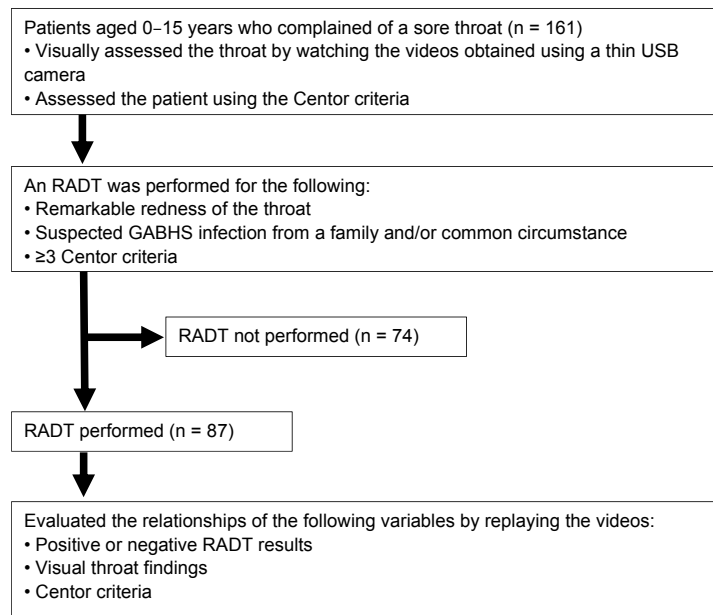
The association between the RADT results and specific erythema or Centor criteria was assessed in the patients who underwent an RADT. Statistical analyses were performed using *STATVIEW*<sup>®</sup> version 5.0 (SAS Institute Inc., Cary, NC). We used *t*-tests to assess the difference in mean age between the RADT and non-RADT groups; we used chi-square tests to assess the differences in the number of patients in each age group and of each sex. Fisher’s exact tests were conducted to assess the differences in the findings between RADT-positive and RADT-negative patients.

### Results

An RADT was conducted in 87 (54.0%) of the 161 patients (Figure 1), and 19 of the 87 patients who underwent RADT had positive results (21.8%). Age and sex were similar between the RADT and non-RADT groups (Table 1).

Of the 87 patients who underwent an RADT, 71 (81.6%) had tonsillar exudates, and 66 (75.9%) had a fever of  $\geq 38.0^{\circ}\text{C}$  (Table 2). None of the patients had swollen cervical lymph nodes. A total of 49

## Evaluating erythema with pharyngitis



GABHS: Group A  $\beta$ -hemolytic *Streptococcus*; RADT: rapid antigen diagnostic tests

Figure 1. Patient inclusion and tests performed in the present study

Table 1. Characteristics of patients aged 0–15 years who complained of a sore throat (n = 161)

	RADT group (n = 87)	Non-RADT group (n = 74)	p value
Age (years)			
Mean $\pm$ standard deviation	6.22 $\pm$ 4.07	6.44 $\pm$ 4.31	0.853
0–2	17 (19.5%)	17 (22.9%)	0.734
3–7	33 (37.9%)	27 (36.5%)	0.980
8–15	37 (42.5%)	30 (40.5%)	0.924
Male sex	46 (52.8%)	37 (50.0%)	0.847

*t*-tests were used to compare the mean age, and chi-square tests were used to compare the number of patients in each age group and of the male sex.

RADT: rapid antigen diagnostic test

(56.3%) patients who underwent the RADT met  $\geq 2$  Centor criteria. Of the 23 patients with specific erythema, 17 (73.9%) showed a positive RADT result ( $p < 0.001$ ). Moreover, specific erythema was present in 89.5% of the patients with positive RADT results. Among patients with 3 Centor criteria, 8 (36.4%) showed a positive RADT result ( $p = 0.075$ ) and 7 of the 8 patients had specific erythema. Among the 8 patients who met 3 Centor criteria and had specific erythema, 7 (87.5%) showed a positive

RADT result ( $p < 0.001$ ).

A few patients with a negative RADT result had positive results in other rapid tests; the nasal swab of 5 patients were positive for influenza antigen ( $n = 4$ , type A influenza;  $n = 1$ , type B influenza), while the tonsillar swab of another patient was positive for mycoplasma antigen. The pharynx of these patients was examined using a USB camera and no specific erythema was noted (Figure 2).

Table 2. Clinical findings and number of positive RADT results in patients who underwent an RADT (n = 87)

Findings	n [% of RADT]	RADT Positive (% of findings)	RADT Negative (% of findings)	p value
(Patients who underwent an RADT)	87 [100.0%]	19 (21.8%)	68 (78.2%)	
Specific erythema	23 [26.4%]	17 (73.9%)	6 (26.1%)	<0.001***
Centor criteria †				
Fever ≥38.0°C	66 [75.9%]	12 (18.2%)	54 (81.8%)	0.223
Absence of a cough	19 [21.8%]	10 (52.6%)	9 (47.4%)	0.449
Tonsillar exudate	71 [81.6%]	19 (26.8%)	52 (73.2%)	0.018**
≥2 Centor criteria	49 [56.3%]	14 (28.6%)	35 (71.4%)	0.117
3 Centor criteria	22 [25.2%]	8 (36.4%)	14 (63.6%)	0.075*
3 Centor criteria and specific erythema	8 [9.2%]	7 (87.5%)	1 (12.5%)	<0.001***

†None of the patients had swollen cervical lymph nodes

\*p < 0.1; \*\*p < 0.05, \*\*\*p < 0.01

Fisher's exact tests were used to compare the proportions.

RADT: rapid antigen diagnostic test




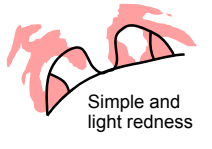
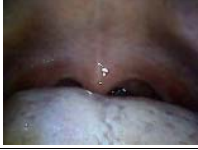
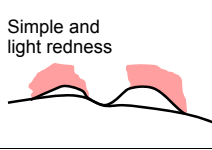

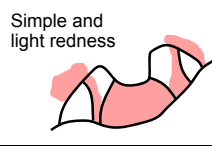
## Discussion

The results of the present study indicate that 73.9% of the patients who underwent RADT and 89.5% of RADT-positive patients with specific erythema of the throat had positive RADT results; this proportion of patients was higher than those who met the Centor criteria, a set of criteria widely used in the clinical evaluation of GABHS pharyngitis. Furthermore, the number of patients with a positive RADT result was higher and more significant than those who met the Centor criteria and with specific erythema. Therefore, we recommend that patients with specific erythema and positive Centor criteria undergo pathological tests for GABHS, such as an RADT, or a throat swab culture for greater accuracy when diagnosing GABHS pharyngitis. Furthermore, we emphasize the importance of accurately observing the throat in patients suspected with GABHS pharyngitis.

The Centor criteria are widely used in the clinical

practice since their first introduction and were improved by McIsaac et al.<sup>5)</sup> with the addition of a generation factor. In addition, owing to the high sensitivity, a throat swab culture is considered the gold standard for GABHS pharyngitis diagnosis; however, an RADT is more widely used in outpatient clinical practice because the diagnosis is typically quicker than with a swab culture. Furthermore, treatment with appropriate antibiotics against rheumatic fever or suppurative complications can be timely with an RADT, as compared with swab cultures. Given the sensitivity of an RADT for GABHS of 83%–88%<sup>4)</sup>, a positive RADT result can be used to diagnose GABHS pharyngitis. However, an RADT should not be performed in patients complaining of sore throat because this complaint is common in the outpatient setting; an RADT can be expensive, and the swabbing can cause pain. The administration of antibiotic to all patients with pharyngitis is not recommended as at least half of the cases of pharyngitis are caused by a virus<sup>6)</sup> and resistant bacteria, and allergic reactions with

## Evaluating erythema with pharyngitis

<ul style="list-style-type: none"> <li>• Case no., age, sex</li> <li>• Diagnosis</li> <li>• Centor criteria</li> <li>• Specific redness (+) or (-)</li> </ul>	Images	Simplified schemes
<ul style="list-style-type: none"> <li>• Case 58, 5 years, M</li> <li>• GABHS pharyngitis</li> <li>• Centor criteria: 2</li> <li>• Specific redness (+)</li> </ul>		 Specific redness
<ul style="list-style-type: none"> <li>• Case 46, 7 years, M</li> <li>• Influenza A pharyngitis</li> <li>• Centor criteria: 0</li> <li>• Specific redness (-)</li> </ul>		 Simple and light redness
<ul style="list-style-type: none"> <li>• Case 85, 8 years, M</li> <li>• Influenza B pharyngitis</li> <li>• Centor criteria: 2</li> <li>• Specific redness (-)</li> </ul>		 Simple and light redness
<ul style="list-style-type: none"> <li>• Case 64, 2 years, F</li> <li>• Mycoplasma pharyngitis</li> <li>• Centor criteria: 1</li> <li>• Specific redness (-)</li> </ul>		 Simple and light redness

**Figure 2.** Comparisons of pharyngeal findings using a thin USB camera between patients with group A  $\beta$ -hemolytic *Streptococcus* (GABHS) pharyngitis, viral influenza pharyngitis, or mycoplasma pharyngitis

frequent antibiotic use are concerns. Therefore, an RADT should be performed properly and limited only to the appropriate patients.

An RADT is performed in patients who meet  $\geq 2$  Centor criteria, which is also recommended by the American Academy of Family Physicians<sup>7)</sup>. However, patients who meet  $\geq 2$  Centor criteria can also have negative RADT results. In the present study, only 28.6% of the patients who met  $\geq 2$  Centor criteria had positive RADT results, and only 36.4% of the patients who met 3 Centor criteria had positive RADT results. These results are similar to the 16% and 34%, respectively, reported by Fine et al. in 206,870 patients<sup>8)</sup>.

Few studies have investigated the association between morphological characteristics of pharyngeal erythema and accuracy of diagnosis in GABHS pharyngitis regardless of the reports of some studies about the diagnostic usefulness of pharyngeal erythema such as scoring of GABHS pharyngitis. Little et al.<sup>2)</sup> reported that accurate findings for GABHS pharyngitis are inflamed tonsils, fever

during the last 24 hours, purulent tonsils, prior duration  $\leq 3$  days, or absence of a bad cough. Based on the present findings, a flame-like, or inflamed, throat, which was also reported by Little et al., is an important finding for GABHS pharyngitis. Reilly et al. reported that specific erythema is a specific finding of an anaerobic bacterial infection, and anaerobic bacteria such as GABHS are frequently detected in throats of patients with specific erythema<sup>9)</sup>. Therefore, specific erythema could broadly indicate pharyngitis caused by anaerobic bacteria. Because pharyngitis is rarely caused by anaerobic bacteria other than GABHS, it should be suspected first.

Thus, detection of specific erythema of the throat is more important in diagnosing GABHS pharyngitis, and more objective findings should be made for accurate diagnosis. Commonly, an observation is enough to directly inspect the throat by an evaluator. However, the findings must be recorded to make the diagnosis more objective and to clearly present these findings to the patients and their families, increasing clinical transparency. In this study, we were able to

obtain objective findings of the patients' pharyngeal examination and observe for specific erythema using a thin USB camera with LED light on top. Using these devices, we can provide a clear information about the pharyngeal findings to each patient and their families. To use those devices is innovate because there is no study to report the usefulness of the thin USB camera in outpatient clinics. Kodama et al. provided a concise report about the throat characteristics of patients with GABHS pharyngitis using digital scope (VersaCam<sup>®</sup>) and emphasized the importance of morphological assessment for proper use of antibiotics<sup>10</sup>. Therefore, we propose that the thin USB camera could be used in the outpatient setting to assess the throat, and suspected GABHS infection should be appropriately diagnosed and treated.

This study has several limitations. First, there are not enough patients to analyze accurately considering that GABHS pharyngitis is a common disease. It is because this single-center study was conducted in remote rural areas. Hence, further research using a larger sample size must be conducted in multicenters or in central cities and should accurately analyze the usefulness of specific erythema and Centor criteria in diagnosing GABHS pharyngitis. Second, a selection bias was noted as only those patients who had RADT were chosen. We performed an RADT in patients who were suspected with GABHS infection from a family and/or epidemic condition. It may contain asymptomatic carriers of *S. pyogenes* who is not applicable GABHS pharyngitis. Hence, an RADT should be performed in further studies. For example, an RADT should be performed in patients who meet  $\geq 1$  Centor criteria or exclude asymptomatic carriers. Finally, the quality of image is also an important limitation because the thin USB camera only contains one charge-coupled device. There are some portable devices with high-resolution camera on the market (such as VersaCam<sup>®</sup>), but they are more expensive (over \$ 4,000). Our next aim is to develop compact, low-cost, and high-resolution devices with LED light on the top to be able to record high-quality images and carry and manage easily while observing with tablet-type device or ordinary PC in the outpatient clinics.

## Conclusion

A high proportion of the patients with specific erythema of the throat had positive RADT results for streptococcal pharyngitis; these findings were more accurate when combined with the Centor criteria. When a patient has the presence of both Centor criteria and specific erythema, streptococcal pharyngitis should be suspected, and an RADT should be performed. Furthermore, a thin USB camera can provide objective clinical findings for both evaluators and patients with a low-cost and simple technique. Therefore, using a thin USB camera to evaluate the existence of specific erythema could accurately and clearly diagnose streptococcal pharyngitis.

## Acknowledgments

This research was presented at the 107<sup>th</sup> Yamagata Regional Meeting of Japan Pediatric Society on December 3, 2017. We are grateful to Kazuyuki Nakamura, MD; Jyun-ichi Yokoyama, MD; and Shino Okuyama, MD, for the helpful discussions.

## Conflict of interest

The authors have stated explicitly that there are no conflicts of interest in connection with this article.

## References

1. Centor RM, Witherspoon JM, Dalton HP, Brody CE, Link K: The diagnosis of strep throat in adults in the emergency room. *Med Decis Making* 1981; 1: 239-246
2. Little P, Hobbs FD, Moore M, Mant D, Williamson I, McNulty C, et al. : Clinical score and rapid antigen detection test to guide antibiotic use for sore throats: randomised controlled trial of PRISM (primary care streptococcal management). *BMJ* 2013; 347: f5806
3. In: Robert MK, Bonita MDS, Joseph SG, Nina FS, eds. *Nelson Textbook of Pediatrics* 20<sup>th</sup> ed (Robert RT: Acute Pharyngitis). Amsterdam; Saunders-Elsevier, 2015: 2017-2021
4. Lean WL, Arnup S, Danchin M, Steer AC: Rapid diagnostic tests for group A streptococcal pharyngitis:

## Evaluating erythema with pharyngitis

- a meta-analysis. *Pediatrics* 2014; 134: 771-781
5. McIsaac WJ, White D, Tannenbaum D, Low DE: A clinical score to reduce unnecessary antibiotic use in patients with sore throat. *CMAJ* 1998; 158: 75-83
  6. Bisno AL: Acute pharyngitis. *N Engl J Med* 2001; 344: 205-211
  7. Snow V, Mottur-Pilson C, Cooper RJ, Hoffman JR; American Academy of Family Physicians; American College of Physicians-American Society of Internal Medicine; Centers for Disease Control: Principles of appropriate antibiotic use for acute pharyngitis in adults. *Ann Intern Med* 2001; 134: 506-508
  8. Fine AM, Nizet V, Mandl KD: Large-scale validation of the Centor and McIsaac scores to predict group A streptococcal pharyngitis. *Arch Intern Med* 2012; 172: 847-852
  9. Reilly S, Timmis P, Beeden AG, Willis AT: Possible role of the anaerobe in tonsillitis. *J Clin Pathol* 1981; 34: 542-547
  10. Kodama K, Waza K, Ichinose H, Inoue K: Positive finding in Strep throat among children in primary care pediatrics. *Gairai Shonika* 2017; 20: 79-84 (Article in Japanese)