



Indian Journal of
**Pathology &
Microbiology**

Volume 55 • Issue 4 • October 2012

Official Publication of
Indian Association of Pathologists and Microbiologists

Fibro-osteochondroma of the uterus

Alan W. H. Bates, Manisha Ram

Department of Cellular Pathology, Royal Free Hospital, London NW3 2QG, UK

Address for correspondence:

Dr. Alan W. H. Bates, Department of Cellular Pathology, Royal Free Hospital, London NW3 2QG, UK. E-mail: alan.bates@nhs.net

ABSTRACT

A case of a uterine fibro-osteochondroma in a 61-year-old woman with postmenopausal bleeding was presented. Ultrasound revealed a calcified lesion in the posterior wall of the uterus and a hysterectomy was performed. Histopathologic examination showed a well-circumscribed triphasic tumor composed of peripheral lobules of mature hyaline cartilage and foci of trabecular bone with a core of loosely arranged fibroblast-like, spindle cells. This is the second reported case of fibro-osteochondroma, which has been described only in the uterus. Diagnosis requires thorough histopathologic examination to exclude metaplasia within a leiomyoma or uterine sarcoma. It is histologically benign and complete excision should be curative.

KEY WORDS: Chondroma, fibro-osteochondroma, osteochondroma, uterus

INTRODUCTION


Heterotopic cartilage and bone within the uterine myometrium can arise through various mechanisms, including dystrophic ossification of soft tissues and metaplasia in a preexisting tumor, most notably leiomyomas or uterine sarcomas; uterine cartilage and bone may also be derived from retained fetal material or formed as part of a mature teratoma. Although primary osteochondromatous tumors have been reported in a variety of extraskelatal sites, they have not previously been described in the uterus, with the exception of a single report of a lesion designated fibro-osteochondroma, a tumor that has not been found at any other site.^[1,2] We report the clinical and histologic findings of a second case of this unusual tumor. A review of the differential diagnosis is presented along with a consideration of its histogenesis.

CASE REPORT

A 61-year-old woman presented with a 6-month history of intermittent postmenopausal bleeding, anemia, and uterine prolapse. She was para 9 + 0, her last child having been born 21 years previously, was 5 years postmenopausal, and was not on hormone therapy.

Examination showed fourth degree uterine prolapse (procidentia). Laboratory studies revealed a microcytic anemia with a hemoglobin level of 10.4 g/dL. All other blood chemistry values were within normal limits. Transabdominal and transvaginal ultrasound showed a retroverted normal-sized uterus with a small posterior "calcified intramural fibroid." The patient underwent vaginal hysterectomy and anterior pelvic floor repair.

The uterus weighed 74 g and contained a hard 12 × 10 × 8 mm intramural nodule in the posterior wall [Figure 1]. This well-circumscribed lesion had no communication with the endometrial cavity. The specimen was fixed in 10% neutral formalin, embedded in paraffin, cut, and stained with hematoxylin and eosin (H and E). Microscopy showed a tumor formed of peripheral lobules of mature hyaline cartilage with a central fibro-myxoid core [Figure 2a]. The chondrocytes showed benign nuclear features with minimal

Access this article online
Website: www.ijponline.org
DOI: 10.4103/0377-4929.107814
Quick Response Code:


pleomorphism [Figure 2b]. Peripheral to the cartilage were several small foci of trabecular woven bone and osteoid [Figure 2c]. Surrounding the cartilage and bone was hypocellular connective tissue composed of fibroblast-like spindle cells with regular nuclei. Binucleation, mitoses, osteoclast-like giant cells, smooth muscle, and endochondral ossification were not identified. The patient remains well 3 months after surgery.

DISCUSSION

Histopathologically, our case closely resembles the fibro-osteochondroma of the uterus reported by Fukuoka *et al.*^[2] This was a much larger tumor weighing 800 g in a 42-year-old woman, but it showed the same triphasic composition with benign-appearing fibrous, osseous, and cartilaginous elements. The differential diagnosis of chondroid and osteoid tissue in the uterus includes heterotopic cartilage and bone formation as part of a non-neoplastic process, implanted fetal tissue, and metaplasia within a preexisting neoplasm.

Fewer than 100 cases of heteroplastic ossification or cartilage formation have been reported in the female genital tract, of which only two occurred in postmenopausal women.^[3,4] The

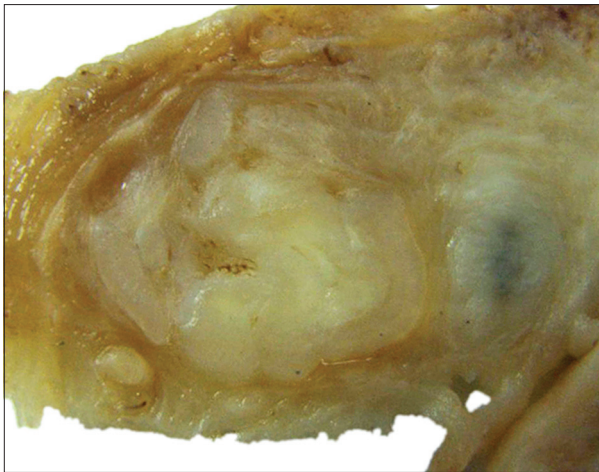


Figure 1: Macroscopic photograph of the intra-myometrial tumor with a firm, translucent cut surface (scale bar = 3 mm)

occurrence of islands of mature cartilage, bone, epidermis, or glia within the uterine wall has also been attributed to “fetal homografts,” usually in women of child-bearing age with a history of instrumental abortion, though the interval between pregnancy and diagnosis has been as long as 18 years.^[5] Prolonged retention of fetal bone may be difficult to differentiate from osseous metaplasia, and they may coexist.^[6] Both conditions typically present with multiple deposits of a single tissue type within the myometrium rather than a solitary heterogeneous mass. Dystrophic calcification or bone formation may occur following a hematoma, but in such cases one would expect to see evidence of hemorrhage, hemosiderin deposition, and foreign body type giant cells, all of which were absent in this case.

Benign or malignant osseous metaplasia has been reported in uterine leiomyomas, and malignant mesenchymoma of the uterus occasionally shows areas of osteosarcomatous differentiation.^[7,8] Our tumor contained neither mature smooth muscle nor sarcomatoid areas; there were no features of malignancy and no epithelial component characteristic of a mature teratoma.

Fibro-osteochondroma shows some similarities to extraskeletal osteochondroma, a tumor that normally arises near tendons and joints but which has been reported to arise in soft tissues.^[1] Fibro-osteochondroma is distinguished by the presence of a fibro-myxoid component and, unlike osteochondroma, it has previously been reported in the uterus. There has also been a report of extraskeletal chondroma of the fallopian tube in which it was suggested that the mesenchyme of the myosalpinx, either of smooth muscle or fibrous tissue lineage, could represent the cell of origin.^[9] Uterine fibro-osteochondroma may arise from similar precursor cells in the myoepithelium, which possesses metaplastic potential as evinced by the non-neoplastic osseous heterotopias from which fibro-osteochondroma must be distinguished.

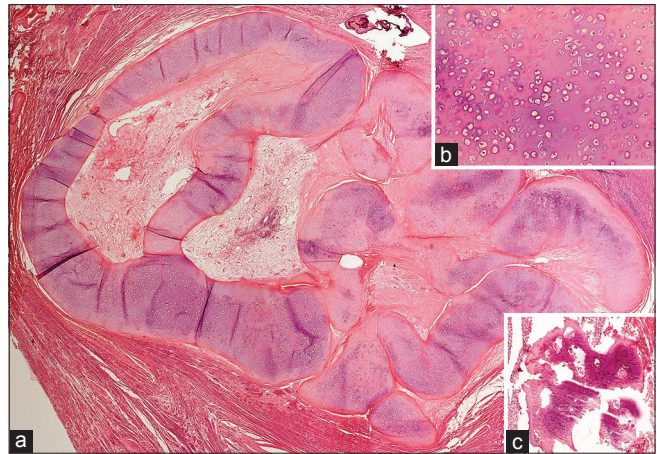


Figure 2: (a) Low-power view of the fibro-osteochondroma showing a well-circumscribed nodule composed of peripheral lobules of mature hyaline cartilage and central fibrous tissue (H and E). (b) High-power view showing benign appearing chondrocytes with minimal atypia. (c) Medium-power view showing trabecular bone formation

Across all sites, some 15% of soft tissue chondromas recur after local excision, probably due to incomplete removal.^[10] Neither case of uterine fibro-osteochondroma was reported to recur and histologically it is a benign lesion: follow-up is recommended after resection, but complete excision should be curative.

REFERENCES

1. Lim SC, Kim YS, Kim YS, Moon YR. Extraskeletal osteochondroma of the buttock. *J Korean Med Sci* 2003;18:127-30.
2. Fukuoka M, Fujii S, Konishi I, Mori T, Parmley TH, Woodruff JD. Fibro-osteochondroma of the uterus. *Obstet Gynecol* 1987;70:517-21.
3. Gerbie AB, Greene RR, Reis RA. Heteroplastic bone and cartilage in the female genital tract. *Obstet Gynecol* 1958;11:573-8.
4. Ogbonmwan SE, Cher G. Endometrial ossification in postmenopausal women. *J Obstet Gynaecol* 2011;31:774-6.
5. Grönroos M, Meurman L, Kahra K. Proliferating glia and other heterotopic tissues in the uterus: Fetal homografts? *Obstet Gynecol* 1983;61:261-6.
6. Bolaji II, Saridogan E, Hasan N, Baithun S, Djahanbakhch O. Prolonged retention of fetal bones with osseous metaplasia of the endometrium. *Int J Gynaecol Obstet* 1995;50:65-6.
7. Kefeli M, Baris S, Aydin O, Yildiz L, Yamak S, Kandemir B. An unusual case of an osteosarcoma arising in a leiomyoma of the uterus. *Ann Saudi Med* 2012;32:544-6.
8. den Bakker MA, Hegt VN, Sleddens HB, Nuijten AS, Dinjens WN. Malignant mesenchymoma of the uterus, arising in a leiomyoma. *Histopathology* 2002;40:65-70.
9. Varras M, Akrivis Ch, Tsoukalos G, Plis Ch, Karadaglis S, Ladopoulos I. Tubal ectopic pregnancy associated with an extraskeletal chondroma of the fallopian tube: Case report. *Clin Exp Obstet Gynecol* 2008;35:83-5.
10. Spanta R, Lawrence WD. Soft tissue chondroma of the fallopian tube. Differential diagnosis and histogenetic considerations. *Pathol Res Pract* 1995;191:174-6.

How to cite this article: Bates AW, Ram M. Fibro-osteochondroma of the uterus. *Indian J Pathol Microbiol* 2012;55:555-6.

Source of Support: Nil, **Conflict of Interest:** None declared.