Journal of Veterinary Internal Medicine
ACVIM
Open Access

Standard Article
J Vet Intern Med 2017;31:1487–1501

The Relationship between Brachycephalic Head Features in Modern Persian Cats and Dysmorphologies of the Skull and Internal Hydrocephalus

M.J. Schmidt, M. Kampschulte, S. Enderlein, D. Gorgas, J. Lang, E. Ludewig, A. Fischer, A. Meyer-Lindenberg, A.R. Schaubmar, K. Failing, and N. Ondreka

Background: Cat breeders observed a frequent occurrence of internal hydrocephalus in Persian cats with extreme brachycephalic head morphology.

Objective: To investigate a possible relationship among the grade of brachycephaly, ventricular dilatation, and skull dysmorphologies in Persian cats.

Animals: 92 Persian-, 10 Domestic shorthair cats.

Methods: The grade of brachycephaly was determined on skull models based on CT datasets. Cranial measurements were examined with regard to a possible correlation with relative ventricular volume, and cranial capacity. Persians with high (peke-face Persians) and lower grades of brachycephaly (doll-face Persians) were investigated for the presence of skull dysmorphologies.

Results: The mean cranial index of the peke-face Persians (0.97 ± 0.14) was significantly higher than the mean cranial index of doll-face Persians (0.66 ± 0.04; $P < 0.001$). Peke-face Persians had a lower relative nasal bone length (0.15 ± 0.04) compared to doll-face (0.29 ± 0.08; $P < 0.001$). The endocranial volume was significantly lower in doll-face than peke-face Persians (89.6 ± 1.27% versus 91.76 ± 2.07%; $P < 0.001$). The cranial index was significantly correlated with this variable (Spearman's r: 0.7; $P < 0.0001$). Mean ventricle: Brain ratio of the peke-face group (0.159 ± 0.14) was significantly higher compared to doll-face Persians (0.015 ± 0.01; $P < 0.001$).

Conclusion and Clinical Relevance: High grades of brachycephaly are also associated with malformations of the calvarial and facial bones as well as dental malformations. As these dysmorphologies can affect animal welfare, the selection for extreme forms of brachycephaly in Persian cats should be reconsidered.

Key words: Brachycephaly; Breeding; Coronal craniosynostosis; Hydrocephalus; Magnetic resonance imaging.

The Persian cat is one of the oldest cat breeds in the world and has a characteristic phenotype that had been unchanged for centuries.[1] In the late 19th century, cat fanciers began to modify the Persian into its present-day appearance. Through the years, the brachycephalic head morphology was accentuated more and more and has become the most important breed-defining trait.[2] Modern breed standards describe the desired Persian head morphology as an extremely round head with great breadth and a "high nose-leather". The forehead, nose, and chin are supposed to be in vertical alignment when viewed from the side, and the transition from nasal to frontal bone (break) is supposed to be centered between the eyes[3] (Fig 1A,B). The brachycephalic morphology of this modern "peke-face" Persian, named after the flat-faced Pekingese dog, accentuates childlike skull characteristics as it produces large round eyes and a flat face with a large forehead. This phenotype has become popular, although high grades of brachycephaly can be associated with severe health problems in Persians.[4–6] For a long time, German breeders preserved the traditional type of Persians, which is considered closer to the ancient original type.

Abbreviations:

2D	two-dimensional
3D	three-dimensional
BAER	brainstem auditory evoked response
CT	computed tomography
DSH	domestic shorthair cat
Kg	kilogram
mAs	milli-Ampere seconds
MRI	magnetic resonance Imaging
ms	milliseconds
NSA	number of signal averages
μA	microAmpere

From the Department of Veterinary Clinical Sciences, Clinic for Small Animals, Justus-Liebig University, Giessen, Germany (Schmidt, Enderlein, Ondreka); Department of Diagnostic and Interventional Radiology, University Hospital Gießen, Gießen, Germany (Kampschulte); Vetsuisse Faculty Berne, Clinical Radiology, Berne, Switzerland (Gorgas, Lang); Department of Companion Animals and Horses, University of Veterinary Medicine, Vienna, Austria (Ludewig); Section of Neurology, Clinic of Small Animal Medicine, Ludwig-Maximilians-University, Munich, Germany (Fischer); Clinic of Small Animal Surgery and Reproduction, Ludwig Maximilians-University, Munich, Germany (Meyer-Lindenberg); Unit for Biomathematics and Data Processing, Faculty of Veterinary Medicine, Justus Liebig-University, Giessen, Germany (Schaubmar, Failing).

Preliminary results of the study were presented at the ECVN Symposium 2015.

Corresponding author: M.J. Schmidt, Department of Veterinary Clinical Sciences, Clinic for Small Animals, Justus-Liebig University, Frankfurter Str. 108, 35392 Giessen, Germany; e-mail: Martin.J.Schmidt@vetmed.uni-giessen.de.

Submitted April 6, 2017; Revised June 1, 2017; Accepted July 13, 2017.

Copyright © 2017 The Authors. Journal of Veterinary Internal Medicine published by Wiley Periodicals, Inc. on behalf of the American College of Veterinary Internal Medicine.

This is an open access article under the terms of the Creative Commons Attribution-NonCommercial License, which permits use, distribution and reproduction in any medium, provided the original work is properly cited and is not used for commercial purposes.

DOI: 10.1111/jvim.14805



Fig 1. Comparison of head phenotype of the peke-face (7 years old, male) **(A, B)** and the doll-face Persian (6 years old, female) **(C, D)**.

Even though these Persians also have smaller noses than the domestic shorthair cat (DSH), they are in proportion with the rest of the face, and a protruding nose is preserved. This phenotype is commonly called "doll-face" by cat breeders[7,8] (Fig 1C,D).

German cat breeders, who crossed in more brachycephalic Persians to establish modern show lines in Germany, have observed the frequent occurrence of internal hydrocephalus with increasing fatality, leading to high losses of kittens in these new lines. Although veterinarians and breeding associations are aware of the higher prevalence of hydrocephalus in Persians, it has been claimed that this malformation is a random error in fetal development or might be associated with a separate genetic defect unrelated to brachycephalic skull morphology.[9–11]

Internal hydrocephalus seems to be linked to brachycephaly. In rodent models for human cranial diseases, in which the skull development is modified toward brachycephaly, hydrocephalus consistently occurs.[12,13] Furthermore, ventriculomegaly and hydrocephalus are common complications in humans with brachycephalic skull dysmorphologies such as achondroplasia[14,15] and craniosynostosis.[16,17] In dogs, small brachycephalic breeds such as the Chihuahua, pug, Pekingese, Maltese, Yorkshire terrier, English bulldog, Pomeranian, and Boston terrier are mostly affected.[18–22] Given this apparent connection between the brachycephalic skull conformation and enlarged ventricular volumes in other species, we hypothesize that the perceived frequent occurrence of hydrocephalus is not an incidental observation, but occurs in conjunction with overemphasizing brachycephalic skull features in these animals.

The aim of this study was to measure craniometric parameters that characterize the degree of brachycephaly and to evaluate for a possible correlation between the grade of brachycephaly and ventricular enlargement. The second aim was to describe morphologic abnormalities of the skull and brain that might be associated with the extreme forms of brachycephaly.

Materials and Methods

Animals

In this cross-sectional study, Persian cats from breeding clubs in Germany were invited for prospective magnetic resonance imaging (MRI) and computed tomography (CT) head examinations. Furthermore, we retrospectively collected CT studies of the head of Persians from different University Veterinary Clinics in Germany, Austria, and Switzerland. In addition, MRI and CT studies of 10 Domestic shorthair cats (DSH) were collected from the JLU archive to compare the general skull morphology, craniometric parameters, and ventricular dimensions between Persian cats and DSH in general. All scans were assessed for suitability according to the following criteria: (1) Scans had to include the whole skull and brain through at least the first cervical vertebra caudally. Series with inadequate image contrast and spatial resolution or incomplete series were excluded from the study. (2) Cats with parenchymal space-occupying lesions of the brain and skull or other conditions potentially influencing craniometric measurements were excluded. (3) Cats with osseous lesions distorting the cranial bones were excluded.

Clinical Examination

A full neurologic examination by a board certified neurologist was performed in cats that were introduced for the prospective part of the study.

Ethics Statement

The prospective part of the study was carried out in strict accordance with the recommendations in the Guidelines for Care and Use of Laboratory Animals of the German Animal Protection Law. The protocol was approved by the Committee on the Ethics

of Animal Experiments of the Justus Liebig University Giessen (JLU) and Regierungspräsidium Hessen (Permit number: 560 AZ-Gi 18/17 Nr. A20/2013). All cats in the prospective part lived with their owners who gave permission for their animals to be used in this study. Full consent was obtained from all owners of the retrospectively collected data, and actual cats remained anonymous.

Image Acquisition

Magnetic Resonance Imaging

Magnetic resonance imaging was performed with a 1 Tesla MRI scanner.[a] Images were obtained with T2-Turbospin echo sequences (TE: 100 ms, TR: 2036 ms, NSA 4) in all three orthogonal planes. Slice thickness was 2 mm. The field of view was 170 × 170 mm with an image matrix of 340 × 340. In addition, transverse FLAIR images were obtained as well as a high-resolution T1-3D fast field echo sequence.

Computed Tomography

The CT datasets were acquired with a 16-slice helical CT scanner[b] (120 kV, 350 mAs, matrix 512 × 512, slice thickness 0.8 mm, pitch 1).

Micro-CT

The skulls of five dead peke-face kittens were examined with a micro-CT System Skyscan 1173.[c] Heads were scanned with a tube voltage of 130 kVp and a tube current of 60 μA. The image pixel size was set to 30.22 μm (nominal isotropic resolution). All samples were scanned over 180° (plus fan angle) in rotation steps of 0.2° and a 4-fold frame averaging for noise reduction. To reduce image artifacts, a beam hardening was carried out with a brass filter of 0.25 mm thickness. Cross-sectional images were reconstructed based on a cone-beam reconstruction algorithm. A Gaussian kernel ($\sigma = 2$) was taken for image noise reduction. The 3D volume rendering was performed by the ANALYZE Software package.[d]

Image Processing

The skulls of the cats were examined by 3D models created from the CT datasets. Image processing for volume rendering of the volumes of interest was achieved by specialized graphical software (AMIRA®).[e] This program combines image information of two or more different planes in association with 3D models, which allows accurate manual and semiautomatic image segmentation on a slice-by-slice basis. The 3D models were combined with orthogonal 2D CT images (ortho-slice) and reconstructed image planes (oblique-slice), allowing the definite identification of measuring points.

Phenotyping of Persian Cats to Peke-Face or Doll-Face Morphology

Peke- and doll-face Persians are not clearly defined and may not represent two distinct morphologic types. However, we adopt these colloquial terms to define two groups of Persians either with high- or low grades of brachycephaly. The description of the CFA standards for a Persian demands the nose to be aligned with the eyes in a lateral view. This feature was used to classify the Persians according to their brachycephaly grade. Based on CT datasets, 3D head models were created witha threshold tool that enabled visualization and selection of the skin surface (Fig 2A–C). A transversal ortho-slice plane was aligned on the rostral end of the eye-globes.

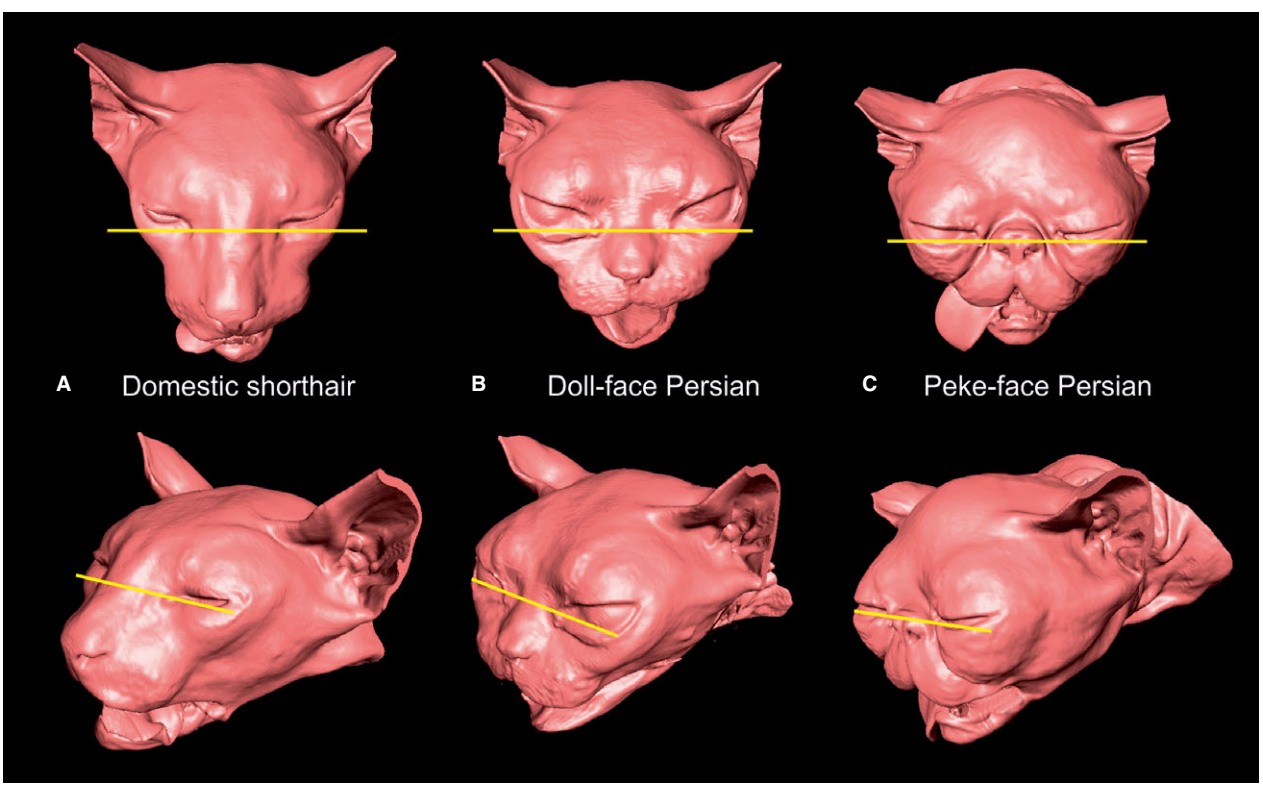

Fig 2. Classification of general head morphology of the studied cats. Classification was based on 3D head models semiautomatically created from the CT datasets with a threshold tool that enabled visualization and selection of the skin surface. An ortho-slice plane was aligned on the rostral end of the eye-ball. If the tip of the nose was rostral to that plane, the cat was assigned to the peke-face group. If the tip of the nose was on or caudal to that line, the cat was classified as a doll-face Persian.

If the tip of the nose was on or caudal to that plane, the cat was assigned to the peke-face group. If the tip of the nose was rostral to that line, the cat was classified as a doll-face Persian.

Craniometric Analysis

The skulls of the cats were semiautomatically reconstructed, and 3D computerized models were generated from the 2D CT images with a threshold that enabled visualization of bone. Measuring points that were not clearly seen in the models (for instance the naso-frontal suture) were identified and set in an ortho-slice combined with the model. The landmarks for craniometric measurements were previously defined for dry skulls and radiographs[23,24] and were previously used for analysis of the 3D models based on the CT datasets[25] (Fig 3). For each group, the following definitions were applied:

Akronasion: Most rostral end of the nasal bone measured in the same plane as the nasion (Fig 3A).
Basion: Caudal margin of basiocciput in the middle of the intercondylar incisures (Fig 3B).
Cranial width: Distance between left and right euryon.
Cranial length: Distance from inion to nasion.
Euryon: The most lateral part of the outside of the braincase on either parietal bone (Fig 3A,B).
Inion: Central surface point on the external occipital protuberance (Fig 3B).
Interorbital distance: minimum distance between the most medial parts of the orbit (orbiton-orbiton, Fig 3A).
Nasion: Junction on the medial plane of the left and right naso-frontal sutures (Fig 3A).
Nasal bone length: Distance from the nasion to the akronasion.
Orbiton: The most medial point of the bony orbit (Fig 3A).
Relative interorbital distance: The interorbital distance was divided by the skull width to exclude allometric influences.
Zygion: The most lateral point on the zygomatic arch (Fig 3A, B).
Skull width: Distance between the left and right zygion.
Occipiton: Most dorsal point of the foramen magnum (Fig 3B).
Occipital height: Distance from basion to inion.
Foramen magnum height: Distance measured from basion to occipiton.
Relative foramen magnum height: To rule out allometric differences of the foramen magnum height, this measurement was related to the occipital height.
Cranial index: Ratio of the cranial width to the cranial length. A high cranial index indicates a wider braincase in relation to length (i.e. a higher grade of brachycephaly).
Nose index: Ratio of the nasal bone length and maximum cranial length. A high nose index indicates a shorter nasal bone in relation to the whole longitudinal skull extension (higher grade of brachycephaly, i.e. brachyrhynchia).

Volumetric Measurements

Brain and Ventricular Volumes

In addition to the craniometric parameters, total brain and ventricular volumes were determined based on the CT datasets with a threshold that enabled visualization of brain tissue and cerebrospinal fluid (CSF). Both compartments were manually segmented based on their differences in contrast. Segmentation techniques were performed as described previously.[26] The caudal boundary of the volumetric analyses was an oblique-slice aligned to the basion-occipiton line. Rather than compare the absolute ventricular volumes between the cats that are subject to allometric influences, the ventricle: Brain ratio was determined to quantify the amount of ventricular enlargement (Figure S1).

Cranial Capacity

The endocranial volume that was not occupied by brain tissue (described as cranial capacity) was measured based on MRI datasets. First, the total brain volume was determined. All brain volumes were manually segmented and included the volume of the ventricular system. In the second step, the endocranial volume that was not occupied by brain tissue was measured with an automatic threshold selection tool adjusted to the CSF. The caudal boundary was set as described above. From the endocranial volumes and total brain volumes, the percentage of the cranial cavity filled with brain parenchyma was determined (Figure S1).[27]

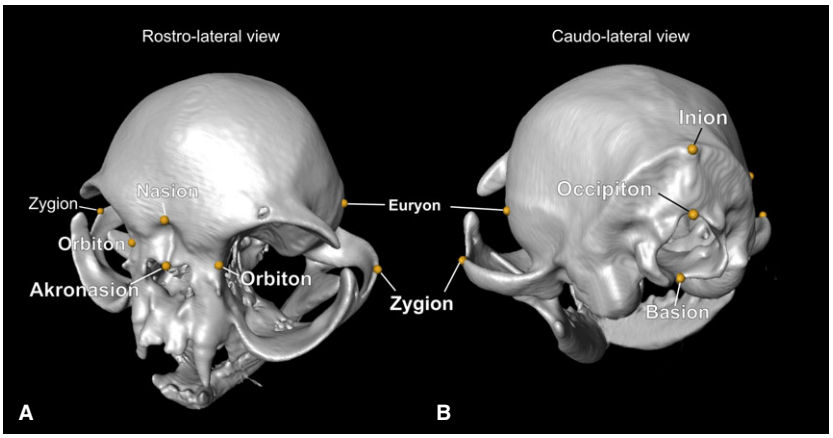

Fig 3. Craniometric parameters measured on the 3D skull models of the cats. The figure shows the skull model of a 5-year-old female peke-face Persian. Linear measurements between the following cranial points were obtained: Akronasion: Most rostral end of the nasal bone measured in the same plane as the nasion. Basion: Caudal margin of basiocciput in the middle of the intercondylar incisure. Euryon: The most lateral part of the outside of the braincase on either parietal bone. Inion: Central surface point on the external occipital protuberance. Nasion: Junction on the medial plane of the left and right naso-frontal sutures. Orbiton: The most medial point of the bony orbit. Occipiton: Most dorsal point of the foramen magnum. Zygion: The most lateral point on the zygomatic arch.

Determination of Cerebral White and Gray Matter Volume

The normal dimensions of the feline cerebral ventricular system have not been described yet so the routine assessment of the ventricles tends to be very subjective for each individual cat. In order to classify ventricular dimensions objectively, the measurement of the cerebral white matter in relation to the cerebral gray matter has been applied to the brain of brachycephalic dogs.[27] Based on the rationale that the relationship between white and gray matter in the forebrain is constant throughout all species[28]; we determined the cerebral white matter and gray matter volume based on MR-Images of all prospectively examined Persians. All segmentation procedures were performed by one investigator that was blinded to the head morphology of the cats.

In the first step, the cerebellum, brainstem, thalamus, and hippocampus were segmented and excluded from the volume of interest. As the white matter (WM) of the cerebral hemispheres, that is the internal capsules, merges into the thalamus running caudal toward the brainstem, a perpendicular line connecting the caudal border of the optic chiasm and the rostral border of the interthalamic adhesion was drawn in the midsagittal plane. This line was automatically represented in all other imaging planes, including the 3D model, and was used to delineate the internal capsule transition from the cerebral hemispheres to the diencephalon. White matter caudal to this line was not included.[27] The segmented WM and gray matter (GM) partitions were calculated and graphically presented by the program. The calculated volumes were used to calculate the GM-WM ratio. A cat was considered to have pathologically enlarged ventricles when there was a high/low ventricle brain ratio in conjunction with an altered WM-GM ratio compared to the control group.[27] WM and GM were not determined in the kittens as incomplete myelination does not allow accurate segmentation.

Statistical Analysis

Statistical analysis was performed by the commercial statistical software packages GraphPad Prism and BMDP (BMDP Statistical Software, Inc., Los Angeles, USA). Normal distribution of the data was assessed by residual analysis and Q-Q-plot with an appropriate regression model (program BMDP1R). Dependent of these results, the tests for mean comparisons were chosen on the basis of normal or non-normal distribution as appropriate. In case of a distribution skewed to the right (e.g. CSF volume), a logarithmic transformation of the data was applied to get nearly normal distribution. To test homogeneity of the groups, the relative frequency of male and female animals in the groups was compared by Fisher's exact test (program BMDP4F). Chi-squared tests were used to test the association between qualitative morphologic abnormalities and the general head morphology. The correlation between parameters was evaluated by Spearmen's correlation.

Regarding the group comparison for WM and GM, the relative GM volume, relative WM volume, CSF volume, and WM/GM ratio were first plotted against the body weight of the animals as a potential confounding variable. The slopes of the regression lines were compared between groups, testing the null hypothesis that, for each dependent variable, the slopes between the groups are identical (analysis of covariance, ANCOVA). In addition, the variability around the regression line was compared by the Levene's test for variability. In a second step of the analysis, the adjusted means (group means adjusted for different body weights at the common mean body weight, performed with a common slope or, if the slopes are significantly different, by unequal group specific slopes) of all groups were calculated and checked for significant differences between groups. As usual, a significance level of $P < 0.05$ was used.

Results

Epidemiologic Data

Thirty-five of 51 retrospectively collected CT studies met the inclusion criteria. Thirty-five Persian cats and 10 DSH were examined for various reasons, primarily for inner and middle ear disease, retropharyngeal mass lesions, retrobulbar mass lesions, thyroid masses, facial nerve paralysis, post-tectal visual deficits, cervical pain, cervical vertebral malformations, and behavioral problems. The same diagnoses were made in the group of 10 DSH.

Fifty-seven Persian cats were examined prospectively. From the entire group of 92 Persian cats, 45 were assigned a doll-face morphology. Twenty-three cats of this group were female and 22 cats were male (age range: 1.5–14 years, mean: 6.5 years; weight range: 2–4.8 kg, mean: 3.3).

From the 47 cats in the peke-face group, 25 were female and 22 were male (age: 3 weeks to 14 years; mean: 3.1 years; weight range: 0.3–4.4 kg, mean: 2.7 kg).

The DSH used as a control group comprised 12 females and eight males, (body weight: 3.3–6.4, mean: 5.2; age: 3–15 years, mean: 8.7). Fisher's exact test revealed no differences in the frequency distribution of gender between groups (doll versus peke, $P = 0.90$, peke versus DSH, $P = 0.78$; doll vs. DSH, $P = 0.59$).

Clinical Signs in the Persian Cats

Neurologic signs in the cats in the retrospective group were attributed to lesions not affecting the brain or cranial cavity. Head tilt, facial paralysis, pain, and abnormal pupillary light response were localized to a peripheral vestibular, peripheral facial, or retrobulbar lesion.

The clinical sign of each individual animal is listed in Table S1. From the cats that underwent neurologic examination in JLU all doll-face Persians were clinically sound. Fourteen peke-face Persians (66%) were obtunded and unresponsive to external stimuli. Eight (38%) had absent menace responses with preserved pupillary light reflexes indicating post-tectal visual impairment. Six cats (28%) did not react to acoustic stimuli. Other signs noted during the neurologic examination were delayed initiation of the hopping and wheelbarrowing reactions (three cats; 14%). Seven cats (33%) showed absent postural reactions. In 12 cats (57%), ataxia was hardly visible on initial examination but was detected after jumping from the examination table. Five kittens (23%) from three different litters had severe ataxia in all four limbs and were unable to stand most of the time. They were obtunded and had mild head tremors and positional nystagmus as well as ventro-lateral strabismus. They showed an abnormal breathing pattern. The owners reported long lasting aimless screaming in the time before presentation. Due to their severe clinical signs the owners decided to euthanize these cats. These kittens were examined with micro-CT.

Description of Skull and Brain Morphology of the Peke-Face Persians

Compared to both DSH and doll-face Persians, a grossly reduced cranial length and increased width and height was noted in the peke-face Persians (Fig 5). When viewed from the front, the width of the braincase (cranial width) almost reached the lateral borders of the orbits in fourteen cats (Fig 4F). The skull was dorsally round and dome-shaped and showed frontal bossing in all peke-face cats (Fig 4C,F,I). An external sagittal crest or a prominent insertion line for the masticatory muscles was not visible (Fig 4I). In four peke-face Persians, the dorsal contour of the skull was asymmetric in the frontal view with diverting orbits (Fig 5D), and a lateral deviation of the maxilla with deformation of the nasal and frontal bone was obvious (Fig 5E,F). The interorbital part of the nasal and frontal bone was indented toward the cranial cavity in all peke-face Persians (Figs 4F, 5C-H). The frontal sinus was small or absent in all peke-face cats. The nasal bone was found to be notably short. In one cat the nasal bone was absent (Fig 5G). Eight peke-face Persians showed osseous defects in the parietal and frontal bones (Fig 5G, F). Flat orbits were noted together with a subjectively increased interorbital distance. Thirty-eight peke-face cats showed a prognathic mandible (Fig 6). The occlusal pattern of the canines and incisors was aberrant in twelve cats. Upwards deviation of the upper incisors was seen in three cats (Fig 6E) and a deviation of the canines in two cats (Fig 6F). Retrograde growing conchae were found in 24 cats, leading to obstruction of the ventral nasal passage. None of these findings were seen in doll-face Persians. Using the Chi-square test a significant association was found between the peke-face

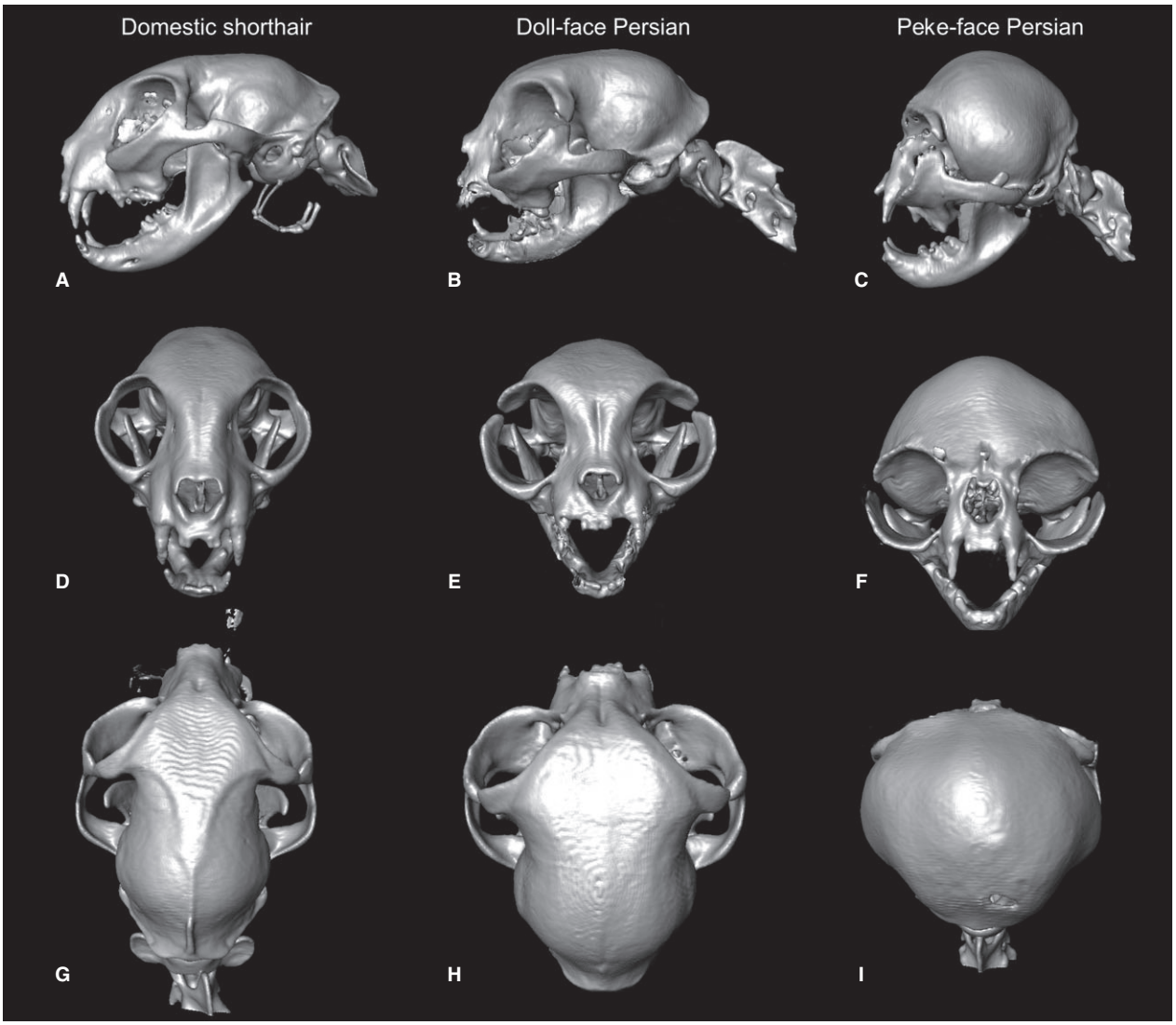

Fig 4. Comparison of skull morphology. The 3D reconstructions of the skulls show a reduced muzzle and reduced longitudinal extension of the skull in a doll-face Persian (2 years old, female) **(B, E, H)** compared to the domestic shorthair (3 years old, female) **(A, D, G)**. The principal skull morphology remains unchanged in the doll-face Persian. The peke-face Persian (6 years old, male) **(C, F, I)** shows profound aberrations compared to the other cats.

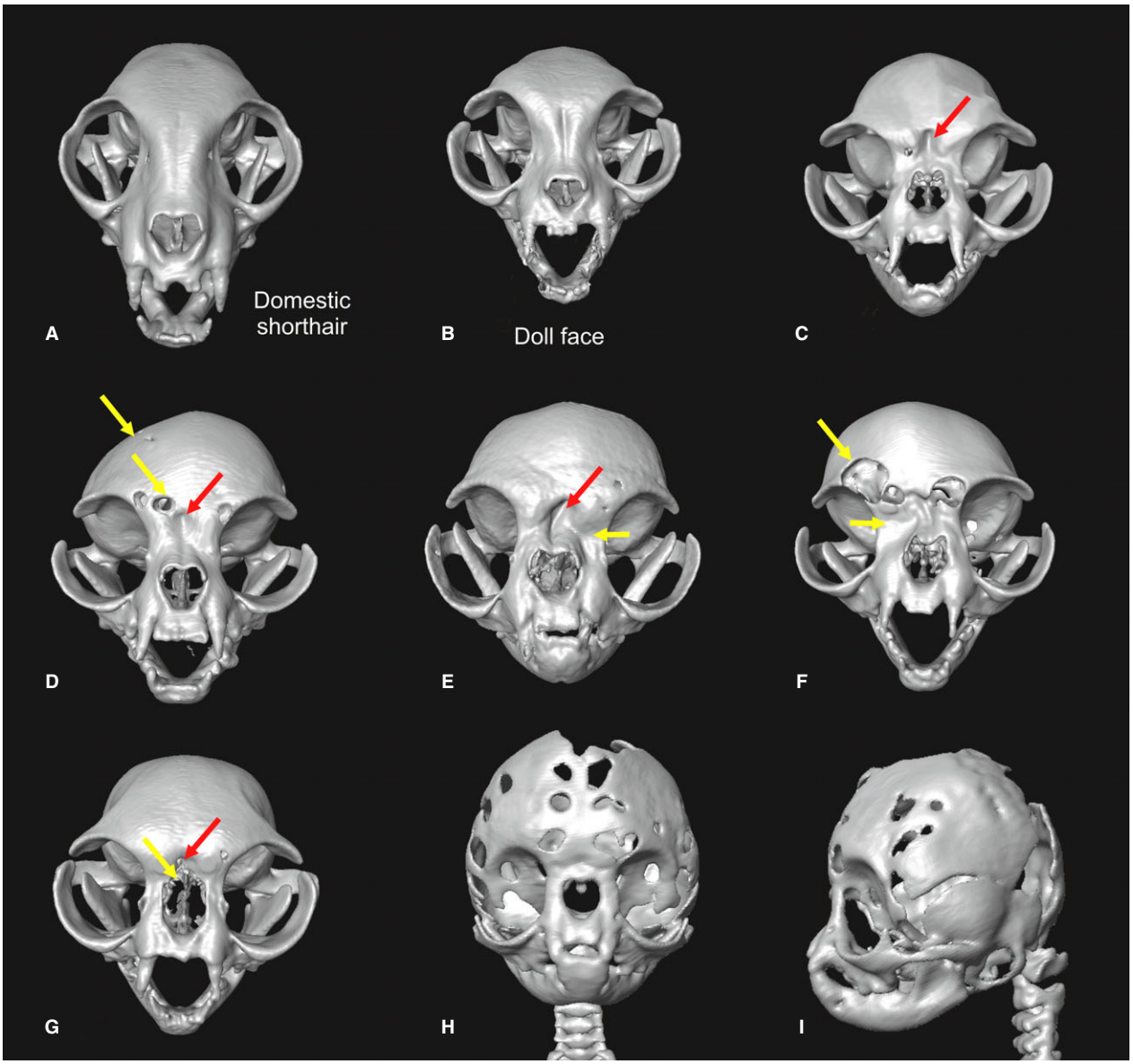

Fig 5. Skull changes in peke-face Persians. (C-I) a doll-face Persian (B) compared to a Domestic Shorthair cat (A). The interorbital part of the nasal and frontal bone was indented toward the cranial cavity in peke-face Persians (marked by the red arrow in **C**, 3 years old, male) seen in all peke-face Persians **(C-I)** but not in doll-face Persians (**B**, 18 months old, male). In some cats the skull was asymmetric in the frontal view with diverting orbits (**D**, 3 years old female), and a lateral deviation of the maxilla with deformation of the nasal and frontal bone was obvious (**E**, 5 years old, male; **F**, 3 years old, male). Osseous defects in the parietal and frontal bones were seen (Fig 5 **G**, 2 years old, female; **F**, 3 years old, male) and were most pronounced in the kittens (3 and 4 weeks old, both female) **(H, I)**.

morphology and osseous defects ($P = 0.0097$), upper jaw dental malformations ($P < 0.0001$), mandibular prognathism ($P < 0.0001$), and retrograde growing conchae ($P < 0.0001$).

Midsagittal MR-images revealed a displacement of the turbinates toward, or into, the cranial cavity (Figs 7C–E, 8A,C,F). In peke-face Persians, the rostral aspect of the brain was compressed leading to a more circular brain shape in sagittal views. Olfactory bulbs were ventrally and laterally shifted. The corpus callosum was round, separated from the fornix, and dorsally displaced in eighteen peke-face Persians (Figs 7 C, E; 8A,C,F). Thirty-eight cats showed cerebellar deviation into the foramen magnum, which was also seen in twelve of the doll-face Persians (Figs 7C-F; 8A,C,F). In five kittens, almost half of the cerebellum herniated into the vertebral canal (Fig 9A,D).

Dimensions of the lateral ventricles were subjectively increased in 29 peke-face Persians. Ventricular distension was confined to the lateral cerebral ventricles, and the third and fourth ventricles were normal in all cats in this study (Figs 7-9). The mesencephalic aqueduct was patent in all examined cats. All doll-face Persians showed subjectively normal ventricular dimensions

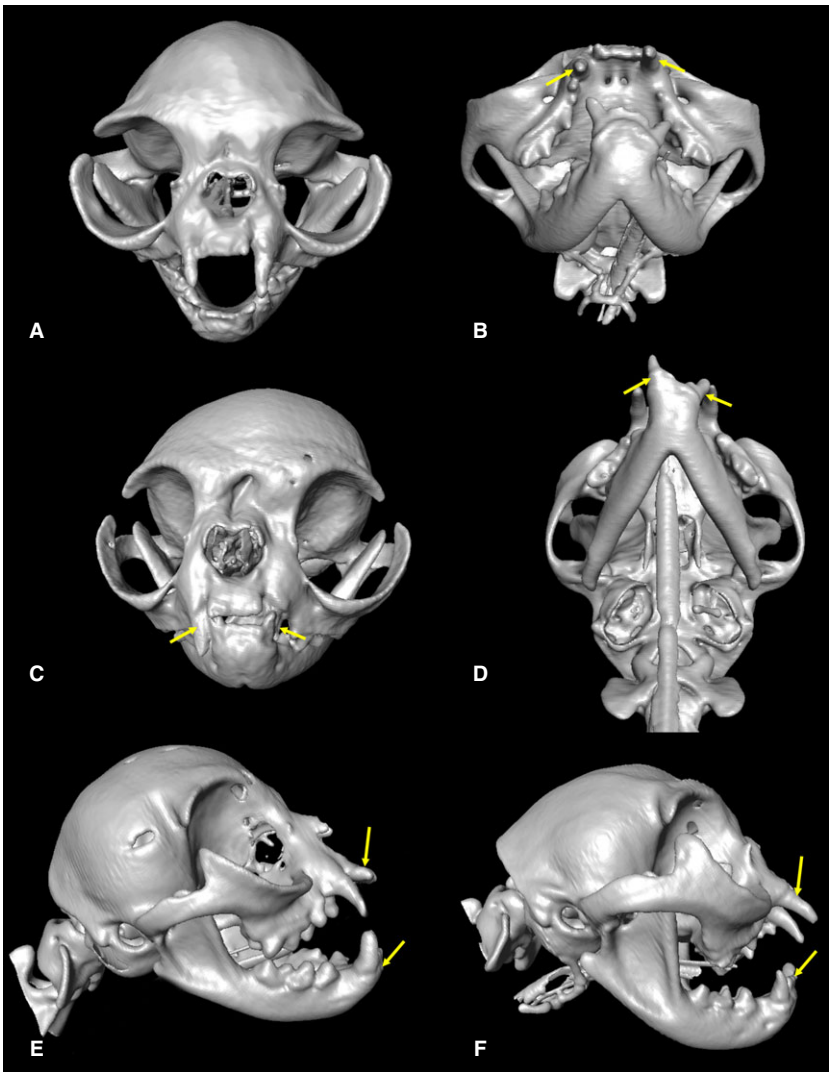

Fig 6. Dental abnormalities in peke-face Persians. Mandibular prognathism was seen in peke-face Persians as well as dental malalignments of incisive and canine teeth (**A, B**: 3 years old, female; **C**: 3 years old female; **D**: 5 years old, female; **E**: 2 years old, male; **F**: 2 years old, male).

(Fig 10). Ventricular enlargement (ventricle brain ratio) ($P < 0.0001$) and cerebellar herniation ($P < 0.001$) were clearly associated with the peke-face morphology.

Micro-CT Examination

Based on severe neurologic signs and MRI findings, five kittens of 4–5 weeks of age were euthanized and examined with a micro-CT system post mortem. The skulls of 2–6-week-old kittens from the anatomical specimen collection of the Clinic for Small Animals (JLU) were also scanned for comparison. Based on the micro-CT images, 3D-skull models were automatically generated (Fig 11). Micro-CT models allowed excellent visualization of the cranial growth centers, which could not be visualized via conventional CT. All cranial base synchondroses (spheno-occipital, intersphenoidal, and spheno-ethmoidal) and calvarial sutures (interfrontal, sagittal, fronto-temporal, parieto-temporal, and lambdoid) could be identified. However, the coronal sutures (fronto-parietal sutures) were absent or reduced to minimal irregular residues (Fig 11). Compared to the two mesocephalic kittens (Fig 11H–K), the sagittal- and fronto-occipital sutures were distended showing focal isolated bony islands within the sutures (wormian bones, Fig 11B, F, Q, R, S, red arrows). The supraoccipital and the interparietal bone appeared increased in size, and the widely open lambdoid suture appeared to be shifted rostrally compared to the mesocephalic kittens. Osseous defects in various degrees were seen.

Craniometric Parameters

All measured parameters are listed in Table S1.

All data were normally distributed. The ANOVA and post hoc Newmans-Keuls tests revealed the following differences. The cranial index was significantly different

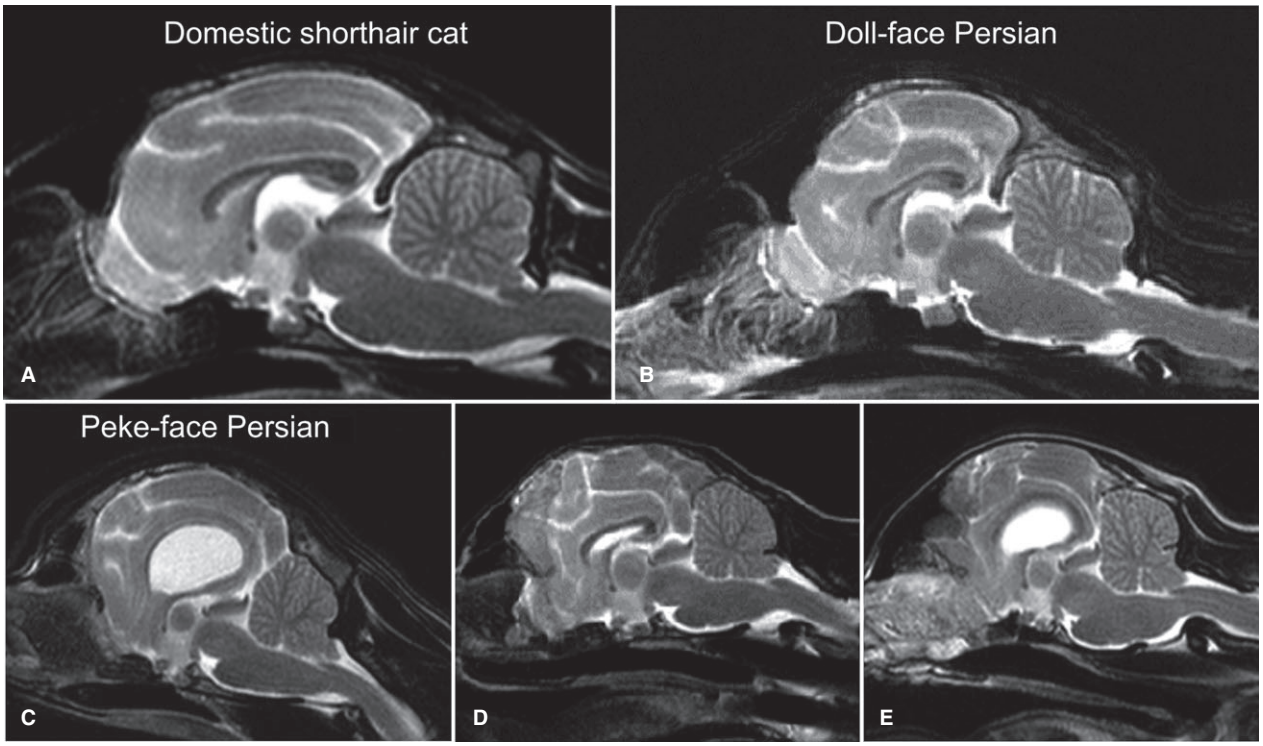

Fig 7. Changes in brain morphology. Midsagittal T2-weighted MR-images of a domestic shorthair cat (**A**: 5 years old, female), a doll-face Persian cat (**B**: 2 years old, female), and peke-face Persian cats (**C**: 5 years old, female; **D**: 2 years old, female; **E**: 2 years old, male). With reduction in the skull length a gradual push back of the conchal bones toward the cranial cavity can be seen. The frontal sinuses are more and more reduced. The frontal lobes are compressed.

between groups ($P < 0.001$). The mean cranial index of the peke-face Persians (0.97 ± 0.14) was significantly higher than the mean cranial index in DSH (0.63 ± 0.06; $P < 0.001$) and the mean cranial index of doll-face Persians (0.66 ± 0.04; $P < 0.001$). There was no significant difference between DSH and doll-face Persians.

The nose index was significantly different among all three groups ($P < 0.001$). Peke-face Persians had a lower relative nasal bone length (0.15 ± 0.04) compared to doll-face (0.29 ± 0.08; $P < 0.001$) and DSH (0.46 ± 0.03; $P < 0.001$). The nose index and cranial index were significantly correlated ($P < 0.0001$, Spearman's r: 0.75).

The percentage of endocranial volume occupied by the brain was significantly lower in DSH (mean $88.17 \pm 0.95\%$) than in both other groups ($P < 0.001$). Doll-face Persians had a significantly lower percentage than peke-face Persians ($89.6 \pm 1.27\%$ versus $91.76 \pm 2.07\%$; $P < 0.001$). The cranial index was significantly correlated with this parameter (Spearman's r: 0.7; $P < 0.0001$).

The relative interorbital distance was significantly different between all groups ($P < 0.0001$). The mean of the relative interorbital distance of the DSH (0.15 ± 0.008) was significantly lower than doll-face Persians (0.19 ± 0.02; $P < 0.001$) and peke-face Persians (0.28 ± 0.03; $P < 0.001$). The relative interorbital distance was also different between the two Persian groups ($P < 0.001$), revealing a larger interorbital distance in peke-face cats.

The relative height of the foramen magnum was significantly larger in peke-face Persians (0.56 ± 0.06) compared to both other groups (doll-face 0.45 ± 0.02; $P < 0.001$; DSH 0.42 ± 0.02; $P < 0.001$). Significant differences between doll-face Persians and DSH could not be found.

Ventricular Dimensions

ANOVA revealed a global difference between groups ($P < 0.0001$). Multiple group comparisons did not reveal a difference between DSH and doll-face Persians. However, mean ventricle: Brain ratio of the peke-face group (0.159 ± 0.14) was significantly higher (i.e. larger relative ventricular volumes) compared to doll-face Persians (0.015 ± 0.01; $P < 0.001$) and DSH (0.017 ± 0.004; $P < 0.001$). The cranial index and ventricle: Brain ratio were correlated (Spearman's $r = 0.51$; $P < 0.0001$).

Gray Matter and White Matter Volumes

Except for the GM, the residual mean square for the regression between the other variables and the body weight was significantly higher for the peke-face Persians ($P = 0.0015$ or lower). Gray matter was clearly related to body weight over all groups ($P < 0.0001$).

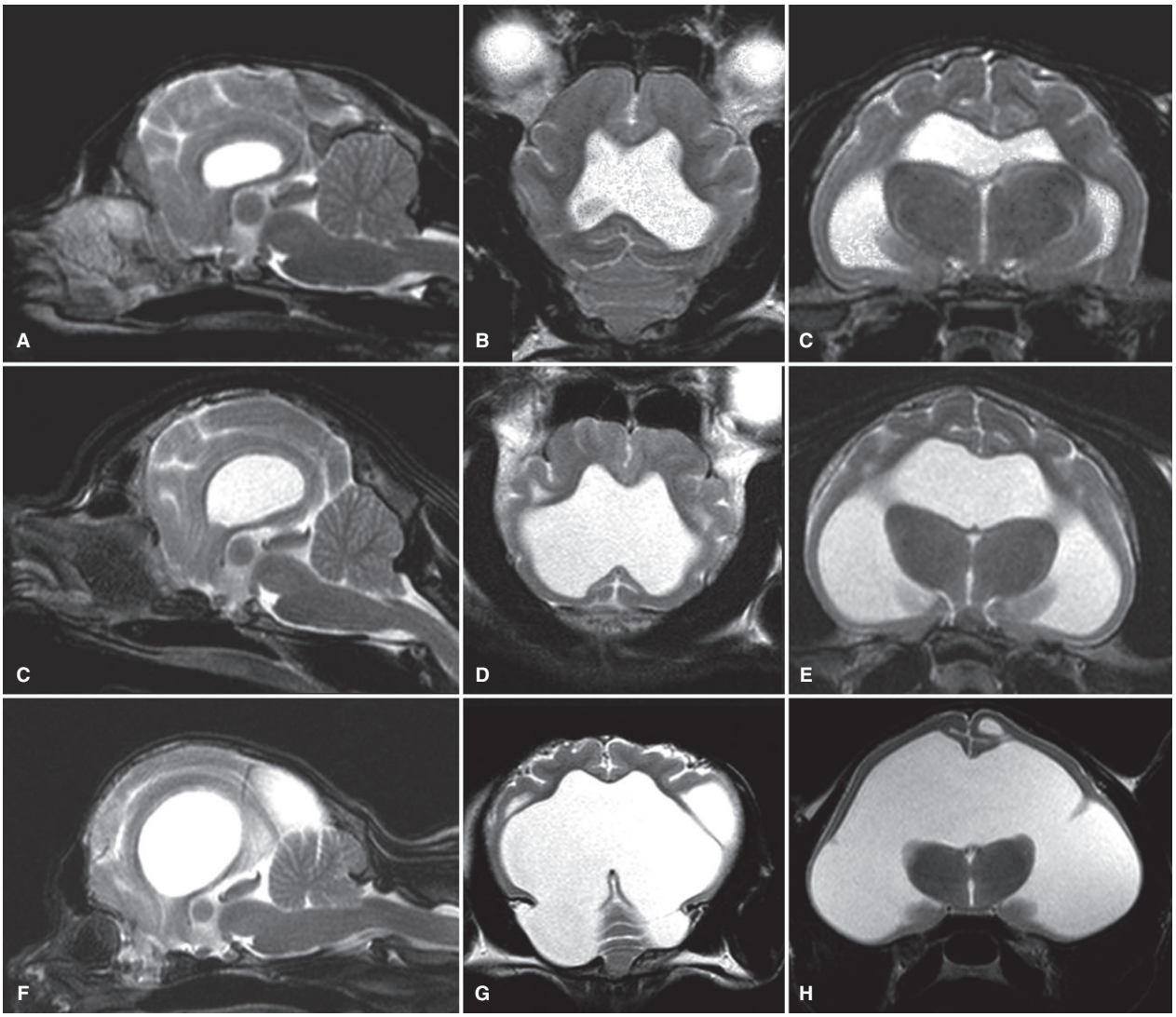

Fig 8. Enlarged ventricular dimensions in peke-face Persians. MRI midsagittal **(A, D)**, dorsal **(B, E)**, and transversal **(C, F)** T2-weighted MR-images of three peke-face Persians (**A, B**: 2 years old, female; **B, C**: 5 years old male; **C, D**: 2 years old, female). Images reveal severe dilatation of the lateral ventricles, reduction, and destruction of the cerebral parenchyma, as well as severe cerebellar herniation into the vertebral canal.

For this variable, the slopes between groups were not significantly different ($P = 0.564$) allowing comparison of the groups using a common slope. After adjusting the GM to body weight, the resulting means were not significantly different between the two Persian types (13.88 ± 0.194 versus 13.64 ± 0.11; $P = 0.30$).

Because the statistical distribution of the CSF volume was skewed to the right, data were logarithmically transformed to get nearly normal distribution. The relation to the body weight given by slopes was inhomogeneous between the groups. Although the common slope was not significantly different from zero ($P = 0.093$) this was considered an indication of a possible dependency, and adjusted geometric means were calculated with individual slopes for each group, adjusted to the mean body weight of 3.0 kg. Peke-face Persians had a significantly higher adjusted geometric mean of the brain ventricle ratio (geometric mean: 0.055 versus 0.011; $P < 0001$).

Similarly, the adjusted means of the cerebral WM showed a significantly lower volume in peke-face Persians (3.06 cm^3) compared to doll-face Persians (3.88 cm^3; $P < 0.0001$). The same holds for the adjusted means of the WM/GM ratio, which was significantly lower in peke-face Persians (0.226 versus 0.282; $P = 0.0001$). Therefore, the model predicts that at the same bodyweight peke-face Persians with oversized ventricles have less WM than doll-face Persians with subjectively normal lateral ventricles.

Discussion

The results of this study show that the increasing emphasis on a brachycephalic phenotype can have a correlating negative impact on general skull- and brain morphology in Persian cats. In the modern peke-face type, the increased reduction of the nose is associated

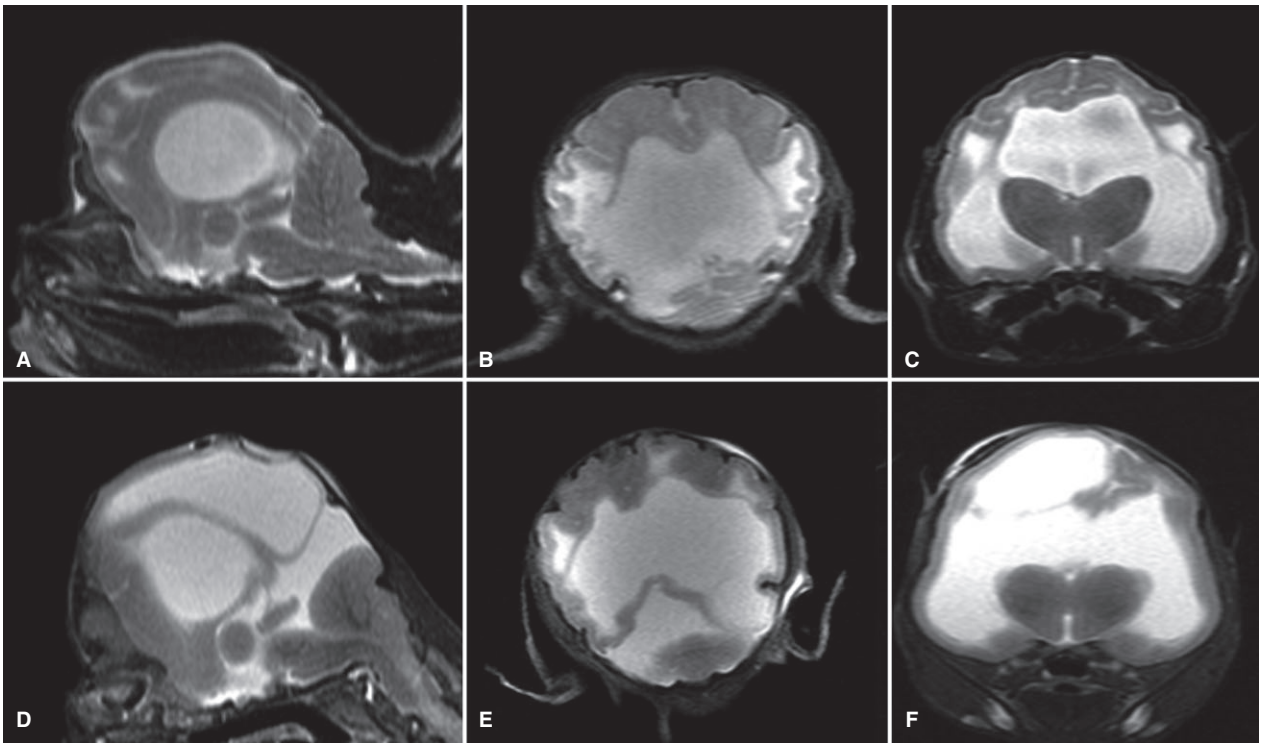

Fig 9. MRI of euthanized peke-face kittens. The MR-Images show internal hydrocephalus with periventricular edema/cavitations, supracollicular fluid accumulation, and severe cerebellar herniation (Both 3 weeks old, female).

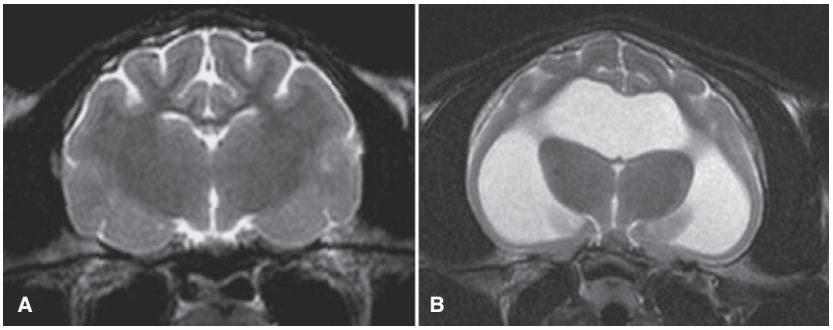

Fig 10. MRI of the brain in domestic shorthair cats (DSH) and peke-face Persian. The MR-images show the physiologic dimensions of the lateral cerebral ventricles in a domestic shorthair cat (4 years old, female, **A**) and peke-face Persian cat (4 years old, male, **B**).

with a number of severe facial, dental, and neurocranial abnormalities. We found that with increased reduction of the facial bones, the deformation of the neurocranium increases as well, suggesting a functional link in cranial and facial development. The reduction in longitudinal extent and the increased width of the braincase was also clearly correlated with a reduced cranial capacity, and internal hydrocephalus in some cases with a more severe clinical outcome.

Our data obtained from examination of computerized 3D models are in agreement with measurements on feline dry skulls (DSH) that showed comparable results for certain cranial parameters.[29,30] Validity of these data can be assumed. Volumetric measurements of the delicate brain tissues (WM and GM) based on MRI datasets may not have the same accuracy compared to elaborate histologic investigations. However, the accuracy of the technique has been confirmed even for small volumes.[31–34] Segmentation procedures can be subject to investigator bias, which is the main limitation of the present study. The validity of our results might have increased further with repeated determination of WM and GM, but we refrained from the determination of interobserver-variability as the manual segmentation process is extremely time consuming. The WM and GM volume were determined based on MRI images. The majority of the doll-face Persians were recruited retrospectively. Magnetic resonance images of these animals were not available, which is why only thirteen doll-face cats could be examined compared to 42 peke-face

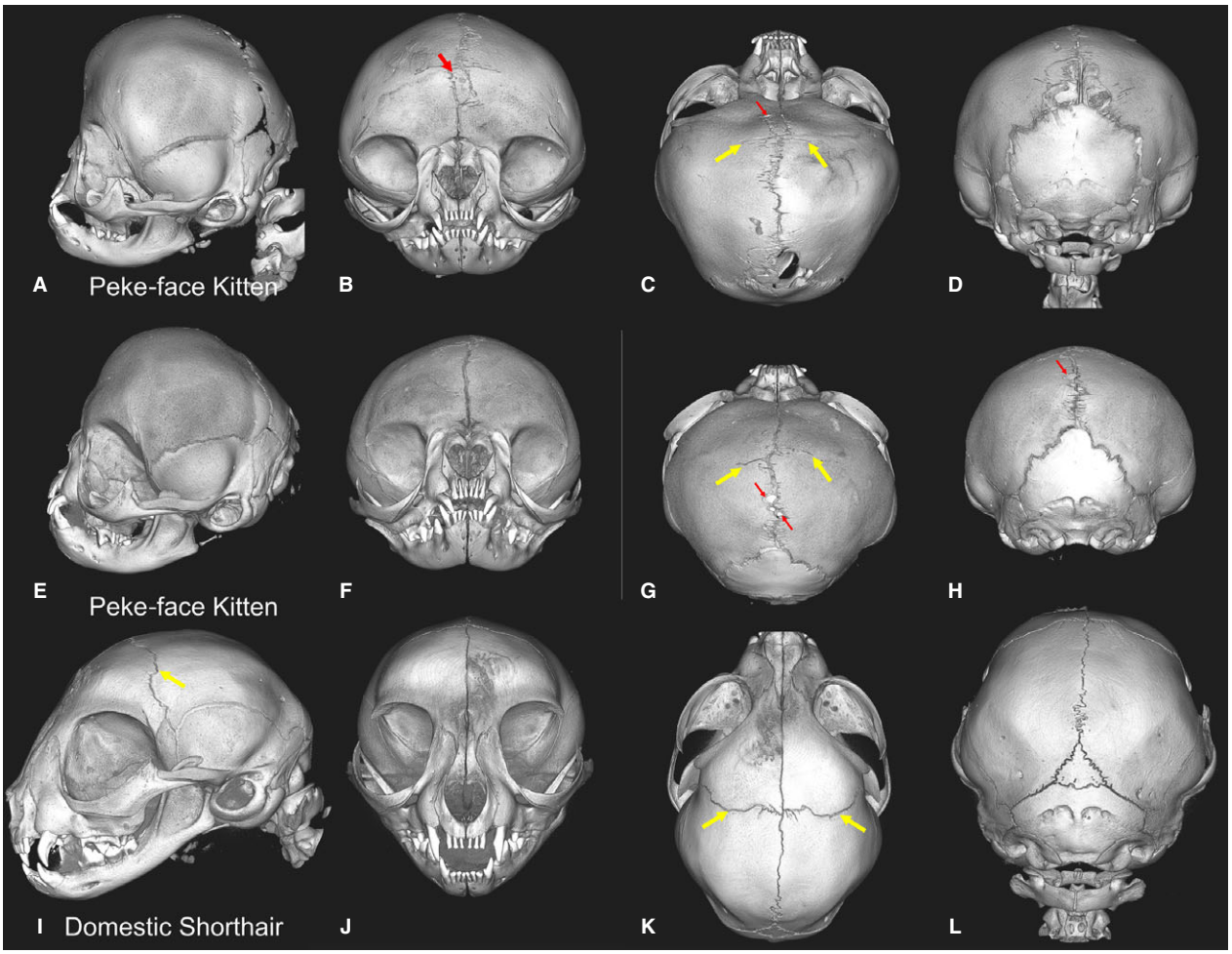

Fig 11. Micro -CT examination and volume rendering. Three-dimensional skull models of four 4- to 5-week-old peke-face kittens **(A–H)** are shown compared to a 6-week-old domestic shorthair kitten **(I-L)**. The yellow arrows indicate the position of the coronal suture, the red arrows mark bony islands within the sutures ("wormian bones").

Persians. However, differences between groups were highly significant indicating sufficient statistical power.

The results of this study suggest that the difference in endocranial volume between the two Persian groups may be due to the general modification of the skull. However, brain expansion associated with dilated ventricles may have also led to decreased free space inside the cranial cavity. Signs of increased intraventricular pressure that have been defined for dogs[35] could also be seen in the Persian cats. The cranial capacity in peke-face Persians might therefore be falsely reduced due to actual brain expansion.

Breeders might assume that brachycephalic facial features are accentuated characteristics of a physiologic spectrum of head morphology. This is in contrast to the scientific insights of human pediatrics, where brachycephaly is a not seen as a normal facial characteristic. Brachycephaly is instead known as a clinical symptom indicative of fundamental cranial dysmorphology associated with various genetic diseases (Crouzon-, Apert, Muenke-, Pfeiffer-, and Saethre-Chotzen-syndrome).[36–38] All of these syndromes are based on premature closure of calvarial sutures. Functional impairment of the coronal sutures results in reduced longitudinal and increased cranial growth in affected children. Due to the interrelationship of skull base growth and suture growth,[39] coronal craniosynostosis also influences growth of the synchondroses of the skull base, and in turn, growth of the facial bones.[40] Shortening and involution of the whole infraorbital region (midfacial retrusion or hypoplasia) occurs as a consequence of the stunted growth and caudal displacement of the conchal and nasal bones. The increased flatness of the face and the pronounced nasolabial angle represents the underdevelopment of the maxillary bones.[41] This in turn causes a short and upwards projecting alveolar ridge leading to dental malalignments.[42] Asymmetric orbits and foreheads as well as lateral deviation of the nose and maxilla revealed in the face of patients with craniosynostosis are due to unilateral closure of the growth centers.[42] Around 50% of children with craniosynostosis have ventricular distension and/or clinically overt internal hydrocephalus.[4,16,17,43]

The cranial phenotype in these patients and the associated brain changes have striking similarities to our findings in Persian cats. Based on these similarities and the findings of absent coronal sutures in the young peke-face kittens, we propose that the skull conformation of the peke-face Persian can be seen as a feline form of coronal craniosynostosis. It has already been demonstrated that the premature closure of cranial growth centers has a major impact on the morphology of the face and neurocranium in brachycephalic dogs. A correlation between patterns of suture- and synchondrosis- closure and the development of brachycephalic skulls in domestic dogs has been found in morphologic examinations of dry skulls[44] and also in MRI investigations.[45]

Recently, the genetic basis for brachycephaly in Persian cats was investigated, and two candidate genes have been identified: CNTN6 and CHL1.[46] The latter encodes for a protein that is a member of the immunoglobulin superfamily of neuronal cell adhesion molecules (L1 cell adhesion molecule, L1CAM). Interestingly, it has been shown that the functional gene products, especially from L1CAM, interact with fibroblast growth factor receptors (FGFRs) in human suture regulation.[47] As defects of this receptor family are causal to many forms of craniosynostoses,[47] it is possible that the cranial dysmorphology in Persians is related to a gradual impairment of physiologic interaction of suture regulating proteins such as L1CAM with FGFRs or others.

The different ventricular volumes between the cat breeds were consistent. A third of the peke-face Persians had clinically overt internal hydrocephalus, and other clinically normal cats showed different stages of ventriculomegaly. The causative mechanism for the development of ventricular enlargement is not clear. Interestingly all peke-face Persians showed biventricular enlargement confined to the lateral cerebral ventricles. The third and fourth ventricle were never affected. Mechanic outflow obstruction at the craniocervical junction may therefore be called into question. In addition, cerebellar herniation was not present in all of the cats in the peke-face group. Magnetic resonance imaging showed a patent mesencephalic aqueduct in all cases. When a third ventricle is normal in size, outflow obstruction to the mesencephalon seems unlikely.

Interestingly apart from the euthanized kittens, neurologic signs were often mild or absent in the affected cats. It is reasonable to expect that the degree of intraventricular pressure determines the speed and severity of white matter injury and thereby functional brain deficits. Moderately increased pressure or intermittently high intraventricular CSF pressure might play an important role in the pathogenesis of WM loss in the Persians with ventriculomegaly as proposed for dogs.[26] Clinical neurologic examination only assesses limited functions of the nervous system in animals. Signs of cognitive impairment are difficult to diagnose in cats, at least not in a clinical setting. Upon request, breeders and owners often describe their cats as "dummies", sometimes running into objects or falling from the windowsill. They are often uninterested in playing and have reduced social interactions with other cats and with the owner, which might imply more neurologic deficits than initially detectable. However, behavioral studies are necessary to prove the actual degree of feline cognitive abilities.

Brainstem auditory evoked response (BAER) was not performed in the cats that did not react on auditory stimuli, which is why congenital deafness cannot be ruled out. However, sensorineural deafness is usually associated with white coat- and blue eye-color in cats, and only one of the cats with hearing deficits was white and its eyes had copper color.

Conclusion

Appearance-oriented breeding in Persian cats emphasizing the brachycephalic head morphology can also lead to the occurrence of severe skull and brain abnormalities in this breed. Breeders and cat fanciers must face the fact that desired phenotypic traits in these cats would be considered a severe developmental abnormality in humans. The selection for extreme forms of brachycephaly must be reconsidered.

Footnotes

[a] Gyroscan Intera, Phillips, Hamburg, Germany
[b] CT Brilliance, Philips, Hamburg, Germany
[c] Bruker microCT, Kontich, Belgium
[d] ANALYZE 12, Mayo Clinic, Rochester, MN
[e] Mercury Computers Systems, Berlin, Germany

Author Contributions

MJS, NO, MK, Conceived and designed the experiments; NO, RH, SG, MKO, Performed the experiments; MJS, RH, KF, Analyzed the data; MJS, MK, SG, DG, JL, EL, AF, AML, Contributed reagents/materials/analysis tools; MJS, NO, Wrote the paper.

Acknowledgments

Conflict of Interest Declaration: Authors declare no conflict of interest.

Off-Label Antimicrobial Declaration: Authors declare no off-label use of antimicrobials.

References

1. Morris D. The Cat Breeds of the World. A Complete Illustrated Encyclopedia. New York: Viking Penguin; 1999.
2. Wastlhuber J. History of domestic cats and cat breeds. In: Pederson NC, ed. Feline Husbandry. Goleta, CA: American Veterinary Publications INC; 1991:1–59.
3. cfa.org/Portals/0/documents/breeds/standards/persian.pdf
4. Farnworth MJ, Chen R, Packer RMA, et al. Flat feline faces: Is brachycephaly associated with respiratory abnormalities in the domestic cat (Felis catus)? PLoS ONE 2016;11:e0161777.

5. Schlueter C, Budras KD, Ludewig E. Brachycephalic feline noses. CT and anatomical study of the relationship between head conformation and the nasolacrimal drainage system. J Feline Med Surg 2009;11:891–900.

6. Malik R, Sparkes A, Bessant C. Brachycephalia–a bastardisation of what makes cats special. J Feline Med Surg 2009;11:889–890.

7. Monfared AL. Anatomy of the Persian cat's skull and its clinical value during regional anesthesia. Global Veterinaria 2013;10:551–555.

8. Müller-Girard C. Lexikon der Rasse Katzen. Eltville am Rhein, German: Bechter-Munz; 1988

9. Widmann-Acanal B. Rasseneffekte auf Fortpflanzungs- und Welpenab gangsrate bei Hunden unter gleichzeitiger Berücksichtigung rassebedingter Dystokie dispositionen bei einigen Hunde- und Katzenrassen. Thesis in Veterinary Medicine, Tierärztliche Hochschule Hannover, German; 1992

10. Prescot CW. Reproduction patterns in the domestic cat. Austr Vet J 1973;49:126–129.

11. Gunn-Moore DA, Thrusfield MV. Feline dystocia: Prevalence, and association with cranial conformation and breed. Vet Rec 1995;136:350–353.

12. Perlyn CA, DeLeon VB, Babbs C, et al. The craniofacial phenotype of the Crouzon mouse: Analysis of a model for syndromic craniosynostosis using three-dimensional MicroCT. Cleft Palate Craniofac J 2006;43:740–748.

13. Bloom MW, Murakami S, Cody D, et al. Aspects of achondroplasia in the skulls of dwarf transgenic mice: A cephalometric study. Anat Rec A Discov Mol Cell Evol Biol 2006;288:316–322.

14. Gordon N. The neurological complications of achondroplasia. Brain Develop 2000;22:3–7.

15. Horton WA, Hall JG, Hecht JT. Achondroplasia. Lancet 2007;370:162–172.

16. Collmann H, Sörensen N, Krauss J. Hydrocephalus in craniosynostosis: A review. Childs Nerv Syst 2005;21:902–912.

17. Cinalli G, Sainte-Rose C, Kollar EM, et al. Hydrocephalus in craniosynostosis. J Neurosurg 1998;88:209–214.

18. Biel M, Kramer M, Forterre F, et al. Outcome of ventriculoperitoneal shunt implantation for treatment of congenital internal hydrocephalus in dogs and cats: 36 cases (2001–2009). J Am Vet Med Assoc 2013;242:948–958.

19. de Stefani A, de Risio L, Platt SR, et al. Surgical technique, postoperative complications and outcome in 14 dogs treated for hydrocephalus by ventriculoperitoneal shunting. Vet Surg 2011;40:183–191.

20. Shihab N, Davies E, Kenny PJ, et al. Treatment of hydrocephalus with ventriculoperitoneal shunting in twelve dogs. Vet Surg 2011;40:77–84.

21. Selby LA, Hayes HM Jr, Becker SV. Epizootiologic features of canine hydrocephalus. Am J Vet Res 1979;40:411–413.

22. Thomas B. Hydrocephalus in dogs and cats. Vet Clin Small Anim 2010;40:143–159.

23. Regodón S1, Vivo JM, Franco A, et al. Craniofacial angle in dolicho-, meso- and brachycephalic dogs: Radiological determination and application. Ann Anat 1993;175:361–363.

24. Stockard CR. The Genetic and Endocrinic Basis for Differences in Form and Behavior. Philadelphia: Wistar Institute of Anatomy and Biology; 1941.

25. Schmidt MJ, Neumann AC, Amort KH, et al. Cephalometric measurements and determination of the general skull type of Cavalier King Charles Spaniels. Vet Radiol Ultrasound 2011;52:436–440.

26. Schmidt MJ, Laubner S, Kolecka M, et al. Comparison of the relationship between cerebral white matter and grey matter in normal dogs and dogs with lateral Ventricular enlargement. PLoS ONE 2015;4:e0124174.

27. Schmidt MJ, Amort KH, Failing K, et al. Comparison of the endocranial- and brain volumes in brachycephalic dogs, mesaticephalic dogs and Cavalier King Charles spaniels in relation to their body weight. Acta Vet Scand 2014;56:30.

28. Zhang K, Sejnowski TJ. A universal scaling law between gray matter and white matter of cerebral cortex. Proc Natl Acad Sci USA 2000;97:5621–5626.

29. Stacharski M, Pęzińska K, Wróblewska M, et al. The biometric characteristics of domestic cat skull in three stages of growth: Juvenile, subadult and adult. Acta Sci Pol Zootechnica 2010;9:65–78.

30. Uddin M, Sarker MHR, Hossain ME, et al. Morphometric investigation of neurocranium in domestic cat (Felis catus). Bangl J Vet Med 2013;11:69–73.

31. Vullo T, Deo-Narine V, Stallmeyer MJ, et al. Quantitation of normal canine hippocampus formation volume: Correlation of MRI with gross histology. Magn Reson Imaging 1996;14:657–662.

32. Milne ME, Anderson GA, Chow KE, et al. Description of technique and lower reference limit for magnetic resonance imaging of hippocampal volumetry in dogs. Am J Vet Res 2013;74:224–231.

33. Thames R, Robertson ID, Flegel T, et al. Development of a morphometric magnetic resonance image parameter suitable for distinguishing between normal dogs and dogs with cerebellar atrophy. Vet Radiol Ultrasound 2010;51:246–253.

34. Rifa H, Bloch I, Hutchinson S, et al. Segmentation of the skull in MRI volumes using deformable model and taking the partial volume effect into account. Med Image Anal 2000;4:219–233.

35. Laubner S, Ondreka N, Failing K, et al. Magnetic resonance imaging signs of high intraventricular pressure-comparison of findings in dogs with clinically relevant internal hydrocephalus and asymptomatic dogs with ventriculomegaly. BMC Vet Res 2015;1:181.

36. Morriss-Kay GM, Wilkie AO. Growth of the normal skull vault and its alteration in craniosynostosis: Insights from human genetics and experimental studies. J Anat 2005;207:637–653.

37. Rice DP, Rice DPC. Craniofacial anomalies: From development to molecular pathogenesis. Cur Mol Med 2005;5:699–722.

38. Kimonis V1, Gold JA, Hoffman TL, et al. Genetics of craniosynostosis. Semin Pediatr Neuro 2007;14:150–161.

39. Kreiborg S. Postnatal growth and development of the craniofacial complex in premature craniosynostosis. In: Cohen MM Jr, ed. Craniosynostosis Diagnosis, Evaluation, and Management. New York: Raven; 1986.

40. Dixon AD, Hoyte DAN, Ronning O. Fundamentals of Craniofacial Growth. Boca Raton: CRC Press; 1997.

41. Allanson JE, Cunniff C, Hoyme HE. Elements of morphology: Standard terminology for the head and face. Am J Med Genet A 2009;149:6–28.

42. Akram A, McKnight MM, Bellardie H, et al. Craniofacial malformations and the orthodontist. Br Dent J 2015;218:129–141.

43. deJong T, Rijken BFM, Lequin MH, et al. Brain and ventricular volume in patients with syndromic and complex craniosynostosis. Childs Nerv Syst 2012;28:137–140.

44. Geiger M, Haussman S. Cranial suture closure in domestic dog breeds and its relationships to skull morphology. Anat Rec (Hoboken) 2016;299:412–420.

45. Schmidt MJ, Volk H, Klingler M, et al. Comparison of closure times for cranial base synchondroses in mesaticephalic, brachycephalic, and Cavalier King Charles Spaniel dogs. Vet Radiol Ultrasound 2013;54:497–503.

46. Bertolini F, Gandolfi B, Kim ES, et al. Evidence of selection signatures that shape the Persian cat breed. Mamm Genome 2016;27:144–155.

47. Teven CM, Farina EM, Rivas J, et al. Fibroblast growth factor (FGF) signaling in development and skeletal diseases. Genes Dis 2014;1:199–213.

Supporting Information

Additional Supporting Information may be found online in the supporting information tab for this article:

Figure S1. Volumetric skull and brain measurements. Frontal (A) and lateral (B) view of a 3D model of a peke-face Persian skull in a transparent mode allowing visualization of the brain parenchyma (yellow tissue). Total brain volume, cranial capacity, and ventricular volume (gray volume, C) were determined.

Table S1. Summary of all measured variables in the Persian cats and Domestic Shorthairtcats