

**Comparative TP53 targeted next generation sequencing
analysis as a diagnostic tool for determining lung tumor
origin in patients with head and neck squamous cell
carcinoma and synchronous / metachronous squamous cell
lung carcinoma**

Inaugural dissertation

for obtaining the Degree of Doctor of Medicine
of the faculty of medicine
of the Justus-Liebig-University Gießen

submitted by
Daher, Tamás
from Pécs, Hungary

Gießen 2018

From the Institute of Pathology
of the faculty of medicine
of the Justus-Liebig-University
Director: Prof. Dr. Stefan Gattenlöhner

Reviewer 1: Prof. Dr. Stefan Gattenlöhner

Reviewer 2: Prof. Dr. Leander Ermert

Day of disputation: 25.10.2018

TABLE OF CONTENTS

1. INTRODUCTION	5
1.1. EPIDEMIOLOGY, ETHIOLOGY AND PATHOGENESIS OF SQUAMOUS CELL CARCINOMA OF THE HEAD AND NECK AND SQUAMOUS CELL CARCINOMA OF THE LUNG	6
1.1.1. Head and neck squamous cell carcinoma.....	6
1.1.1.1. Epidemiology and ethiology	6
1.1.1.2. TP53 mutations and mutation landscape.....	7
1.1.1.3. The role of the human papillomavirus	8
1.1.2. Squamous cell carcinoma of the lung	9
1.1.2.1. Epidemiology and ethiology	9
1.1.2.2. Mutations in squamous cell lung cancer	10
1.2. MORPHOLOGICAL AND IMMUNOHISTOCHEMICAL ASPECTS IN SQUAMOUS CELL CARCINOMA	10
1.3. THERAPEUTIC CONSIDERATIONS AND SURVIVAL RATES	11
1.3.1. Therapy of squamous cell carcinoma of the head and neck	11
1.3.2. Therapy of squamous cell carcinoma of the lung.....	12
1.4. AIMS OF THIS STUDY.....	14
2. MATERIALS AND METHODS	15
2.1. MATERIALS.....	15
2.2. METHODS.....	18
2.2.1. Patients	18
2.2.2. Histopathology	18
2.2.3. DNA isolation	19
2.2.4. Concentration determination of the DNA.....	19
2.2.5. p16 immunohistochemistry	19
2.2.6. HPV typing	20
2.2.7. Targeted next generation sequencing of the TP53 exones	22
2.2.7.1. Preparation of the DNA library	22
2.2.7.2. Clonal amplification.....	25
2.2.7.3. Sequencing reaction	27
2.2.7.4. Analysis of targeted next generation sequencing data.....	28
2.2.8. Assessment	28
3. RESULTS.....	30
4. DISCUSSION	39
5. SUMMARY	43
6. SUMMARY (GERMAN VERSION).....	44
7. LIST OF TABLES	45

8. LIST OF FIGURES	46
9. LIST OF ABBREVIATIONS	47
10. LITERATURE	48
11. BIBLIOGRAPHY	49
12. LIST OF PUBLICATIONS AND CONGRESS CONTRIBUTIONS	60
13. ACKNOWLEDGEMENTS	62
14. AFFIRMATION	63

1. Introduction

Head and neck squamous cell carcinoma (HNSCC) is a malignant epithelial disease arising from the mucosa of the upper aerodigestive tract. It is the 6th most common malignancy worldwide with approximately 650 000 new cases diagnosed each year (Torre et al. 2015; Ferlay et al. 2010). It can be localised in different anatomical sites of the head and neck region (oral cavity, oropharynx, nasopharynx, larynx and occasionally in the paranasal sinuses) (Barnes, World Health Organization, and International Agency for Research on Cancer 2007). Current therapy consists of surgical resection or radiation therapy or a combination of these methods (Sweeney et al. 1994), but to date survival rates remain relatively low, with a 5-year survival rate of around 30-40% (Vokes et al. 1993).

In patients with HNSCC in the anamnesis, the chance of acquiring a second malignancy in the lung is about 5.4% according to a study carried out on 3907 patients (Atabek et al. 1987). The differentiation between a lung metastasis of a HNSCC and a second primary squamous cell carcinoma of the lung (LSCC) remains one of the most difficult tasks in diagnostic pathology, although differentiation would be crucial because of the highly different therapeutic regimes in the patient groups. In most cases traditional morphological-immunohistochemical examinations fail to find the origin of the lung tumor, so that a reliable method of differentiation is desperately needed.

The most well-known risk factors of HNSCC are tobacco and alcohol consumption and the prevalence of mutations of the TP53 gene is traditionally high in these tumors (Kropveld et al. 1999).

However, recent research has shown that differentiation has to be made between two major types of HNSCC; HPV-associated and non-HPV-associated tumors. An increasing amount of HNSCC is associated with high risk HPV-serotypes (HPV-16, 18, 31, 33, etc.). About 40-80% of HNSCC is associated with HPV-16 in the USA and 20-90% is associated with high risk HPV in Europe (Marur et al. 2010a). HPV-associated HNSCC is traditionally not TP53 mutated (Westra et al. 2008), whereas in HPV negative HNSCC, TP53 mutations can be found in most of the cases (Kropveld et al. 1999).

Researchers have tried to differentiate between lung metastasis and second primary lung tumor comparing HPV-status of the head and neck tumor and the lung tumor. This approach seems to be successful in some of the cases (Weichert et al. 2009; Bishop et al. 2012). However, in cases of HPV negativity in both tumors, additional methods

should be considered. Further studies have described a number of comparative molecular methods to find out the origin of the lung tumor (these will be discussed in detail in this work later on), but an universally accepted method has not yet been presented.

In the past few years, next generation sequencing technology has been established worldwide and also in our institute of pathology. With this technology it became easier and faster to analyse mutations of the TP53 gene (or other genes of interest) and to find out tumor origin of squamous cell carcinomas by sequencing of the TP53 exons. This method has the advantage, that mutations of all coding exons of the TP53 gene can be examined in a very time-effective high-throughput way. We hypothesised, that comparing the mutations of the HNSCC and LSCC can lead to a decision on lung tumor origin.

The aim of this study was to analyse patients with HNSCC and synchronous/metachronous LSCC to decide on lung tumor origin using a combination of HPV-typing and targeted next generation sequencing of all coding exons of the TP53 gene. We analysed a total 32 cases to try and make a decision on lung tumor origin. Furthermore, we analysed clinical records and therapeutic data to see, in what way this diagnostic method might contribute to diagnostic precision and clinical decision making.

1.1. Epidemiology, etiology and pathogenesis of squamous cell carcinoma of the head and neck and squamous cell carcinoma of the lung

1.1.1. Head and neck squamous cell carcinoma

1.1.1.1. Epidemiology and etiology

Head and neck squamous cell carcinoma is the 6th most common malignancy worldwide responsible for more than 650 000 annual newly diagnosed cases and 300 000 annual deaths (Parkin et al. 2005). Localisation of the tumors may be different (oral cavity, oropharynx, nasopharynx, larynx and occasionally in the paranasal sinuses) and localisation of the tumor is a relevant factor influencing survival rates.

Traditional risk factors of HNSCC include genetic risk factors, poor oral hygiene, as well as tobacco and alcohol consumption. Traditional HNSCC is associated with mutations of the TP53 gene.

Recent research has shown though, that human papilloma virus infections are responsible for the disease in an increasing proportion of the cases. HPV has more than 100 serotypes, which can be categorised in low risk (6, 11, 40, etc.) and high risk (16, 18, 31, 33, etc.) serotypes and it has a well-known pathogenetic role in anogenital cancer, being probably most well-known for its role in the cervical cancer of the uterus. In HPV-associated cases, typically younger white men at the age of 40-50 years are affected, who have no tobacco or alcohol consumption in their anamnesis (Marur et al. 2010b).

TP53 mutations and HPV-association are mutually exclusive in HNSCC in the majority of the cases (Westra et al. 2008).

1.1.1.2. TP53 mutations and mutation landscape

The p53 protein is possibly one of most frequently and longest studied proteins in the history of cancer research. It is also called the *guardian of the genome* and is responsible for many essential cell functions like DNA-synthesis and DNA-repair, cell cycle arrest and programmed cell death, as well as energy metabolism. It is the product of the TP53 gene.

The TP53 gene is located on the short arm of chromosome 17 in humans (Matlashewski et al. 1984), it has 11 exons of which exon 2-11 are protein coding. Most mutations of the gene appear on exon 5-8, coding the DNA binding domain of the p53 protein (Greenblatt et al. 1994), but according to literature, about 25% of the mutations can be found outside of these exons. Thus some authors suggest, that TP53 analysis should be carried out on all coding exons when searching for mutations (Hartmann et al. 1995).

Mutations of the TP53 gene are mostly 'small mutations' (missense and nonsense mutations, as well as deletions or insertions of more nucleotides) (Perri et al. 2015), as well as the recently reported and poorly understood gain of function mutations (Donzelli et al. 2008). It has been pointed out, that immunohistochemical reactions for the diagnosis of TP53 mutations are insufficient and they can lead to confusions (MacGeoch et al. 1993; Calzolari et al. 1997). Consequently, when analysing TP53 mutations, molecular genetic methods should be preferred over immunohistochemistry.

It has been shown in recent whole exome sequencing experiments, that adherent to the already known frequently mutated genes in HNSCC (TP53, HRAS, PTEN, PIK3CA,

CDKN2A etc), other genes, like TP63, NOTCH1 and FBXW7 might play an important role (Stransky et al. 2011; Agrawal et al. 2011).

Some of the patients with HNSCC develop further carcinomas in the head and neck region and it has been suggested, that these tumors are clonally different from the primary head and neck carcinoma, containing different genetic alterations. This phenomenon is described by the 'field cancerisation' theory, and suggests, that patients with such tumors have a high risk of developing tumors in the upper aerodigestive mucosa because of extensive mucosal damage. The tumors are described as independent events (Savary et al. 1991) and it has been pointed out, that patients with two primary tumors in their patient history have about 50% chance to develop a 3rd head and neck tumor (Savary et al. 1991).

1.1.1.3. The role of the human papillomavirus

The human papillomavirus has more than 100 serotypes, which can be categorised in low risk (6, 11, 40, etc.) and high risk (16, 18, 31, 33, etc.) serotypes. The role of HPV is well known in cervical cancer, but according to recent publications, the number of HPV-positive HNSCC compared to traditional HNSCC caused by tobacco and alcohol consumption, has been increasing rapidly.

At the molecular level, HPV infection leads to the degradation of the p53 protein and the inactivation of the retinoblastoma pathway as well as to an upregulation of the p16 protein. The virus first integrates in the human DNA and causes dysregulation with two proteins named E6 and E7. The E6 protein leads to the ubiquitin-mediated proteolysis of the p53 protein, whereas E7 binds to pRB, a product of the retinoblastoma tumor suppressor gene and inactivates it (Wiest et al. 2002). The p53 protein leads to cell cycle arrest or apoptosis in case of a transcriptional mistake, unless the DNA is repaired. Degradation of this protein inevitably leads to genomic instability. Furthermore, the E7 protein inactivates pRB and it causes the cell to enter into the S-phase and thus causes uncontrolled proliferation and malignant transformation of the cell (Wiest et al. 2002).

There is an essential need for routine testing of HPV-positivity in HNSCC, because of the better prognosis of HPV-positive tumors. However, finding an appropriate method for testing is not self-evident. There are multiple possible methods, as type-specific PCR-methods, in situ DNA hybridisation methods, real-time PCR methods or p16

immunohistochemistry. According to literature a combination of p16 immunohistochemistry (100% specificity) and HPV in situ hybridization (nearly 100% sensitivity) leads to highly accurate information on HPV-association (Marur et al. 2010).

1.1.2. Squamous cell carcinoma of the lung

1.1.2.1. Epidemiology and ethiology

According to the definition of the World Health Organisation, '*squamous cell carcinoma (SCC) is a malignant epithelial tumor showing keratinization and/or intercellular bridges that arises from bronchial epithelium*' (Travis et al. 2004). In men 44%, whereas in women 25% of lung cancer is squamous cell carcinoma. In 2012 more than 1.6 million deaths were caused by lung cancer and expectations are, that this number grows to 3 million by 2035. Although a century ago, cancer of the lung was extremely rare, now it is the most frequent cause of death of all cancers (Didkowska et al. 2016).

Numerous risk factors have been inquired (asbestos, nickel, coal-tars, dioxin, etc.) in connection with lung cancer, but their effects are not to be compared with the most important risk factor of all, tobacco smoking. Decline of mortality and incidence has started in some countries (UK, USA, etc.) in the 1970s but some other countries (Hungary, Poland, etc.) are still having increasing incidence and mortality rates.

Lung cancer can be subdivided in small cell lung cancer (SCLC) and in non-small cell lung cancer (NSCLC) – including squamous cell carcinoma, adenocarcinoma, large cell carcinoma, adenosquamous carcinoma and sarcomatoid carcinoma (Rosai and Ackerman 2011).

Histological classification of squamous cell carcinoma of the lung according to the WHO:

1. Squamous cell carcinoma
2. Papillary carcinoma
3. Clear cell carcinoma
4. Small cell carcinoma
5. Basaloid carcinoma.

1.1.2.2. Mutations in squamous cell lung cancer

Mutation profiles of lung cancer depend on histological type. There are characteristic mutations in NSCLC, which originate from the epithelial cells of bronchi and alveoli, as well as in SCLC, originating from epithelial cells of the lung with neuro-endocrine features. Furthermore, there are differences in mutation profiles of squamous cell carcinoma and adenocarcinoma. However, some of the mutations appear in most lung cancers independent of histology. These are p53 mutations, mutations of the retinoblastoma pathway and loss of heterozygosity (LOH) on the chromosome 3p (Travis et al. 2004). Mutations of the TP53 gene can be found in about 50% of the cases (Pfeifer et al. 2002).

Mutations of the retinoblastoma pathway can have different reasons, such as CDKN2A silencing (the gene encoding p16), RB1 expression loss or CCND1 (encoding cyclin D1) overexpression (Brambilla et al. 1999).

Finally, LOH on the chromosome 3p affects many, yet poorly understood tumor suppressor genes (FHIT, RASSF1, SEMA3B) (Lerman and Minna 2000; Lu et al. 1999). This mutation can be found in about 80% of NSCLC (Brauch et al. 1987).

Overexpression of the epidermal growth factor (EGFR) can be seen in virtually all squamous cell carcinomas (Franklin et al. 2002), whereas Her2/neu expression and RAS mutations are rather rare (Travis et al. 2004).

The EGFR is expressed in 84% of squamous cell carcinomas of the lung (Herbst 2004). EGFR is responsible for cell survival, proliferation and metastasis and it is associated with chemotherapy and radiotherapy resistance (Iliakis 1997), but is also an important target of targeted molecular therapies (Mendelsohn and Dinney 2001).

1.2. Morphological and immunohistochemical aspects in squamous cell carcinoma

Squamous cell carcinomas (SCC) can be divided in two groups morphologically: keratinizing and non-keratinizing carcinomas (Chernock 2012). Squamous cell carcinomas have the same morphological and immunohistochemical profile independent on tumor origin (Hayashi et al. 2013; Dotto and Rustgi 2016). The tumors stain positive for the pancytokeratin markers like MNF116 and AE1/AE3 as well as for CK5/6 and partly for cytokeratin 7 (Pulitzer, Desman, and Busam 2010). A squamous

cell specific marker, P40 has been recently established in pathological diagnostics. It is a nuclear antigen, that is specifically expressed in normal squamous cell epithelium and also in squamous cell carcinomas (Nobre, Albergaria, and Schmitt 2013; Ha Lan et al. 2014). It is important to point out, that the origin of the SCC can not be assessed by the use of this marker. Both HNSCC, its metastases and also primary squamous cell carcinomas of other primaries (lung, skin, etc.) stain positive for P40 (Alomari, Glusac, and McNiff. 2014).

1.3. Therapeutic considerations and survival rates

1.3.1. Therapy of squamous cell carcinoma of the head and neck

HNSCC therapy depends on many factors, such as localisation of the tumor, resectability, TNM stadium, operability and general condition of the patient, comorbidities and evidently the preferations of the patient, etc. It is always important that the therapy is discussed at tumor conferences, where, as a result of a multidisciplinary discussion, the best possible therapy can be chosen.

When considering therapy, HNSCC is currently divided into three main stages,

1. Early stage HNSCC (Stage I-II)
2. Locally advanced HNSCC (Stage III-IV)
3. Recurrent or metastatic disease (Pan, Gorin, and Teknos 2009).

Therapy of early stage HNSCC as well as of metastatic disease are not far disputed in the literature, it is agreed on, that early stage cancer must be treated with surgery or radiotherapy and in many cases of early cancer, these therapies are curative.

Therapy of metastatic disease is in most cases platinum based palliative chemotherapy, which is effective in about 1/3 of the cases. If it does not bring any effect, further treatment options are profoundly limited (Pan, Gorin, and Teknos 2009). The overall survival of patients with metastatic disease is 5-9 months (Cohen, Lingen, and Vokes 2004).

In locally advanced disease, therapy should always be multimodal, consisting of combinations of chemotherapy, radiotherapy and surgery. Chemotherapy can be used in neoadjuvant (before surgical resection), concurrent (simultaneously with radiotherapy) and adjuvant (after surgery) concepts. Although many studies have been carried out,

superiority of one or the other is not clear, as well as it is also not clear, whether one chemotherapeutic combination is better than the other. However, there is sufficient proof, that chemotherapy combined with radiotherapy has better results than radiotherapy alone in case of locally advanced disease (Pan, Gorin, and Teknos 2009).

The most widespread chemotherapeutic agents are platinum based agents (cisplatin, carboplatin), and these are often combined with 5-fluorouracil (5-FU) or taxanes (doxorubicin, paclitaxel) (Adelstein et al. 2006; Taylor et al. 1997).

The EGFR inhibitor cetuximab has been recently approved by the FDA for therapy of cisplatin resistant metastatic/recurrent HNSCC and a Phase III study (EXTREME study) has shown that it increases overall survival also combined with platinum based chemotherapy in metastatic/recurrent HNSCC. Although EGFR inhibitors are effective in some of the patients, finding the optimal patient eligible for EGFR inhibitor therapy is yet a problem (Pan, Gorin, and Teknos 2009; Jedlinski et al. 2013; Loeffler-Ragg et al. 2008; Vermorken et al. 2008).

An also recently emerged question is the therapy of HPV-associated and HPV-negative HNSCC. Some authors suggest, that HPV-positive HNSCC, being a less aggressive disease, should be treated with milder therapy regimens (George 2014; Lui and Grandis 2012). However, until now, therapy is same for both groups (Whang, Filippova, and Duerksen-Hughes 2015).

Survival rates of HNSCC depend on the localisation and stage of the tumor. The best survival rates can be expected in laryngeal and nasopharyngeal cancer, independent on stage, the worst prognosis can be expected by tumors of the hypopharynx. Relative survival negatively correlates with years after diagnosis and stage of the tumor (Greene, American Joint Committee on Cancer, and American Cancer Society 2002).

Stage 1 tumors have the best prognosis with relatively high relative survival rates, whereas metastasized carcinoma of the head and neck region is automatically categorised as stage IVc and has the worse prognosis.

1.3.2. Therapy of squamous cell carcinoma of the lung

The gold standard therapy of early stage NSCLC is anatomical resection (lobectomy, segmentectomy, pneumectomy) combined with regional lymph node dissection of peribronchial, interlobar, hilar and mediastinal nodes according to recent treatment

guidelines (Vansteenkiste et al. 2014; Howington et al. 2013). Sublobular resection has, according to recent advances, nearly as good results as anatomical resection in peripheral tumors smaller than 2 cm (Vansteenkiste et al. 2014). In inoperable patients (medically not fit for an operation) an alternative treatment of choice can be stereotactic ablative radiotherapy.

Cisplatin based adjuvant chemotherapy increases 5-year-survival by 5% in early stage NSCLC, although it is not recommended in completely resected stage IA, IB cancer (Pignon et al. 2008; Howington et al. 2013). Adjuvant chemotherapy is recommended in stage II disease, where an N1 lymph node was positive after pathological staging (Howington et al. 2013).

In stage III NSCLC, therapeutic decision is dependent on many factors and decision should be made at multidisciplinary tumor conferences in most cases. Therapeutic opportunities include neoadjuvant chemotherapy followed by surgery, as well as surgery combined with adjuvant chemotherapy, as well as definitive chemoradiotherapy without surgery (Eberhardt et al. 2015).

In stage IV disease, platinum combinations with docetaxel, paclitaxel, gemcitabine and vinorelbine are recommended. If EGFR mutations are diagnosed, afatinib, erlotinib or gefitinib should be added to the chemotherapy (Masters et al. 2015).

EGFR inhibitors can be monoclonal antibodies (cetuximab) or small molecule tyrosine kinase inhibitors (afatinib, erlotinib, gefitinib) and recent research has concluded, that they should be used as first-line therapy in advanced EGFR-positive NSCLC (Eberhardt et al. 2015).

According to recent publications the 5-year survival rates of stage 1 and stage 2 NSCLC are approximately 60-80% and 40-60%, respectively (Scott et al. 2007; Howington et al. 2013).

Compared to stage IVc HNSCC, stage 1 NSCLC has a significantly better prognosis according to this data. This underlines the importance of differentiating between metastasized HNSCC and early stage NSCLC before choosing the therapeutic protocol.

1.4. Aims of this study

The aim of this study was to find out, how precise the combination of clinical and routinely used histomorphological and immunohistochemical diagnostic methods are in distinguishing between metastatic squamous cell carcinoma and second primary squamous cell carcinoma of the lung in patients with squamous cell carcinoma of the head and neck region in the patient history. More precisely, our aim was to define

1. in how many cases are we able to diagnose the origin of the lung tumor using human papilloma virus diagnostics;
2. in how many cases are TP53 gene mutations to be found in the head and neck and lung tumors and whether routine mutation analysis would improve diagnostic decision making;
3. whether the results of sequencing all coding exons (2-11) of the TP53 gene are superior to sequencing exons 5-8, on which exons the most mutations are to be found according to literature;
4. analyse clinical records to examine therapeutic decision making in cases, in which mutational analysis data had not been available;
5. as well as to find out, whether a combination of human papilloma virus diagnostics and TP53 all-exon sequencing and mutation analysis could contribute to better therapeutic decision making.

2. Materials and methods

2.1. Materials

For materials (primers, hardware, kits, consumable materials, reagents, enzymes and chemicals) please see the corresponding tables 1-5.

TP 53 Exon	Forward Primer Sequence	Reverse primer Sequence
2	CCTTCCAATGGATCCACTCACA	GTTGGAAGTGTCTCATGCTGGAT
3	CCTTACCAGAACGTTGTTTTCAGG	CAGGAAACATTTTCAGACCTATGGAAAC
	GATGGGTGAAAAGAGCAGTCAGA	GTGGGAAGCGAAAATTCCATGG
4	GGATACGGCCAGGCATTGA	CCCTGTCATCTTCTGTCCCTT
	GGCATTCTGGGAGCTTCATCTG	GAGGACCTGGTCCTCTGACT
	GCTGCCCTGGTAGGTTTTCTG	CGATATTGAACAATGGTTCACTGAAGAC
5	ACAACCTCCGTCATGTGCT	CTTTCAACTCTGTCTCCTTCCTCTTC
6	GCCACTGACAACCACCCTTAAC	GCATCTTATCCGAGTGGAAAGGAAA
	GCTAGGCTAAGCTATGATGTTCCCTTAGA	AAAGAGAGCATGAAAATGGTTCTATGACT
	GGCCAGACCTAAGAGCAATCAG	CATGGCCATCTACAAGCAGTCA
	TCATCCAAATACTCCACACGCAAA	CTGCTCAGATAGCGATGGTGA
	AGGAAGTAACACCATCGTAAGTCAAG	CAATGGCTCCTGGTTGTAGCTA
7	TGTGATGAGAGGTGGATGGGTA	CCATCCTCACCATCATCACA CTG
	GGCTCCTGACCTGGAGTCTT	CTCATCTTGGGCCTGTGTTATCT
8	CTTGCTTACCTCGTTAGTGCT	GCTTCTCTTTTCCTATCCTGAGTAGTG
	GTGCTAGGAAAGAGGCAAGGAAA	GGAAGAGAATCTCCGCAAGAAAGG
	GCTGTTCCGTCCCAGTAGATTAC	CTGGAGCTTAGGCTCCAGAAAG
9	GTGTTAGACTGGAAACTTTCCACTTGA	GCAGTTATGCCTCAGATTCACTTTTATC
10	TGAGTTCCAAGGCCTCATTCAG	CTTTTGTACCGTCATAAAGTCAAACAATTG
	GGCAGGATGAGAATGGAATCCT	CGCTTCGAGATGTTCCGAGA
11	ACCTATTGCAAGCAAGGGTTCA	AGTCCAAAAAGGGTCAGTCTACCT
	CCCTTCTGTCTTGAACATGAGTTTTT	CAAAGCATTGGTCAGGGAAAAGG

Table 1. The list of forward and reverse primer sequences used for targeted next generation sequencing of TP53 exons 2-11.

Material	Type	Manufacturer, location
Automated IHC machine	Leica Bond Max	Leica, Wetzlar
Bioanalyzer	2100	Agilent, Santa Clara (CA)
Centrifuges	5417R 5415R Rotanta/TRC Heraeus Biofuge 15R Heraeus Biofuge Pico	Eppendorf, Hamburg Eppendorf, Hamburg Hettich, Tuttlingen Thermo Scientific, Waltham (MA) Thermo Scientific, Waltham (MA)
Enzymatic assay analyzer	ELISPot reader	AID, Straßberg
Fluorometer	Qubit 2.0	Life Technologies, Carlsbad (CA)
Ion Torrent System	Ion OneTouch Ion One Touch ES Ion Torrent PGM	Life Technologies, Carlsbad (CA)
Light microscope	Olympus CX41	Olympus, Tokyo, Japan
Magnet	Invitrogen DynaMag-2	Life Technologies, Carlsbad (CA)
Microtome	SM2000R	Leica, Wetzlar
Nucleic acid extraction machine	Maxwell MDx	Promega, Madison (WI)
Pipettes	0.5-10/10-100/100-1000 µl	Biohit, Helsinki (Finland)
Thermocycler	Biometra T3000	LabrepcO, Horsham (PA)
Thermomixer	F1.5	Eppendorf, Hamburg
Vacuum oven	Memmert Model 400	Memmert, Schwabach
Vortexer	VF2	IKA, Staufen
Water purification system	Direct-Q 3	Merck Millipore, Billerica (MA)

Table 2. List of hardware (material, type, manufacturer and location).

Material	Manufacturer, location
Agilent High Sensitivity DNA Reagents Kit	Agilent Technologies, Santa Clara (CA)
Bond Polymer Refine Detection Kit	Leica, Wetzlar
Cintec Histology Kit	Roche, Pleasanton (CA)
HPV DNA Array Kit	AID, Straßberg
Ion 318 chip Kit	Life Technologies, Carlsbad (CA)
Ion Ampliseq Library Kit 2.0	Life Technologies, Carlsbad (CA)
Ion Ampliseq p53 Primers 1-2	Life Technologies, Carlsbad (CA)
Ion OneTouch 200 Template Kit v2	Life Technologies, Carlsbad (CA)
Ion PGM Hi-Q Reagent Mix	Life Technologies, Carlsbad (CA)
Ion Sphere Quality Control Kit	Life Technologies, Carlsbad (CA)
Ion X-press Barcode Adapters 1-16 Kit	Life Technologies, Carlsbad (CA)
Maxwell 16 FFPE Plus LEV DNA Purification Kit	Promega, Madison (WI)
Qubit dsDNA BR Assay Kit	Life Technologies, Carlsbad (CA)
Qubit dsDNA HS Assay Kit	Life Technologies, Carlsbad (CA)

Table 3. List of kits (material, manufacturer and location).

Material	Manufacturer, location
Cover glasses	R Langenbrinck, Emmendingen
Falcon tubes (15 ml, 50ml)	Greiner bio-one, Frickenhausen
Super Frost slides	R Langenbrinck, Emmendingen
Qubit Assay Tubes	Life Technologies, Carlsbad (CA)
Rainin SR-L10F pipette tips	Mettler Toledo, Greifensee
Rainin SR-L200F pipette tips	Mettler Toledo, Greifensee
SafeSeal Tips (10, 100, 1000 µl)	Biozym, Hessisch Oldendorf
DNA LoBind Tubes (1.5 ml)	Eppendorf, Hamburg
Eppendorf Safe-Lock Tubes (1,5 ml; 2 ml)	Eppendorf, Hamburg

Table 4. List of consumable materials (material, manufacturer and location).

Material	Manufacturer, location
Agencourt Ampure XP Reagent	Beckman Coulter, Brea (CA)
DynaBeads MyOne Streptavidin C1	Life Technologies, Carlsbad (CA)
Ethanol (absolute)	Sigma Aldrich, St. Louis (MO)
HotStar Taq DNA Polymerase	Quiagen, Venlo (Netherlands)
MgCl ₂	Quiagen, Venlo (Netherlands)
Nuclease-free water	Life Technologies, Carlsbad (CA)
Polymerase buffer	Quiagen, Venlo (Netherlands)
Tween 20	Carl Roth, Karlsruhe

Table 5. List of reagents, enzymes and chemicals (material, manufacturer and location).

2.2. Methods

2.2.1. Patients

Head neck squamous cell carcinomas and synchronous / metachronous squamous cell carcinomas of 32 patients between 2011-2016 were compared in our study. The patients were aged between 44-72 years at the time of HNSCC diagnosis (median age 61.8 years). The median time between HNSCC diagnosis and LSCC diagnosis was 17.5 months. The patient pool was mixed in terms of the primary site of the HNSCC (14 laryngeal, 8 oral cavity, 5 oropharyngeal, 4 hypopharyngeal, 1 tumor of unknown primary). In case of the tumor of unknown primary, the tumor was diagnosed in a cervical lymph node. Differentiation between lung metastasis and second primary with conventional morphological and immunohistochemical analysis could not be made in these cases with certainty (figure 1). The analysis was carried out on formaline fixed paraffin embedded (FFPE) specimens (biopsies and resectates) of the tumors. All specimens had been obtained during routine diagnostic procedure. The study was approved by the ethical committee of the Justus-Liebig University of Giessen (AZ 105/16).

2.2.2. Histopathology

Specimens were formalin fixed and paraffin embedded. 2µm thick sections of the routinely processed paraffin blocks were stained with hematoxylin-eosin (HE) and examined by an expert pathologist during the routine diagnostic workflow.

2.2.3. DNA isolation

Tumor areas containing more than 30% tumor cells were manually marked under light microscope on the hematoxylin-eosin stained slides and the regions of interest were manually macrodissected from subsequent 3 μm thick sections for DNA isolation. DNA isolation was carried out by the Maxwell 16 System (Promega, Madison, WI) and the FFPE LEV DNA Purification Kit (Promega, Madison, WI).

The specimen was transferred into 180 microliter incubation buffer and 20 microliter (20 mg/ml) Proteinase K solution was added. The specimen was incubated overnight on 70°C, than 400 microliter lysis buffer was added. The solution was vortexed and then transferred into the adequate chamber of the Maxwell cartridge for automated extraction.

2.2.4. Concentration determination of the DNA

DNA concentration determination followed by the Qubit method (Life Technologies, Carlsbad, CA). This method is based on marking the DNA with a fluorescent particle and comparing the fluorescence to that of standard fluorescent solutions. Two fluorescent particles were used depending on the concentration range of the solution – the Qubit dsDNA HS Assay Kit (10 pg/ μl – 100 ng/ μl) and the Qubit dsDNA BR Assay Kit (0,1 ng/ μl – 1000 ng/ μl). For concentration determination 1 μl solution was used.

2.2.5. p16 immunohistochemistry

Fresh 3 micrometer thick sections were prepared from the FFPE blocks with a microtome (SM2000R, Leica, Wetzlar, Germany). Deparaffination was carried out with xylene, 100% ethanol, 95% ethanol, 70% ethanol and 50% ethanol (immunohistochemistry does only function on deparaffinated material). The slides were incubated in hydrogen peroxide to block hydrogen peroxidase activity. The slides were immunostained with a primary p16 antibody (clone E6H4 mouse monoclonal, CINtec, Ventana Medical Systems, Tucson, AZ) for 20 minutes, than with a secondary rabbit anti-mouse IgG antibody (Bond Polymer Refine Detection Kit, Leica Biosystems, Nussloch, Germany) for 8 minutes. The reaction was visualized via a brown precipitate after adding a polymer Anti-rabbit poly-horseradish peroxidase (HRP) IgG linker reagent and a chromogen substrate (3,3'-diaminobenzidine tetrahydrochloride hydrate or DAB). Incubation time with the chromogene substrate was 10 minutes. Slides were counterstained with hematoxylin to mark nuclei. Staining was carried out using

autostaining machines (BOND-III, Leica, Wetzlar, Germany). The slides were dried in a vacuum oven for 30 minutes at 60°C. Stainings were assessed by manually evaluating the specific nuclear reaction of the tumor cells (figure 2).

2.2.6. HPV typing

The extracted DNA was used to amplify the highly conserved E1 region of the HPV genome (if present in the sample) by polymerase chain reaction. The primers used for the PCR reaction were biotin labeled consensus primers for the most common HPV types (HPV 6, 11, 16, 18, 26, 31, 33, 35, 39, 40, 42, 44, 45, 51, 54, 52, 53, 56, 58, 59, 66, 67, 68, 69, 70, 73, 82, 85 and 97). For this purpose a HPV DNA kit (HPV DNA Array Kit, AID, Straßberg, Germany) was used. The amplification was carried out with the HPV Easy-PN-Mix that also contained a primer of the GAP-DH housekeeping gene as a positive control of the cellular DNA.

The reagents used for the PCR-reaction:

Reagent	Quantity
HPV Easy-PN-Mix	15 µl
Polymerase Buffer	2.5 µl
MgCl ₂	1 µl
H ₂ O	1.25 µl
Taq-polymerase	0.25 µl
Probe	5 µl

The solution was covered with oil to prevent contamination.

PCR parameters:

Time	Temperature	Cycles
3 min	95°C	1
10 sec	96°C	10
20 sec	60°C	10
10 sec	95°C	30
15 sec	55°C	30
15 sec	72°C	30
3 min	72°C	1
	8°C	∞

After PCR, the quantity of the DNA had to be measured with the Qubit method. Optimal concentration of the DNA after PCR amplification was 100 ng/ μ l.

The amplified fragments were than hybridized with sequence-specific oligonucleotide probes (SSOP) in a reverse dot blot in situ hybridisation step using a HPV DNA-Array, which is a 96-well plate with the SSOPs linked to its bottom. For this purpose, 25 μ l of denaturation reagent (HPV DNA Array Kit, AID, Straßberg, Germany) was added and incubated on room temperature for 30 minutes to create single stranded DNA from the double stranded DNA and thus enable hybridisation to the AID plates (AID, Straßberg, Germany). 10 μ l of the probe and 200 μ l hybridisation buffer was than added to the wells. The wells were incubated at 47°C for 30 minutes. The supernatant was removed and washing steps and addition of the conjugate followed.

Washing reagent	Time	Temperature
Stringent solution	1 min.	RT
Stringent solution	1 min.	RT
Stringent solution	15 min.	47°C
Rinse solution	1 min.	RT
Rinse solution	1 min.	RT
Conjugate solution	30 min.	RT
Rinse solution (repeat 3x)	1 min.	RT

The amplified biotin labeled HPV-DNA (if present) would specifically bind to the probes and after a washing step, streptavidin-coupled alkaline phosphatase of the conjugate solution bound to the hybrids.

The conjugate solution consisted of streptavidin coupled alkaline phosphatase (2 μ l) and conjugate buffer (199 μ l). A chromogene substrate (nitroblautetrazolinumchlorid/5-Brom-4-chlor-3-indoxylphosphat or NBT/BCIP) was added (200 μ l, 10 minutes incubation on RT) to enable the color reaction. The plates were than washed 2x with water and the test could be evaluated.

Evaluation was semi-automated, using the ELISPot reader (AID, Straßberg, Germany). The different HPV serotypes were marked with triplet dots if HPV DNA was present in the sample. HPV status was evaluated by half automated detection.

2.2.7. Targeted next generation sequencing of the TP53 exones

Targeted next generation sequencing (NGS) is a powerful high-throughput sequencing method based on parallel sequencing of millions of DNA sequences at the same time. Using special primer mixes, relatively short (some 100 bp long) fragments of the DNA can be amplified and sequenced in a short period of time. Targeted next generation sequencing of exones 2-11 of the TP53 was carried out on the previously extracted DNA from the tumor cells of HNSCC and LSCC using the Ion Torrent platform (Life Technologies, Carlsbad, CA, USA) according to the manufacturers instructions. The list of the forward and reverse primers is included in table 1. The primer pool encompassing the TP53 gene was designed with the Ion Ampliseq Designer tool (multi-pool design for 175 bp amplicons).

The sequencing consisted of the following steps:

1. Preparation of the DNA library
2. Clonal amplification
3. Sequencing reaction
4. Data analysis

2.2.7.1. Preparation of the DNA library

After isolation of the DNA, a DNA library had to be prepared. A DNA library consists of many DNA fragments of different lengths. The concentration of the DNA isolated from the FFPE material was adjusted to 10 ng/microliter using the Qubit concentration measurement (see above). A PCR reaction was carried out to amplify the DNA fragments of interest. For the first PCR the following reagents were used:

Reagent	Quantity
2x Ion Ampliseq TP53 Primer Pool (1-2)	10 μ l
5x Ion Ampliseq HiFi Master Mix	4 μ l
genomic DNA, 10 ng	1 μ l
Nuclease-free water	ad 20 μ l

PCR parameters:

PCR-Step	Time	Temperature	Cycles
Initial denaturation	2 min.	99°C	-
Denaturation	15 sec.	99°C	20
Annealing/elongation	4 min.	60°C	20
Cooling	∞	10°C	-

Our TP53 primer pool consisted of 22 primer pairs.

The PCR-reaction was followed by a partial digestion of the primer-sequences to enable ligation of the adapters, that are essential for the next generation sequencing reaction. This was carried out with 2 μ l of FuPa reagent (an enzyme mix) to partially digest the primers. Incubation was carried out for 10 minutes at 50°C, 10 minutes at 55°C, 20 minutes at 65°C and finally for 1 hour at 10°C.

To enable clonal amplification and next generation sequencing, the DNA fragments had to be conjugated with two adapters (P1 and a barcode) at the two ends of the fragments. The adapter ligation was carried out adding following components to the reaction:

Reagent	Quantity
Digested Probe	22 μ l
Switch Solution	4 μ l
Ion Ampliseq X-press barcode	2 μ l
DNA ligase	2 μ l

Preparation of the X-press barcode mix:

Reagent	Quantity
P1 adapter	2 μ l
X-press barcode	2 μ l
Nuclease-free water	4 μ l

Because every barcode marks a different probe, probes from many tumors could be processed simultaneously in the sequencing process.

Incubation of the ligation reagent lasted for 30 minutes at 22°C and then 10 minutes at 72°C.

In the next step, the excess of primers and adapters had to be removed. This was carried out using magnetic beads that are covered with carboxyl groups and are able to bind DNA. Using the beads, the approx. 100 bp long DNA fragments are bound and can be washed and once again eluted. For this purpose, the DNA library was transferred in a tube after ligation and magnetic beads (45 µl of Agencourt AMPure XP reagent) were added to the solution and incubated for 5 minutes. The incubation was carried out on the Dynamag magnets for 3 minutes. Eventually, the beads were washed with 150 µl 70% ethanol two times and then airdried. The beads (and the DNA library fragments of interest now bound to them) were then resuspended in 2 µl Library Amplification Primer Mix and 50 µl PCR Supermix High Fidelity solution to carry out library amplification. The solution was once again placed on the Dynamag magnets. In this step, the DNA dissolved from the beads and were eluted in the supernatant. The supernatant was pipetted into a PCR tube. Next, an other PCR reaction followed to amplify the DNA library fragments.

PCR parameters for the DNA-library amplification:

PCR Step	Time	Temperature	Cycles
Initial denaturation	2 min.	98°C	-
Denaturation	15 sec	98°C	5
Annealing/Elongation	1 min.	60°C	5
Cooling	∞	10°C	-

After the PCR, a second DNA-purification step followed using the magnetic beads (25 µl of Agencourt AMPure XP Reagent). Incubation lasted again for 5 minutes at room temperature and then using the Dynamag magnets for another 5 minutes. The supernatant, now containing the amplified DNA fragments was then pipetted into an other tube and 60 µl of the Agencourt AMPure XP Reagent was added once again. The solution was incubated using the Dynamag magnets again for another 5 minutes. In this step, the approx. 100 bp long DNA fragments bound to the beads. Afterwards another washing step followed using 70% ethanol two times. The DNA was resuspended in 50 µl Low TE and incubated using the Dynamag magnets for 5 minutes.

Quantification of the DNA was carried out using the Agilent Bioanalyzer and the Agilent High Sensitivity DNA Kit. For DNA quantification, 1 μl of the previously prepared DNA library was used. This kit enabled us to visualize the DNA length on a virtual gel as well as on an electropherogram and also calculated DNA molarity. For this analysis a maximum of 500 $\text{pg}/\mu\text{l}$ DNA should be used, therefore concentration determination of the DNA library had to be carried out using the Qubit method again. When analysing the DNA fragments with the Agilent Bioanalyzer, we should see multiple peaks between 125-300 bp. After determination of the molar concentration of the DNA library, the end-concentration was adjusted to 100 pM.

2.2.7.2. Clonal amplification

The DNA library creation and amplification was followed by the clonal amplification of the DNA. For clonal amplification and the following sequencing reaction, the DNA fragments had to be bound to the Ion Sphere particles (ISP). The ISP has DNA sequences complementary to the adapter sequence P1 (P1 oligo). The library fragments can bind to the ISPs and it functions as a primer for amplification.

During the reaction, the DNA is synthesised and after denaturation the single stranded DNA binds to another P1-oligo on the same ISP and the synthesis is repeated. The original DNA strand stays bound to the ISP. The synthesis also begins in the reverse direction, beginning with the barcode that functions as the reverse primer. Bound to the reverse primer is biotin, that enables separation of DNA binding ISPs (positive ISPs from negative ISPs) through streptavidin linked magnetic beads.

The clonal amplification was carried out in form of an emulsion PCR using the Ion OneTouch Instrument. The fragments were amplified in oil-enclosed water drops, so called microreactors. DNA fragments and ISPs were mixed in an adequate ratio, so that statistically only one ISP and one DNA fragment could be found per microreactor. At the end of the parallel sequencing, there were millions of ISPs binding the many DNA fragments. One ISP had the same DNA fragments in many copies on the surface. The amplification solution was prepared as follows:

Reagent	Quantity
Ion PGM Hi-Q Reagent Mix	800 μ l
Ion OneTouch Enzyme Mix	50 μ l
Diluted library, 100 pM	25 μ l
Ion OneTouch 200 Ion Sphere Particle	100 μ l
Nuclease-free water	25 μ l

The solution was pipetted into the Ion OneTouch Reaction Filter and covered with 1.7 ml reaction oil. The filter was placed into the Ion OneTouch Instrument and the reaction was started. After the emulsion PCR, the ISPs were centrifuged in the Ion OneTouch instrument and collected into two reaction tubes. These tubes had been previously filled with 150 μ l breaking solution. The supernatant was removed and only 50 μ l solution remained. The ISPs (and bound to them the DNA fragments) were resuspended and 1 ml Ion OneTouch Wash Solution was added. The ISPs were then centrifuged (2.5 minutes, 15500 g) and the wash solution was mostly removed (100 μ l remained). The ISPs were then resuspended in this solution. The negative ISPs were removed using magnetic beads paired with streptavidin. This step was automatised and carried out by the Ion OneTouch Instrument on an 8-well strip. The strip was filled according to the manufacturer's instructions.

Well number	Reagent to dispense in well
Well 1	100 μ l Entire template-positive ISP sample
Well 2	130 μ L of Dynabeads MyOne Streptavidin C1 Beads resuspended in MyOne Beads Wash Solution
Well 3	300 μ L of Ion OneTouch Wash Solution
Well 4	300 μ L of Ion OneTouch Wash Solution
Well 5	300 μ L of Ion OneTouch Wash Solution
Well 6	Empty
Well 7	300 μ L of freshly-prepared Melt-Off Solution
Well 8	Empty

The MyOne beads had been washed before this step (13 μl of the beads resuspended in 130 μl MyOne Beads Wash Solution) and incubated for 2 minutes on the Dynamag magnets. The supernatant had been removed and the beads had been once again resuspended in 130 μl MyOne Beads Wash Solution.

The Melt-Off Solution of well 7 was freshly prepared using 125 μl 1 M NaOH, 10 μl 10% Tween 20 in nuclease free water and 865 μl nuclease free water.

The purification step was then started and the probes were automatically collected in a PCR tube. Afterwards a centrifugation step followed (1.5 minutes, 15500 g). The supernatant was removed, until 10 μl solution remained. The Melt-Off Solution had to be washed out of the ISPs by adding 200 μl of the Ion OneTouch Wash Solution. The ISPs were then once again centrifuged (1.5 minutes, 15500 g). The supernatant was once again removed, so that only 10 μl solution remained and it was then diluted to 100 μl .

2.2.7.3. Sequencing reaction

In case of the Ion Torrent Platform, the sequencing reaction is based on the following principle: The ISPs with the DNA fragments on their surface are loaded on a chip (Ion 318 chip). This chip has millions of microwells on its surface, but these wells are so small, that only one ISP can fit into one well. When the sequencing reaction is started, the chip is flooded with deoxynucleotides in a determined order and if they are compatible with the corresponding nucleotide of the DNA fragment, they bind to the single stranded DNA on the ISPs with the help of the DNA polymerase. When a nucleotide is bound, a proton is released and it leads to a pH change in the well. This pH change creates an electronic impulse that can be detected on a protein sensitive plate at the bottom of the well. Because of the prior amplification of the fragments, many protons are released when a nucleotide is incorporated, so that the pH change is great enough to be registered. Should more of the same nucleotides be incorporated in the prolonging DNA sequence, the pH change is proportionately greater and can be easily registered. It is important to point out, that it might come to reading mistakes when sequencing homopolymer repeats (sequences with repeating units). After flooding the chip with one nucleotide, the chip is washed and flooded with the next nucleotide. This cycle is repeated about 500 times, although more cycles would be needed, when sequencing longer fragments.

Annealing of IPSs and primers was carried out preparing the following solution: positive ISPs (100 μ l), Control Ion Sphere Particle (5 μ l) and Annealing Buffer (100 μ l). The solution was then centrifuged for 1.5 minutes at 15500 g and the supernatant was removed except for the last 15 μ l. Then 12 μ l of sequencing primer was added to the solution. The solution was then placed into a thermocycler (2 minutes at 95°C and then 2 minutes at 37°C) to promote annealing. After that, 3 μ l of the PGM sequencing polymerase was added and incubated for 5 minutes on room temperature. The chip was set up and the solution was pipetted onto the chip. The sequencing reaction was started according to protocols of the manufacturer.

2.2.7.4. Analysis of targeted next generation sequencing data

After raw data had been processed by the Ion Torrent Variant Caller software, the sequence was compared with the human reference genome (hg19). The single nucleotide variations were displayed with the exact localisation of the mutation using the Ion Torrent Variant Caller program. To rule out single nucleotide polymorphisms, the mutations were compared with an online database (Exome Variant Server, National Heart, Lung and Blood Institute, USA).

The minimal read depth within the region of interest was >1000, mutation frequencies had to be >10% to be considered as relevant.

2.2.8. Assessment

In case of HPV-positivity of the HNSCC, the lung tumor was classified as a metastasis, if it also contained the DNA of the same HPV serotype and was classified as second primary LSCC, if HPV negativity was demonstrated. If the HNSCC was HPV negative, next generation sequencing of all coding TP53 exons was carried out in the HNSCC and in the LSCC and the mutations were compared. In case of similar mutations a metastasis, in case of different mutations a second primary lung tumor was diagnosed. In case of HNSCC without TP53 mutations, a decision on lung tumor origin could not be made, because if the lung tumor contained TP53 mutations, it was not clear, whether it was a result of clonal evolution or a second primary LSCC occurred. Analysis was always carried out with consideration of the histopathological assessment.

We analyzed clinical records to see, whether the patients were subjected to the best possible therapy. We compared the molecular pathological diagnosis with the clinico-pathological diagnosis. In cases, in which the clinical (radiological) and pathological

diagnosis were different, the pathological diagnosis was compared with the molecular pathological diagnosis.

In case of metastases no resection, or wedge resection without lymph node dissection was classified as the correct therapy of choice. In case of a second primary LSCC, anatomical resections (segmentectomy, lobectomy and pneumonectomy) with regional lymph node dissection were assessed as ideal therapy (Howington et al. 2013; Vansteenkiste et al. 2014).

3. Results

In our study, 65 tumors of 32 patients were analyzed. In these cases a decision on lung tumor origin could not be made using conventional morphological-immunohistological methods (figure 1).

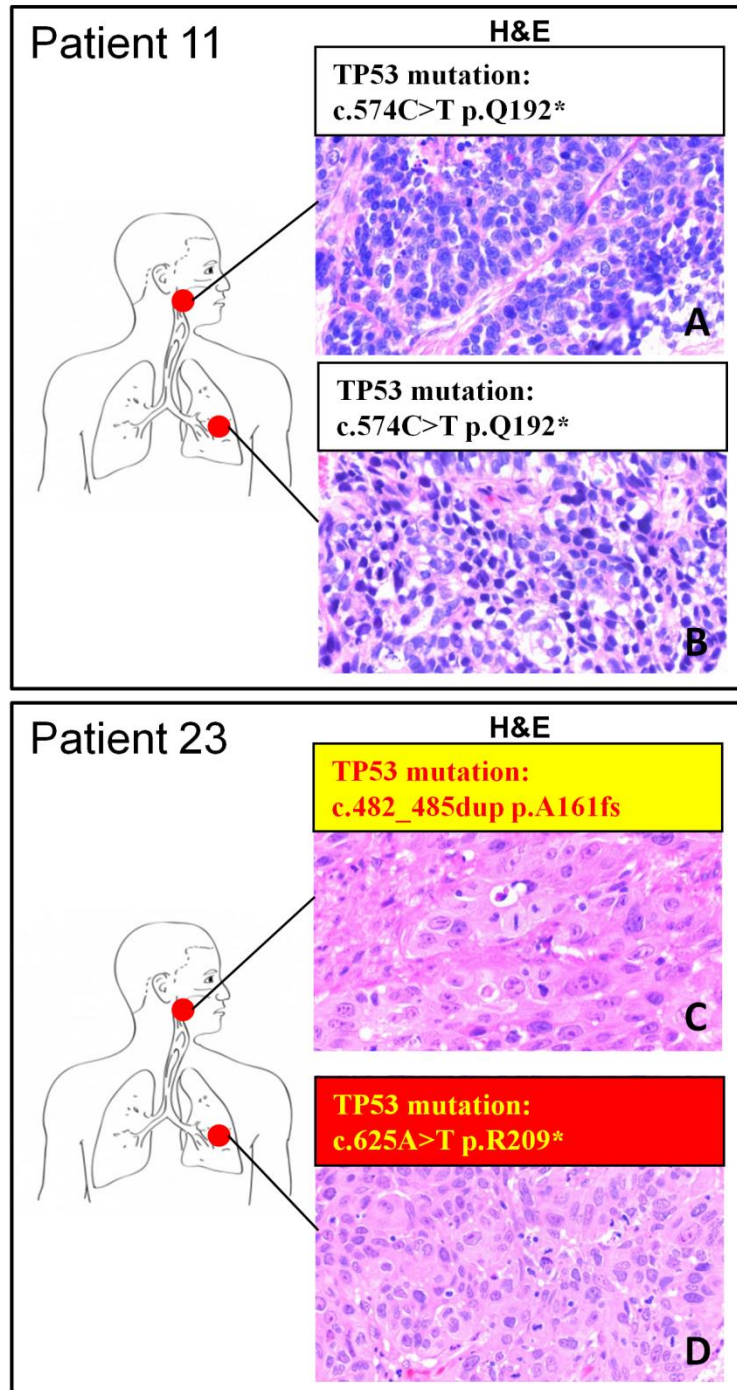


Figure 1. There is no difference between HNSCC and LSCC in terms of marker profile and morphology irrespective of lung tumor origin. **A.** HNSCC of patient 23 stained with hematoxylin – eosin. Mutation analysis results were included (insert). **B.** Lung SCC of patient 23

stained with hematoxylin – eosin. Mutation analysis results were included (insert). **C.** HNSCC of patient 16 stained with hematoxylin – eosin. Mutation analysis results were included (insert). **D.** Lung SCC of patient 16 stained with hematoxylin – eosin. Mutation analysis results were included (insert) (Daher et al. Article in press. 2017). Abbreviations: TP53 = tumor protein 53 gene.

At first, HPV status of the tumors was determined using p16 immunohistochemistry and HPV typing. After verifying HPV negativity, targeted next generation sequencing of exons 2-11 of the TP53 gene was carried out in the HNSCC and LSCC of the patients.

The data is shown in tables 6 and 7.

Patient Number	Age / Sex	HNSCC localization / tumor stadium	p16 IHC / HPV-PCR/ISH HNSCC	p16 IHC / HPV-PCR/ISH Lung tumor	Match of TP53 mutation profile in HNSCC and lung tumor	Clinico- pathological Diagnosis	Molecular-pathological Diagnosis	Lung Surgery	Further therapy
1	57 / M	Oropharyngeal / T2N2b	- / -	- / -	+	Metastasis	Metastasis	No surgery	N/A
2§	57 / M	CUP-Syndrome / T1aNx	- / -	- / -	-	Primary Tumor	Primary Tumor	Lobectomy with lymph node dissection	Curative radiation therapy of the cervical lymph node
3	61 / M	Oral cavity / T1aN1	+ / -	+ / -	+	Metastasis	Metastasis	No surgery	Adjuvant chemotherapy
4	58 / M	Laryngeal / T2N2c	+ / -	- / -	+	Metastasis	Metastasis	Lobectomy with lymph node dissection	Palliative chemotherapy
5	61 / M	Oral cavity / T2N0	- / -	- / -	-	Primary Tumor	Primary Tumor	Pneumonectomy with lymph node dissection	Adjuvant chemotherapy
6	57 / M	Hypopharyngeal / TxNx	- / -	- / -	+	Metastasis	Metastasis	Wedge resection without lymph node dissection	Palliative chemotherapy
7	59 / M	Oropharyngeal / TxNx	+ / -	N/A / -	+	Metastasis	Metastasis	No surgery	Palliative radiotherapy
8	44 / M	Hypopharyngeal / T3N1	- / -	- / -	+	Metastasis	Metastasis	No surgery	Radio-chemotherapy
9	54 / M	Laryngeal / T2N2b	+ / -	- / -	+	Metastasis	Metastasis	No surgery	Palliative therapy
10	60 / M	Laryngeal / T2N2c	+ / -	- / -	-	Primary Tumor	Primary Tumor	No surgery	Radiotherapy of bone metastases

11	61 / M	Laryngeal / T2N2b	- / -	- / -	+	Metastasis	Metastasis	No surgery	Chemotherapy
12	57 / M	Oropharyngeal / T2N2b	+ / HPV -16	+ / HPV -16	+	Metastasis	Metastasis	No surgery	N/A
13	62 / M	Oral cavity / TxNx	- / -	- / -	-	Primary Tumor	Primary Tumor	No surgery	Death immediately after diagnosis
14	57 / F	Laryngeal / T2N2b	- / -	- / -	-	Not specified	Primary Tumor	Wedge resection without lymph node dissection	No further therapy
15†	65 / M	CUP-Syndrome / TxNx2c	+ / -	N/A / -	-	Primary Tumor	Metastasis	Lobectomy with lymph node dissection	Lobectomy (if worsening, palliative chemotherapy)
16	59 / M	Oral cavity / T2N1	- / -	- / -	-	Metastasis	Primary Tumor	Segmentectomy with lymph node dissection	No further therapy
17	67 / M	Hypopharyngeal / T2N1b	N/A / -	N/A / -	+	Primary Tumor	Metastasis	Pneumectomy with lymph node dissection	No further therapy
18	63 / M	Oral cavity / TxNx	- / -	- / -	+	Primary Tumor	Metastasis	Wedge resection with lymph node dissection	Palliative radio-chemotherapy
19	56 / M	Oral cavity / T1N0	- / -	- / -	-	Not specified	Primary Tumor	Wedge resection without lymph node dissection	N/A
20	64 / M	Laryngeal / T1Nx	- / -	- / -	+	Not specified	Metastasis	No surgery	Palliative chemotherapy
21	66 / M	Hypopharyngeal / TxNx	- / -	- / -	-	Metastasis	Primary Tumor	Segmentectomy with lymph node dissection	No further therapy
22	66 / M	Laryngeal / T2N0	N/A / -	N/A / -	+	Not specified	Metastasis	No surgery	Death immediately after diagnosis
23	72 / M	Oropharyngeal / T2N0	- / -	- / -	-	Not specified	Primary Tumor	Wedge resection without lymph node dissection	Palliative chemotherapy discussed, no further therapy
24	76 / M	Laryngeal / T4bN1	- / -	N/A / -	+	Primary Tumor	Metastasis	No surgery	Radiotherapy, in case chemotherapy

25	67 / M	Laryngeal / TxNx	+ / -	- / -	-	Metastasis	Primary Tumor	Wedge resection without lymph node dissection	Palliative chemotherapy
26	66 / M	Laryngeal / T2N2b	+ / -	- / -	-	Metastasis	Primary Tumor	No surgery	No further therapy
27	57 / M	Laryngeal / T1N1	- / -	- / -	-	Not specified	Primary Tumor	Lobectomy with lymph node dissection	No further therapy
28	65 / M	Laryngeal / T2N2b	- / -	- / -	+	Not specified	Metastasis	No surgery	Palliative Chemotherapy
29	56 / M	Oropharyngeal / TxNx	- / HPV -16	N/A / -	N/A	Metastasis	Primary Tumor	No surgery	Chemotherapy
30	54 / M	Oral cavity / T1aNx	N/A / -	- / -	N/A	Metastasis	Not specified	Wedge resection without lymph node dissection	Adjuvant chemotherapy
31	72 / M	Laryngeal / T4aN0	- / -	- / -	N/A	Metastasis	Not specified	Wedge resection without lymph node dissection	No further therapy
32	60 / M	Laryngeal / T3N0	- / -	- / -	N/A	Primary Tumor	Not specified	No surgery	Radiotherapy

Table 6. Overview of patients showing tumor type, HPV typing results, TP53 mutation analysis results (detailed mutational profiling data details shown in table 7), clinicopathological data and therapeutic decisions. HPV-typing enabled differentiation between primary tumor of the lung and metastasis in 2 cases (patients 12 and 29), while mutation analysis made a differentiation possible in 27 cases. Mutational analysis of exons other than 5-8 was needed for a decision in 6 cases. Clinico-pathological diagnoses represent the combination of pathological diagnosis and clinical diagnosis made without knowledge of the molecular genetic data. If clinical and pathological diagnosis were different, the pathological diagnosis was compared with the molecular genetic diagnosis. Clinico-pathological diagnoses matched the molecular pathological diagnosis in 13 cases (green highlight), while clinico-pathological diagnoses differed from the molecular pathological diagnosis in 16 cases (red highlight). In patients 30-32, a molecular pathological diagnosis was not possible, because no TP53 mutations were detected in the HNSCC (grey highlight) § Patient 2 was diagnosed with a cervical lymph node infiltration adherent to his lung tumor. Surprisingly, all three tumors (head and neck, lymph node and lung) harbored different TP53 mutations, therefore it was concluded that the cervical lymph node was infiltrated by a cancer of unknown primary. Curative resection of the lung tumor and curative radiation of the cervical lymph nodes was carried out. † Patient 15 had different mutations in the lymph node metastases of an unknown primary tumor and the lung tumor, but the morphological histological pattern was very suggestive of a metastasis, so that a lung

metastasis of an unknown head and neck primary tumor was diagnosed (Daher et al. Article in press. 2017).

Patient Number	TP53 Mutation HNSCC	TP53 Mutation LSCC
1	c.993+1G>A splice donor intron 9 inactivation	c.993+1G>A splice donor intron 9 inactivation
2§	c.661G>T p.E221X (HNSCC); c.166G>T p.E56* (Cervical lymph node)	c.811G>T p.E271*
3	c.524G>A p.R175H	c.524G>A p.R175H
4	c.725G>A p.C242Y	c.725G>A p.C242Y
5	c.892G>T p.E298	c.672+1G>A splice donor intron 6
6	c.538G>T pE180*	c.538G>T pE180*
7	c848G>C pR283P	c848G>C pR283P
8	c.916C>T pR306*	c.916C>T pR306*
9	c.476 C>T p.A159V	c.476 C>T p.A159V
10	c.217_219 delinsGT P.P72fs; c.824 G>A pC275Y	No mutation
11	c.574 C>T p.Q192*	c.574 C>T p.Q192*
12	N/A	N/A
13	c.332T>A p.L111Q	c.818G>T p.R273L
14	c.892G>T p.E298X; c.464C>A p.T155N	c.1.010G>C p.R337P
15	c.597delA p.G199fs	c.818G>T p.R273L
16	c.338T>G p.F113C	c.775G>T p.D259Y
17	c.476C>A pA159D	c.476C>A pA159D
18	c.659A>G p.Y220C	c.659A>G p.Y220C
19	c.161delT p.F54fs	c.535C>G p.H179D
20	c.517G>T p.V173L; c.35G>T p.G12V	c.517G>T p.V173L; c.35G>T p.G12V
21	c.713G>T p.C238F	No Mutation
22	c.844 C>T p.R282W	c.844 C>T p.R282W
23	c.482_485dup pA161fs	c.625A>T p.R209*
24	c.1024C>T p.R342*	c.1024C>T p.R342*
25	c.659A>G p.Y220C	No mutation
26	c.1005_1006ins TGC,GGG,TGC,CTA,GG p.R335fs	No mutation
27	c.733 G>T p.G245C; c.447delC p.149fs	c.301_314del p.K101fs
28	c.844 C>T p.R282W	c.844 C>T p.R282W
29	N/A	N/A
30	No mutation	No mutation
31	No mutation	No mutation
32	No mutation	c.742C>T p.R248W

Table 7. Mutational profiling data in samples from head and neck squamous cell carcinoma (HNSCC) and corresponding lung squamous cell carcinoma (LSCC). § Patient 2 was diagnosed with a cervical lymph node infiltration adherent to his lung tumor. Mutations are shown for all three tumors (Daher et al. Article in press. 2017).

p16 immunohistochemistry could be successfully performed with 55 tumors (figure 2). In case of 10 tumors, there was not enough tumor material available for both p16 immunohistochemistry and HPV typing analysis, so that in these cases HPV typing was preferred. 11 tumors (20%) showed p16 positivity, although HPV positivity could be shown in only two of these cases using HPV typing.

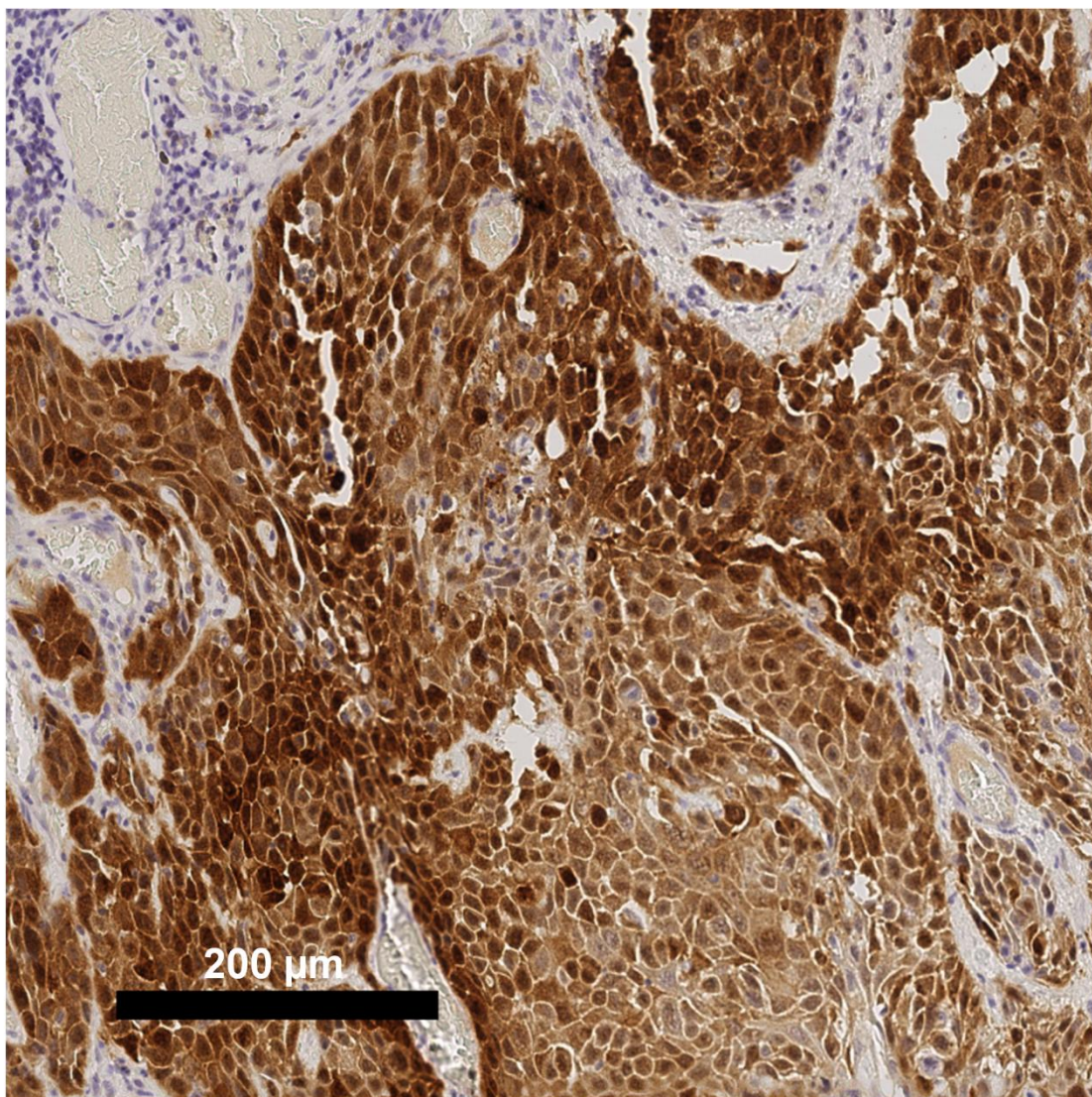


Figure 2. Positive immunohistochemical staining of p16 (brown stain) in a laryngeal resectate (patient 10). Nuclei were counterstained with hematoxylin (blue stain). Scale bar 200 μm . Abbreviations: p16 = protein 16 (Daher et al. Article in press. 2017).

HPV typing showed HPV positivity in 3 tumors of two patients (patient 12, 29). Every other analyzed tumor turned out to be HPV negative. A decision on lung tumor origin could be made in 2 of 32 cases (6%) using HPV analysis only.

Targeted next generation sequencing of the TP53 coding exons in 61 tumors of the 30 remaining patients found 57 mutations in 54 tumors. Mutations on exons 5-8 were detected in 43 of the 57 cases (75%). Mutations on exons 2-4 and 9-11 were found in 14 cases (25%). Data included in figure 3. Diagnosis of the LSCC origin depended on all-exon sequencing in 6 of 32 cases (19%).

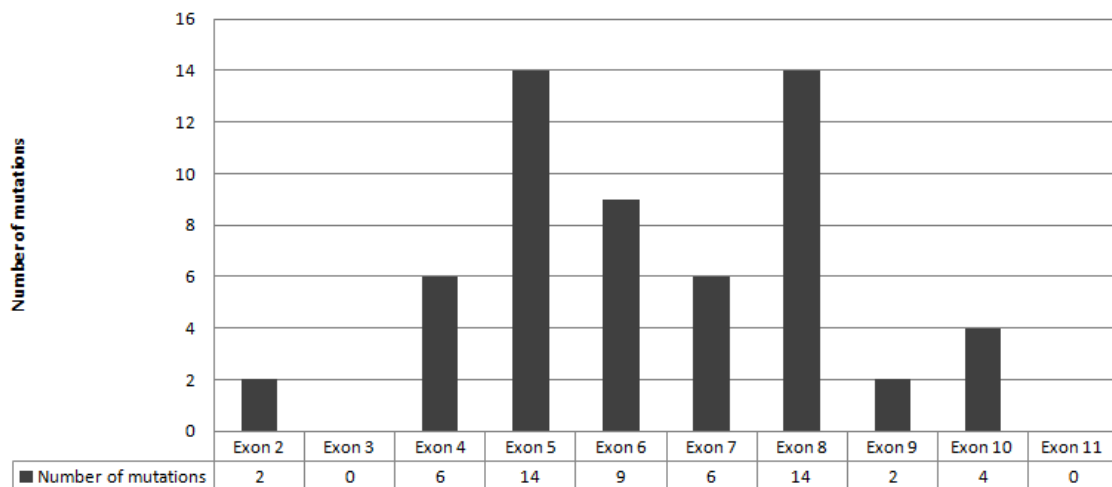


Figure 3. TP53 gene mutation distribution on exons 2-11 in the examined tumors. The mutations located on the splice donor and acceptor sites of the introns adherent to the exon were counted with the respective exon mutations. 25% of mutations were located outside of exons 5-8. This stresses the importance of analysis of all coding exons (Daher et al. Article in press. 2017).

Of the 57 mutations, 47 were substitutions (11 leading to nonsense mutations), 3 splice donor site mutations, 1 duplication, 1 insertion and 5 deletions (one combined with an insertion).

Identification of lung tumor origin was achieved in 29 of 32 cases (90%) using a combination of HPV typing and TP53 mutation analysis.

In case of patient 2, three tumors (head and neck squamous cell carcinoma, cervical lymph node metastasis of a squamous cell carcinoma and lung squamous cell carcinoma) were compared. It turned out, that all three tumors harbored different

mutations, so that a primary lung tumor and a cancer of unknown origin (CUP) were diagnosed.

In case of patient 15, different mutations were found in a cervical lymph node metastasis of a squamous cell carcinoma and in the lung squamous cell carcinoma. However, the growth pattern of the lung tumor was so suggestive for a metastasis, that a lung metastasis of a cancer of unknown primary and a lymph node metastasis of another primary were diagnosed.

The analysis of clinico-pathological diagnoses and comparison with the molecular pathological diagnoses revealed that a correct evaluation of lung tumor origin had only been possible in 13 out of 29 cases (45%) based on clinical and morphological data alone. In 16 cases clinicopathological and molecular pathological diagnosis were discrepant, and in three cases a molecular pathological diagnosis was not possible, because there were no mutations detected in the head and neck tumors (table 6).

Analysis of the surgical treatments showed that 11 out of 23 patients (48%), in whose case surgical resection had been carried out before mutational profiling, had not received the most suitable treatment: 3 patients (4, 15, 17) with pulmonary HNSCC metastases were subjected to extensive resections (pulmonary lobectomy or pneumectomy with excision of regional lymph nodes), (figure 4, patient 17), while the second primary LSCC of 8 patients (10, 14, 19, 23, 25, 26, 29) were not excised radically (Table 6). In contrast, availability of HPV typing and mutational profiling data made it possible, that all patients got the most suitable therapy (table 6; figure 4, patient 16).

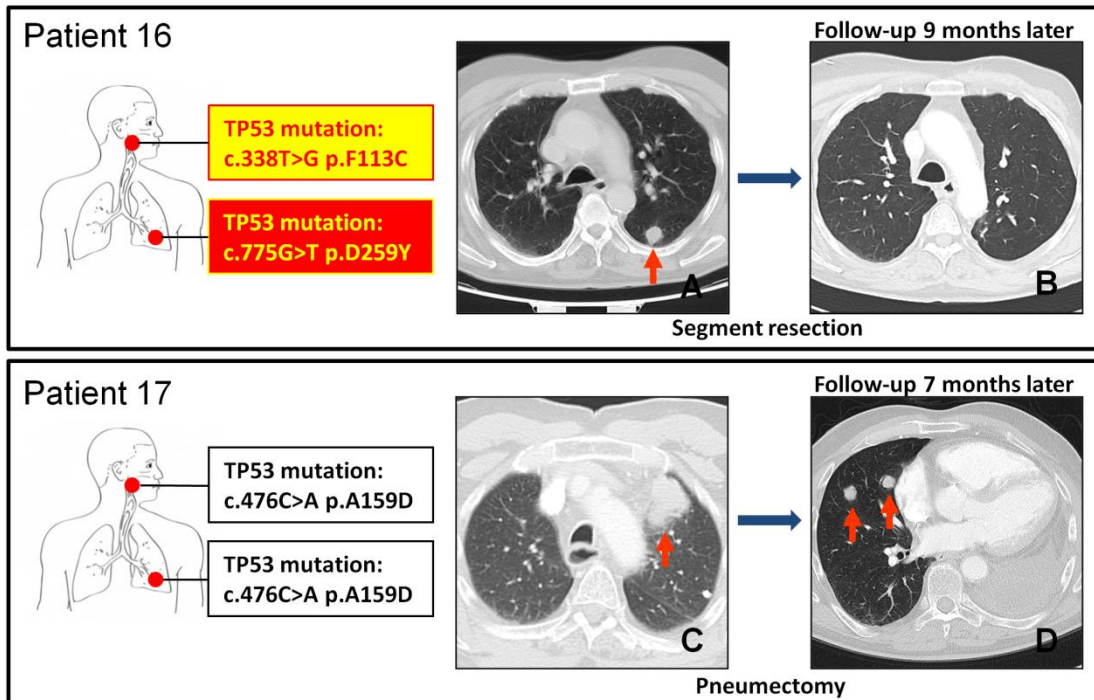


Figure 4. Therapeutic consequences of surgical resection of the lung tumor on two representative cases. Patient 7 had a pT1a primary lung squamous cell carcinoma diagnosed 1 month after the diagnosis of his HNSCC, mutation status was confirmed by TP53 mutation analysis. The therapy of choice was segment resection with regional lymph node dissection. Patient 9 had a lung squamous cell carcinoma diagnosed 54 months after diagnosis of his HNSCC. Mutation analysis was not carried out on a biopsy, the right upper lobe was rather resected accompanied by regional lymph node dissection. **A.** Computed tomography image of the lungs of patient 7 at the time of lung tumor diagnosis. **B.** Computed tomography image of the lungs of patient 7, 9 months after surgical resection of the lung tumor. No sign of further tumors. **C.** Computed tomography image of the lungs of patient 9 at the time of lung tumor diagnosis. **D.** Computed tomography image of the lungs of patient 9, 7 months after resection of the left upper lobe. Several newly diagnosed tumors in the right lung. This stresses the importance of mutation analysis already on the biopsy material before resection. The orange arrows point at the lung tumors (Daher et al. Article in press. 2017).

4. Discussion

In our study 65 head and neck squamous cell carcinomas and lung squamous cell carcinomas of 32 patients were analysed. In our experience, using only traditional morphological / immunohistochemical diagnostics, patients with head and neck squamous cell carcinoma and synchronous / metachronous lung squamous cell carcinoma pose an unsolvable diagnostic challenge in the pathological diagnostic routine. However, as therapeutic protocols and patient outcomes are potentially different in patient groups with metastasized HNSCC and low stage second primary LSCC, a reliable diagnostic method would be essential to differentiate between them.

We combined p16 immunohistochemistry and HPV typing to compare HPV status of the tumors in the hope to differentiate between metastasis and second primary tumor in the lung. In case of a HPV negativity in both HNSCC and LSCC we performed a targeted next generation sequencing of all coding exons (exon 2-11) of the TP53 gene to compare mutation status. With the use of HPV analysis, a decision on lung tumor origin could have been made in only 2 of the 32 cases (6%). With the use of targeted next generation sequencing of all coding exons we could make a decision in 29 of 32 cases (90%). Without the use of molecular methods a diagnosis could have only been reached in 13 of 29 cases (45%). According to our results 25% of the mutations were found to be localised outside of the most often examined exons 5-8, and diagnosis on LSCC origin in 6 of 32 cases (19%) depended on all-exon sequencing. This stresses the importance of analysing all coding exons when searching for mutations.

The analysis of the pathology reports showed, that diagnostic criteria for lung tumor origin determination are inconsistent. The decisions in the pathological decision making depended on tumor growth pattern or immunohistochemical phenotype. Furthermore, clinical decision making depending on radiology reports was also inconsistent. We concluded, that the origin of lung tumors had only been identified correctly in 45% of the cases based on clinical and morphological data alone. Analysis of the administered surgical treatments showed that more than almost 50% of patients, where mutation analysis data had not been available, had not received the most suitable treatment. In this study we conclude, that traditional histomorphological analysis is not sufficient in these cases and the use of molecular diagnostics is indispensable.

In countries, where tendentially less individuals are smoke, the prevalence of HPV-associated head and neck cancer has been growing in the last decades (Chaturvedi et al. 2008; Ryerson et al. 2008). HPV testing of head and neck cancer has become part of the routine diagnostics. This is an important aspect, because the prognosis of HPV positive disease is better, than that of HPV negative disease (Fakhry et al. 2008; Licitra et al. 2006; Weinberger et al. 2006).

An important question of HPV analysis is the method of choice. The possibilities are overwhelming, but choosing the right method needs some consideration. According to recent literature, a combined analysis with immunohistochemistry and in situ hybridisation gives a highly precise information on the HPV status of the tumor (Marur et al. 2010b; Singhi and Westra 2010).

It should be pointed out, that p16 positivity might occur in HPV negative cases. In our case it happened in 20% of the cases. This underlines the importance of combined testing.

It has been described by other authors, that 20% of LSCC tested positive for HPV in patients with HNSCC in the clinical history (Bishop et al. 2012). In an other study of HNSCC and female genital tract cancer patients with a following LSCC, concordant HPV status was found in 14.2% and different HPV status was found in 42.9% of the cases. A decision depending on HPV status of the tumors could be made in 57.1% of the cases (Weichert et al. 2009).

However, if both tumors turn out to be negative and also in patient collectives with less HPV-associated tumors, additional methods should be considered.

Some authors favorised a microsatellite analysis of the chromosomes 3p and 9p and could decide on LSCC origin in 13 of 16 cases in one study (Leong et al. 1998). In a further study, loss of heterozygosity (LOH) analysis of several chromosomes was carried out for differentiation between lung metastasis and second primary in HNSCC patients and the method could be successfully used in 43 of 44 analysed cases (Geurts et al. 2005).

The LOH method has also been combined with a PCR based single-strand conformation polymorphism assay of exon 5-8 of TP53 and this study also showed, that a correct diagnosis impacts further therapy in a patient collective with different primary and

secondary tumors. In some of the analysed cases the patients had a HNSCC as a primary and a LSCC as a secondary tumor (van der Sijp et al. 2002).

These works show, that although the gold standard method has been debated, TP53 analysis has been widely used for tumor origin determination. TP53 mutations have been described as very good clonal markers because of their stability during metastasis and variability of mutations (van Oijen et al. 2000; Tabor, van Houten, et al. 2002), which make the analysis of the TP53 gene a feasible marker for mutation analysis when looking for secondary tumor origin (Tabor, Brakenhoff, et al. 2002; Hittelman 2001; Brennan et al. 1995; van Houten et al. 2002; Califano et al. 1999; Garcia et al. 1999).

The discussed studies concluded, that finding the same mutations / genetic alterations in two different tumors point to a metastasis, whereas different mutations / genetic alterations suggest a second primary tumor. HNSCC have been described to be clonally stable in terms of TP53 mutations. However, most works discussing this question mostly used sequencing of exons 5-8 mostly because of technical reasons.

According to literature and also our own results presented here, mutations localised on exons 2-4 and 9-11 are also to be expected (Saunders et al. 1999; Hartmann et al. 1995). This makes all-exon sequencing particularly important in these cases.

It would be indispensable to find a diagnostic tool to differentiate between metastasis and second primary LSCC in patients with HNSCC in the clinical history, because therapeutic concepts in the two cases might be radically different (as discussed in the corresponding part of this work). In case of individuals with a low stage primary squamous cell carcinoma of the lung, a curative radical resection with lymph node dissection should be favored (Howington et al. 2013; Vansteenkiste et al. 2014). In metastatic cases radical resections should not be carried out, because it might unnecessarily impair respiratory function. On the other hand, patients with second primary LSCC should not be categorised as metastatic and get subjected to palliative therapy. Our results listed here show that our diagnostic setting can be used to reach a diagnostic decision in the majority of the cases and lead to improved clinical decisions.

Further analysis of the survival statistics of the patients would be needed at a later timepoint to confirm, that patient groups with metastatic disease and low stage second primary lung carcinoma have different prognosis.

In cases, in which a diagnostic decision could not be made because there was no TP53 mutation to be found in the head and neck tumor, analysis of a larger group of relevant genes should be considered. With recent advances in the discovery of tumor relevant genes and better understanding of the genetics of these tumors and because of the spread of next generation sequencing technology it is possible that all tumors be categorised as metastasis or second primary, promoting personalised therapy of the patients.

5. Summary

Head and neck squamous cell carcinoma (HNSCC) is a malignant epithelial disease arising from the mucosa of the upper aerodigestive tract. It is the 6th most common malignancy worldwide with approximately 650 000 new cases diagnosed each year. In patients with HNSCC, the chance of acquiring a second malignancy in the lung is about 5.4%. Differentiation between a lung metastasis of a HNSCC and a second primary squamous cell carcinoma of the lung (LSCC) remains one of the most difficult tasks in diagnostic pathology, although differentiation would be crucial because of the highly different therapeutic regimes. In most cases traditional morphological examinations fail to find the origin of the lung tumor, so that a reliable method of differentiation is desperately needed. Differentiation has to be made between two major types of HNSCC; HPV-associated and non-HPV-associated tumors which are caused by tobacco smoking and alcohol consumption and harbor TP53 mutations in most of the cases. Researchers have tried to differentiate between lung metastasis and second primary comparing HPV-status of the head and neck and the lung tumors with some success, but in case of negativity of both tumors further analysis is needed. In the past few years, next generation sequencing technology (NGS) has been established worldwide and also in our institute of pathology. This method has the advantage, that mutations of all coding exons of the TP53 gene can be examined in a time-effective high-throughput way. We hypothesized, that comparing the mutations of the HNSCC and LSCC can lead to a decision on lung tumor origin. In our study 65 head and neck squamous cell carcinomas and lung squamous cell carcinomas of 32 patients were analysed. We combined p16 immunohistochemistry and HPV typing to compare HPV status of the tumors in the hope to differentiate between these two entities in the lung. In case of HPV negativity in both tumors we performed a targeted next generation sequencing of all coding exons (exon 2-11) of the TP53 gene to compare mutation status. With the use of HPV analysis only, a decision on lung tumor origin could be made in 2 of the 32 cases (6%). With the use of targeted next generation sequencing of all coding exons of the TP53 gene we could make a decision in 29 of 32 cases (90%). Analysis of clinical records showed, that lung tumor origin has been identified correctly in only 13 out of 29 cases (45%). Furthermore, 11 out of 23 patients (48%) for whom mutational profiling data had not been available, had not received the most suitable treatment. We conclude, that NGS of all TP53 exons in these tumors can lead to better therapeutic decisions.

6. Summary (german version)

Das Plattenepithelkarzinom der Kopf-Hals-Region (HNSCC) ist eine maligne epitheliale Erkrankung ausgehend von der Mukosa des oberen Aerodigestivtraktes. Es ist die 6. häufigste maligne Erkrankung weltweit mit ca. 650000 neu diagnostizierten Fällen jährlich. Etwa 5,4% der Patienten mit HNSCC entwickeln Zweitmalignome in der Lunge. Unterscheidung zwischen einer Lungenmetastase und einem zweiten Primarius in der Lunge (LSCC) bleibt eine der schwierigsten Aufgaben in der diagnostischen Pathologie. Dabei wäre eine Abgrenzung der beiden Entitäten voneinander entscheidend, da die Therapieprotokolle verschieden sind. In den meisten Fällen können morphologische Untersuchungen die Herkunft des Lungentumors nicht identifizieren, deswegen ist eine vertrauliche diagnostische Methode zwingend notwendig. Es muss zwischen zwei Haupttypen von Tumoren unterschieden werden: HPV-assoziierten und nicht-HPV-assoziierten Tumoren. Die letzteren werden durch Rauchen und Alkoholkonsum verursacht und sind häufig mit TP53 Mutationen assoziiert. Einige Autoren haben versucht, zwischen einer Metastase und einem zweiten Primarius anhand des HPV-Status zu differenzieren. Bei HPV-Negativität im HNSCC und LSCC sind aber weitere diagnostische Maßnahmen notwendig. In den letzten Jahren wurde die Sequenzierung der neuen Generation (NGS) weltweit und auch in unserem Institut für Pathologie etabliert. Diese Methode hat den Vorteil, dass alle kodierenden Exone des TP53 Gens mit hohem Durchsatz und zeiteffektiv sequenziert werden können. In unserer Studie haben wir 65 HNSCC und LSCC von 32 Patienten verglichen. Wir haben p16 Immunohistochemie und HPV-Typisierung kombiniert, in der Hoffnung, dass wir zwischen den zwei Entitäten in der Lunge differenzieren können. Im Falle einer Negativität in dem HNSCC und LSCC haben wir eine targetierte Next-Generation-Sequenzierung der kodierenden Exone (Exon 2-11) des TP53 Gens durchgeführt, um den Mutationsstatus zu vergleichen. Mit der HPV-Analyse konnten wir nur in 2 von 32 Fällen (6%) eine Entscheidung bezüglich der Herkunft des Lungentumors treffen. Mit targetierter NGS konnten wir in 29 von 32 (90%) Fällen eine Entscheidung treffen. Die Analyse der klinischen Daten zeigte, dass die Herkunft des Lungentumors nur in 13 von 29 Fällen (45%) korrekt angegeben wurde. Dementsprechend wurden 11 von 23 (48%) Patienten ohne vorheriger Mutationsanalyse nicht laut Leitlinien therapiert. Wir schlussfolgern daraus, dass NGS von allen kodierenden TP53 Exonen zu besseren therapeutischen Entscheidungen führen kann.

7. List of tables

TABLE 1	15
TABLE 2	16
TABLE 3	17
TABLE 4	17
TABLE 5	18
TABLE 6	33
TABLE 7	35

8. List of figures

FIGURE 1.....	30
FIGURE 2.....	35
FIGURE 3.....	36
FIGURE 4.....	38

9. List of abbreviations

CUP – Center of Unknown Primary

DNA – Deoxyribonucleic Acid

FFPE – Formalin Fixed Paraffin Embedded

HNSCC – Head and Neck Squamous Cell Carcinoma

HPV – Human Papilloma Virus

ISH – In Situ Hybridisation

LOH – Loss of Heterozygosity

LSCC – Lung Squamous Cell Carcinoma

NGS – Next Generation Sequencing

NSCLC – Non-Small Cell Lung Cancer

PCR – Polymerase Chain Reaction

RT – Room Temperature

SCC – Squamous Cell Carcinoma

SCLC – Small Cell Lung Cancer

SSOP – Sequence-Specific Oligonucleotide Probe

TP53 – Tumor Protein 53 Gene

10. Literature

Barnes, Eveson, Reichart, Sidransky 2005: WHO Classification of Tumors of the Head and Neck. 3rd Edition. International Agency for Research on Cancer. Lyon (France).

Edge, Byrd, Compton, Fritz, Greene, Trotti 2010: AJCC Cancer Staging Manual. 7th edition. Springer, New York, NY (USA)

Rosai 2011: Surgical Pathology. 10th edition. Elsevier Ltd, Oxford (UK).

Sternberg 2009: Diagnostic Surgical Pathology. 5th edition. Lippincott Williams & Wilkins. Philadelphia, PA (USA).

Travis, Brambilla, Burke, Marx, Nicholson 2015: WHO Classification of Tumours of Lung, Pleura, Thymus and Heart. 4th edition. International Agency for Research on Cancer. Lyon (France).

11. Bibliography

- Adelstein, David J., Jerrold P. Saxton, Lisa A. Rybicki, Ramon M. Esclamado, Benjamin G. Wood, Marshall Strome, Pierre Lavertu, Robert R. Lorenz, and Marjorie A. Carroll. 2006. "Multiagent Concurrent Chemoradiotherapy for Locoregionally Advanced Squamous Cell Head and Neck Cancer: Mature Results from a Single Institution." *Journal of Clinical Oncology: Official Journal of the American Society of Clinical Oncology* 24 (7):1064–71. <https://doi.org/10.1200/JCO.2005.01.5867>.
- Agrawal, Nishant, Mitchell J. Frederick, Curtis R. Pickering, Chetan Bettegowda, Kyle Chang, Ryan J. Li, Carole Fakhry, et al. 2011. "Exome Sequencing of Head and Neck Squamous Cell Carcinoma Reveals Inactivating Mutations in NOTCH1." *Science (New York, N.Y.)* 333 (6046):1154–57. <https://doi.org/10.1126/science.1206923>.
- Alomari, Ahmed K., Earl J. Glusac, and Jennifer M. McNiff. 2014. "p40 Is a More Specific Marker than p63 for Cutaneous Poorly Differentiated Squamous Cell Carcinoma." *Journal of Cutaneous Pathology* 41 (11):839–45. <https://doi.org/10.1111/cup.12388>.
- Atabek, U., M. A. Mohit-Tabatabai, S. Raina, B. F. Rush, and K. S. Dasmahapatra. 1987. "Lung Cancer in Patients with Head and Neck Cancer. Incidence and Long-Term Survival." *American Journal of Surgery* 154 (4):434–38.
- Barnes, Leon, World Health Organization, and International Agency for Research on Cancer, eds. 2007. *Pathology and Genetics of Head and Neck Tumours: [... Reflects the Views of a Working Group That Convened for an Editorial and Consensus Conference in Lyon, France, July 16 - 19, 2003]*. Reprinted. World Health Organization Classification of Tumours 9. Lyon: IARC Press.
- Bishop, Justin A., Takenori Ogawa, Xiaofei Chang, Peter B. Illei, Edward Gabrielson, Sara I. Pai, and William H. Westra. 2012. "HPV Analysis in Distinguishing Second Primary Tumors from Lung Metastases in Patients with Head and Neck Squamous Cell Carcinoma." *The American Journal of Surgical Pathology* 36 (1):142–48. <https://doi.org/10.1097/PAS.0b013e3182395c7b>.
- Brambilla, E., D. Moro, S. Gazzeri, and C. Brambilla. 1999. "Alterations of Expression of Rb, p16(INK4A) and Cyclin D1 in Non-Small Cell Lung Carcinoma and Their Clinical Significance." *The Journal of Pathology* 188 (4):351–60.

[https://doi.org/10.1002/\(SICI\)1096-9896\(199908\)188:4<351::AID-PATH385>3.0.CO;2-W](https://doi.org/10.1002/(SICI)1096-9896(199908)188:4<351::AID-PATH385>3.0.CO;2-W).

Brauch, H., B. Johnson, J. Hovis, T. Yano, A. Gazdar, O. S. Pettengill, S. Graziano, G. D. Sorenson, B. J. Poiesz, and J. Minna. 1987. "Molecular Analysis of the Short Arm of Chromosome 3 in Small-Cell and Non-Small-Cell Carcinoma of the Lung." *The New England Journal of Medicine* 317 (18):1109–13. <https://doi.org/10.1056/NEJM198710293171803>.

Brennan, J. A., L. Mao, R. H. Hruban, J. O. Boyle, Y. J. Eby, W. M. Koch, S. N. Goodman, and D. Sidransky. 1995. "Molecular Assessment of Histopathological Staging in Squamous-Cell Carcinoma of the Head and Neck." *The New England Journal of Medicine* 332 (7):429–35. <https://doi.org/10.1056/NEJM199502163320704>.

Califano, J., P. L. Leong, W. M. Koch, C. F. Eisenberger, D. Sidransky, and W. H. Westra. 1999. "Second Esophageal Tumors in Patients with Head and Neck Squamous Cell Carcinoma: An Assessment of Clonal Relationships." *Clinical Cancer Research: An Official Journal of the American Association for Cancer Research* 5 (7):1862–67.

Calzolari, A., I. Chiarelli, S. Bianchi, L. Messerini, O. Gallo, B. Porfirio, and P. L. Mattiuz. 1997. "Immunohistochemical vs Molecular Biology Methods. Complementary Techniques for Effective Screening of p53 Alterations in Head and Neck Cancer." *American Journal of Clinical Pathology* 107 (1):7–11.

Chaturvedi, Anil K., Eric A. Engels, William F. Anderson, and Maura L. Gillison. 2008. "Incidence Trends for Human Papillomavirus-Related and -Unrelated Oral Squamous Cell Carcinomas in the United States." *Journal of Clinical Oncology: Official Journal of the American Society of Clinical Oncology* 26 (4):612–19. <https://doi.org/10.1200/JCO.2007.14.1713>.

Chernock, Rebecca D. 2012. "Morphologic Features of Conventional Squamous Cell Carcinoma of the Oropharynx: 'Keratinizing' and 'Nonkeratinizing' Histologic Types as the Basis for a Consistent Classification System." *Head and Neck Pathology* 6 Suppl 1 (July):S41-47. <https://doi.org/10.1007/s12105-012-0373-4>.

Cohen, Ezra E. W., Mark W. Lingen, and Everett E. Vokes. 2004. "The Expanding Role of Systemic Therapy in Head and Neck Cancer." *Journal of Clinical Oncology: Official Journal of the American Society of Clinical Oncology* 22 (9):1743–52. <https://doi.org/10.1200/JCO.2004.06.147>.

- Daher, T., Tur, M.K., Brobeil, A., Etschmann, B., Witte, B., Engenhardt-Cabillic, R., Krombach, G., Blau, W., Grimminger, F., Seeger, W., Klussmann, J.P., Bräuninger, A., Gattenlöhner, S. n.d. “Combined Human Papillomavirus Typing and TP53 Mutation Analysis in Distinguishing Second Primary Tumors from Lung Metastases in Patients with Head and Neck Squamous Cell Carcinoma.” *Head & Neck*. <https://doi.org/10.1002/hed.25041>. Article in press.
- Didkowska, Joanna, Urszula Wojciechowska, Marta Mańczuk, and Jakub Łobaszewski. 2016. “Lung Cancer Epidemiology: Contemporary and Future Challenges Worldwide.” *Annals of Translational Medicine* 4 (8):150. <https://doi.org/10.21037/atm.2016.03.11>.
- Donzelli, Sara, Francesca Biagioni, Francesca Fausti, Sabrina Strano, Giulia Fontemaggi, and Giovanni Blandino. 2008. “Oncogenomic Approaches in Exploring Gain of Function of Mutant p53.” *Current Genomics* 9 (3):200–207. <https://doi.org/10.2174/138920208784340713>.
- Dotto, G. Paolo, and Anil K. Rustgi. 2016. “Squamous Cell Cancers: A Unified Perspective on Biology and Genetics.” *Cancer Cell* 29 (5):622–37. <https://doi.org/10.1016/j.ccell.2016.04.004>.
- Eberhardt, W. E. E., D. De Ruyscher, W. Weder, C. Le Péchoux, P. De Leyn, H. Hoffmann, V. Westeel, et al. 2015. “2nd ESMO Consensus Conference in Lung Cancer: Locally Advanced Stage III Non-Small-Cell Lung Cancer.” *Annals of Oncology: Official Journal of the European Society for Medical Oncology / ESMO* 26 (8):1573–88. <https://doi.org/10.1093/annonc/mdv187>.
- Fakhry, Carole, William H. Westra, Sigui Li, Anthony Cmelak, John A. Ridge, Harlan Pinto, Arlene Forastiere, and Maura L. Gillison. 2008. “Improved Survival of Patients with Human Papillomavirus-Positive Head and Neck Squamous Cell Carcinoma in a Prospective Clinical Trial.” *Journal of the National Cancer Institute* 100 (4):261–69. <https://doi.org/10.1093/jnci/djn011>.
- Ferlay, Jacques, Hai-Rim Shin, Freddie Bray, David Forman, Colin Mathers, and Donald Maxwell Parkin. 2010. “Estimates of Worldwide Burden of Cancer in 2008: GLOBOCAN 2008.” *International Journal of Cancer* 127 (12):2893–2917. <https://doi.org/10.1002/ijc.25516>.
- Franklin, Wilbur A., Robert Veve, Fred R. Hirsch, Barbara A. Helfrich, and Paul A. Bunn. 2002. “Epidermal Growth Factor Receptor Family in Lung Cancer and Premalignancy.” *Seminars in Oncology* 29 (1 Suppl 4):3–14.

- Garcia, S. B., H. S. Park, M. Novelli, and N. A. Wright. 1999. "Field Cancerization, Clonality, and Epithelial Stem Cells: The Spread of Mutated Clones in Epithelial Sheets." *The Journal of Pathology* 187 (1):61–81. [https://doi.org/10.1002/\(SICI\)1096-9896\(199901\)187:1<61::AID-PATH247>3.0.CO;2-I](https://doi.org/10.1002/(SICI)1096-9896(199901)187:1<61::AID-PATH247>3.0.CO;2-I).
- George, Monica. 2014. "Should Patients with HPV-Positive or Negative Tumors Be Treated Differently?" *Current Oncology Reports* 16 (5):384. <https://doi.org/10.1007/s11912-014-0384-2>.
- Geurts, Tom W., Petra M. Nederlof, Michiel W. M. van den Brekel, Laura J. van't Veer, Daphne de Jong, August A. M. Hart, Nico van Zandwijk, Houke Klomp, Alfons J. M. Balm, and Marie-Louise F. van Velthuysen. 2005. "Pulmonary Squamous Cell Carcinoma Following Head and Neck Squamous Cell Carcinoma: Metastasis or Second Primary?" *Clinical Cancer Research: An Official Journal of the American Association for Cancer Research* 11 (18):6608–14. <https://doi.org/10.1158/1078-0432.CCR-05-0257>.
- Greenblatt, M. S., W. P. Bennett, M. Hollstein, and C. C. Harris. 1994. "Mutations in the p53 Tumor Suppressor Gene: Clues to Cancer Etiology and Molecular Pathogenesis." *Cancer Research* 54 (18):4855–78.
- Greene, Frederick L., American Joint Committee on Cancer, and American Cancer Society, eds. 2002. *AJCC Cancer Staging Manual*. 6th ed. New York: Springer-Verlag.
- Ha Lan, Thanh T., Stephanie J. T. Chen, David P. Arps, Douglas R. Fullen, Rajiv M. Patel, Javed Siddiqui, Shannon Carskadon, Nallasivam Palanisamy, and Paul W. Harms. 2014. "Expression of the p40 Isoform of p63 Has High Specificity for Cutaneous Sarcomatoid Squamous Cell Carcinoma." *Journal of Cutaneous Pathology* 41 (11):831–38. <https://doi.org/10.1111/cup.12387>.
- Hartmann, A., H. Blaszyk, R. M. McGovern, J. J. Schroeder, J. Cunningham, E. M. De Vries, J. S. Kovach, and S. S. Sommer. 1995. "p53 Gene Mutations inside and outside of Exons 5-8: The Patterns Differ in Breast and Other Cancers." *Oncogene* 10 (4):681–88.
- Hayashi, Tomayoshi, Hisao Sano, Ryoko Egashira, Kazuhiro Tabata, Tomonori Tanaka, Toshiyuki Nakayama, Yukio Kashima, Takashi Hori, Sayuri Nunomura, and Junya Fukuoka. 2013. "Difference of Morphology and Immunophenotype between Central and Peripheral Squamous Cell Carcinomas of the Lung."

- BioMed Research International* 2013:157838. <https://doi.org/10.1155/2013/157838>.
- Herbst, Roy S. 2004. "Review of Epidermal Growth Factor Receptor Biology." *International Journal of Radiation Oncology, Biology, Physics* 59 (2 Suppl):21–26. <https://doi.org/10.1016/j.ijrobp.2003.11.041>.
- Hittelman, W. N. 2001. "Genetic Instability in Epithelial Tissues at Risk for Cancer." *Annals of the New York Academy of Sciences* 952 (December):1–12.
- Houten, Viola M. M. van, Maarten P. Tabor, Michiel W. M. van den Brekel, J. Alain Kummer, Fedor Denkers, Janny Dijkstra, René Leemans, Isaäc van der Waal, Gordon B. Snow, and Ruud H. Brakenhoff. 2002. "Mutated p53 as a Molecular Marker for the Diagnosis of Head and Neck Cancer." *The Journal of Pathology* 198 (4):476–86. <https://doi.org/10.1002/path.1242>.
- Howington, John A., Matthew G. Blum, Andrew C. Chang, Alex A. Balekian, and Sudish C. Murthy. 2013. "Treatment of Stage I and II Non-Small Cell Lung Cancer: Diagnosis and Management of Lung Cancer, 3rd Ed: American College of Chest Physicians Evidence-Based Clinical Practice Guidelines." *Chest* 143 (5 Suppl):e278S–313S. <https://doi.org/10.1378/chest.12-2359>.
- Iliakis, G. 1997. "Cell Cycle Regulation in Irradiated and Nonirradiated Cells." *Seminars in Oncology* 24 (6):602–15.
- Jedlinski, Adam, Anna Ansell, Ann-Charlotte Johansson, and Karin Roberg. 2013. "EGFR Status and EGFR Ligand Expression Influence the Treatment Response of Head and Neck Cancer Cell Lines." *Journal of Oral Pathology & Medicine: Official Publication of the International Association of Oral Pathologists and the American Academy of Oral Pathology* 42 (1):26–36. <https://doi.org/10.1111/j.1600-0714.2012.01177.x>.
- Kropveld, A., E. H. Rozemuller, F. G. Leppers, K. C. Scheidel, R. A. de Weger, R. Koole, G. J. Hordijk, P. J. Slootweg, and M. G. Tilanus. 1999. "Sequencing Analysis of RNA and DNA of Exons 1 through 11 Shows p53 Gene Alterations to Be Present in Almost 100% of Head and Neck Squamous Cell Cancers." *Laboratory Investigation; a Journal of Technical Methods and Pathology* 79 (3):347–53.
- Leong, P. P., B. Rezai, W. M. Koch, A. Reed, D. Eisele, D. J. Lee, D. Sidransky, J. Jen, and W. H. Westra. 1998. "Distinguishing Second Primary Tumors from Lung Metastases in Patients with Head and Neck Squamous Cell Carcinoma." *Journal of the National Cancer Institute* 90 (13):972–77.

- Lerman, M. I., and J. D. Minna. 2000. "The 630-Kb Lung Cancer Homozygous Deletion Region on Human Chromosome 3p21.3: Identification and Evaluation of the Resident Candidate Tumor Suppressor Genes. The International Lung Cancer Chromosome 3p21.3 Tumor Suppressor Gene Consortium." *Cancer Research* 60 (21):6116–33.
- Licitra, Lisa, Federica Perrone, Paolo Bossi, Simona Suardi, Luigi Mariani, Raffaella Artusi, Maria Oggionni, et al. 2006. "High-Risk Human Papillomavirus Affects Prognosis in Patients with Surgically Treated Oropharyngeal Squamous Cell Carcinoma." *Journal of Clinical Oncology: Official Journal of the American Society of Clinical Oncology* 24 (36):5630–36. <https://doi.org/10.1200/JCO.2005.04.6136>.
- Loeffler-Ragg, Judith, Ilona Schwentner, Georg M. Sprinzl, and Heinz Zwierzina. 2008. "EGFR Inhibition as a Therapy for Head and Neck Squamous Cell Carcinoma." *Expert Opinion on Investigational Drugs* 17 (10):1517–31. <https://doi.org/10.1517/13543784.17.10.1517>.
- Lu, Y. J., X. Y. Dong, J. Shipley, R. G. Zhang, and S. J. Cheng. 1999. "Chromosome 3 Imbalances Are the Most Frequent Aberration Found in Non-Small Cell Lung Carcinoma." *Lung Cancer (Amsterdam, Netherlands)* 23 (1):61–66.
- Lui, Vivian Wai Yan, and Jennifer Rubin Grandis. 2012. "Primary Chemotherapy and Radiation as a Treatment Strategy for HPV-Positive Oropharyngeal Cancer." *Head and Neck Pathology* 6 Suppl 1 (July):S91-97. <https://doi.org/10.1007/s12105-012-0364-5>.
- MacGeoch, C., D. M. Barnes, J. A. Newton, S. Mohammed, S. V. Hodgson, M. Ng, D. T. Bishop, and N. K. Spurr. 1993. "p53 Protein Detected by Immunohistochemical Staining Is Not Always Mutant." *Disease Markers* 11 (5–6):239–50.
- Marur, Shanthi, Gypsyamber D'Souza, William H. Westra, and Arlene A. Forastiere. 2010a. "HPV-Associated Head and Neck Cancer: A Virus-Related Cancer Epidemic." *The Lancet. Oncology* 11 (8):781–89. [https://doi.org/10.1016/S1470-2045\(10\)70017-6](https://doi.org/10.1016/S1470-2045(10)70017-6).
- Marur, Shanthi, Gypsyamber D'Souza, William H Westra, and Arlene A Forastiere. 2010b. "HPV-Associated Head and Neck Cancer: A Virus-Related Cancer

- Epidemic.” *The Lancet Oncology* 11 (8):781–89. [https://doi.org/10.1016/S1470-2045\(10\)70017-6](https://doi.org/10.1016/S1470-2045(10)70017-6).
- Masters, Gregory A., Sarah Temin, Christopher G. Azzoli, Giuseppe Giaccone, Sherman Baker, Julie R. Brahmer, Peter M. Ellis, et al. 2015. “Systemic Therapy for Stage IV Non-Small-Cell Lung Cancer: American Society of Clinical Oncology Clinical Practice Guideline Update.” *Journal of Clinical Oncology: Official Journal of the American Society of Clinical Oncology* 33 (30):3488–3515. <https://doi.org/10.1200/JCO.2015.62.1342>.
- Matlashewski, G., P. Lamb, D. Pim, J. Peacock, L. Crawford, and S. Benchimol. 1984. “Isolation and Characterization of a Human p53 cDNA Clone: Expression of the Human p53 Gene.” *The EMBO Journal* 3 (13):3257–62.
- Mendelsohn, J., and C. P. Dinney. 2001. “The Willet F. Whitmore, Jr., Lectureship: Blockade of Epidermal Growth Factor Receptors as Anticancer Therapy.” *The Journal of Urology* 165 (4):1152–57.
- Nobre, Ana Rita, André Albergaria, and Fernando Schmitt. 2013. “p40: A p63 Isoform Useful for Lung Cancer Diagnosis - a Review of the Physiological and Pathological Role of p63.” *Acta Cytologica* 57 (1):1–8. <https://doi.org/10.1159/000345245>.
- Oijen, M. G. van, F. G. Leppers Vd Straat, M. G. Tilanus, and P. J. Slootweg. 2000. “The Origins of Multiple Squamous Cell Carcinomas in the Aerodigestive Tract.” *Cancer* 88 (4):884–93.
- Pan, Quintin, Michael A. Gorin, and Theodoros N. Teknos. 2009. “Pharmacotherapy of Head and Neck Squamous Cell Carcinoma.” *Expert Opinion on Pharmacotherapy* 10 (14):2291–2302. <https://doi.org/10.1517/14656560903136754>.
- Parkin, D. Max, Freddie Bray, J. Ferlay, and Paola Pisani. 2005. “Global Cancer Statistics, 2002.” *CA: A Cancer Journal for Clinicians* 55 (2):74–108.
- Perri, Francesco, Roberto Pacelli, Giuseppina Della Vittoria Scarpati, Laura Cella, Mario Giuliano, Francesco Caponigro, and Stefano Pepe. 2015. “Radioresistance in Head and Neck Squamous Cell Carcinoma: Biological Bases and Therapeutic Implications.” *Head & Neck* 37 (5):763–70. <https://doi.org/10.1002/hed.23837>.
- Pfeifer, Gerd P., Mikhail F. Denissenko, Magali Olivier, Natalia Tretyakova, Stephen S. Hecht, and Pierre Hainaut. 2002. “Tobacco Smoke Carcinogens, DNA Damage

- and p53 Mutations in Smoking-Associated Cancers.” *Oncogene* 21 (48):7435–51. <https://doi.org/10.1038/sj.onc.1205803>.
- Pignon, Jean-Pierre, H el ene Tribodet, Giorgio V. Scagliotti, Jean-Yves Douillard, Frances A. Shepherd, Richard J. Stephens, Ariane Dunant, et al. 2008. “Lung Adjuvant Cisplatin Evaluation: A Pooled Analysis by the LACE Collaborative Group.” *Journal of Clinical Oncology: Official Journal of the American Society of Clinical Oncology* 26 (21):3552–59. <https://doi.org/10.1200/JCO.2007.13.9030>.
- Pulitzer, Melissa, Garrett Desman, and Klaus J. Busam. 2010. “CK7 Expression in Primary Cutaneous Squamous Cell Carcinoma.” *Journal of Cutaneous Pathology* 37 (9):966–72. <https://doi.org/10.1111/j.1600-0560.2010.01562.x>.
- Rosai, Juan, and Lauren Vedder Ackerman. 2011. *Rosai and Ackerman’s Surgical Pathology. Vol. 2: [...]*. 10th ed. Edinburgh: Elsevier Mosby.
- Ryerson, A. Blythe, Edward S. Peters, Steven S. Coughlin, Vivien W. Chen, Maura L. Gillison, Marsha E. Reichman, Xiaocheng Wu, Anil K. Chaturvedi, and Kelly Kawaoka. 2008. “Burden of Potentially Human Papillomavirus-Associated Cancers of the Oropharynx and Oral Cavity in the US, 1998-2003.” *Cancer* 113 (10 Suppl):2901–9. <https://doi.org/10.1002/cncr.23745>.
- Saunders, M. E., R. MacKenzie, R. Shipman, E. Fransen, R. Gilbert, and R. C. Jordan. 1999. “Patterns of p53 Gene Mutations in Head and Neck Cancer: Full-Length Gene Sequencing and Results of Primary Radiotherapy.” *Clinical Cancer Research: An Official Journal of the American Association for Cancer Research* 5 (9):2455–63.
- Savary, M., P. Monnier, R. Pasche, E. Brossard, P. Pasche, and F. Lang. 1991. “Multiple Primary Malignancies.” *Advances in Oto-Rhino-Laryngology* 46:165–75.
- Scott, Walter J., John Howington, Steven Feigenberg, Benjamin Movsas, Katherine Pisters, and American College of Chest Physicians. 2007. “Treatment of Non-Small Cell Lung Cancer Stage I and Stage II: ACCP Evidence-Based Clinical Practice Guidelines (2nd Edition).” *Chest* 132 (3 Suppl):234S–242S. <https://doi.org/10.1378/chest.07-1378>.
- Sijp, Joost R. M. van der, Jan P. A. M. van Meerbeeck, Alex P. W. M. Maat, Pieter E. Zondervan, Hein F. B. M. Sleddens, Albert N. van Geel, Alex M. M. Eggermont, and Winand N. M. Dinjens. 2002. “Determination of the Molecular

- Relationship between Multiple Tumors within One Patient Is of Clinical Importance.” *Journal of Clinical Oncology: Official Journal of the American Society of Clinical Oncology* 20 (4):1105–14.
- Singhi, Aatur D., and William H. Westra. 2010. “Comparison of Human Papillomavirus in Situ Hybridization and p16 Immunohistochemistry in the Detection of Human Papillomavirus-Associated Head and Neck Cancer Based on a Prospective Clinical Experience.” *Cancer* 116 (9):2166–73. <https://doi.org/10.1002/cncr.25033>.
- Stransky, Nicolas, Ann Marie Egloff, Aaron D. Tward, Aleksandar D. Kostic, Kristian Cibulskis, Andrey Sivachenko, Gregory V. Kryukov, et al. 2011. “The Mutational Landscape of Head and Neck Squamous Cell Carcinoma.” *Science (New York, N.Y.)* 333 (6046):1157–60. <https://doi.org/10.1126/science.1208130>.
- Sweeney, P. J., D. J. Haraf, E. E. Vokes, M. Dougherty, and R. R. Weichselbaum. 1994. “Radiation Therapy in Head and Neck Cancer: Indications and Limitations.” *Seminars in Oncology* 21 (3):296–303.
- Tabor, Maarten P., Ruud H. Brakenhoff, Henrike J. Ruijter-Schippers, Jacqueline E. Van Der Wal, Gordon B. Snow, C. René Leemans, and Boudewijn J. M. Braakhuis. 2002. “Multiple Head and Neck Tumors Frequently Originate from a Single Preneoplastic Lesion.” *The American Journal of Pathology* 161 (3):1051–60. [https://doi.org/10.1016/S0002-9440\(10\)64266-6](https://doi.org/10.1016/S0002-9440(10)64266-6).
- Tabor, Maarten P., Viola M. M. van Houten, J. Alain Kummer, Maria J. W. D. Vosjan, Ronald Vlasblom, Gordon B. Snow, C. René Leemans, Boudewijn J. M. Braakhuis, and Ruud H. Brakenhoff. 2002. “Discordance of Genetic Alterations between Primary Head and Neck Tumors and Corresponding Metastases Associated with Mutational Status of the TP53 Gene.” *Genes, Chromosomes & Cancer* 33 (2):168–77.
- Taylor, S. G., A. K. Murthy, K. L. Griem, D. C. Recine, K. Kiel, C. Blendowski, P. B. Hurst, et al. 1997. “Concomitant cisplatin/5-FU Infusion and Radiotherapy in Advanced Head and Neck Cancer: 8-Year Analysis of Results.” *Head & Neck* 19 (8):684–91.
- Torre, Lindsey A., Freddie Bray, Rebecca L. Siegel, Jacques Ferlay, Joannie Lortet-Tieulent, and Ahmedin Jemal. 2015. “Global Cancer Statistics, 2012.” *CA: A Cancer Journal for Clinicians* 65 (2):87–108. <https://doi.org/10.3322/caac.21262>.

- Travis, William D., World Health Organization, International Agency for Research on Cancer, International Association for the Study of Lung Cancer, and International Academy of Pathology, eds. 2004. *Pathology and Genetics of Tumours of the Lung, Pleura, Thymus and Heart*. World Health Organization Classification of Tumours 7. Lyon : Oxford: IARC Press, Oxford University Press (distributor).
- Vansteenkiste, J., L. Crinò, C. Doooms, J. Y. Douillard, C. Faivre-Finn, E. Lim, G. Rocco, et al. 2014. “2nd ESMO Consensus Conference on Lung Cancer: Early-Stage Non-Small-Cell Lung Cancer Consensus on Diagnosis, Treatment and Follow-Up.” *Annals of Oncology: Official Journal of the European Society for Medical Oncology / ESMO* 25 (8):1462–74. <https://doi.org/10.1093/annonc/mdu089>.
- Vermorken, Jan B., Ricard Mesia, Fernando Rivera, Eva Remenar, Andrzej Kawecki, Sylvie Rottey, Jozsef Erfan, et al. 2008. “Platinum-Based Chemotherapy plus Cetuximab in Head and Neck Cancer.” *The New England Journal of Medicine* 359 (11):1116–27. <https://doi.org/10.1056/NEJMoa0802656>.
- Vokes, E. E., R. R. Weichselbaum, S. M. Lippman, and W. K. Hong. 1993. “Head and Neck Cancer.” *The New England Journal of Medicine* 328 (3):184–94. <https://doi.org/10.1056/NEJM199301213280306>.
- Weichert, Wilko, Christiane Schewe, Carsten Denkert, Lars Morawietz, Manfred Dietel, and Iver Petersen. 2009. “Molecular HPV Typing as a Diagnostic Tool to Discriminate Primary from Metastatic Squamous Cell Carcinoma of the Lung.” *The American Journal of Surgical Pathology* 33 (4):513–20. <https://doi.org/10.1097/PAS.0b013e3181938319>.
- Weinberger, Paul M., Ziwei Yu, Bruce G. Haffty, Diane Kowalski, Malini Harigopal, Janet Brandsma, Clarence Sasaki, et al. 2006. “Molecular Classification Identifies a Subset of Human Papillomavirus--Associated Oropharyngeal Cancers with Favorable Prognosis.” *Journal of Clinical Oncology: Official Journal of the American Society of Clinical Oncology* 24 (5):736–47. <https://doi.org/10.1200/JCO.2004.00.3335>.
- Westra, William H., Janis M. Taube, M. L. Poeta, Shanaz Begum, David Sidransky, and Wayne M. Koch. 2008. “Inverse Relationship between Human Papillomavirus-16 Infection and Disruptive p53 Gene Mutations in Squamous Cell Carcinoma

- of the Head and Neck.” *Clinical Cancer Research: An Official Journal of the American Association for Cancer Research* 14 (2):366–69. <https://doi.org/10.1158/1078-0432.CCR-07-1402>.
- Whang, Sonia N., Maria Filippova, and Penelope Duerksen-Hughes. 2015. “Recent Progress in Therapeutic Treatments and Screening Strategies for the Prevention and Treatment of HPV-Associated Head and Neck Cancer.” *Viruses* 7 (9):5040–65. <https://doi.org/10.3390/v7092860>.
- Wiest, Tina, Elisabeth Schwarz, Christel Enders, Christa Flechtenmacher, and Franz X. Bosch. 2002. “Involvement of Intact HPV16 E6/E7 Gene Expression in Head and Neck Cancers with Unaltered p53 Status and Perturbed pRb Cell Cycle Control.” *Oncogene* 21 (10):1510–17. <https://doi.org/10.1038/sj.onc.1205214>.

12. List of publications and congress contributions

Daher, T., Tur, M.K., Brobeil, A., Etschmann, B., Witte, B., Engenhardt-Cabillic, R., Krombach, G., Blau, W., Grimminger, F., Seeger, W., Klussmann, J.P., Bräuninger, A., Gattenlöhner, S. Combined human papillomavirus typing and TP53 mutation analysis in distinguishing second primary tumors from lung metastases in patients with head and neck squamous cell carcinoma. *Head Neck*. DOI:10.1002/hed.25041. Article in press.

ABSTRACT

Background: In head and neck squamous cell carcinoma (HNSCC), the occurrence of concurrent lung malignancies poses a significant diagnostic challenge because metastatic HNSCC is difficult to discern from second primary lung squamous cell carcinoma (LSCC). However, this differentiation is crucial because the recommended treatments for metastatic HNSCC and second primary LSCC differ profoundly.

Methods: We analyzed lung tumors origin in 32 HNSCC patients using human papilloma virus (HPV) typing and targeted next generation sequencing of all coding exons of tumor protein 53 (TP53).

Results: Lung tumors were clearly identified as HNSCC metastases or second primary tumors in 29 patients, thus revealing that 16 patients had received incorrect diagnoses based on clinical and morphological data alone.

Conclusions: HPV typing and mutation analysis of all TP53 coding exons is a valuable diagnostic tool in patients with HNSCC and concurrent LSCC which can help to ensure that patients receive the most suitable treatment.

Daher, T., Witte, B., Klußmann, J.P., Blau, W., Steiner, D., Engenhardt-Cabillic, R., Bräuninger, A., Gattenlöhner, S. Pulmonale Raumforderung bei einem Patienten mit einem Hypopharynxkarzinom in der Vorgeschichte: Metastase oder zweiter Primarius? *101. Tagung der Deutschen Gesellschaft für Pathologie (2017)*, congress contribution in german language.

ABSTRACT

Anamnesis: A pulmonary neoplasm of the left lung has been incidentally described in a 72 year old male patient. The patient had been diagnosed with a hypopharyngeal squamous cell carcinoma 54 months earlier. The hypopharyngeal tumor had been successfully resected (Tumorstadium: pT2, pN2b (2/39), L0, V0, G3, R0). A CT-guided biopsy of the neoplasm followed. On the biopsy material a squamous cell carcinoma was diagnosed in an external institution. The therapy of choice was pneumectomy combined with regional lymph node dissection.

Examinations: Using conventional histomorphological methods it was not to decide, whether it is a metastasis of the laryngeal carcinoma or a second primary squamous cell carcinoma of the lung. To find it out, a comparative HPV analysis and after that targeted next generation sequencing of the coding exons of the TP53 gene was carried out in both tumors.

Diagnosis, therapy and clinical course: The mutation analysis showed the same mutations in the head and neck and in the lung tumor. Corresponding to this, seven months after the lung tumor resection, further metastases were discovered in the contralateral lung.

Conclusion: Therapy of low stage primary squamous cell carcinoma and metastatic squamous cell carcinoma is drastically different. In metastatic cases a radical resection of the lung tumor is not indicated. In case of newly diagnosed pulmonary neoplasms in patients with head and neck squamous cell carcinoma in the patient history a molecular pathological analysis should be carried out already on the biopsy material before resection, if possible. This may help to differentiate between lung metastasis and second primary and help to guide therapeutic decisions.

13. Acknowledgements

I would like to thank Prof. Dr. Stefan Gattenlöhner, Prof. Dr. Andreas Bräuninger and Dr. Alexander Brobeil for their supervision of this project. Without their expert guidance this work would not have come to existence. Furthermore, I would like to thank all my colleagues in the routine and immunohistochemistry laboratory for their contribution, as well as all colleagues in the molecular pathology department for helping my work, with special thanks to Cindy Arnold for her expert assistance in the NGS experiments.

14. Affirmation

„Hiermit erkläre ich, dass ich die vorliegende Arbeit selbständig und ohne unzulässige Hilfe oder Benutzung anderer als der angegebenen Hilfsmittel angefertigt habe. Alle Textstellen, die wörtlich oder sinngemäß aus veröffentlichten oder nichtveröffentlichten Schriften entnommen sind, und alle Angaben, die auf mündlichen Auskünften beruhen, sind als solche kenntlich gemacht. Bei den von mir durchgeführten und in der Dissertation erwähnten Untersuchungen habe ich die Grundsätze guter wissenschaftlicher Praxis, wie sie in der „Satzung der Justus-Liebig-Universität Gießen zur Sicherung guter wissenschaftlicher Praxis“ niedergelegt sind, eingehalten sowie ethische, datenschutzrechtliche und tierschutzrechtliche Grundsätze befolgt. Ich versichere, dass Dritte von mir weder unmittelbar noch mittelbar geldwerte Leistungen für Arbeiten erhalten haben, die im Zusammenhang mit dem Inhalt der vorgelegten Dissertation stehen, oder habe diese nachstehend spezifiziert. Die vorgelegte Arbeit wurde weder im Inland noch im Ausland in gleicher oder ähnlicher Form einer anderen Prüfungsbehörde zum Zweck einer Promotion oder eines anderen Prüfungsverfahrens vorgelegt. Alles aus anderen Quellen und von anderen Personen übernommene Material, das in der Arbeit verwendet wurde oder auf das direkt Bezug genommen wird, wurde als solches kenntlich gemacht. Insbesondere wurden alle Personen genannt, die direkt und indirekt an der Entstehung der vorliegenden Arbeit beteiligt waren. Mit der Überprüfung meiner Arbeit durch eine Plagiatserkennungssoftware bzw. ein internetbasiertes Softwareprogramm erkläre ich mich einverstanden.“

Ort, Datum

Unterschrift