

## ORIGINAL ARTICLE

# Recessive germline *SDHA* and *SDHB* mutations causing leukodystrophy and isolated mitochondrial complex II deficiency

Charlotte L Alston,<sup>1</sup> James E Davison,<sup>2,3</sup> Francesca Meloni,<sup>4</sup> Francois H van der Westhuizen,<sup>1,5</sup> Langping He,<sup>1</sup> Hue-Tran Hornig-Do,<sup>1</sup> Andrew C Peet,<sup>2,6</sup> Paul Gissen,<sup>7,8</sup> Paola Goffrini,<sup>4</sup> Ileana Ferrero,<sup>4</sup> Evangeline Wassmer,<sup>2</sup> Robert McFarland,<sup>1</sup> Robert W Taylor<sup>1</sup><sup>1</sup>Wellcome Trust Centre for Mitochondrial Research, Newcastle University, Newcastle upon Tyne, UK<sup>2</sup>Birmingham Children's Hospital, Birmingham, UK<sup>3</sup>School of Clinical & Experimental Medicine, University of Birmingham, Birmingham, UK<sup>4</sup>Department of Genetics, Biology of Microorganisms, Anthropology and Evolution, University of Parma, Parma, Italy<sup>5</sup>Centre for Human Metabonomics, North-West University, Potchefstroom, South Africa<sup>6</sup>Cancer Sciences, University of Birmingham, Birmingham, UK<sup>7</sup>UCL Institute of Child Health, London, UK<sup>8</sup>Great Ormond Street Hospital for Children NHS Trust, London, UK**Correspondence to**

Professor Robert W Taylor, Wellcome Trust Centre for Mitochondrial Research, Institute for Ageing and Health, Medical School, Newcastle University, Newcastle upon Tyne NE2 4HH, UK; robert.taylor@ncl.ac.uk

Received 28 June 2012

Revised 20 July 2012

Accepted 20 July 2012

**ABSTRACT****Background** Isolated complex II deficiency is a rare form of mitochondrial disease, accounting for approximately 2% of all respiratory chain deficiency diagnoses. The succinate dehydrogenase (SDH) genes (*SDHA*, *SDHB*, *SDHC* and *SDHD*) are autosomally-encoded and transcribe the conjugated heterotetramers of complex II via the action of two known assembly factors (*SDHAF1* and *SDHAF2*). Only a handful of reports describe inherited *SDH* gene defects as a cause of paediatric mitochondrial disease, involving either *SDHA* (Leigh syndrome, cardiomyopathy) or *SDHAF1* (infantile leukoencephalopathy). However, all four *SDH* genes, together with *SDHAF2*, have known tumour suppressor functions, with numerous germline and somatic mutations reported in association with hereditary cancer syndromes, including paraganglioma and pheochromocytoma.**Methods and results** Here, we report the clinical and molecular investigations of two patients with histochemical and biochemical evidence of a severe, isolated complex II deficiency due to novel *SDH* gene mutations; the first patient presented with cardiomyopathy and leukodystrophy due to compound heterozygous p.Thr508Ile and p.Ser509Leu *SDHA* mutations, while the second patient presented with hypotonia and leukodystrophy with elevated brain succinate demonstrated by MR spectroscopy due to a novel, homozygous p.Asp48Val *SDHB* mutation. Western blotting and BN-PAGE studies confirmed decreased steady-state levels of the relevant SDH subunits and impairment of complex II assembly. Evidence from yeast complementation studies provided additional support for pathogenicity of the *SDHB* mutation.**Conclusions** Our report represents the first example of *SDHB* mutation as a cause of inherited mitochondrial respiratory chain disease and extends the *SDHA* mutation spectrum in patients with isolated complex II deficiency.**INTRODUCTION**

In eukaryotic cells, the mitochondrial oxidative phosphorylation (OXPHOS) pathway is the primary mechanism for ATP production. This OXPHOS system comprises five transmembrane complexes consisting of ~90 protein subunits that are encoded by the mitochondria's own genetic material (mtDNA) and the nuclear genome. Electrons,

supplied by the oxidation of fat and carbohydrates, are transferred through the mitochondrial respiratory chain complexes to complex V, where oxygen acts as the ultimate electron acceptor. Coincident with electron transfer is the extrusion of protons across the inner membrane from the matrix to the intermembrane space, creating an electrochemical gradient which is dissipated through complex V (ATP synthase) driving the phosphorylation of ADP to form ATP. Mitochondrial respiratory chain disease represents a major inborn error of metabolism and is caused by defective OXPHOS.<sup>1</sup> Mitochondrial disease is associated with both a varied age of onset and a diverse phenotypic spectrum.<sup>2</sup> The hallmark clinical and genetic heterogeneity is often compounded further by the lack of clear genotype-phenotype correlations. Biochemical assessment of respiratory chain complex activities can often provide guidance for the genetic testing strategy, but uncovering the underlying genetic defect can be difficult. For many patients, especially children, the genetic aetiology of their condition remains unknown.Complex II differs from the other complexes of the mitochondrial respiratory chain in that its four structural subunits (*SDHA*, *SDHB*, *SDHC* and *SDHD*) and two known assembly factor genes (*SDHAF1* and *SDHAF2*) are all nuclear-encoded. The soluble flavoprotein (Fp/*SDHA*) and iron-sulphur (Fe-S/*SDHB*) proteins, encoded by *SDHA* and *SDHB*, respectively, have catalytic activity and together form succinate dehydrogenase (SDH), while the *SDHC* and *SDHD* subunits act to anchor the complex to the inner mitochondrial membrane and its interaction with the quinone pool.<sup>3</sup> Complex II is also unique in that it is part of both the respiratory chain and the Krebs cycle.Mitochondrial disease presentations associated with an isolated deficiency of complex II are rare, accounting for an estimated 2% of respiratory chain deficiencies.<sup>4–5</sup> Reported cases have presented in childhood with Leigh syndrome,<sup>4–8</sup> a fatal respiratory disease with severe hypoglycaemia,<sup>9</sup> neonatal cardiomyopathy<sup>10</sup> and an infantile leukoencephalopathy.<sup>11</sup> The only reported exception to these childhood presentations is the report of two sisters with an adult-onset phenotype characterised by progressive optic atrophy, ataxia and myopathy.<sup>12</sup>This paper is freely available online under the BMJ Journals unlocked scheme, see <http://jmg.bmj.com/site/about/unlocked.xhtml>

In addition to primary mitochondrial disease presentations, germline mutations in *SDHA*,<sup>13</sup> *SDHB*,<sup>14</sup> *SDHC*,<sup>15</sup> *SDHD*<sup>16 17</sup> and *SDHAF2*<sup>18</sup> are recognised causes of familial pheochromocytomas and paragangliomas, thus establishing a link between SDH deficiency and susceptibility to tumourigenesis.<sup>19</sup> The factors determining whether *SDH* defects lead to neurological disease or impaired tumour suppression are poorly understood, yet both are related to loss of enzyme activity and perturbation of the complex formation. On account of its similarity with the human enzyme, the *Saccharomyces cerevisiae* has proven a useful model system to study the effects of *SDH* gene mutations, in particular germline missense mutations associated with paraganglioma development.<sup>20</sup>

Here, we report two paediatric patients presenting with leukoencephalopathy with isolated complex II deficiency in whom molecular investigations revealed novel compound heterozygous p.Thr508Ile and p.Ser509Leu *SDHA* mutations in one patient, and a novel, homozygous p.Asp48Val *SDHB* mutation in the second. This represents the first example of *SDHB*-related pathology in association with a primary mitochondrial disease presentation, with pathogenicity confirmed by functional modelling studies in yeast.

## SUBJECT AND METHODS

### Patient 1

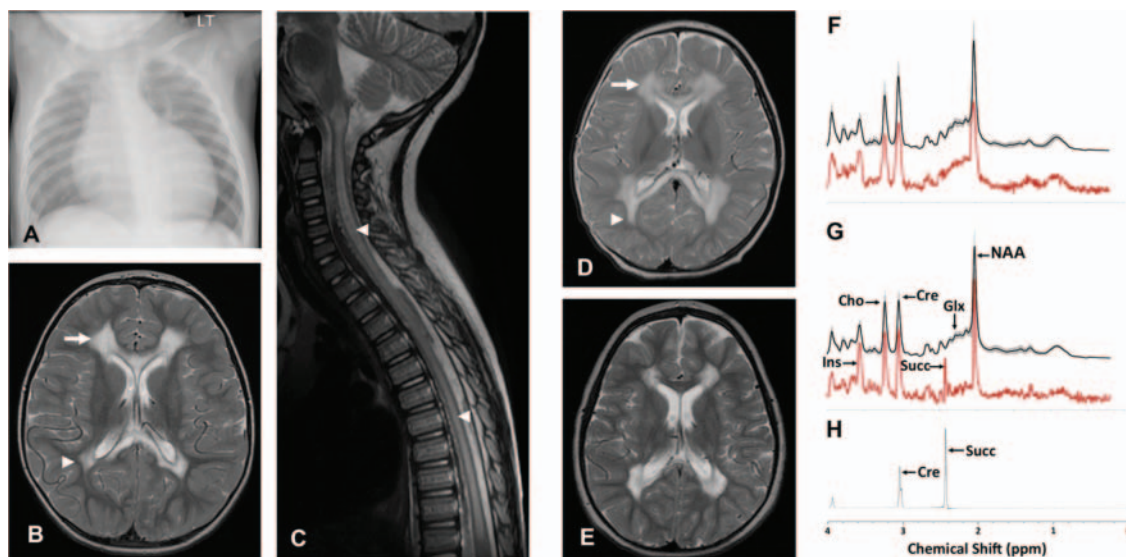
Patient 1 is a male child born at term to non-consanguineous, mixed ethnicity parents following an uncomplicated pregnancy. He was well during the neonatal period, but at 3 months of age he presented with increasing dyspnoea, sweating and difficulty feeding. Cardiomegaly was evident on chest radiograph (figure 1A) while echocardiogram demonstrated ischaemia and a dilated and markedly hypertrophied left ventricle, with a degree of non-compaction of the left ventricular myocardium and a fractional shortening of only 10%. Cardiac catheter investigation demonstrated no abnormality of the coronary arteries, and he was diagnosed with dilated cardiomyopathy. Cardiac function improved and stabilised with short-term inotropic support, ongoing diuretic therapy and ACE inhibitors.

Initial development was satisfactory so that by 8 months of age he could sit unsupported, roll over, pull to stand and was babbling. However, motor delay was noted by 18 months of age. At review at 2.5 years of age, he was able to stand, but with knees and hips in flexion due to contractures. He had a few single words of speech. Examination revealed generalised hypertonia in all limbs with brisk deep tendon reflexes and bilateral upgoing plantar response.

Cranial and spinal MRI at 2.5 years age (figure 1B) demonstrated extensive cystic change and abnormal high T2 and FLAIR signal in the central cerebral white matter symmetrically and bilaterally, with scattered peripheral foci of abnormal signal in the frontal lobes. There was also abnormal signal in the anterior and posterior corpus callosum, ventral pons, medulla and throughout the majority of the grey matter of the spinal cord (figure 1C). Metabolic investigations included normal random plasma lactate (1.5 mmol/l). Acylcarnitine profile demonstrated increased acetyl and hydroxybutyryl carnitines consistent with ketosis/lactic acidosis, with a normal free carnitine concentration. Urinary amino acids were normal, while organic acids demonstrated raised lactate, ketones and 3-hydroxyisovalerate and elevated tricarboxylic acid cycle metabolites (succinate, fumarate and 2-ketoglutarate). A diagnostic open skeletal muscle biopsy was obtained at 3 years of age.

### Patient 2

Patient 2 is a female child born at term to consanguineous Asian parents. There were no antenatal or perinatal complications, no previous history of miscarriages, and two older siblings are alive and well. Growth and developmental milestones were normal until 1 year of age by which time she could cruise around furniture and was babbling. Subsequently, over a 6-week period, she lost the ability to walk, became unsteady and had repeated falls. There was no associated head injury or febrile illness. She became very hypotonic with poor head control and difficulty feeding. After the 6-week period of deterioration she made slow developmental progress, and there were no further episodes of developmental regression. By the age of 4 years, she could stand



**Figure 1** (B) Axial T2-weighted MR image of Patient 1's brain demonstrates high signal intensity in frontal (arrow) and peritrigonal (arrow head) white matter sparing subcortical U-fibres, normal basal ganglia whilst the sagittal T2-weighted spinal image (C) demonstrates extensive high signal intensity in spinal cord grey matter (arrow heads).

briefly with support although remains wheelchair-dependent, having developed flexion contractures in both her arms and legs.

MRI acquired at the initial presentation (figure 1D) revealed leukodystrophy with extensive signal changes in the deep cerebral white matter, sparing U-fibres, with abnormalities also present in cerebellum and brainstem. A repeat brain MRI study at 4.5 years (figure 1E) revealed a similar pattern of abnormalities but with cyst formation in the abnormal white matter, and persistent signal abnormalities in the corpus callosum. The short echo time MR spectroscopy of the dystrophic white matter (figure 1G) demonstrated the presence of a singlet lactate peak at 2.4 ppm, seen also in long echo time (not shown) but not detected in a control group or in the normal appearing basal ganglia of patient 2 (figure 1H),<sup>21</sup> confirming the accumulation of succinate in the dystrophic white matter *in vivo*. The metabolite profile of the white matter also demonstrated significantly decreased glutamine and glutamate, relative preservation of the neuronal marker N-acetylaspartate and increased myo-inositol compared with a previously reported age-matched cohort.<sup>22</sup> The metabolite profile of the unaffected basal ganglia appeared relatively normal with no succinate detected (figure 1F).

Metabolic investigations demonstrated normal plasma, very long chain fatty acids, carnitine profile, amino acids, ammonia and lactate. Urinary organic and amino acids, glycosaminoglycans and oligosaccharides were also normal, as were cerebrospinal fluid glucose and lactate. A diagnostic open skeletal muscle biopsy was obtained at age 5 years.

### Muscle histology and biochemistry

Informed consents with appropriate ethics review committee approvals were obtained. Histological and histochemical analyses were performed on 10 µm transversely-orientated serial cryosections of skeletal muscle biopsy samples using standard procedures. The activities of individual respiratory chain complex activities and citrate synthase, a mitochondrial matrix marker, were determined in muscle homogenates as previously described.<sup>23</sup>

### Molecular genetics

Total genomic DNA was obtained using standard methods and the coding region plus intron–exon boundaries of the *SDHA*, *SDHB* and *SDHAF1* genes were amplified using locus specific primers (sequences available upon request). Amplicons were sequenced using the BigDye v3.1 kit and capillary electrophoresed on the ABI3130×1 fluorescent sequencing platform (Life Technologies, Warrington, UK). Chromatograms were compared with appropriate GenBank reference sequences (*SDHAF1*: NM\_001042631.2; *SDHA*: NM\_004168.2; and *SDHB*: NM\_003000.2). All sequence variants were cross-referenced against dbSNP (build 135) and all variants of unknown pathological significance were investigated using *in silico* methodologies.<sup>24–27</sup>

### In silico prediction tools

Amino acid residue conservation and predicted impact of the novel *SDHA* and *SDHB* variants were investigated using Ensembl release 66,<sup>24</sup> Polyphen2,<sup>25</sup> SIFT<sup>26</sup> and AlignGVGD.<sup>27</sup> Putative effects of the novel *SDHB* variant on SDHB tertiary structure were proposed using Phyre2,<sup>28</sup> while residue interactions between the SDH subunits were characterised using Piccolo.<sup>29</sup> Sequence alignment for mutation analysis was performed with Clustal<sup>30</sup> and BLAST.<sup>31</sup>

### BN-PAGE and SDS-PAGE

Blue native polyacrylamide gel electrophoresis (BN-PAGE) was used to investigate the native structures of respiratory chain enzymes. For BN-PAGE, the NativePAGE Novex Bis-Tris Gel and blot transfer system was used and samples were run using precast 4%–16% Bis-Tris gels (Invitrogen, Carlsbad, California, USA). For Patient 2 and two aged-matched controls, enriched mitochondria were prepared from muscle using differential centrifugation after homogenisation in Medium A (120 mM KCl, 20 mM HEPES, 5 mM MgCl<sub>2</sub>, 1 mM EGTA, pH 7.2). For Patient 1 and two separate paediatric controls, mitochondria were isolated from cultured fibroblasts as described<sup>32</sup> using anti-TOM22 coated MicroBead system (Miltenyi Biotec, Bergisch Gladbach, Germany). Protein content was determined using Bradford reagent (Bio-Rad, Hercules, California, USA) and between 2 and 10 µg of mitochondria were loaded, depending on the postrun analysis. For Patient 1 and controls, complex I ingel activity analysis was performed.<sup>33</sup> Following western blot transfer of BN-PAGE gels, complexes I and II were probed with mouse antihuman immunoglobulin directed at NDUFA9 and the flavoprotein and iron–sulphur subunits of SDH, respectively. All primary antibodies, except TOM20 (Santa Cruz, Biotechnology, Santa Cruz, California, USA), were purchased from Mitosciences/Abcam (Cambridge, UK).

Proteins were separated by SDS-PAGE, transferred and membranes probed with antibodies against SDHA, SDHB and NDUFB8 as well as porin or TOM20 (as mitochondrial loading markers). For detection, blots were treated with appropriate HRP-conjugated immunoglobulins (Dako, Glostrup, Denmark), followed by ChemiLucent detection reagents (GE Healthcare, Buckinghamshire, UK).

### Yeast strains and culture conditions

Yeast strains, BY4741 (MATa; his3D1 leu2D0 lys2D0 ura3D0) and its isogenic *sdh2:kanMX4* mutant, were transformed using the lithium acetate method.<sup>34</sup> Restriction-enzyme digestions, *Escherichia coli* transformation and plasmid extractions were performed using standard methods.<sup>35</sup>

Cells were cultured in yeast nitrogen base (YNB) medium (0.67% YNB without amino acids (ForMedium, Hunstanton, UK)) supplemented with 1 g/l of drop-out powder<sup>36</sup> containing all amino acids except those required for plasmid maintenance. Various carbon sources were added at 2% (w/v) (Carlo Erba Reagents, Milan, Italy). Media were solidified with 20 g/l agar (ForMedium). For respiration and mitochondria extraction, cells were grown to late-log phase in the YNB medium supplemented with 0.6% glucose.

### Construction of yeast mutant alleles

The *sdh2* p.Asn42Asp and p.Asn42Val mutant alleles were obtained by site-directed mutagenesis using the overlap extension technique.<sup>37</sup> In the first set of PCR reactions, the SDH2 region was obtained using the forward primer HSDH2F-CGCGAAGCTTGCTGAGGTGCAAATGGCCACCC and the following reverse mutagenic primers RS242ND-GGTTTAGCACTTGGCTCGTCTGGG**TCC**CACTGTAAACTTTAAAAG and RS242NV-GGTTTAGCACTTGGCTCGTCTGG**CACCC**CACTGTAAACTTTAAAAG where base changes are indicated in bold. The second SDH2 region was obtained using the forward mutagenic primers FS242ND and FS242NV, complementary to RS242ND and RS242NV, and the reverse primer SSDH2R-CCCCGTCGCCACCTTGTCGCCTATGATGG. The final mutagenised products were obtained using the overlapping

PCR fragments as template with HSDH2F and SSDH2R as external primers. The products were then digested with *HindIII* and *Sall* and cloned in *HindIII-Sall* digested pFL38 centromeric plasmid.<sup>38</sup>

#### Isolation of mitochondria, enzyme assays and respiration

Oxygen uptake was measured at 30°C using a Clark-type oxygen electrode in a 1 ml stirred chamber containing 1 ml of air-saturated respiration buffer (0.1 M phthalate-KOH, pH 5.0) and 10 mM glucose (Oxygraph System, Hansatech Instruments, England). The reaction was initiated with the addition of 20 mg of wet weight of cells, as described.<sup>20</sup> Preparation of mitochondria and SDH activity (expressed as nmol/min/mg protein) were also performed as described.<sup>20</sup>

## RESULTS

### Histological, histochemical and respiratory chain analyses

The histological examination of diagnostic skeletal muscle biopsies was normal for both patients, with the exception of a few atrophic fibres in Patient 1, and a subtle increase in intrafibre lipid content for Patient 2 (figure 2). Histochemical analysis of both patients' biopsies demonstrated normal cytochrome *c* oxidase reactions, with no evidence of mitochondrial proliferation, but severe deficiencies in SDH activity (figure 2C,G) compared with age-matched control muscle. This was confirmed by the spectrophotometric assay of respiratory chain activities, which demonstrated a severe and isolated deficiency involving complex II in muscle homogenates from both patients (table 1).

### Molecular genetic analysis

Sequencing of the *SDHAF1* gene in both patients revealed no known or potentially pathogenic mutations. Analysis of the coding region of the *SDHA* gene in Patient 1 revealed two novel heterozygous variants affecting adjacent amino acids within exon 11; a c.1523C>T transition predicting a p.Thr508Ile substitution and a c.1526C>T transition predicting a p.Ser509Leu substitution within the catalytic flavoprotein subunit of complex II (figure 3A). The lack of an *SDHA* or *SDHAF1* defect

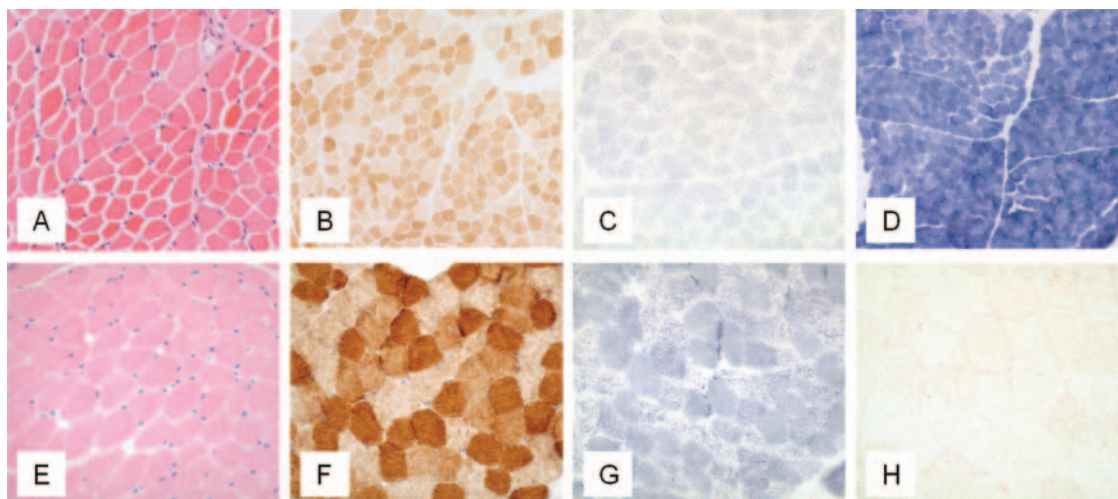
in Patient 2 prompted analysis of the *SDHB* gene, identifying a novel homozygous c.143A>T *SDHB* transversion in exon 2 that predicts a p.Asp48Val substitution within the catalytic iron-sulphur subunit of SDH (figure 3B). Recessive inheritance of all variant alleles was confirmed by screening parental DNA samples (see figure 3A,B). In silico predictions regarding the putative functional effects of the p.Thr508Ile and p.Ser509Leu *SDHA* and p.Asp48Val *SDHB* variants supported a deleterious aetiology. Phyre2 and Piccolo modelling revealed no obvious conformational differences between predicted tertiary structures of the wild-type and mutant *SDHA* and *SDHB* proteins.

### Western blotting

To assess the impact of the novel *SDHA* and *SDHB* variants on the steady-state levels of complex II and the respective subunits' stability, BN-PAGE and SDS-PAGE analyses were performed on available material from the two patients. BN-PAGE analysis using isolated mitochondria from cultured fibroblasts of Patient 1 revealed a significantly decreased amount of fully assembled complex II compared with aged-matched controls (figure 4A). In contrast, comparatively higher complex I in-gel activities were noted in this patient. SDS-PAGE analysis confirmed an almost complete absence of *SDHA* in the patient, relative to the mitochondrial loading marker, porin. BN-PAGE analysis using enriched skeletal muscle mitochondria from Patient 2 showed a relative lower amount of fully assembled complex II compared with complex I (figure 4B), while SDS-PAGE analysis demonstrated an almost complete absence of the *SDHB* subunit compared to both control samples and mitochondrial loading controls. In addition, expression of the *SDHA* subunit of complex II also appeared to be decreased, suggesting instability of the assembled complex.

### Complementation studies in yeast of human *SDHB* mutant alleles

To validate the pathogenic role of the p.Asp48Val *SDHB* mutation in Patient 2, we performed complementation studies using the *Saccharomyces cerevisiae* strain BY4741, deleted in the *SDH2* gene (the yeast orthologue of mammalian *SDHB*), hereafter



**Figure 2** (A–C) H&E staining, cytochrome *c* oxidase (COX) histochemistry and succinate dehydrogenase (SDH) histochemistry respectively, for Patient 1, indicating a marked decrease in the activity of SDH (C) compared with a control SDH reaction (D). (E–H) Images from the muscle biopsy of Patient 2 including H&E staining (E), COX histochemistry reactivity (F), SDH histochemistry reactivity (G) and the Oil Red O stain (H), the last highlighting a very subtle increase in intrafibre lipid.

**Table 1** Assessment of patient respiratory chain complex activities in skeletal muscle homogenate

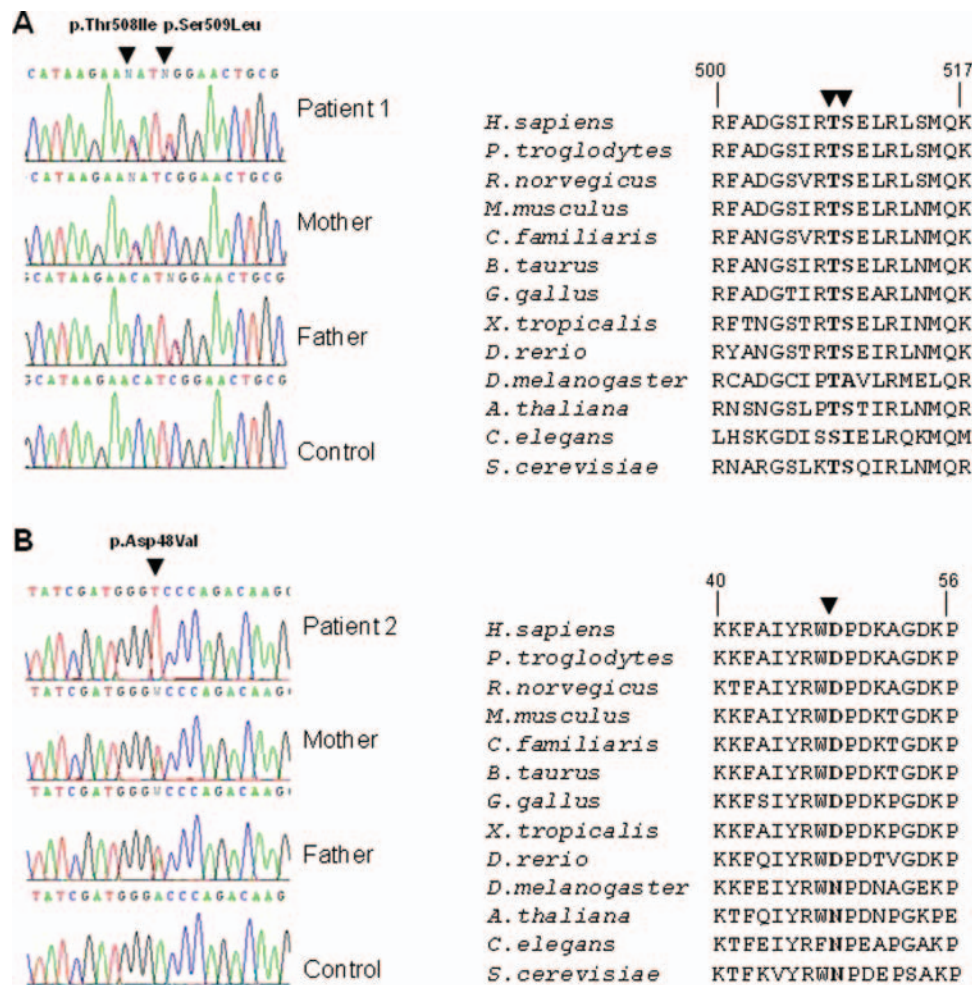
	Complex I/CS	Complex II/CS	Complex III/CS	Complex IV/CS
Patient 1	0.065	0.022	1.158	0.701
Patient 2	0.182	0.049	0.705	0.475
Controls (n=25)	0.104±0.036	0.145±0.047	0.554±0.345	1.124±0.511

Enzyme activities are expressed as nmol NADH oxidised min/unit citrate synthase (CS)<sup>-1</sup> for complex I, nmol DCPIP reduced min/unit citrate synthase<sup>-1</sup> for complex II (succinate to ubiquinone-1 reductase) and the apparent first-order rate constant s/ unit citrate synthase<sup>-1</sup> for complexes III and IV ( $\times 10^3$ ). Control values are shown as mean±SD. DCPIP, 2,6-dichlorophenol-indophenol.

referred to as  $\Delta$ sdh2 strain. The mutated SDHB residue p.Asp48Val is not conserved between human and yeast; Aspartate-48 in human SDHB is conservatively substituted by Asparagine-42 in the yeast Sdh2 protein (figure 5A). We therefore constructed the 'humanised wild-type' allele by replacing the codon specific to the amino acid residue of the wild-type SDH2 yeast sequence, with the codon corresponding to the amino acid residue of the wild-type SDHB human sequence. The humanised wild-type SDH2 variant allele (p.Asn42Asp) was then introduced into  $\Delta$ sdh2 yeast mutant and the

transformants were tested for oxidative growth on YNB medium supplemented with 2% ethanol or 2% acetate (figure 5B). The 'humanised allele' was able to complement the oxidative growth defect of  $\Delta$ sdh2 strain.

We then prepared the second construct by introducing the p.Asn42Val substitution, corresponding to the purported pathogenic mutant residue in the SDHB protein of Patient 2, and measured its effect on oxidative growth, SDH activity and respiration. Growth on 2% ethanol and 2% acetate was barely impaired in transformants carrying the p.Asn42Val substitution (figure 5B). When respiration was measured, both strains sdh2p.Asn42Asp and sdh2p.Asn42Val displayed an oxygen consumption rate equivalent to that of the wild-type strain, suggesting that decreased SDH activity does not impair electron flux through the respiratory chain (figure 5C). We then studied the effect of both the sdh2p.Asn42Val mutation and sdh2p.Asn42Asp humanised wild-type variant on SDH enzyme activity. The results obtained indicated that the SDH activity was reduced by approximately 50% in the strain harbouring the p.Asn42Val mutant allele whereas the SDH activity of the humanised wild-type allele was indistinguishable from that of the parental strain (figure 5D).

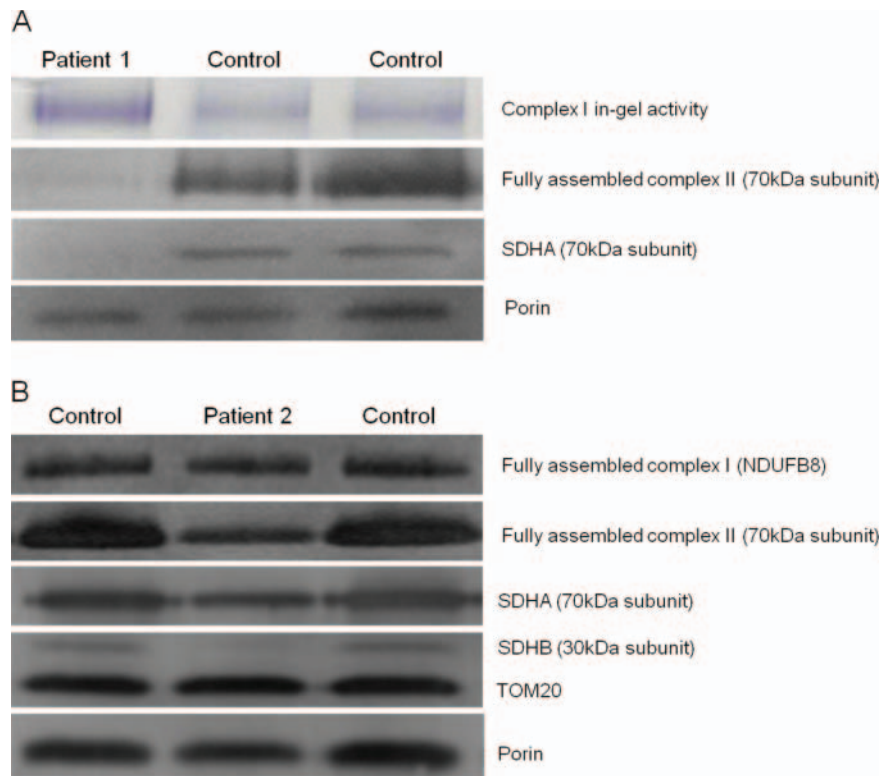


**Figure 3** Identification of pathogenic SDHA and SDHB mutations. (A) Compound heterozygous c.1523C>T (p.Thr508Ile) and c.1526C>T (p.Ser509Leu) SDHA mutations were identified in Patient 1, with parental DNA screening supporting recessive inheritance. Both mutations affect highly conserved p.Thr508 and p.Ser509 residues in the SDHA-encoded subunit A of succinate dehydrogenase (SDH). (B) A novel homozygous c.143A>T (p.Asp48Val) SDHB mutation was identified in Patient 2, with recessive inheritance supported by parental DNA screening. Multiple sequence alignment of this region of the SDHB subunit confirms that p.Asp48Val mutation affects an evolutionary conserved residue.

**Figure 4** Investigation of complex activities and protein expression in Patients 1 and 2 and controls.

(A) BN-PAGE analysis of mitochondria isolated from cultured patient and control fibroblasts revealed a reduction of assembled complex II. SDS-PAGE analysis, probed with antibodies against porin (loading control) and the flavoprotein subunit of succinate dehydrogenase (SDH), revealed an almost complete obliteration of *SDHA* expression for Patient 1, corroborating the pathogenicity of the c.1523C>T (p.Thr508Ile) and c.1526C>T (p.Ser509Leu) *SDHA* variants.

(B) BN-PAGE analysis of enriched mitochondria from patient and control muscle revealed a reduction of complex II assembly, with normal complex I assembly. SDS-PAGE analysis shows a gross decrease in iron-sulphur (SDHB) and a slightly reduction in SDHA subunit expression, with normal levels of TOM20 and porin.



## DISCUSSION

Mitochondrial complex II is a critical enzyme for cellular respiration and despite its key roles in both the Krebs cycle and the electron transport chain, it represents a rare cause of disease in the general population. Given that so few Krebs cycle enzyme deficiencies are reported, bi-allelic mutations affecting these enzymes appear to be typically incompatible with life; all reported cases are recessive and involve isolated deficiencies of fumarate hydratase, SDH and, most recently, aconitase,<sup>39</sup> and are associated with a severe neurological phenotype and very poor prognosis, being almost always fatal in the neonatal period. Conversely, OXPHOS disease presentations are comparatively common, can present at any stage throughout life and are associated with vast clinical and genetic heterogeneity. Pathogenic mutations have been identified in numerous OXPHOS genes, but the correlation with clinical phenotype is rarely pathognomonic. Isolated deficiencies involving SDH are the rarest of all OXPHOS deficiencies, accounting for approximately 2% of all mitochondrial disease cases.

Here, we describe two children who presented during infancy with motor manifestations of leukodystrophy and one who also had significant cardiomyopathy, in whom biochemical and histochemical analyses of respiratory chain activities in skeletal muscle uncovered a severe, isolated deficiency of complex II. Mutations in *SDHAF1* and *SDHA* genes are known to cause mitochondrial complex II deficiency;<sup>7, 10, 11</sup> thus, sequencing of these genes was prioritised. This analysis revealed novel compound heterozygous variants of unknown pathological significance within the *SDHA* gene (c.1523C>T; p.Thr508Ile and c.1526C>T; p.Ser509Leu) for Patient 1, while analysis of the *SDHAF1* and *SDHA* genes for Patient 2 revealed only wild-type sequence. A candidate gene sequencing approach led to the discovery of a novel homozygous (c.143A>T; p.Asp48Val) *SDHB* variant in Patient 2. Recessive inheritance of

the *SDHA* and *SDHB* variants was confirmed by parental DNA screening. Functional investigations supported the deleterious effect of the putative *SDHA* and *SDHB* mutations, with SDS-PAGE, BN-PAGE and western blotting confirming decreased levels of SDHA and SDHB protein expression for Patients 1 and 2, respectively; both patients had a marked reduction in stable, fully-assembled complex II.

While there are numerous reports describing *SDHB* mutations in the context of hereditary and sporadic cancer pathology, this report represents the first case of *SDHB* mutation in association with a neurological phenotype. Additional functional evidence supporting the pathogenicity of the novel homozygous *SDHB* mutation was provided through modelling the p.Asp48Val mutation in *Saccharomyces cerevisiae*. Despite a very high degree of conservation across the *SDHB/SDH2* genes, a lack of homology at the human p.Asp48 *SDHB* locus and corresponding *Saccharomyces cerevisiae* p.Asn42 residue was noted and addressed in our experimental design. Site-directed mutagenesis was employed to generate a p.Asn42Val mutant, in which a marked decrease in SDH activity was observed. A humanised wild-type yeast model was subsequently generated to investigate whether the lack of homology at the p.Asn42/p.Asp48 locus impacted upon SDH activity; SDH activity in the humanised p.Asp42 and wild-type *Sdh2* model were comparable, thus corroborating the pathogenicity of the human p.Asp48Val mutation.

Based on Piccolo modelling, the wild-type human p.Asp48 residue is not involved in direct binding to other SDH residues but is located within the highly conserved 2Fe-2S binding domain of the SDHB protein. While p.Asp48 has no obvious primary interaction with other residues of the complex, we hypothesise that it is critical for efficient binding and onward procession of electrons within the mitochondrial respiratory chain.



cell, increasing the likelihood of transformation to immortalised cell status.<sup>41</sup>

Proving the pathogenicity of candidate gene mutations is always important, perhaps more so when the genes involved are also tumour suppressors. Having confirmed the *SDH* mutation as pathogenic, there are further ethical considerations with regard to disclosure of carrier status and prenatal testing. A child born to carrier parents has a 25% risk of a severe neurological phenotype, a 50% risk of 'elevated cancer susceptibility' and in the situation where only one parent harbours a *SDHB* mutation, a 50% risk of elevated cancer susceptibility. The issue of whether clinicians should be able to reveal carrier status as well as 'clinically affected' status during prenatal screening is one that should be considered in depth, particularly if there is evidence of oncogenesis in relation to the *SDH* gene mutation in question.

While the recessive genetic defects in *SDHA* and *SDHB* identified in the two probands described here have caused severe neurological presentations and complex II deficiency, the fact that the parents of Patients 1 and 2 are heterozygous carriers of germline SDH mutations may place them at an elevated risk of tumourigenesis although neither the *SDHA* (p.Ala508Thr and p.Ser509Thr) nor *SDHB* (p.Asp48Val) mutations are reported in the Leiden Open Variation Database (<http://chromium.liacs.nl/LOVD2/SDH/home.php>), suggesting that these particular mutations have not yet been linked to tumourigenesis. Although there is no indication of cancer susceptibility in either family, both families have been referred for surveillance.

As with the majority of mitochondrial disease presentations, there are no effective cures for SDH deficiency although riboflavin has been shown to alleviate some of the symptoms and delay disease progression.<sup>49</sup> Following the diagnosis of SDH deficiency, oral coenzyme Q10 treatment was commenced in Patient 2 and a subjective improvement in strength was reported.

We recommend screening of the *SDHA*, *SDHB* and *SDHAF1* genes for patients with a biochemically and histochemically characterised isolated complex II deficiency. Identifying the underlying genetic basis of isolated complex II deficiency is vital to ensure that appropriate counselling is available for the family. It facilitates access to cascade screening, and given the increased cancer susceptibility, particularly in relation to *SDHB* defects, routine surveillance would enable early detection of tumours and appropriate intervention.

**Acknowledgements** The authors thank Dr Marie-Anne Brundler and Mr Gavin Falkous for their help with the histopathology.

**Contributors** CLA, JED, PGo, IF, RM and RWT contributed to the project design, analysis of the data and/or the drafting of the manuscript. JED and EW recruited patients and family members and phenotypically characterised the families. CLA, FHvdW, LH and H-TH-D performed the biochemical, molecular and protein analysis. JED, ACP and PGo performed the MR studies. FM, PGo and IF performed the yeast experiments. RWT supervised the study.

**Funding** This work was supported by grants from the Wellcome Trust (906919), Fondazione Telethon (GGP11011), CARIPO (2011/0526) and the UK NHS Specialist Commissioners who fund the 'Rare Mitochondrial Disorders of Adults and Children' Diagnostic Service in Newcastle upon Tyne (<http://www.mitochondrialncg.nhs.uk>). JED is supported by a Sparks Clinical Research Training Fellowship. FHvdW was supported by a Newcastle University Research Committee Visiting Professorship bursary and a North-West University (South Africa) research grant. H-TH-D is supported by a Deutsche Forschungsgemeinschaft (DFG) postdoctoral fellowship.

**Competing interests** None.

**Patient consent** Obtained.

**Ethics approval** Ethics approval was provided by the Newcastle and North Tyneside 1 Ethics Committee.

**Provenance and peer review** Not commissioned; externally peer reviewed.

## REFERENCES

1. Skladal D, Halliday J, Thorburn DR. Minimum birth prevalence of mitochondrial respiratory chain disorders in children. *Brain* 2003;**126**:1905–12.
2. McFarland R, Taylor RW, Turnbull DM. A neurological perspective on mitochondrial disease. *Lancet Neurol* 2010;**9**:829–40.
3. Rustin P, Rötig A. Inborn errors of complex II—unusual human mitochondrial diseases. *Biochim Biophys Acta* 2002;**1553**:117–22.
4. Parfait B, Chretien D, Rötig A, Marsac C, Munnich A, Rustin P. Compound heterozygous mutations in the flavoprotein gene of the respiratory chain complex II in a patient with Leigh syndrome. *Hum Genet* 2000;**106**:236–43.
5. Briere JJ, Favier J, El Ghouzi V, Djouadi F, Bénit P, Gimenez AP, Rustin P. Succinate dehydrogenase deficiency in human. *Cell Mol Life Sci* 2005;**62**:2317–24.
6. Bourgeron T, Rustin P, Chretien D, Birch-Machin M, Bourgeois M, Viegas-Péquignot E, Munnich A, Rötig A. Mutation of a nuclear succinate dehydrogenase gene results in mitochondrial respiratory chain deficiency. *Nat Genet* 1995;**11**:144–9.
7. Horvath R, Abicht A, Holinski-Feder E, Laner A, Gempel K, Prokisch H, Lochmüller H, Klopstock T, Jaksch M. Leigh syndrome caused by mutations in the flavoprotein (Fp) subunit of succinate dehydrogenase (*SDHA*). *J Neurol Neurosurg Psychiatry* 2006;**77**:74–6.
8. Pagnamenta AT, Hargreaves IP, Duncan AJ, Taanman JW, Heales SJ, Land JM, Bitner-Glindzicz M, Leonard JV, Rahman S. Phenotypic variability of mitochondrial disease caused by a nuclear mutation in complex II. *Mol Genet Metab* 2006;**89**:214–21.
9. Van Coster R, Seneca S, Smet J, Van Hecke R, Gerlo E, Devreese B, Van Beummen J, Leroy JG, De Meirleir L, Lissens W. Homozygous Gly555Glu mutation in the nuclear-encoded 70 kDa flavoprotein gene causes instability of the respiratory chain complex II. *Am J Med Genet A* 2003;**120**:13–18.
10. Levitas A, Muhammad E, Harel G, Saada A, Caspi VC, Manor E, Beck JC, Sheffield V, Parvari R. Familial neonatal isolated cardiomyopathy caused by a mutation in the flavoprotein subunit of succinate dehydrogenase. *Eur J Hum Genet* 2010;**18**:1160–5.
11. Ghezzi D, Goffrini P, Uziel G, Horvath R, Klopstock T, Lochmüller H, D'Adamo P, Gasparini P, Strom TM, Prokisch H, Invernizzi F, Ferrero I, Zeviani M. *SDHAF1*, encoding a LYR complex-II specific assembly factor, is mutated in SDH-defective infantile leukoencephalopathy. *Nat Genet* 2009;**41**:654–6.
12. Birch-Machin MA, Taylor RW, Cochran B, Ackrell BA, Turnbull DM. Late-onset optic atrophy, ataxia, and myopathy associated with a mutation of a complex II gene. *Ann Neurol* 2000;**48**:330–5.
13. Burnichon N, Briere JJ, Libé R, Vescovo L, Rivière J, Tissier F, Jouanno E, Jeunemaitre X, Bénit P, Tzagoloff A, Rustin P, Bertherat J, Favier J, Gimenez-Roqueplo AP. *SDHA* is a tumor suppressor gene causing paraganglioma. *Hum Mol Genet* 2010;**19**:3011–20.
14. Astuti D, Latif F, Dallol A, Dahia PL, Douglas F, George E, Sköldbberg F, Husebye ES, Eng C, Maher ER. Gene mutations in the succinate dehydrogenase subunit *SDHB* cause susceptibility to familial pheochromocytoma and to familial paraganglioma. *Am J Hum Genet* 2001;**69**:49–54.
15. Niemann S, Müller U. Mutations in *SDHC* cause autosomal dominant paraganglioma, type 3. *Nat Genet* 2000;**26**:268–70.
16. Baysal BE, Ferrel RE, Willett-Brozick JE, Lawrence EC, Myssiorek D, Bosch A, van der Mey A, Taschner PE, Rubinstein WS, Myers EN, Richard CW III, Cornelisse CJ, Devilee P, Devlin B. Mutations in *SDHD*, a mitochondrial complex II gene, in hereditary paraganglioma. *Science* 2000;**287**:848–51.
17. Gimm O, Armanios M, Dziema H, Neumann HP, Eng C. Somatic and occult germ-line mutations in *SDHD*, a mitochondrial complex II gene, in nonfamilial pheochromocytoma. *Cancer Res* 2000;**60**:6822–5.
18. Bayley JP, Kunst HP, Cascon A, Sampietro ML, Gaal J, Korpershoek E, Hinojar-Gutierrez A, Timmers HJ, Hoefsloot LH, Hermens MA, Suárez C, Hussain AK, Vriends AH, Hes FJ, Jansen JC, Tops CM, Corssmit EP, de Knijff P, Lenders JW, Cremers CW, Devilee P, Dinjens WN, de Krijger RR, Robledo M. *SDHAF2* mutations in familial and sporadic paraganglioma and pheochromocytoma. *Lancet Oncol* 2010;**11**:366–72.
19. Bardella C, Pollard PJ, Tomlinson I. SDH mutations in cancer. *Biochim Biophys Acta* 2011;**1807**:1432–43.
20. Goffrini P, Ercolino T, Panizza E, Giachè V, Cavone L, Chiarugi A, Dima V, Ferrero I, Mannelli M. Functional study in a yeast model of a novel succinate dehydrogenase subunit B gene germline missense mutation (C191Y) diagnosed in a patient affected by a glomus tumor. *Hum Mol Genet* 2009;**18**:1860–8.
21. Wishart DS, Knox C, Guo AC, Eisner R, Young N, Gautam B, Hau DD, Psychogios N, Dong E, Bouatra S, Mandal R, Sinelnikov I, Xia J, Jia L, Cruz JA, Lim E, Sobsey CA, Shrivastava S, Huang P, Liu P, Fang L, Peng J, Fradette R, Cheng D, Tzur D, Clements M, Lewis A, De Souza A, Zuniga A, Dawe M, Xiong Y, Clive D, Greiner R, Nazyrova A, Shaykhtudinov R, Li L, Vogel HJ, Forsythe I. HMDB: a knowledgebase for the human metabolome. *Nucleic Acids Res* 2009;**37**:D603–10.
22. Davison JE, Davies NP, Wilson M, Sun Y, Chakrapani A, McKiernan PJ, Walter JH, Gissen P, Peet AC. MR spectroscopy-based brain metabolite profiling in propionic acidemia: metabolic changes in the basal ganglia during acute decompensation and effect of liver transplantation. *Orphanet J Rare Dis* 2011;**6**:19.



23. **Kirby DM**, Thorburn DR, Turnbull DM, Taylor RW. Biochemical assays of respiratory chain complex activity. *Methods Cell Biol* 2007;**80**:93–119.
24. **Flicek P**, Amode MR, Barrell D, Beal K, Brent S, Carvalho-Silva D, Clapham P, Coates G, Fairley S, Fitzgerald S, Gil L, Gordon L, Hendrix M, Hourlier T, Johnson N, Kähäri AK, Keefe D, Keenan S, Kinsella R, Komorowska M, Koscielny G, Kulesha E, Larsson P, Longden I, McLaren W, Muffato M, Overduin B, Pignatelli M, Pritchard B, Riat HS, Ritchie GR, Ruffier M, Schuster M, Sobral D, Tang YA, Taylor K, Trevanion S, Vandrovicova J, White S, Wilson M, Wilder SP, Aken BL, Birney E, Cunningham F, Dunham I, Durbin R, Fernández-Suarez XM, Harrow J, Herrero J, Hubbard TJ, Parker A, Proctor G, Spudich G, Vogel J, Yates A, Zadissa A, Searle SM. Ensembl 2012. *Nucleic Acids Res* 2012;**40**:D84–90.
25. **Adzhubei IA**, Schmidt S, Peshkin L, Ramensky VE, Gerasimova A, Bork P, Kondrashov AS, Sunyaev SR. A method and server for predicting damaging missense mutations. *Nat Methods* 2010;**7**:248–9.
26. **Kumar P**, Henikoff S, Ng PC. Predicting the effects of coding non-synonymous variants on protein function using the SIFT algorithm. *Nat Protoc* 2009;**4**:1073–81.
27. **Mathe E**, Olivier M, Kato S, Ishioka C, Hainaut P, Tavtigian SV. Computational approaches for predicting the biological effect of p53 missense mutations: a comparison of three sequence analysis based methods. *Nucleic Acids Res* 2006;**34**:1317–25.
28. **Kelley LA**, Sternberg MJ. Protein structure prediction on the web: a case study using the Phyre server. *Nat Protoc* 2009;**4**:363–71.
29. **Bickerton GR**, Higuero AP, Blundell TL. Comprehensive, atomic-level characterization of structurally characterized protein–protein interactions: the PICCOLO database. *BMC Bioinformatics* 2011;**12**:313.
30. **Larkin MA**, Blackshields G, Brown NP, Chenna R, McGettigan PA, McWilliam H, Valentin F, Wallace IM, Wilm A, Lopez R, Thompson JD, Gibson TJ, Higgins DG, Clustal W, Clustal X. Version 2.0. *Bioinformatics* 2007;**23**:2947–8.
31. **Tatusova TA**, Madden TL. BLAST 2 Sequences, a new tool for comparing protein and nucleotide sequences. *FEMS Microbiol Lett* 1999;**174**:247–50.
32. **Hornig-Do HT**, Günther G, Bust M, Lehnartz P, Bosio A, Wiesner RJ. Isolation of functional pure mitochondria by superparamagnetic microbeads. *Anal Biochem* 2009;**389**:1–5.
33. **Zerbetto E**, Vergani L, Dabbeni-Sala F. Quantification of muscle mitochondrial oxidative phosphorylation enzymes via histochemical staining of blue native polyacrylamide gels. *Electrophoresis* 1997;**18**:2059–64.
34. **Gietz RD**, Schiestl RH. Quick and easy yeast transformation using the LiAc/SS carrier DNA/PEG method. *Nat Protoc* 2007;**2**:35–7.
35. **Sambrook J**, Russel DW. *Molecular cloning: a laboratory manual*. Cold Spring Harbor, NY: Cold Spring Harbor Laboratory Press, 2001.
36. **Baruffini E**, Ferrero I, Foury F. In vivo analysis of mtDNA replication defects in yeast. *Methods* 2010;**51**:426–36.
37. **Ho SN**, Hunt HD, Horton RM, Pullen JK, Pease LR. Site-directed mutagenesis by overlap extension using the polymerase chain reaction. *Gene* 1989;**77**:51–9.
38. **Bonneaud N**, Ozier-Kalogeropoulos O, Li GY, Labouesse M, Minvielle-Sebastia L, Lacroute F. A family of low and high copy replicative, integrative and single-stranded *S. cerevisiae*/E. coli shuttle vectors. *Yeast* 1991;**7**:609–15.
39. **Spiegel R**, Pines O, Ta-Shma A, Burak E, Shaag A, Halvardson J, Edvardson S, Mahajna M, Zenvirt S, Saada A, Shalev S, Feuk L, Elpeleg O. Infantile cerebellar-retinal degeneration associated with a mutation in mitochondrial aconitase, *ACO2*. *Am J Hum Genet* 2012;**90**:518–23.
40. **van der Knaap MS**, van der Voorn P, Barkhof F, Van Coster R, Krägeloh-Mann I, Feigenbaum A, Blaser S, Vles JS, Rieckmann P, Pouwels PJ. A new leukoencephalopathy with brainstem and spinal cord involvement and high lactate. *Ann Neurol* 2003;**53**:252–8.
41. **Guzy RD**, Sharma B, Bell E, Chandel NS, Schumacker PT. Loss of the SdhB, but Not the SdhA, subunit of complex II triggers reactive oxygen species-dependent hypoxia-inducible factor activation and tumorigenesis. *Mol Cell Biol* 2008;**28**:718–31.
42. **Korpershoek E**, Favier J, Gaal J, Burnichon N, van Gessel B, Oudijk L, Badoual C, Gadessaud N, Venisse A, Bayley JP, van Dooren MF, de Herder WW, Tissier F, Plouin PF, van Nederveen FH, Dirjens WN, Gimenez-Roqueplo AP, de Krijger RR. SDHA immunohistochemistry detects germline SDHA gene mutations in apparently sporadic paragangliomas and pheochromocytomas. *J Clin Endocrinol Metab* 2011;**96**:E1472–6.
43. **Janeway KA**, Kim SY, Lodish M, Nosé V, Rustin P, Gaal J, Dahia PL, Liegl B, Ball ER, Raygada M, Lai AH, Kelly L, Hornick JL, O'Sullivan M, de Krijger RR, Dirjens WN, Demetri GD, Antonescu CR, Fletcher JA, Helman L, Stratakis CA, NIH Pediatric and Wild-Type GIST Clinic. Defects in succinate dehydrogenase in gastrointestinal stromal tumors lacking *KIT* and *PDGFRA* mutations. *Proc Natl Acad Sci USA* 2011;**108**:314–18.
44. **Ricketts C**, Woodward ER, Killick P, Morris MR, Astuti D, Latif F, Maher ER. Germline *SDHB* mutations and familial renal cell carcinoma. *J Natl Cancer Inst* 2008;**100**:1260–2.
45. **Schimke RN**, Collins DL, Stolle CA. Paraganglioma, neuroblastoma, and a *SDHB* mutation: resolution of a 30-year-old mystery. *Am J Med Genet A* 2010;**152**:1531–5.
46. **Haigis MC**, Deng CX, Finley LW, Kim HS, Gius D. SIRT3 is a Mitochondrial tumor suppressor: a scientific tale that connects aberrant cellular ROS, the warburg effect, and carcinogenesis. *Cancer Res* 2012;**72**:2468–72.
47. **Koivunen P**, Hirsilä M, Remes AM, Hassinen IE, Kivirikko KI, Myllyharju J. Inhibition of hypoxia-inducible factor (HIF) hydroxylases by citric acid cycle intermediates: possible links between cell metabolism and stabilization of HIF. *J Biol Chem* 2007;**282**:4524–32.
48. **Selak MA**, Armour SM, MacKenzie ED, Boulahbel H, Watson DG, Mansfield KD, Pan Y, Simon MC, Thompson CB, Gottlieb E. Succinate links TCA cycle dysfunction to oncogenesis by inhibiting HIF- $\alpha$  prolyl hydroxylase. *Cancer Cell* 2005;**7**:77–85.
49. **Bugiani M**, Lamantea E, Invernizzi F, Moroni I, Bizzi A, Zeviani M, Uziel G. Effects of riboflavin in children with complex II deficiency. *Brain Dev* 2006;**28**:576–81.