

Skin graft donor site: a procedure for a faster healing

Roberto Cuomo, Luca Grimaldi, Brandi Cesare, Giuseppe Nisi, Carlo D'Aniello

Plastic and Reconstructive Surgery, University of Siena, Siena, Italy

Summary. *Background:* The authors want to evaluate the efficacy of fibrillary tabotamp dressing in skin graft-donor site. A comparison was made with Vaseline gauzes. Tabotamp is an absorbable haemostatic product of Ethicon (Johnson and Johnson) obtained by sterile and oxidized regenerated cellulose (Rayon). It is used for mild to moderate bleeding. *Materials and methods:* 276 patients were subject to skin graft and divided into two group: Group A and Group B. The donor site of patients in Group A was medicated with fibrillary tabotamp, while the patients of Group B were medicated only with Vaseline gauze. We recorded infection, timing of healing, number of dressing change, the pain felt during and after the dressing change with visual analog scale (VAS) and a questionnaire. *Results:* Patients allocated in Group A healed faster than the Group B. Questionnaires and VAS analysis showed lower pain felt, lower intake of pain drugs and lower infection rate in the Group A than the Group B. Analysis of coast showed lower dressing change in Group A than the Group B. *Conclusion:* We believe that the use of tabotamp is a very viable alternative to improve healing. (www.actabiomedica.it)

Key words: tabotamp fibrillary, skin graft, skin graft donor site, wound healing

Abbreviations and acronyms:

VAS: visual analog scale

Introduction

Since the 1950s, oxidised regenerate cellulose (TABOTAMP®) has been successfully applied for local haemostasis in intra- or post-operative bleeding complications. The scope of this medical product is large and it has found its place in oral and maxillofacial surgery.

Split-thickness skin graft are often used for covering large losses of skin. The removal of the skin produces a wound in turn that must be medicated to allow rapid healing. To promote a fast and an easy re-epithelialization of the donor site numerous types of dressing are used.

Occlusive dressings are able to promote a fast recovery than non-occlusive dressing, with a lower rate of infections (1, 2). Numerous studies have been evaluated to compare benefits of different dressings, such as hydrocolloids (3, 4), gauze impregnated with substances that improve re-epithelialization (5, 6), hydrogels (7), Vaseline gauze (8), but actually a comparison between Tambotamp fibrillar and vaseline gauzes has not yet been investigate. This study was designed after a dressing made with tabotamp in a patient who was taking anticoagulant therapy for mechanical mitral valve subjected to skin graft: the donor site was medicated with tabotamp and the authors noted a reduction in healing time and better postoperative management.

Tabotamp was compared with vaseline gauzes because vaseline gauze is generally used as a method of comparison to other medications. Both are occlusive dressings.

Materials and methods

In the year 2002 a patient with mechanical mitral valve was subjected to skin graft in our Operative Unite. We applied Tabotamp fibrillar in the donor site to get a better and faster hemostasis. Tabotamp fibrillar is a sponge-like collagen product used in surgical procedures to facilitate the monitoring of small haemorrhages when ligation or other conventional hemostatic control methods are ineffective. In the days after the surgery we noted a reduction in healing time and better management postoperative. After this result, the authors have made this study assuming that the use of Tabotamp could be a good dressing in patients undergoing skin graft.

In the period between 2003 and 2011, 276 patients were underwent to split-thickness skin grafting in our Operative Unit. Skin grafts were performed to treat post-traumatic tissue losses, burns, diabetic and venous leg ulcers. All procedures were in according to the Declaration of Helsinki and all patients signed an informed consent.

We divided all patients into two groups: Group A and Group B. The area of removal of skin was treated with Tabotamp fibrillary in patients in Group A, and with Vaseline gauzes in patients of Group B.

We treated trauma, venous ulcers, diabetic ulcers, burns. The recruitment of patients in each group and in each subgroup was conducted by alternating first Group A and then Group B in every admission: for example in case of two skin graft for trauma, one was been allocated in the Group A and another in Group B.

The treated areas (donor site) measured between 4 x 8 cm and 5 x 15 cm . The donor areas were identified in all cases in the anterolateral face of the thigh.

All patients signed an informed consent regarding the proposed surgery.

The skin was taken by donor site with the use of an electric dermatome with a thickness of 0,4 mm.

Surgical procedures were performed under local anesthesia (lidocaine).

At the end of removal of skin phase, the donor area has been always compressed with sterile gauze soaked in saline solution to decrease the bleeding for ten minutes.

Fibrillar Tabotamp or Vaseline gauzes were applied in the donor area in the patients of respective Groups. Steril gauzes were applied and a moderate compressive dressing was subsequently performed in all patients.

Antibiotic therapy was administered intra and post-operative for 7 days (amoxicillin and clavulanate or azithromycin if allergic).

The dressing stayed in situ for 6 days and was subsequently removed with the help of irrigation of sodium Hypochlorite solution. Tabotamp fibrillar (Group A) was not removed while the vaseline gauzes (Group B) was removed and replaced. The area was again medicated with this modality every three days.

We recorded the presence of excess fluid, infection and other situations that could slow down the healing of the donor site

All patients were given a questionnaire (9) to assess the presence of pain and a VAS (Visual Analog Scale) after every the dressing change. The questionnaire was filled at home.

Results were analyzed with Student's T test to compare the average of time-healing. A probability value (p) less than 0,05 was considered significant. The analyses were performed in GESS 2006 statistical software.

Results

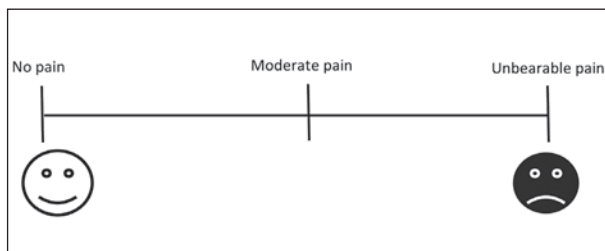
In both groups the donor area has reached a complete re-epithelialization in 7 to 20 days.

Table 1. Patients

Group A: Tabotamp 138 patients				Group B: Vaseline Gauze 138 patients			
Traumas	Burns	Diabetic ulcers	Venous leg ulcers	Traumas	Burns	Diabetic ulcers	Venous leg ulcers
57 patients	22 patients	24 patients	35 patients	57 patients	22 patients	24 patients	35 patients

Table 2. Questionnaire for pain

- 1) After the dressing change, in how much time the pain disappeared or was alleviated?
- 2) Have you taken analgesics within 6 hours after the medication?
Yes / No
a. If you answered YES to the previous question, please indicate who has taken drugs and dosage: _____
- 3) The pain felt during the dressing change within 6 hours after affects your ability to walk?
Yes / No
- 4) The pain felt during the dressing change within 6 hours after affects your ability to work?
Yes / No
- 5) The pain felt during the dressing change within 6 hours after affects your ability to sleep?
Yes / No
- 6) The pain felt during the dressing change within 6 hours following affect the taste of living?
Yes / No
- 7) The pain felt during the dressing change within 6 hours following affects the relationship with other people?
Yes / No
- 8) The pain felt during the dressing change within 6 hours after affects your mood?
Yes / No

**Figure 1.** Visual Analog Scale

Group A

The process of healing of the donor area was 12 days on average (range 10-15) in patients who received treatment with Tabotamp fibrillar. Four patients removed their dressing before sixth day so it was not possible to assess the effectiveness of medications and we excluded them from the study. We recorded no infections.

Group B

The patients treated with vaseline gauzes healed in 19 (13-24) days on average. It was not possible to evaluate the effectiveness of medication in eight cases because patients removed the dressing before the sixth postoperative day. We recorded the presence of exudate and superficial infection in 8 patients. An antibiogram showed the presence of *Pseudomonas Aeruginosa* and *Staphylococcus Aureus*. In these patients the healing process was completed after 25 days (on average).

VAS analysis

The data of VAS showed an average of 2.25 in Group A (range 0 to 2.8). The average of Group B was 6.8 (range 4 to 7.9) ($p < 0,05$). This difference was present because in the Group A it was not necessary to remove the tabotamp and so no mechanical stimulation of the wound bed was present during dressing change.

Questionnaires analysis

The analysis of questionnaires showed patients in the Group A do not take analgesic drugs and the pain felt within 6 hours after dressing change do not interrupt the normal activity.

The drug most assumed in Group B was paracetamol (73 patients), followed by Ketoprofen (28 patients). Pain felt in the first two dressing changes had a negative impact in 82 patients in the Group B.

The differences between the two groups in terms of time-healing were statistically significant ($p < 0,05$).

Costs analysis

The average cost of a sheet of tabotamp is about 86 Eur. The use of tabotamp, on the other hand, resulted in a reduction of the accesses in the clinic for the dressings: Group A of all patients were required with about 2 dressings less. In our unit the average time of a change in medication surgery (including patient registration and compilation of the report) is estimated to be about 15 minutes. We have therefore spared totally 4140 minutes of dressing change.

In addition to this evidence, the treated group had no infections.

Discussion

The fibrillar tabotamp is a fibrous absorbable hemostatic oxidized regenerated cellulose and is used in surgical procedures to facilitate the monitoring of small haemorrhages (10) when ligation or other conventional hemostatic control methods are ineffective (11-13).

Tabotamp has a bactericidal action because, positioned in situ, creates an acidic environment (pH <4), which many strains of bacteria do not survive (14-16).

It is a product that is largely used in our operating unit. During a skin graft, the sampling area tends to bleed because of the damage to the dermal vessels (9, 17-19). A good hemostatic control is the first step to proper healing of the donor area. Achieving a good hemostasis (14, 15) and a good dressing are key to rapid healing and scarring satisfactory (20).

Often the correct evaluation of the healing of the donor area is very complex because the epithelialization proceeds very subjective depending on the patient's clinical condition and because it focuses on the end result of the graft into the recipient. In any case, several studies have been proposed for a correct management of the donor site (1, 2, 16).

Assadian & Co. compared methacrylate and carboxymethylcellulose in 34 patients with lower pain but no difference in terms of number of dressing changes (5).

Davidson & Co. compared alginate-based dressing and keratin dressing showing that alginate was associated with a benefit in terms of re-epithelialization in patients older than 50 years (6).

Even Aquacel is often used for the dressing in situ with excellent results in terms of healing of the donor site (21), but a comparison between Tabotamp and Vaseline gauze has not yet been done.

Conclusions

Tabotamp is a versatile product that provides a good coverage and antibacterial properties with good scarring. There were no infections, more rapid healing and a smaller number of dressings to perform with 4140 minutes spared and with lower pain felt by the patients.

The use of fibrillar tabotamp produces a number of benefits including: less pain, faster healing and a saving of time and money due to a lower number of dressings change. Both the smaller number of medications, both the reduced intake of pain drug, both the reduced rate of infections result in cost savings for the health system and greater compliance for the patient.

References

1. Nisi G, Brandi C, Grimaldi L, Calabro M, D'Aniello C. Use of a protease-modulating matrix in the treatment of pressure sores. *Chirurgia italiana* 2005; 57(4): 465-8.
2. Drapeau CM, D'Aniello C, Brafa A, et al. Surgical site infections in plastic surgery: an italian multicenter study. *The Journal of surgical research* 2007; 143(2): 393-7.
3. Brolmann FE, Eskes AM, Goslings JC, et al. Randomized clinical trial of donor-site wound dressings after split-skin grafting. *The British journal of surgery* 2013; 100(5): 619-27.
4. Cuomo R, Sisti A, Grimaldi R, et al. Modified Arrow Flap Technique for Nipple Reconstruction 2016; 22(6): 710-1.
5. Assadian O, Arnoldo B, Purdue G, et al. A prospective, randomised study of a novel transforming methacrylate dressing compared with a silver-containing sodium carboxymethylcellulose dressing on partial-thickness skin graft donor sites in burn patients. *International wound journal* 2013.
6. Davidson A, Jina NH, Marsh C, Than M, Simcock JW. Do functional keratin dressings accelerate epithelialization in human partial thickness wounds? A randomized controlled trial on skin graft donor sites. *Eplasty* 2013; 13: e45.
7. Dornseifer U, Lonic D, Gerstung TI, et al. The ideal split-thickness skin graft donor-site dressing: a clinical comparative trial of a modified polyurethane dressing and aquacel. *Plastic and reconstructive surgery* 2011; 128(4): 918-24.
8. Ding X, Shi L, Liu C, Sun B. A randomized comparison study of Aquacel Ag and Alginate Silver as skin graft donor site dressings. *Burns : journal of the International Society for Burn Injuries* 2013; 39(8): 1547-50.
9. Cuomo R, Zerini I, Botteri G, Barberi L, Nisi G, D'Aniello C. Postsurgical pain related to breast implant: reduction with lipofilling procedure. *In vivo* 2014; 28(5): 993-6.
10. Brandi C, Grimaldi L, Nisi G, et al. The role of carbon dioxide therapy in the treatment of chronic wounds. *In vivo* 2010; 24(2): 223-6.
11. Nisi G, Barberi L, Ceccaccio L, et al. Effect of repeated subcutaneous injections of carbon dioxide (CO2) on inflammation linked to hypoxia in adipose tissue graft. 2015; 19(23): 4504-6.
12. Nisi G, Cuomo R, Brandi C, Grimaldi L, Sisti A, D'Aniello C. Carbon dioxide therapy and hyaluronic acid for cosmetic correction of the nasolabial folds. 2016; 15(2): 169-75.
13. D'Aniello C, Cuomo R, Grimaldi L, et al. Superior Pedicle

- Mammoplasty without Parenchymal incisions after Massive Weight Loss 2016; 1-11.
14. Cuomo R, Nisi G, Grimaldi L, Brandi C, Sisti A, D'Aniello C. Immunosuppression and Abdominal Wall Defects: Use of Autologous Dermis. *In vivo* 2015; 29(6): 753-5.
 15. Cuomo R, Russo F, Sisti A, et al. Abdominoplasty in Mildly Obese Patients (BMI 30-35 kg/m²): Metabolic, Biochemical and Complication Analysis at One Year. *In vivo* 2015; 29(6): 757-61.
 16. Grimaldi L, Cuomo R, Brandi C, Botteri G, Nisi G, D'Aniello C. Octyl-2-cyanoacrylate adhesive for skin closure: eight years experience. *In vivo* 2015; 29(1): 145-8.
 17. D'Aniello C, Brandi C, Grimaldi L. Cutaneous metastasis from small cell lung carcinoma. Case report. *Scandinavian journal of plastic and reconstructive surgery and hand surgery / Nordisk plastikkirurgisk forening [and] Nordisk klubb for handkirurgi* 2001; 35(1): 103-5.
 18. D'Aniello C, Grimaldi L, Meschino N, Brandi C, Andreassi A, Bosi B. Verrucous 'cuniculatum' carcinoma of the sacral region. *The British journal of dermatology* 2000; 143(2): 459-60.
 19. D'Antonio A, Cuomo R, Angrisani B, Memoli D, Angrisani P. Desmoplastic cellular neurothekeoma mimicking a desmoplastic melanocytic tumor. *Journal of the American Academy of Dermatology* 2011; 65(2): e57-8.
 20. D'Antonio A, Adesso M, Memoli D, et al. Lymph node-based disease and HHV-8/KSHV infection in HIV seronegative patients: report of three new cases of a heterogeneous group of diseases. 2011; 93(3): 795-801.
 21. Blome-Eberwein S, Johnson RM, Miller SF, et al. Hydrofiber dressing with silver for the management of split-thickness donor sites: a randomized evaluation of two protocols of care. *Burns : journal of the International Society for Burn Injuries* 2010; 36(5): 665-72.

Received: 6 September 2016

Accepted: 15 September 2016

Correspondence:

Roberto Cuomo, M.D.

Plastic and Reconstructive Surgery Unit

Santa Maria Alle Scotte Hospital

Viale Mario Bracci - 53100 Siena, Italy

Tel/fax: +0039-0577-585158

E-mail: robertocuomo@outlook.com