

Bugeja J, Dimech T, Borg C, Meilaq S, Sammut M, Grech V. Back trauma resulting in commotio cordis.  
*Images Paediatr Cardiol* 2018;20(2):5-6.

# IMAGES in PAEDIATRIC CARDIOLOGY

**Bugeja J<sup>1</sup>, Dimech T<sup>1</sup>, Borg C<sup>1</sup>, Meilak S<sup>2</sup>, Sammut M<sup>2</sup>, Grech V<sup>1</sup>. Back trauma resulting in commotio cordis. *Images Paediatr Cardiol* 2018;20(2):5-6.**

Department of Paediatrics, Mater Dei Hospital, Malta

## MeSH

Athletic Injuries/\*complications, Commotio Cordis, Thoracic Injuries/\*complications .

## Introduction

Commotio cordis (Latin: "agitation of the heart") is a dysrhythmia provoked by praecordial trauma during the early part of cardiac repolarisation. Recorded rhythms include ventricular tachycardia/fibrillation, bradyarrhythmias, idioventricular rhythm, complete heart block and asystole. The quoted fatality rate is 65% even with prompt CPR and defibrillation, and exceeds 80% in the absence of such interventions. Above a certain threshold of trauma/impact, structural cardiac damage may also occur (contusio cordis).<sup>1,2</sup>

## Case report

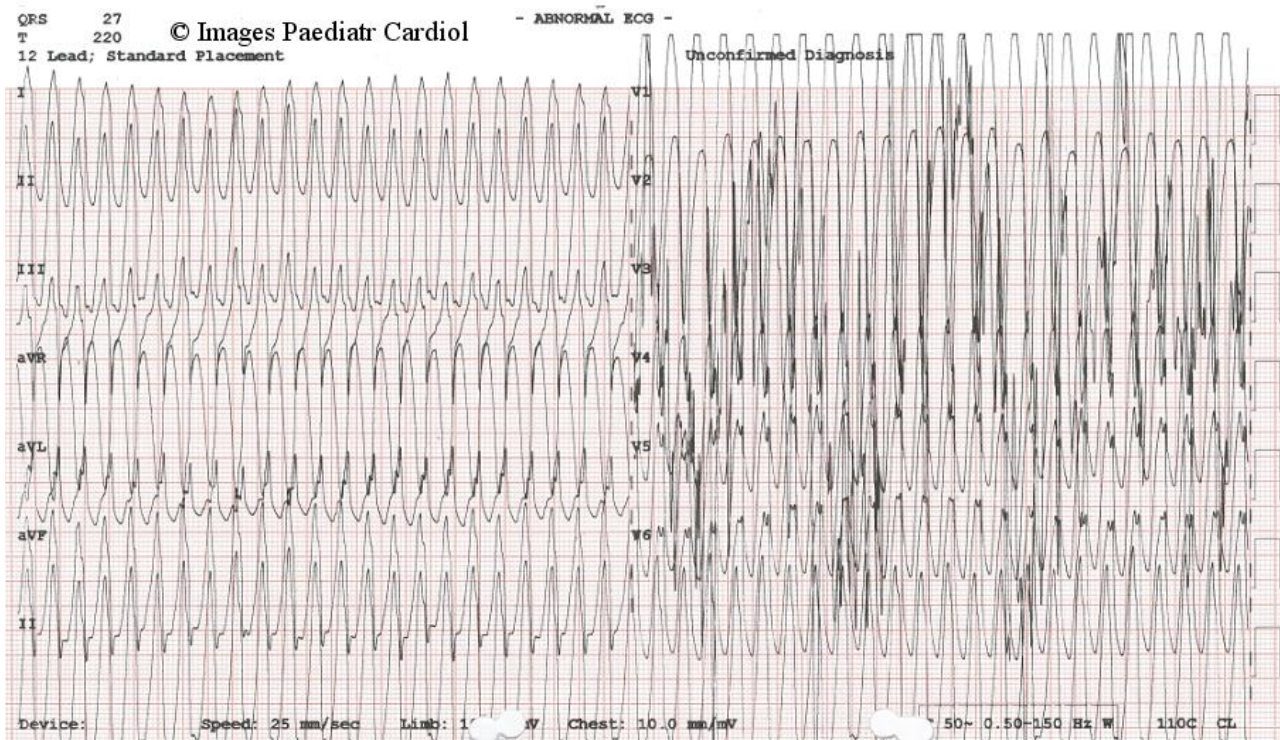
We report the case of a 14 year old boy who, after attempting to perform a somersault, landed forcefully on his back. On standing, he reported dizziness with blurring of vision, and presented to the emergency department. He was noted to be tachycardic at a rate of 270bpm, clinically pale and sweaty with poor peripheral perfusion. ECG showed a regular, wide-complex tachycardia (Figure 1). The diagnosis of ventricular tachycardia was made, and the patient was prepared for electrical cardioversion. The rhythm spontaneously reverted back to normal before cardioversion was commenced.

There was globally reduced systolic function on echocardiography soon after the event, however indices normalised the following day. The patient remained stable with normal parameters during admission. Serial ECGs showed no signs of abnormal repolarisation, with normal conduction. Magnetic resonance imaging of the heart showed a normal cardiac size with good biventricular function, with no evidence of macroscopic fibrosis, intracardiac shunts or valvular abnormalities.

There was a past history of a ventricular septal defect which was successfully closed with a device by cardiac catheterisation at 12 years of age. The device was visualised in situ on both echocardiography and magnetic resonance imaging.

Since this episode 9 months ago, the patient has since remained well with no sequelae, and is being followed up regularly. ECGs are entirely normal.

**Figure 1: ECG showing ventricular tachycardia**



## Discussion

Our case is unusual in that ventricular tachycardia was provoked by trauma applied to the back of the chest and not the praecordium. The classical mechanism of action with commotio cordis usually involves a seemingly innocent blow to the praecordium during ventricular repolarisation, during the ascending phase of the T wave. Typically, this involves young, male athletes. Most cases are fatal, manifesting as sudden unexpected cardiac death in young people undergoing physical activity with no previous documentation of electrical or structural cardiac abnormalities.

Dysrhythmias induced by chest wall impact are various, with descriptions of ventricular fibrillation, ventricular tachycardia, ST segment elevations and complete heart block, among others. Survival rates are dependent on the efficiency of resuscitation and the underlying nature of the induced dysrhythmia.

## References

1. Maron BJ, Estes NA 3rd. Commotio cordis. *N Engl J Med*. 2010;362(10):917-27.
2. Maron BJ, Gohman TE, Kyle SB, Estes NA 3rd, Link MS. Clinical profile and spectrum of commotio cordis. *JAMA*. 2002;287(9):1142-6.

## Contact Information

© Images in  
Paediatric Cardiology  
(1999-2018)

Justine Bugeja  
Paediatric Dept.  
Mater Dei Hospital, Malta  
[justine.a.bugeja@gov.mt](mailto:justine.a.bugeja@gov.mt)

