

ANATOMIC AND SURGICAL CONSIDERATIONS IN THE DESIGN OF A NEW RECEIVER-STIMULATOR SUITABLE FOR IMPLANTATION IN YOUNG CHILDREN

B. C. PYMAN, DLO, FRACS; G. M. CLARK, PHD, FRACS

From the Human Communication Research Centre and the Department of Otolaryngology, University of Melbourne, and the Cooperative Research Centre for Cochlear Implant, Speech and Hearing Research, Melbourne, Australia.

The anatomy of the temporal bone was studied to determine the optimal shape and dimensions of a new receiver-stimulator for use in young children even less than 12 months of age. There was a need to make the receiver-stimulator electronic package smaller so that it could be placed within the mastoid cavity, and the antenna wider, for more efficient power and data transmission. The antenna needed to conform to the smaller radius of a young child's skull. Anatomic dissections were carried out on skulls of children from 3 to 11 months of age to establish the variations in dimensions relevant for implantation. Prototype implant designs were evaluated in these skulls and it was found that the maximum thickness the anterior section of the receiver-stimulator should be was 5.5 mm, and its maximum width, 18 mm. It was found that a prototype electronics package with these dimensions could be fitted comfortably into the average skull of an 8-month-old child. A particular constraint was the depth of the bone over

the sigmoid sinus and middle fossa. The radius of curvature of the skull of young children also required the package to be bent in its center at an angle of 160° .

MATERIALS AND METHODS

To accommodate the electronics required for the receiver-stimulator, the conical container, shown in Fig 1A, was proposed. This had a diameter of 5 mm at its apex and 12 mm at its base, and a height of 4.4 mm. Together with the overlying coil and feed-throughs to the package, the front section was 7.9 mm thick.

To determine whether this particular design could be accommodated in young children's mastoid cavities, the temporal bones of 13 children who died before the age of 11 months (gathered from a collection previously used in a study of temporal bone growth¹) were examined. In each bone the

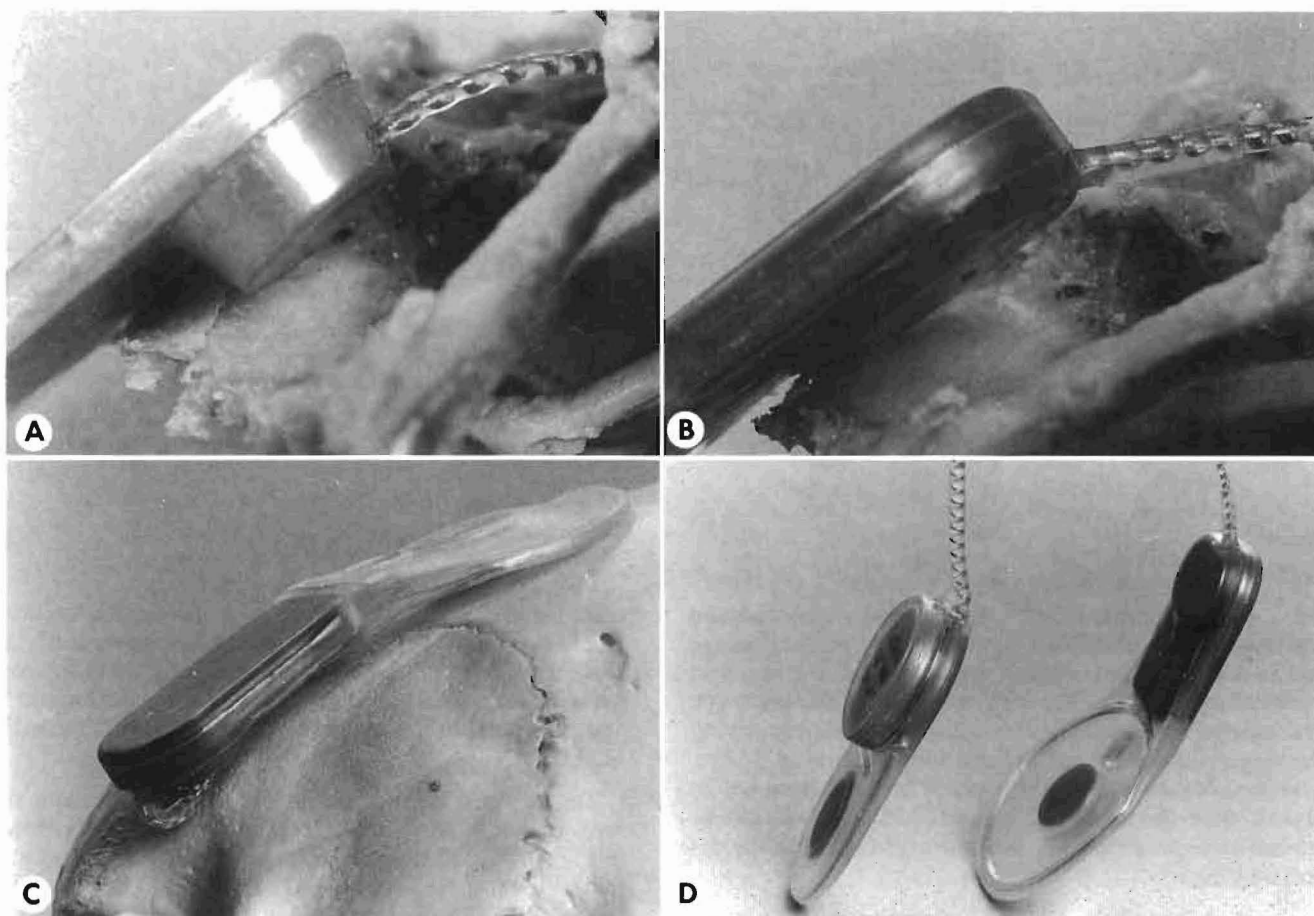


Fig 1. Micro-receiver-stimulator for young children. A) Initial prototype receiver-stimulator package resting on bone overlying sigmoid sinus in skull of 8-month-old child. B) Second prototype receiver-stimulator package resting on bone overlying sigmoid sinus in skull shown in A. C) Micro-receiver-stimulator in place on skull of 12-month-old child. D) New Cochlear Pty Limited micro-receiver-stimulator for research studies in children under 2 years, next to present mini device for regular clinical use.

external canal wall was absent, as it had been drilled away in a previous study. However, the site of the canal wall could be determined easily in each case. The depth to the bone over the sigmoid sinus was measured at a point 5 mm behind the ear canal as a rough measure of how thick the front section of the package could be without depressing the sinus. The mastoid cavity in each case was then extended posteriorly. The height of this posterior extension was measured to determine the maximum width of a receiver-stimulator package lying within or overlying the mastoid cavity. The superior margin was the floor of the middle fossa, and the inferior margin, the line of insertion of the neck muscles. The depth of bone overlying the middle fossa dura at its inferior limit was measured to determine how well the package could be accommodated if the receiver-stimulator was rotated significantly above the orbitomeatal line (the Frankfurt plane). The curvature of the skull of a young child (approximately 12 months of age) in the region behind the external auditory meatus was assessed from three-dimensional computer reconstructions of radiographs of the skull. Although not necessarily representative of all variations in skull shape, it gave a useful measure of the best orientation for the package to lie against the skull with the smallest bend between the receiver-stimulator and the coil. The angle needed was also evaluated in a number of children

of 2 years of age having implant surgery with the mini-device.

RESULTS

The measurements of the depth of bone over the sigmoid sinus, 5 mm behind the lateral edge of the osseous ear canal, showed the depth to be on average 5 mm. The average maximum height of the posterior extension of the mastoid cavity, from the floor of the middle fossa to the line of insertion of the neck muscles, was 20 mm. The minimum depth to the dura of the middle fossa at its most inferior limit was 2 mm. The circumference of the child's skull used for curvature measurements was 45 cm. The curvature behind the external auditory meatus had a radius of 4.5 cm in the Frankfurt plane. The radius was much greater (the skull flatter) when the plane was rotated 45° and then vertically. This is illustrated in Fig 2.

DISCUSSION

Although the measurements of the depth of bone to the sigmoid sinus 5 mm behind the external auditory canal showed the conical-shaped design (Fig 1A) could be accommodated, there was little tolerance for a more posterior placement. Furthermore, the acute angle made between the side wall and the apex of the cone could depress the sigmoid

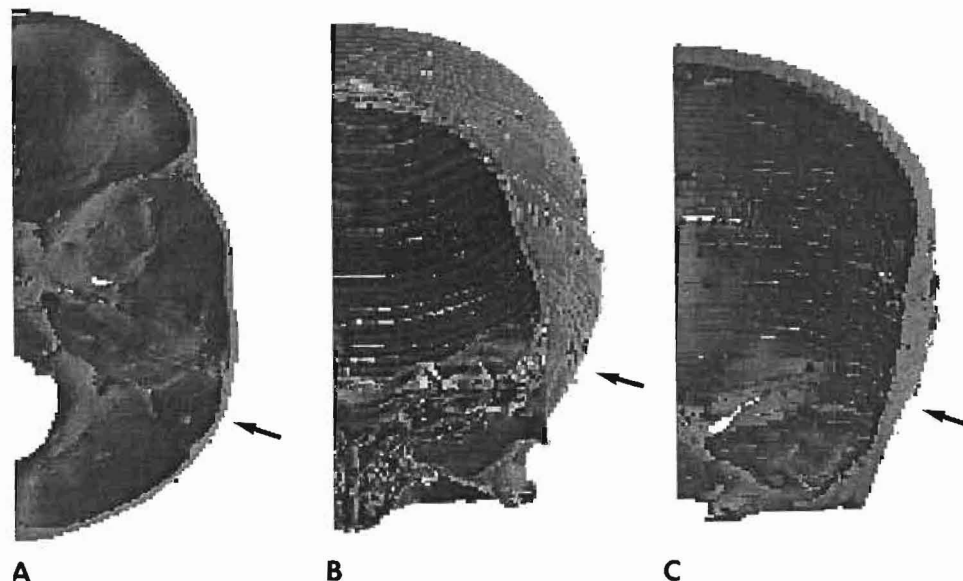


Fig 2. Three-dimensional reconstruction of radiographs of 12-month-old child's skull. A) Horizontal section parallel to orbitomeatal plane. B) Coronal-horizonal section at 45° to Frankfurt plane. C) Coronal section at right angles to Frankfurt plane. Curvature of bone where implant will lie in three sections is marked with arrow.

sinus. For this reason, a flatter, wider package was examined and found to lie better within the mastoid cavity. The package had an overall thickness of 5.7 mm at the front section, with a protrusion of 2.0 mm. The width was 18 mm. This prototype package can be seen in Fig 1B resting on the bone overlying the sigmoid sinus for comparison with the conical design. Another advantage with this package is that it need not be placed within the mastoid cavity, but a shallow well can be created more posteriorly without having to significantly depress the dura.

The superior-inferior height of the space created posteriorly in the mastoid cavity was 20 mm. Therefore, it was considered that 18 mm should be the width of a new receiver-stimulator for young children to allow some tolerance for anatomic variations and to allow it to be rotated more vertically.

After considering the measurement of the curvature of the skull in the 12-month-old child (Fig 2), assessment at surgery in 2-year-old children, and comparison of head circumference measurements of Heimedinger,² it was decided that a 160°

bend between the electronic package and antenna sections would be optimal for abutting against the curvature of the skull. How the 160° angle will allow the implant to approximate the curve of a young child's skull when the implant is angled 45° superiorly from the Frankfurt plane is illustrated in Fig 1C.

The new Cochlear Pty Limited receiver-stimulator for research studies in young children as well as adults is shown in Fig 1D beside the mini-receiver-stimulator presently in routine clinical use. As can be seen, the receiver-stimulator section is considerably smaller, but the coil is larger, for better power transmission.

ACKNOWLEDGMENTS — We thank Frank Nielsen for technical assistance, and Lisa Breayley from the Royal Victorian Eye & Ear Hospital for the photography.

REFERENCES

1. Dahm MC, Shepherd RK, Clark GM. The postnatal growth of the temporal bone and its implications for cochlear implantation in children. *Acta Otolaryngol [Suppl]* (Stockh) 1993(suppl 505):5-39.
2. Heimedinger J. Survey of the head circumference of Swiss-German children. *Helv Paed Acta* 1964;19:406.



Minerva Access is the Institutional Repository of The University of Melbourne

Author/s:

Pyman, B. C.; Clark, Graeme M.

Title:

Anatomic and surgical considerations in the design of a new receiver-stimulator suitable for implantation in young children

Date:

1995

Citation:

Pyman, B. C., & Clark, G. M. (1995). Anatomic and surgical considerations in the design of a new receiver-stimulator suitable for implantation in young children. *Annals of Otology, Rhinology & Laryngology*, 104(suppl.166), 428-430.

Persistent Link:

<http://hdl.handle.net/11343/27438>

File Description:

Anatomic and surgical considerations in the design of a new receiver-stimulator suitable for implantation in young children