

The histological and physiological effects of the auditory brainstem prosthesis on the auditory pathway

X. LIU, G. McPHEE, L. SELDON
and G. CLARK

*Department of Otolaryngology, The University of Melbourne
Bionic Ear and Hearing Research Institute, Melbourne (AUS)*

SYDNEY '97
XVI World
Congress of
Otorhinolaryngology
Head and
Neck Surgery

Sydney, Australia
2-7 March 1997

SUMMARY

To rehabilitate profoundly deaf patients who cannot benefit from the cochlear implant due to bilateral interruption of the auditory nerve, particularly from neurofibromatosis II, the histological and physiological effects of an auditory brainstem prosthesis on the cochlear nuclei of guinea pigs were examined in order to establish the safety and the efficacy of this prosthesis.

INTRODUCTION

The cochlear implant can successfully rehabilitate many profoundly deaf patients. However, some of them cannot benefit from cochlear implants due to bilateral interruption of the auditory nerve, particularly from neurofibromatosis II. These patients can be directly stimulated with an auditory brainstem prosthesis on the cochlear nucleus (Portillo et al. 1993). One current model of the auditory brainstem prosthesis is an array of surface electrodes. The concept of the prosthesis is similar to that of a cochlear implant, that is to stimulate the auditory pathway electrical except that the electrode design and surgical placement are targeted for the cochlear nucleus in the brainstem rather than the scala tympani of the cochlea. Elect

current can cause damage when exciting the target neural tissue, as well as interference with the tissues around the target tissue. Data on the histological and physiological effects of the surface auditory brainstem implant are limited. The only histological study reported is an analysis on the tissue sheath of the implant removed from a patient. Studies of penetrating cochlear nucleus implants showed that the auditory brainstem implants could cause decreased neuronal excitability and significant tissue response in cats (McCreery et al. 1992) and guinea pig (Niparko et al.). As "a surface array" auditory brainstem implant is going on worldwide clinical trials, it is urgent to examine the histological and physiological effects of the prosthesis to ensure that this prosthesis can stimulate neuronal tissue above the excitatory threshold and below the injury threshold.

MATERIALS AND METHOD

Fourteen healthy guinea pigs weighing 650 -- 1000 g were used. A click-evoked auditory brainstem response (ABR) was recorded before the animals were implanted with the surface auditory brainstem prosthesis. All animals had an ABR threshold of at least 22dB SPL and clear, intact tympanic membrane. After successful implantation and recording of EABRs (electrical evoked auditory brainstem responses), the animals were divided into two groups (rate group and intensity group). The rate group of seven animals was firstly stimulated at 250 pulses/sec at twice the EABR threshold current, followed by 500 and 1000 pulses/sec stimulation. The intensity group was stimulated at 250 pulses/sec with varying charge density (1.8, 2.8, 3.5 and 7.1 $\mu\text{C}/\text{phase cm}^2$). Each stimulation session lasted for two continuous hours. Two animals in each group were used for 2-DG (2-deoxy glucose) study and five for histological examination.

The animals were monitored with respiration rate, expired CO_2 concentration and rectal temperature during the experiment.

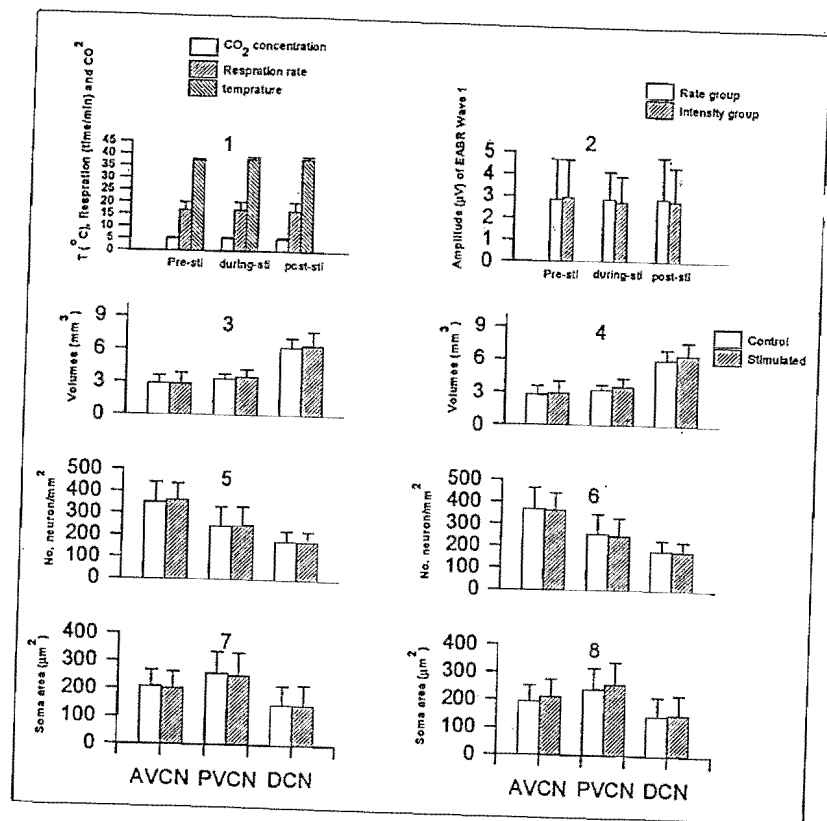
Autoradiography After six hours of electrical stimulation, 100 $\mu\text{Ci}/\text{kg}$ of 2-DG (Amersham England) was administered by intraperitoneal injection. The animals were then stimulated at the twice EABR threshold currents for 45 minutes. The animals were sacrificed, and the brainstem was rapidly harvested and frozen in liquid nitrogen. 30 μ sections of the brainstem were cut at -20°C in a cryostat, collected on gelatine coated slides and dried on a hot plate at 60°C . The sections were then exposed with Kodak diagnostic film SB 5 (Kodak, U.S.A.) for 10 days. The films were developed with Kodak GBX developer (Kodak, Australia). The inferior colliculi (IC) and cochlear nuclei (CN) were examined.

Histology On completion of the stimulation program, the animals were sacrificed and perfused with paraformaldehyde/glutaraldehyde solution. The brainstem were dissected and prepared for histological processing. The tissues were embedded in Spurr's resin, and serial sections were cut with Autocut microtome. All sections were stained with Thionin/Toluidine blue (Nissl stain) and Haematoxylin and Eosin (H&E). The morphology of different kinds of cells in the cochlear nucleus were examined. The volume, soma area and density of certain types of cells in the cochlear nucleus were measured with 3-dimensional techniques, on both the operated and control sides.

The Student's t-test (Jandel, Sigmaplot 2.01) was used to analyse differences between the control and stimulated sides.

RESULTS

No changes were found in the respiration rate, CO_2 concentration and body temperature during the electrical stimulation (Fig. 1). The waveform, amplitude



and latency of the post-stimulation EABRs waves were the same as the pre-stimulation (Fig 2).

A broad 2-DG labelling was found in the ipsilateral cochlear nucleus and in bilateral the IC. The CN showed variable 2-DG uptake patterns. However an increased labelling was found adjacent to the electrode tracks in all the cochlear nuclei. There was no recognisable 2-DG labelling in the surrounding non-auditory structures. The right IC (contralateral to stimulated cochlear nucleus) exhibited the most robust glucose metabolic response with a pattern of banding seen in all the stimulated animals. The morphology, location, and numbers of bands differed between individual subjects. The bands were always oriented in the dorsomedial to ventrolateral direction. The left inferior colliculus (ipsilateral to stimulated cochlear nucleus) also showed some evidence of banding, although the bands were not as sharp and dense as the right side of the IC.

In both the control and stimulated sides of the cochlear nuclei, three major cell types were readily recognisable as being typical of the VCN in Nissl staining. These were the octopus cell, spherical bushy cell and globular bushy cell. A similar situation occurred in the DCN where again there were at least three distinctive types of cell, the pyramidal cell, cartwheel cell and molecular layer stellate cell. In addition to these cell types, which were restricted to one or other major divisions of the complex, there were four categories of cells within all of them. These were the

granule cell, multipolar cell, giant cell and small cells. They shared the same shape and staining. No histological differences were observed between the control and stimulated sides of the cochlear nuclei. In both the rate group and charge group, the morphology was very similar. No pathological changes were found inside or outside the cochlear nuclei.

No changes were found in the volumes of the cochlear nuclei (Fig 3,4), the neuron density (Fig.5,6), and the soma cross-sectional area of neurons (Fig.7,8) in the cochlear nucleus.

DISCUSSION

The goal of the auditory brainstem prosthesis is to activate the auditory system (cochlear nucleus) without any side effects, such as damage to the auditory system or interference with other functions in the central nervous system. Results of the present study show that the surface electrode can effectively activate the auditory system without interference with other brainstem functions or damage to the stimulated tissues.

The main safety concerns (or side effects) about a brainstem prosthesis are tissue damage and interference with other brainstem functions, as the respiratory centers in the brainstem could be affected by electrical stimulation. The electrical stimulation of the lower brainstem had been reported to result in a rise of body temperature and respiratory rate while heart rate did not show a consistent change (Szelenyi et al 1976). The results of the present study show that stimulation on the cochlear nucleus via this prosthesis can effectively evoke auditory brainstem responses without affecting other life essential functions of the brainstem. There is no change of respiratory rate, CO₂ concentration or body temperature during and after stimulation of the cochlear nucleus, corresponding with the results from penetrating electrodes (Niparko et al. 1989).

The neural damage induced by microelectrode stimulation has generally been examined in two aspects: physiological and morphological effects. The primary concern of pathophysiological effect is depression of the electrical excitability of neurons near the stimulating microelectrode. This is of particular interest because it can seriously compromise the clinical functioning of the neuroprosthesis. The EABR results show that neuronal excitability had not changed after 6 hours of continuous stimulation.

Results of the present study show that only the auditory pathway was labelled by 2-DG, this is a good indication of the efficacy of the prosthesis. That non-auditory systems were not involved shows the auditory brainstem prosthesis is an effective and safe device.

A morphological study is the most reliable technique for safety study. The volume, cell density and cell size of the cochlear nucleus have been used for the study of auditory impairment, and most importantly, for the safety study of the cochlear implant. No changes in the volume, neuron density and soma area of the stimulated cochlear nuclei were found compared with that of the control side. This corroborates earlier study which showed that the changes of neuron excitability preceded gross histological injury (McCreery et al. 1992); our study showed even no changes of the neuron excitability.

In conclusion, the results of this study indicate that with the given stimulation parameter neuronal excitability, volume, neuron size and neuron density of the cochlear nucleus are not affected by continuous electrical stimulation with a bipolar surface electrode in the guinea pig.

REFERENCES

- McCREERY D.B., YUEN T.G.H., AGNEW W.F. & BULLARA L.A.: Stimulation with chronically implanted microelectrode in the cochlear nucleus of the cat: Histologic and physiologic effects. *Hear Res* 62:42-56 (1992).
- NIPARKO, J.K., ALTSCHULER, R.A., EVANS, D.A., XUE, X., FARRAYE, J. & ANDERSON D.J.: Auditory brainstem prosthesis: Biocompatibility of stimulation. *Otolaryngol Head Neck Surg.* 101:344-352 (1989).
- PORTILLO F., NELSON R.A., BRACKMANN D.E., HITSSELBERGER W.E., SHANNON R.V., WARING M.D. & MOORE J.K.: Auditory brain stem implant: Electrical stimulation of the human cochlear nucleus. In: *Cochlear Implants: New Perspectives.* Adv. Otorhinolaryngol. Eds., Frayssse B and Deguine O., Basel, Karger. 248-252 (1993).
- SZELENYI Z., ZEISBERGER E. & BRUCK K.: Effects of electrical stimulation in the lower brainstem on temperature regulation in the unanaesthetized guinea pig. *Pflugers Archiv-European J. of Physiol* 364:123-127 (1996).



Minerva Access is the Institutional Repository of The University of Melbourne

Author/s:

Lui, Xuguang; McPhee, Greg.; Seldon, H. Lee; Clark, Graeme M.

Title:

The histological and physiological effects of the auditory brainstem prosthesis of the auditory pathway

Date:

1997

Citation:

Lui, X., McPhee, G., Seldon, H. L., & Clark, G. M. (1997). The histological and physiological effects of the auditory brainstem prosthesis of the auditory pathway. In Cochlear Implants: XVI World Congress of Otorhinolaryngology Head and Neck Surgery, Sydney, N.S.W.

Persistent Link:

<http://hdl.handle.net/11343/26995>

File Description:

The histological and physiological effects of the auditory brainstem prosthesis of the auditory pathway