

CIBTech Journal of Zoology ISSN: 2319–3883 (Online)

An Open Access, Online International Journal Available at <http://www.cibtech.org/cjz.htm>

2016 Vol. 5 (3) September-December, pp.19-28/Olaolu et al.

## Research Article

# EVALUATION OF THE EFFECT OF *ANCHOMANES DIFFORMIS* ROOT AND BLACK SOAP MIXTURE ON UTERINE FUNCTION INDICES OF RATS

\*T.D. Olaolu, V.A.Okedare and O.B. Akpor

Department of Biological Sciences, Landmark University, PMB 1001, Omu-aran, Kwara State, Nigeria

\*Author for Correspondence

## ABSTRACT

This study was aimed at investigating the effect of aqueous infusion of *Anchomanes difformis* root-black soap mixture on uterine function indices in Wistar rats. Twenty female albino rats (*Rattus norvegicus*) weighing 120-130 g were randomized into 4 subgroups, A – D. Animals in these subgroups received 1 ml of distilled water (control), 0.02, 0.04 and 0.08 ml/kg body weight of aqueous infusion of *Anchomanes difformis* root-black soap mixture respectively. Oral administration to the animals was done once daily for 7 days. Administration of aqueous *A. difformis* root-black soap mixture at all the doses resulted in significant increase ( $P < 0.05$ ) in uterus–body weight ratio, uterine glucose, protein, cholesterol, alkaline phosphatase, serum estradiol, luteinizing hormone and follicle stimulating hormones. This increase was observed to be 171 kg, 0.06 mg/ml, 169 mg/ml, 158 mg/ml, 14.53 nM/min/ml, 58.9 mg/ml, 26.5 mIU/ml and 56.9 mIU/ml respectively compared with control levels of 98.3 kg, 0.02 mg/ml, 100 mg/ml, 99.7 mg/ml, 14.5 nM/min/ml, 10 mg/ml, 8 mIU/ml and 8 mIU/ml respectively. It may be concluded from this study that the oral administration of aqueous infusion of *A. difformis* root-black soap mixture has the ability to increase the synthesis of female hormones and uterine function indices leading to a general enhancement in the functioning of the uterus.

**Keywords:** *Anchomanes difformis*, Black Soap, Uterine Function Indices, Serum Hormones, Infusion

## INTRODUCTION

The uterus is a female reproductive organ situated between the bladder and the rectum in the pelvic region. The uterus has three layers: the internal coating (endometrium); the center solid layer (myometrium); and the external layer (perimetrium). The uterus is associated with the uterine tubes, the cervix, and the vagina. In menstruating females, the ovaries discharge eggs/ova that travel by means of the fallopian tubes to the uterus, the ova will tie themselves to the mass of the uterus and the embryo is formed. The primary role of the uterus is to sustain and ensure the growth of the fetus until delivery/birth (Tekoa *et al.*, 2010). Proper functioning of the uterus may be altered or enhanced by several plant products and chemical compounds through their direct action on the uterus or through their effect on the hypothalamo-pituitary-gonadal axis, inhibiting or improving certain important biochemical processes.

*Anchomanes difformis* is a medicinal plant with the potential to modulate the functioning of the uterus. It belongs to the family Araceae and it is an herbaceous plant with thorny stem having huge isolated leaf and spathe that arise from a horizontal tuber. It is native to Nigeria, Ghana, Ivory Coast, Senegal, Sierra Leone and Togo. It is considered in western part of Nigeria as a powerful herb for treatment of infertility in females, in form of ethanolic or aqueous infusion (Fongod *et al.*, 2013). *A. difformis* is called ogirisako in Igboland and langbodo in Yorubaland, Nigeria, West Africa. *Anchomanes difformis* root has been observed to be a pungent herb that helps in difficult child bearing. It has been reported that the stem leaf and tuber extracts of *A. difformis* contains terpenoids, tannins, alkaloids and glycosides while the extract of the leaf contains steroids (Abah *et al.*, 2011). The stem extract is reported to possess antifungal activity while the water and ethanolic extracts exhibit antitrypanosomal activity (Osho and Adetunji, 2010; Bero *et al.*, 2011). *A. difformis* root in combination with black soap is locally recommended and used by herbal practitioners in a part of Southwest Nigeria for the treatment of female fertility problems, however, there is scarcity of scientific data on its use.

## Research Article

Black soap hails from West Africa, it is also known as ose-dudu in the Yoruba speaking parts of Nigeria (Southwest). It is made up of roasted plantain skin, cocoa pod powder, tropical honey and virgin coconut oil. In some parts of West Africa, coconut oil is usually replaced with palm kernel oil or shea butter. The color of black soap varies from light to dark brown depending on the color of the roasted plantains. A unique characteristic of the black soap is that it does not contain added chemicals, preservatives and colour enhancers (Oyekanmi *et al.*, 2014). This study is therefore, aimed at investigating the effects of infusion of *Anchomanes difformis* root and black soap mixture on some uterine function indices of female Wistar rats.

## MATERIALS AND METHODS

*Anchomanes difformis* root samples were obtained from local herb sellers in Omu-aran community, Kwara State, Nigeria. These root samples were left to dry at room temperature. The plant root was prepared in the form of infusions (30 g of the root was soaked in 50 ml of distilled water and allowed to stand for 72 hours). The infusion was subsequently mixed with black soap in the ratio 3:7 w/v using an electric blending machine and the resulting paste was packed into a glass jar. This was carried out based on the interview with the traditional healers on the preparation of the sample.

A total of 20 female rats were housed in clean metabolic cages contained in well-ventilated standard housing conditions. The animals were allowed free access to rat pellets and tap water and were used according to the Guide for the Care and Use of Laboratory Animals (NRC, 2011). These animals were acclimatized for two weeks before the commencement of the infusion administration. The rats were randomized into 4 subgroups, A – D. Animals in these subgroups received 1 ml of distilled water (control), 0.02, 0.04 and 0.08 ml/kg body weight of aqueous infusion of *Anchomanes difformis* root-black soap mixture respectively.

The animals received the infusion orally, using syringes attached to oropharyngeal cannula once daily for 7 days. The weight of the animals were taken and recorded once in two days.

The animals were sacrificed twenty-four hours after their last dose, blood samples were collected, their uteri were excised and homogenates obtained using standard procedure (Sahoo, 2013).

Assay kits were used for the determination of cholesterol as well as serum hormone levels of Follicle Stimulating Hormone, Luteinizing Hormone and estradiol. These assay kits were products of Agappe Diagnostics Ltd, Switzerland (cholesterol) and Monobind Inc. Lake Forest USA (estradiol, follicle stimulating hormone and luteinizing hormone). FSH, LH and estradiol hormone concentration were quantitatively determined using the enzyme immunoassay (EIA) kit as described in the manufacturer's protocol version.

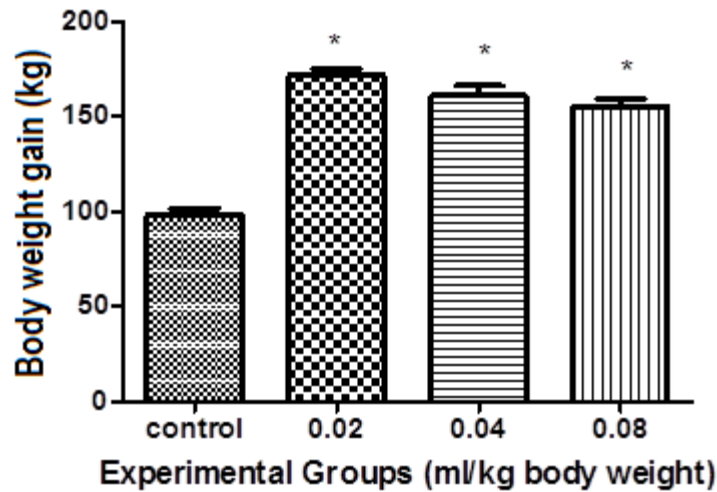
Protein concentration in all the tissues was estimated via biuret reaction as described by Gornall *et al.*, (1949). The concentration of total cholesterol in the uterus was evaluated using the CHOL-CAL reaction according to the method described by Fredrickson *et al.*, (1949). The 'GLUC-PAP' reaction as described by Kemp *et al.*, (1954) was adopted for the determination of uterine glucose concentration. The method employed for the determination of alkaline phosphatase was described by Wright *et al.*, (1972).

The data obtained were expressed as mean  $\pm$  standard error of mean (Mean  $\pm$  SEM) and were analyzed using a one-way analysis of variance (ANOVA) with multiple comparisons and values at  $p < 0.05$  were considered statistically significant.

## RESULTS AND DISCUSSION

The effect of the aqueous infusion of *Anchomanes difformis* root-black soap (Ose-dudu) mixture for 7 days at different concentration of 0.02, 0.04 and 0.08 ml/kg body weight on rats' body weight gain is shown in figure 1. After the 7-day administration of the aqueous infusion of *A. difformis* root-black soap mixture, an increase in the average weight of the animals to 171.9 kg, 161.2 kg and 155.6 kg was observed in animals that received 0.02 ml, 0.04 ml and 0.08 ml per kg body weight of the mixture respectively compared with the control, 98.3 kg. The increment was observed to be significant ( $p < 0.05$ ) across all the groups.

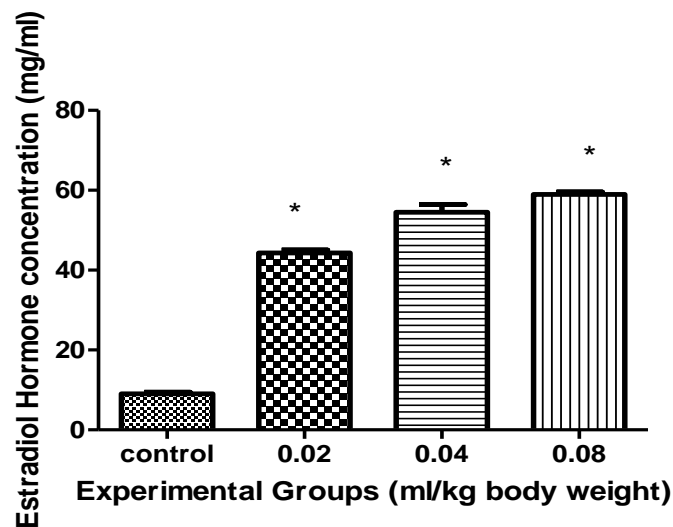
**Research Article**



**Figure 1: The Effect of Aqueous Infusion of *A. difformis* Root-Black Soap Mixture on Rats' Body Weight Gain**

\*Means significantly different at  $P < 0.05$

The effect of aqueous infusion of *A. difformis* root-black soap mixture on the serum estradiol level in animals that received 0.02 ml, 0.04 ml and 0.08 ml/kg body weight of mixture is displayed in figure 2. Increase in the level of serum estradiol was observed to 44.3 mg/ml, 54.5 mg/ml and 58.9 mg/ml respectively compared with the control animals with estradiol level of 10 mg/ml. Significant increase ( $p < 0.05$ ) was observed in the level of serum estradiol in all the animals compared with the control, this was observed to be dose dependent.



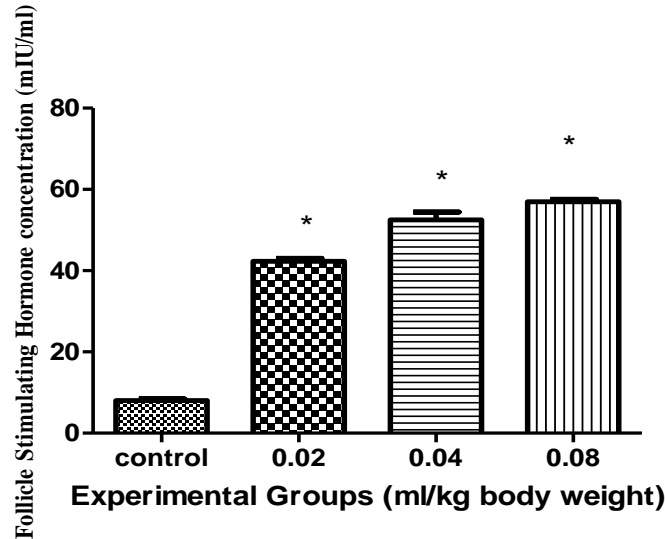
**Figure 2: The Effect of Aqueous Infusion of *A. difformis* Root-Black Soap Mixture on Serum Estradiol Concentration of Treated Female Rats**

\*Means significantly different at  $P < 0.05$

An increase in the level of Follicle Stimulating Hormone FSH across all the groups treated with 0.02 ml/kg, 0.04 ml/kg and 0.08 ml/kg of the mixture was observed at the end of the administration period, this is shown in figure 3. This resulted to 42.3 mIU/ml, 52.5 mIU/ml and 56.9 mIU/ml concentration of

### Research Article

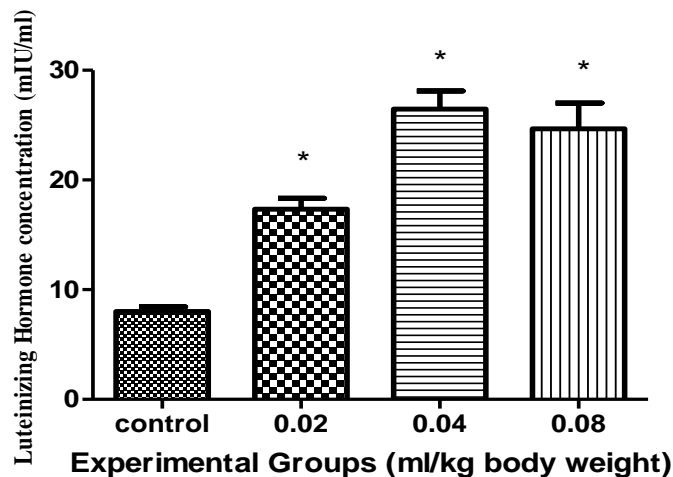
follicle stimulating hormone level respectively compared with the control animals that had FSH level of 8mg/ml concentration. The increment observed in the serum FSH level was dose related. This increase was observed to be significant compared with the control animals ( $p < 0.05$ ).



**Figure 3: The Effect of Aqueous Infusion of *A. difformis* Root-Black Soap Mixture on Follicle Stimulating Hormone Concentration**

\*Means significantly different at  $P < 0.05$

From figure 4, there was an increase in the level of serum luteinizing hormone concentration in the animals across all the groups that received 0.02, 0.04 and 0.08 ml/kg body weight of aqueous infusion from control level of 8 mIU/ml to 17.3 mIU/ml, 26.5 mIU/ml and 24.6 mIU/ml respectively. The increase was observed to be significant ( $p < 0.05$ ) compared with the control.



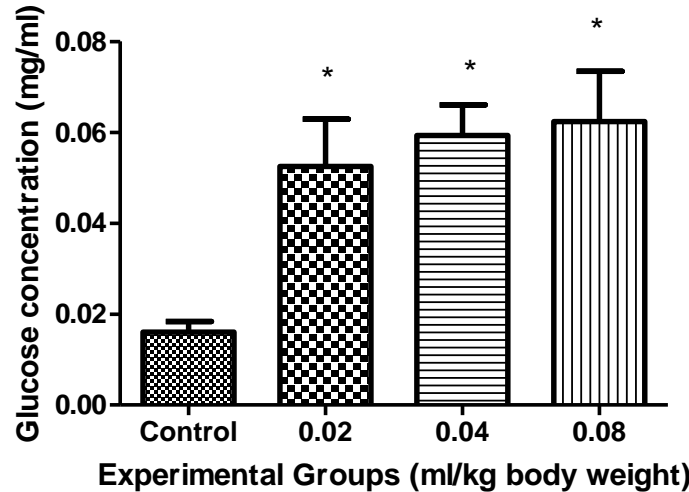
**Figure 4: The Effect of Aqueous Infusion of *Anchomanes Difformis* Root-Black Soap Mixture Infusion on Luteinizing Hormone Concentration**

\*Means significantly different at  $P < 0.05$ .

The effect of aqueous infusion of *A. difformis* root-black soap mixture on uterine glucose as shown in figure 5 reveals an increase in the level of uterine glucose across all the groups that received 0.02 ml, 0.04

### Research Article

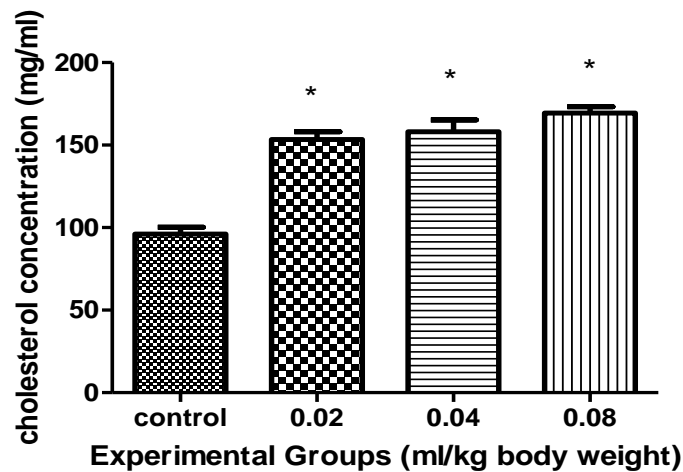
ml and 0.08 ml/kg body weight of mixture from 0.054 mg/ml to 0.065 mg/ml compared with the control animals (0.02 mg/ml). The increment was observed to be in a dose-dependent manner and was statistically significant ( $p < 0.05$ ).



**Figure 5: Effect of Aqueous Infusion of *A. Difformis* Root-Black Soap Mixture on Uterine Glucose Content on Rats**

\*Means significantly different at  $P < 0.05$ .

As shown in figure 6, the administration of aqueous infusion of *A. difformis* root-black soap mixture at different doses displayed remarkable increase in the level of cholesterol. This was observed across all the groups with the concentration of the uterine cholesterol resulting to 152 mg/ml, 155 mg/ml and 158 mg/ml after administration with 0.02, 0.04 and 0.08 ml/kg body weight of the mixture respectively compared with the control (99.7 mg/ml). The increment was observed to be dose-dependent and significant ( $p < 0.05$ ).



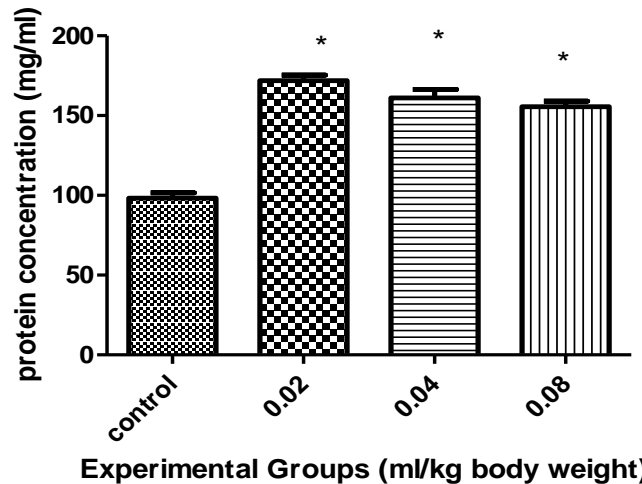
**Figure 6: Effect of Aqueous Infusion of *A. difformis* Root-Black Soap Mixture on Uterine Cholesterol Content**

\*Means significantly different at  $P < 0.05$

Figure 7 reveals the effect of aqueous infusion of *A. difformis* root black soap mixture on uterine protein concentration of animals that received doses ranging from 0.02 ml/kg to 0.08 ml/kg body weight, this was

### Research Article

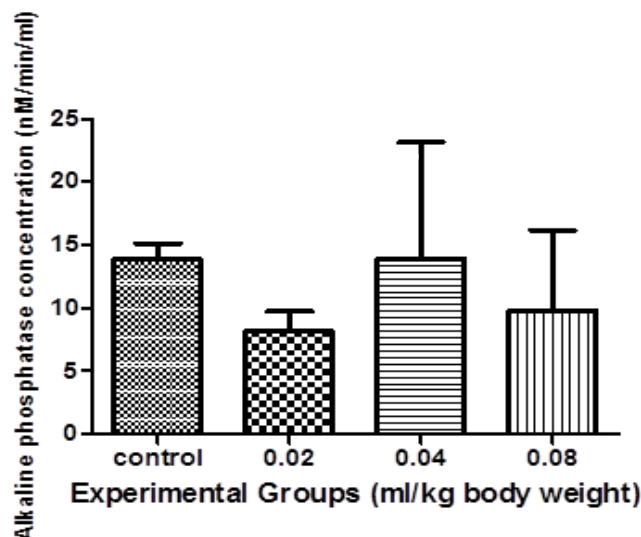
observed to be 169 mg/ml, 160 mg/ml and 154 mg/ml respectively compared with the control (100 mg/ml). This increase was highest in the animals that received 0.02 ml/kg body weight of aqueous infusion of *A. difformis* root-black soap mixture. This increment was observed to be statistically significant ( $P < 0.05$ ) compared to the control group.



**Figure 7: Effect of Aqueous Infusion of *A. difformis* Root-Black Soap Mixture on Uterine Protein Content on Rats**

\*Means significantly different at  $P < 0.05$

In figure 8, the effect of aqueous infusion of *Anchomanes difformis* root-black soap mixture on Alkaline phosphatase ALP level of animals administered with 0.02, 0.04 and 0.08 ml/kg body weight showed the level of alkaline phosphatase activity to be 8.25, 14.53 and 11.2 nM/min/ml respectively compared with the concentration of 14.5 nM/min/ml for control animals, a decrease was observed in ALP level of animals that received 0.02 and 0.08 ml/kg body weight which was not significant ( $P > 0.05$ ) but there was a slight increase in ALP level of animals administered with 0.04 ml/kg body weight of the aqueous infusion which was also not statistically significant ( $P < 0.05$ ).

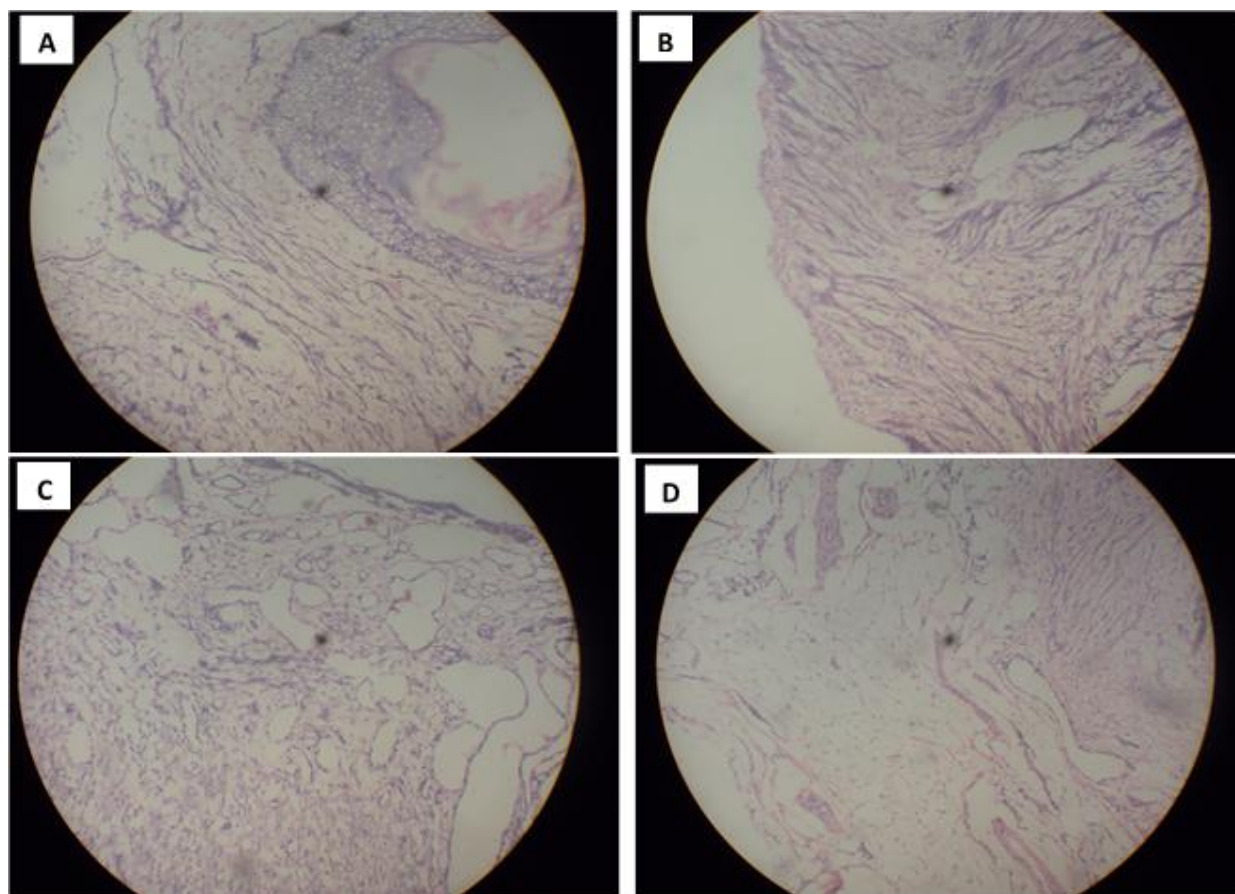


**Figure 8: Effect of Aqueous Infusion of *A. difformis* Root-Black Soap Mixture on Alkaline Phosphatase Content on Uterus of Rat**

\*Means significantly different at  $P < 0.05$

### Research Article

Figure 9 shows the photomicrograph of the uterus of female Wistar rats that received distilled water only (control animals). It shows normal architecture of the wall of the endometrium and the uterus. In the section of uterus of rats that were administered with 0.02 ml/kg body weight of infusion, the micrograph showed the myometrium of the tissue and it appears to be grossly normal. This normal uterine wall architecture observed from the photomicrograph implies that the aqueous infusion of *Anchomanes difformis* root-black soap mixture had no deleterious effect on the uterine tissue at 0.02 ml/kg body weight of infusion. For the photomicrograph of the uterus of animals administered with 0.04 ml/kg body weight of infusion, normal uterine architecture was observed implying grossly normal tissue. This could indicate that the administration of aqueous infusion of *Anchomanes difformis* root-black soap mixture at the dose of 0.04 ml/kg body weight did not adversely affect the normal histology of the uterus of the animals. The photomicrograph of the uterus of animals that received 0.08 ml/kg body weight of infusion showed slight hypertrophy of the tissue, possibly physiological as observed in the increased synthesis of the follicle stimulating hormone and luteinizing hormone with this current dose.



**Figure 9: Micrographs of the Uteri of Female Wistar Rats Administered with Aqueous Infusion of *Anchomanes difformis* Root-Black Soap Mixture; A – Control, B – 0.02 ml/kg Body Weight, C – 0.04 ml/kg Body Weight, D – 0.08 ml/kg Body Weight**

An increase in rat body weight gain was observed in the experimental animals that received aqueous infusion of *Anchomanes difformis* root-black soap mixture. This significant rise in the final weight of the animals in this present study depicts that the animals were generally healthy, this result is in corroboration with a previous report by Al-Nakkash *et al.*, (2010), where they observed an increase in final weight of experimental rats while working on genistein's induction of estrogen-like effects in ovariectomized rats.

## Research Article

The increase in general animal weight observed in this study also aligns with the result of Thakur *et al.*, (2009) who worked on the effect of *Carum carvi* and *Curcuma longa* on female albino rats' hormone.

This study reveals a significant increase in the cholesterol concentration of animals administered with the aqueous infusion of *Anchomanes difformis* root-black soap mixture. This increase in cholesterol concentration could stimulate an increase in the secretion of steroid hormone because cholesterol serves as a precursor in steroidogenesis which is required for increased uterine function (Nurudeen and Ajiboye, 2012).

This result supports the increase that was also observed in the serum estradiol level of the experimental rats in this same study. The result of this study supports that of Dhar (1995) where he worked on antifertility activity and hormonal profile of Trans-anethole in rats.

Alkaline phosphatase has been reported for the ability to recruit carbohydrate, lipids and other metabolites which are essential for steroidogenesis and it is also used by other accessory sex structures (Ramalingam and Vimaladevi, 2002; Yakubu *et al.*, 2008). In this present study, no significant difference was observed in the level of alkaline phosphatase. This may imply that aqueous infusion of *Anchomanes difformis* root-black soap mixture does not negatively impede the process of steroidogenesis. This result is supported by that of Yakubu *et al.*, (2008) who worked on the effect of oral administration of aqueous extract of *Fadogia agrestis* on some reproductive parameters of rats.

In this study, there was an increase in glucose concentration following the administration of the aqueous infusion of *Anchomanes difformis* root-black soap mixture. This reveals an enhancing effect of the herbal infusion on the uterus because glucose is the primary source of energy for uterine cells, it also helps in strengthening the uterine walls and facilitates oogenesis (Gunaga *et al.*, 1972).

Significant increase in the level of uterine protein of animals administered with the aqueous infusion of *Anchomanes difformis* root-black soap mixture was observed in this current study. This could imply improvement in uterine function and oogenesis (Chauhan *et al.*, 2008). Uterine protein concentration has also been associated with enhancement in egg cells formation (Nurudeen and Ajiboye, 2012).

The hormonal assay result for LH, FSH and Estradiol at all doses administered shows significant increase in the levels of these hormones in the serum of animals administered with the aqueous infusion of *Anchomanes difformis* root-black soap mixture. FSH is secreted from the pituitary gland and it regulates reproduction (Dias, 2002).

FSH is a member of glycoprotein polypeptide that induces maturation to ovarian follicle and also regulates the developmental growth (Fan and Hendrickson, 2005). An increase in FSH in this current study may therefore imply enhanced uterine function in the rats. This agrees with the result of Dias (2002) where there was an increase in the level of FSH which enhanced the maturation of ovarian follicle and facilitated oogenesis.

LH stimulates the growth of ova and triggers the production of female estrogen. LH also stimulates ovulation which enhances the function of the uterus (Fan and Hendrickson, 2005). A significant increase in the serum level of LH in the animals administered with aqueous infusion of *Anchomanes difformis* root-black soap mixture in this study indicates increased secretion of estrogen which supports the significant increase in estrogen levels observed in this present study. This is in line with the report of Skibola *et al.*, (2004) while working on the effect of *Fucus vesiculosus* on menstrual cycle length and hormonal status in pre-menopausal women

The increase in serum estradiol level of the experimental rats observed in this study reflects enhancement of uterine function. Estradiol is an essential female sex hormone which is vital for the regulation of the estrous and menstrual female conceptive cycles. The result of this study corroborates with that of Dhar (1995) where he worked on anti fertility activity and hormonal profile of trans-anethole in rats.

## Conclusion

The findings of this present study show that the aqueous infusions of *Anchomanes difformis* root-black soap mixture has a general enhancing effect on the uterus at the dose range of 0.02, 0.04 and 0.08ml/kg body weight of the infusions. This could help in making the uterus conducive in preparation for the fertilization of the egg, implantation and development of the fetus.



## Research Article

### REFERENCES

- Abah ES, Egwari LO and Mosaku TO (2011).** In vitro antimicrobial screening of *Anchomanes difformis*(Blume) Engl. leaves and rhizomes against selected pathogens of public health importance. *Advance Biology Research* **5** 221-225.
- Al-Nakkash L, Markus B, Batia L, Prozialeck WC and Broderick TL (2010).** Genistein induces estrogen-like effects in ovariectomized rats but fails to increase cardiac GLUT4 and oxidative stress. *Journal of Medicinal Food* **13**(6) 1369-1375.
- Bero J, Ganfon H, Jonville MC, Frederich M, Gbaguidi F, Demol P, Moudachirou M and Quetin-Leclercq J (2009).** In vitro antiplasmodial activity of plants used in Benin in traditional medicine to treat malaria. *Journal of Ethnopharmacology* **122** 439-444.
- Chauhan A, Agarwal M, Kushwaha S and Mutreja A (2008).** Antifertility studies of *Aegle marmelos* Corr., an Indian medicinal plant on male albino rats. *Egyptian Journal of Biology* **10** 28-35.
- Dhar SK (1995).** Antifertility activity and hormonal profile of Trans-Anethole in rats. *Indian Journal of Physiology and Pharmacology* **39** 63-67.
- Dias JA (2002).** Molecular, structural and cellular biology of follitropin and follitropin receptor. *Vitamin and Hormones* **64** 249- 322.
- Fan QR & Hendrickson WA (2005).** Structure of human follicle- stimulating hormone in complex with its receptor. *Nature* **433**.
- Fongod AGN, Veranso MC and Libalah MN (2013).** Identification and use of plants in treating infertility in human females in Fako Division, Cameroon. *Global Journal of Research in Medicinal Plants & Indigenous Medicine* **2**(11) 724–737.
- Fredrickson DS, Levy RI and Lees RS (1967).** Fat transport in lipoproteins-An integrated approach to mechanisms and disorders. *New England Journal of Medicine* **276** 148–156.
- Gornal AC, Bardawill CJ and David MM (1949).** Determination of serum protein by means of biuret reaction. *Journal of Biological Chemistry* **177** 751–756.
- Gunaga KP, Rao MC, Sheth AR and Rao SS (1972).** The role of glycogen during the development of the rat testis and prostate. *Journal of Reproduction and Fertility* **29** 157-162.
- Kemp A, Adrienne JM and Heijningen KV (1954).** A colorimetric micro-method for the determination of glycogen in tissues. *Biochemical Journal* **56** 646–648.
- King TL and Brucker MC (2010).** *Pharmacology for Women's Health*, (Jones & Bartlett Publishers, Sudbury, USA) 372–373.
- NRC National Research Council (2011).** *Guide for the Care and Use of Laboratory Animals*, eighth edition, (The National Academies Press, Washington DC, USA).
- Nurudeen QO and Ajiboye TO (2012).** Aqueous root extract of *Lecaniodiscus cupanioides* restores the alterations in testicular parameters of sexually impaired male rats. *Asian Pacific Journal of Reproduction* **1**(2) 120-124.
- Osho A and Adetunji T (2010).** Antimicrobial activity of *Anchomanes difformis* (Blume). *Acta SATECH* **3** 87- 90.
- Oyekanmi AM, Adebayo OR and Farombi AG (2014).** Physicochemical properties of African black soap, and its comparison with industrial black soap. *American Journal of Chemistry* **4**(1) 35-37.
- Sahoo DK (2013).** Protocols for evaluating antioxidant defence and oxidative stress parameters in rats' testis. *Webmedcentral Biochemistry* **4**(5) WMC004265.
- Skibola CF (2004).** The effect of *Fucus vesiculosus*, an edible brown seaweed, upon menstrual cycle length and hormonal status in three pre-menopausal women: a case report. *Journal of Alternate Complement Medicine* **4** 10.
- Thakur S, Bawara B, Dubey A, Durgesh N, Chauhan NS and Saraf DK (2009).** Effect of *Carumcarvi* and *Curcuma longa* on hormonal and reproductive parameter of female rats. *International Journal of Phytomedicine* **1**(1) 31-38.
- Wright PJ, Leathwood PD and Plummer DT (1972).** Enzymes in rat urine: Alkaline phosphatase. *Enzymologia* **42** 317-327.

**Research Article**

**Yakubu MT, Akanji MA and Oladiji AT (2008).** Effect of oral administration of aqueous extract of *Fadogia agrestis* stem on some testicular function indices of male rats. *Journal of Ethno Pharmacology* **11** 288-292.