

ID Design Press, Skopje, Republic of Macedonia
 Open Access Macedonian Journal of Medical Sciences. 2018 Oct 25; 6(10):1829-1832.
<https://doi.org/10.3889/oamjms.2018.409>
 eISSN: 1857-9655
 Clinical Science



EBV Positive Gastric Carcinomas and Their Clinicopathological Characteristics

Ljubomir Ognjenovic^{1*}, Aleksandar Shumkovski¹, Stojan Gjoshev¹, Goce Volchevski¹, Gjorgji Trajkovski¹, Zoran Karadzov¹, Darko Dzambaz¹, Dragan Hadzi-Manchev¹, Todor Hadzi-Manchev¹, Gordana Petrushevska², Vesna Janevska², Vlado Janevski¹, Nikola Brzanov³

¹University Clinic for Abdominal Surgery, Faculty of Medicine, Ss. Cyril and Methodius University in Skopje, Skopje, Republic of Macedonia; ²Institute of Pathology, Faculty of Medicine, Ss. Cyril and Methodius University in Skopje, Skopje, Republic of Macedonia; ³Univeristy Clinic for TOARILUC, Faculty of Medicine, Ss. Cyril and Methodius University in Skopje, Skopje, Republic of Macedonia

Abstract

Citation: Ognjenovic Lj, Shumkovski A, Gjoshev S, Volchevski G, Trajkovski G, Karadzov Z, Dzambaz D, Hadzi-Manchev D, Hadzi-Manchev T, Petrushevska G, Janevska V, Janevski V, Brzanov N. EBV Positive Gastric Carcinomas and Their Clinicopathological Characteristics. Open Access Maced J Med Sci. 2018 Oct 25; 6(10):1829-1832. <https://doi.org/10.3889/oamjms.2018.409>

Keywords: EBV; Gastric carcinoma; Immunohistochemistry; Clinicopathological characteristics

***Correspondence:** Ljubomir Ognjenovic, University Clinic for Abdominal Surgery, Faculty of Medicine, Ss. Cyril and Methodius University in Skopje, Republic of Macedonia. E-mail: ljognjenovic@gmail.com

Received: 13-Sep-2018; **Revised:** 04-Oct-2018; **Accepted:** 05-Oct-2018; **Online first:** 12-Oct-2018

Copyright: © 2018 Ljubomir Ognjenovic, Aleksandar Shumkovski, Stojan Gjoshev, Goce Volchevski, Gjorgji Trajkovski, Zoran Karadzov, Darko Dzambaz, Dragan Hadzi-Manchev, Todor Hadzi-Manchev, Gordana Petrushevska, Vesna Janevska, Vlado Janevski, Nikola Brzanov. This is an open-access article distributed under the terms of the Creative Commons Attribution-NonCommercial 4.0 International License (CC BY-NC 4.0)

Funding: This research did not receive any financial support

Competing Interests: The authors have declared that no competing interests exist

BACKGROUND: The understanding of the etiopathogenesis of gastric carcinoma (GC) can be a base for development of new therapeutic methods to reduce mortality and to increase survival in patients with GC. The percentage of Epstein - Barr virus (EBV) positive gastric carcinomas is uncertain, and the etiologic importance of EBV in the pathogenesis of GC has still not been elucidated.

AIM: This study aimed to determine the percentage of EBV associated GC as well as to determine their clinicopathological characteristics.

MATERIAL AND METHODS: The study included 80 patients with GC who were analysed for ethnicity, local growth of a tumour (T status), the presence of nodal metastases (N), the presence of distant metastases (M), stage of the disease and degree of carcinoma differentiation. For detection of EBV, immunostainings were performed on tumour tissue and the peripheral non-tumour gastric mucosa.

RESULTS: Positive immunostaining with an antibody against EBV was found in 19 (23.75%) of the 80 patients with gastric carcinomas. EBV immunostainings were significantly different in patients with or without metastasis and between patients of Macedonian and Albanian ethnicity ($p < 0.0001$, $p < 0.009$, respectively). EBV immunoexpression was significantly associated with the presence of distant metastases and with patients of Albanian ethnicity.

CONCLUSION: Association of EBV immunostainings with distant metastasis in patients with GC suggests the influence of EBV infection on the progression of gastric carcinoma. Due to scarce and doubtful literature data on EBV associated GC, further studies are necessary to determine the role of EBV regarding aetiology, treatment and prognosis in patients with EBV associated gastric carcinoma.

Introduction

The survival rate of patients with gastric carcinoma (GC) is still low in spite of the numerous surgical techniques and development of supplementary preoperative, neoadjuvant and adjuvant protocols for chemotherapy [1] [2] [3] [4]. Therefore, medical treatment of gastric carcinoma

urgently requires new therapeutic options. The understanding of the etiopathogenesis of this carcinoma can be a solid base for the development of new therapeutic methods for decreasing the mortality and increasing the survival rate in GC patients.

Over the last decade, a large number of data have been published on the association of gastric carcinoma with Epstein - Barr virus (EBV) that is

believed to play a role in the carcinogenesis of this neoplasm. The percentage of EBV positive gastric carcinoma is uncertain, and the etiological importance has still not been elucidated [5] [6]. The conducted meta-analysis of 70 studies that included a total of 15,952 cases of GC revealed that EBV positive gastric carcinomas differed from the other gastric carcinoma by gender distribution, anatomic localisation and surgically different anatomy, indicating that EBV-associated gastric carcinoma is a particular etiological entity [5]. Epidemiological studies from different regions and studies that contribute to defining the role of EBV in the carcinogenesis and progression of GC are useful for the development of new therapeutic modalities [6].

This study aimed to determine the association of EBV with gastric carcinoma as well as to correlate it with different clinicopathological parameters.

Material and Methods

This study included 80 patients with gastric carcinoma surgically treated at the University Clinic for Abdominal Surgery in Skopje, whose operative material was analysed at the Institute of Pathology, Medical Faculty in Skopje.

The following parameters were analysed in the study: ethnicity of patients, local tumour growth (T status), the presence of nodal metastasis (N), the presence of distant metastasis (M), stage of the disease and degree of carcinoma differentiation.

The data for the parameters of the TNM classification (AJCC Cancer Staging 2017) were obtained from the archival histopathological reports of the Institute of Pathology in Skopje, and for the clinical stage we used patient's files from the University Clinic for Abdominal Surgery in Skopje, including ultrasound and computed tomography files.

For detection of EBV, immunostainings were performed on tumour tissue and the peripheral non-tumour gastric mucosa.

A standard commercial control was used for immunostaining control.

Immunohistochemical stainings for EBV were made with a standard procedure using Immunoperoxidase LSAB + system and specific primary monoclonal EBV-antibody (DAKO – Monoclonal Mouse. Anti-Epstein Barr Virus, LMP. Clones CS. 1-4. Code IR753).

EBV expression was defined in 2 histological patterns, nuclear and cytoplasmic (Figure 1).

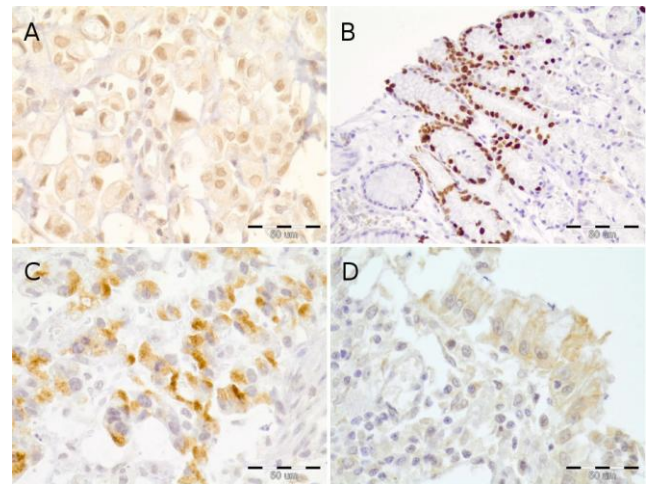


Figure 1: A) Nuclear positivity for EBV in signet cell gastric carcinoma (10 x 20); B) Nuclear EBV positivity in a cluster of glands in peri-tumour mucosa with intestinal metaplasia (10 x 10); C) Cytoplasmic positivity for EBV in gastric cancer (10 x 20); D) Cytoplasmic EBV positivity in peri-tumor cylindrical cells and in plasma cells present in submucosa of the gaster (10 x 20)

Descriptive statistical methods were used for statistical analysis of the data. Categorical variables are presented with absolute and relative numbers (%). Fisher's exact test, Student's t-test and Chi-square test were used for comparison of categorical variables. Spearman's correlation coefficient was used to determine the degree of correlation between analysed parameters. The statistical program SPSS for Windows, version 19.0 was used.

Results

Expression of EBV in cells was nuclear and cytoplasmic. Nuclear expression was found in 15 (18.75%) cases and cytoplasmic in 4 (5%) cases. In 10 (66.66%) of positively stained cases, nuclear EBV expression showed the patchy distribution in clusters of cells and the other 5 (33.33%) cases EBV positivity was diffuse in the tumour cells. The expression of EBV in the peri-tumour gastric mucosa showed patchy distribution.

Positive expression of EBV protein was also detected in plasma cells present in the tumour stroma, or gastric submucosa of the patients with GC (Figure 1).

Positive immunostaining with the antibody against EBV was found in 19 (23.75%) of the total of 80 gastric carcinomas.

The mean age of patients with negative EBV expression was 66.05 ± 10.6 years, and of those with positive EBV expression was 63.2 ± 9.5 years ($p > 0.05$).

The immunoexpression of EBV about the analysed clinicopathologic parameters is shown in Table 1.

Table 1: Immunoexpression of EBV about the analysed clinicopathologic parameters

Parameter	N	EBV expression		P-value
		EBV -	EBV+	
Gender				
Male	25	21 (84%)	4 (16)	0.27 ns P (Chi-square test)
Female	55	40 (72.73)	15 (27.27)	
Intra-gastric localisation				
Cardia	31	23 (74.19)	8 (25.81)	0.55 ns P (Fisher exact test)
Body	20	14 (70)	6 (30)	
Pylorus	29	24 (82.76)	5 (17.24)	
T				
T1	4	4 (100%)	0	0.25 ns P (Fisher exact test)
T2	13	11 (84.62)	2 (15.38)	
T3	14	8 (57.14)	6 (42.86)	
T4	49	38 (77.55)	11 (22.45)	
Lymph node metastasis				
No	16	12 (75%)	4 (25%)	1.0 Ns P (Fisher exact test)
Yes	64	49 (76.56%)	15 (23.44%)	
M				
No	72	53 (73.61)	19 (26.39)	<0.0001 sig P (Fisher exact test)
Yes	8	0	8 (100)	
Stage				
I	7	7 (100%)	0	0.076 ns P (Fisher exact test)
II	17	11 (64.71)	6 (35.29)	
III	47	34 (72.34)	13 (27.66)	
IV	9	9 (100)	0	
Grade				
G1	1	0	1 (100%)	0.12 ns P (Fisher exact test)
G2	36	30 (83.33)	6 (16.67)	
G3	43	31 (72.09)	12 (27.91)	
Ethnicity				
Macedonian	62	52 (83.87)	10 (16.13)	0.009 sig P (Fisher exact test)
Albanian	18	9 (50)	9 (50)	

The results obtained in this study regarding positivity of EBV between patients with gastric carcinoma with different N stage showed no significant difference ($p > 0.05$).

A significant difference regarding immunoexpression of EBV was found in GC patients with or without distant metastases ($p < 0.0001$). In patients with gastric carcinoma, the presence of infection along with EBV was significantly associated with distant metastases.

Infection with Epstein-Bar virus was significantly more common among patients of Albanian nationality than in Macedonian patients ($p = 0.009$). EBV immunoexpression was detected in 50% (9) of Albanian patients against 16.13% (10) of Macedonian patients.

Discussion

EBV is a herpes virus that is widely spread among the human population. The infection with EBV is commonly acquired during early childhood by salivary transmission [7]. The virus causes long-term infection of B lymphocytes in about 90% of adults, who are asymptomatic. A small percentage of infected people develop hematopoietic, epithelial and mesenchymal tumours. The EBV infection is a cause

for the development of Burkitt lymphoma, lymphoma associated with immunosuppression, Hodgkin's lymphoma, sinonasal angiocentric T lymphoma, nasopharyngeal carcinoma and leiomyosarcoma in immunocompromised patients [5] [7]. It is believed that the oncogenic effect of the virus is carried out by expression of an EBV nuclear antigen and latent membranous proteins that interact with some suppressor genes and signal pathways [7].

According to literature data, the EBV infection is associated with 2-16% of gastric carcinoma, but the published data, in general, refer to the role of EBV in carcinogenesis. Few data on the association of EBV with gastric carcinoma and its characteristics are available in the literature [7] [8] [9] [10]. The prevalence of gastric carcinoma associated with EBV infection shows geographic variations [11] and is related to the lifestyle of patients. Thus, studies about EBV associated gastric carcinomas are necessary and very actual [5] [6].

Gastric carcinomas of the antrum show a low percentage of EBV-associated infection compared to the carcinoma of the cardia [5], and it is found in the highest percentage (90.5%) in lymphoepithelioma-like gastric carcinoma [12].

Some studies have demonstrated the association of EBV gastric carcinoma with the age of patients [13].

The meta-analysis conducted by Lee JH *et al.*, of 48 studies on EBV-associated gastric carcinoma (EBVaGC) showed a significant association with the nationality. The analysis also found that EBVaGC was more frequent in men, young individuals, Caucasians and Latin Americans, in cardia as a localisation of the carcinoma, and in the diffuse histological type [14].

In our study, we detected EBV presence in 23.75% (19) of our patients, which is a high percentage of EBV-associated GC in comparison with the results in the literature [11] [13]. EBV immunoexpression was significantly different in patients with or without metastasis and patients of Macedonian and Albanian nationality.

EBV immunosuppression was significantly associated with the presence of distant metastases and with Albanian ethnicity.

The significant correlation of EBV immunosuppression with distant metastasis in GC patients suggests the influence of EBV infection on the progression of gastric carcinoma.

Due to relatively limited and doubtful literature data about EBVaGC, further studies are necessary to determine the role of EBV regarding the aetiology, treatment and prognosis in patients with EBV associated carcinoma.

Reference

1. Parkin DM, Bray F, Ferlay J, Pisani P. Global cancer statistics, 2002. *CA Cancer J Clin.* 2005; 55:74–108. <https://doi.org/10.3322/canjclin.55.2.74> PMID:15761078
2. Jemal A, Bray F, Center MM, et al. Global cancer statistics. *CA Cancer J Clin.* 2011; 61:69–90. <https://doi.org/10.3322/caac.20107> PMID:21296855
3. Cunningham D, Allum WH, Stenning SP, et al. Perioperative chemotherapy versus surgery alone for resectable gastroesophageal cancer. *New Eng J Med.* 2006; 355(1):11–22. <https://doi.org/10.1056/NEJMoa055531> PMID:16822992
4. Macdonald JS, Smalley SR, Benedetti J, et al. Chemoradiotherapy after surgery compared with surgery alone for adenocarcinoma of the stomach or gastroesophageal junction. *N Eng J Med.* 2001; 345(10):725–730. <https://doi.org/10.1056/NEJMoa010187> PMID:11547741
5. Murphy G, Pfeiffer R, Constanza Camargo CM, Rabkin C. Meta-analysis Shows That Prevalence of Epstein–Barr Virus-Positive Gastric Cancer Differs Based on Sex and Anatomic Location. *Gastroenterology.* 2009; 137:824–833. <https://doi.org/10.1053/j.gastro.2009.05.001> PMID:19445939 PMID:PMC3513767
6. Truong CD, Feng W, Li W, Khoury T, Li Q, Alrawi S, Yu Y, Xie K, Yao J, Tan D. Characteristics of Epstein-Barr virus-associated gastric cancer: a study of 235 cases at a comprehensive cancer center in U.S.A. *Exp Clin Cancer Res.* 2009; 28:14. <https://doi.org/10.1186/1756-9966-28-14> PMID:19192297 PMID:PMC2642773
7. Kim Y, Shin A, Gwack J, Ko KP, Kim CS, Park SK, Hong YC, Kang D, Yoo KY. Epstein-Barr virus antibody level and gastric cancer risk in Korea: a nested case-control study. *Br J Cancer.* 2009; 101(3):526–9. <https://doi.org/10.1038/sj.bjc.6605146> PMID:19550421 PMID:PMC2720236
8. Tokunaga M, Land CE. Epstein-Barr virus involvement in gastric cancer: biomarker for lymph node metastasis. *Cancer Epidemiol Biomarkers.* 1998; 7:449–450.
9. Takada K. Epstein-Barr virus and gastric carcinoma. *Mol Pathol.* 2000; 53:255–61. <https://doi.org/10.1136/mp.53.5.255> PMID:11091849 PMID:PMC1186978
10. Fukayama M, Hayashi Y, Iwasaki Y, et al. Epstein-Barr virus associated gastric carcinoma and Epstein-Barr virus infection of the stomach. *Lab Invest.* 1994; 71:73–81. PMID:8041121
11. Burgess DE, Woodman CB, Flavell KJ, et al. Low prevalence of Epstein-Barr virus in incident gastric adenocarcinomas from the United Kingdom. *Br J Cancer.* 2002; 86:702–4. <https://doi.org/10.1038/sj.bjc.6600107> PMID:11875729 PMID:PMC2375309
12. Wang HH, Wu MS, Shun CT, et al. Lymphoepithelioma-like carcinoma of the stomach: a subset of gastric carcinoma with distinct clinicopathological features and high prevalence of Epstein-Barr virus infection. *Hepatogastroenterol.* 1999; 46:1214–9.
13. Herrera-Goepfert R, Akiba S, Koriyama C, Ding S, Reyes E, Itoh T, Minakami Y, Eizuru Y. Epstein-Barr virus-associated gastric carcinoma: Evidence of age-dependence among a Mexican population. *World J Gastroenterol.* 2005; 11(39):6096–103. <https://doi.org/10.3748/wjg.v11.i39.6096> PMID:16273633 PMID:PMC4436624
14. Lee JH, Kim SH, Han SH, An JS, Lee ES, Kim YS. Clinicopathological and Molecular Characteristics of Epstein-Barr Virus-associated Gastric Carcinoma: A Meta-analysis. *J Gastroenterol Hepatol.* 2009; 24(3):354–65. <https://doi.org/10.1111/j.1440-1746.2009.05775.x> PMID:19335785