

ID Design Press, Skopje, Republic of Macedonia
 Open Access Macedonian Journal of Medical Sciences. 2018 Jun 20; 6(6):1059-1061.
<https://doi.org/10.3889/oamjms.2018.135>
 eISSN: 1857-9655
Clinical Science



Apitherapy as a New Approach in Treatment of Palmoplantar Psoriasis

Egharid El-Gamhal¹, Veronica Di Nardo^{2*}, Farah Daaboul³, Georgi Tchernev^{4,5}, Uwe Wollina⁶, Jacopo Lotti², Torello Lotti⁷

¹National Research Centre, Doqi, Cairo, Egypt; ²Department of Nuclear, Subnuclear and Radiation Physics, University of Rome "G. Marconi", Rome, Italy; ³Institute of Dermatological and Regenerative Sciences - Dermatology and Nutrition, Florence, Italy; ⁴Medical Institute of Ministry of Interior (MVR), Department of Dermatology, Venereology and Dermatologic Surgery, Sofia, Bulgaria; ⁵Onkoderma, Policlinic for Dermatology and Dermatologic Surgery, Sofia, Bulgaria; ⁶Städtisches Klinikum Dresden, Department of Dermatology and Allergology, Dresden, Germany; ⁷University "G. Marconi" - Institute of Dermatology, Rome, Italy

Abstract

Citation: El-Gamhal E, Di Nardo V, Daaboul F, Tchernev G, Wollina U, Lotti J, Lotti T. Apitherapy as a New Approach in Treatment of Palmoplantar Psoriasis. Open Access Maced J Med Sci. 2018 Jun 20; 6(6):1059-1061. <https://doi.org/10.3889/oamjms.2018.135>

Keywords: Psoriasis; Apitherapy; Skin disease; Natural therapy; Propolis

***Correspondence:** Veronica Di Nardo. Department of Nuclear, Subnuclear and Radiation Physics, University of Rome "G. Marconi", Rome, Italy. E-mail: studionutrim@gmail.com

Received: 23-Jan-2018; **Revised:** 20-Feb-2018; **Accepted:** 22-Feb-2018; **Online first:** 10-Jun-2018

Copyright: © 2018 Egharid El-Gamhal, Veronica Di Nardo, Farah Daaboul, Georgi Tchernev, Uwe Wollina, Jacopo Lotti, Torello Lotti. This is an open-access article distributed under the terms of the Creative Commons Attribution-NonCommercial 4.0 International License (CC BY-NC 4.0)

Funding: This research did not receive any financial support

Competing Interests: The authors have declared that no competing interests exist

BACKGROUND: Apitherapy is the medical use of honey bee products, "honey, propolis, royal jelly, bee wax, and bee venom to relieve human ailments. Propolis is one of the most well-documented products derived from the honeybee and has always played an important role in traditional folk medicine.

AIM: The aim was to justify the consideration of Aloe Vera as an effective remedy for the treatment of psoriasis.

METHODS: The study follows (857) patients (354 females, 503 males) with a mean age range from (9 - 62) years, affected with moderate to severe psoriasis in palms and foot soles treated by a combination mixture of propolis and Aloe in the form of an ointment (Aloreed) and Beauty reed cream. The treatment duration was for 12 weeks. Results were evaluated by using clinical, histological and statistical parameters.

RESULTS: After the 12 - week treatment, we observed an 86% overall response rate from which 62% showed excellent results and 24% showed good results, therefore proving the efficiency in the use of the mixture of propolis 50% and aloe vera 3% as topically applied ointment in the treatment of mild to moderate psoriasis

CONCLUSION: Patients who have palmoplantar psoriasis, who were treated with a topically applied mixture of propolis (50%) and aloe vera (3%), have shown noteworthy improvement thus proving the efficiency of propolis and aloe vera in the treatment of mild to moderate psoriasis.

Introduction

Psoriasis is a genetic inflammatory and proliferative skin disease characterised by chronic, sharply bordered, dull - red, scaly plaques appeared on the skin and particularly on the extensor prominences and in the scalp area [1]. On the palms and soles, psoriasis may present as scaly white patches; a fine silvery scale can be evoked by scratching, as less well - defined plaques resembling lichen simplex or hyperkeratotic eczema - or as a pustulosis (chronic palmoplantar pustular psoriasis). A strong association between body mass index and psoriasis was shown [2].

There is no satisfactory or effective cure for psoriasis. However a variety of therapeutic modalities have yielded limited efficacy with frequent side effects. Available treatments include both local and systemic ones. *In vivo* and *in vitro* data prove the effectiveness of cytokines taken in low - doses [3] and antioxidants [4]. Complementary therapy based on psychotherapeutic approaches has also shown some efficacy [5].

Apitherapy is a therapy that uses hive products (e.g. propolis) for medical and pharmacological purposes [6]. It was found that propolis has versatile activities including physiological, antibacterial, antiviral, fungicide, local anaesthetic, antiulcer, immunostimulant and recently discovered

cytostatic activities. The principal components of propolis are flavonoids of group 5 (betulinol, quercetin, isovanillin), caffeic acids, unsaturated aromatic acid, and ferulic acids. Propolis is a very stable substance and has equal composition regardless of the geographic areas where it was produced. The composition of propolis indicates high antioxidant activity, and thus the substance can be investigated for the treatment of psoriasis.

Aloe vera is a plant that grows widely in the Egyptian desert. Its mucilaginous gel has been used in folk medicine for its effectiveness in itching, hair loss and burns. Aloe vera has also been proven to be effective in cutaneous wound healing [7]. Research has shown that active agents have considerable analgesic, antipruritic, wound healing and anti-inflammatory properties [8].

The aim was to justify the consideration of Aloe Vera as an effective remedy for the treatment of psoriasis.

Patients and Methods

The study follows (857) patients (354 females & 503 males) with a mean age range from (9 - 62) years, affected with a clinical diagnosis of mild to moderate psoriasis of palms and soles.

The subjects, afferent to the in the centre of dermatology in Heliopolis (Cairo - Egypt), were randomly allocated. Written consent was approved by all patients under this clinical trial, Patient information and progress was thoroughly documented during the study. Both treatment and follow - up was taken place in the centre of dermatology in Heliopolis from July 2006 to August 2008.

During the start and toward the end of the study skin biopsies were taken and stained with hematoxylin and eosin (H&E) for the evaluation of acanthosis, parakeratosis, thinning capillary dilatation, and inflammatory infiltration. A leading pharmaceutical company was responsible for preparation of the mixture (Propolis 50% with Aloe 3%) as an ointment [6].

Pre-treatment biopsy

A punch biopsy was taken before application of the treatment and stained by H&E for histological examination.

Treatment application

Patients were advised to rub the ointment into psoriatic palms and soles twice daily for 4 - 12 weeks.

Follow up

On a weekly basis reexamination and evaluation of the treated areas were done to control any side effects and to analyse the degree of patient satisfaction or inconvenience, follow up lasted for 12 weeks.

Post-treatment biopsy

At the end of the study, a punch biopsy was taken from the treated area to evaluate the efficacy of the treatment.

Post-treatment assessment

Assessment of the trial therapy depended on clinical state, photography and histopathology and was classified as follows:

1. Excellent response: when all psoriatic lesions disappeared, and skin became nearly normal (No erythema, no infiltration or desquamation of skin).
2. Good response: when some of the lesions disappeared.
3. Weak response: when no marked improvement was noted.
4. No response: when no improvement was seen.

For a standard method of clinical assessment of patients, Psoriasis Area and Severity Index (PASI score) was used. This clinical rating system assesses the area of the body affected by the intensity of the main symptoms.

To measure the % reduction of PASI Score, we applied the following equation:

$$\% \text{ reduction of PASI score} = \frac{\text{Baseline PASI} - \text{PASI at the end of the program}}{\text{Baseline PASI}} \times 100$$

Result

After the 12 - week treatment, we observed an 86% overall response rate from which 62% showed excellent results and 24% showed good results, therefore proving the efficiency in the use of the mixture of propolis 50% and aloe vera 3% as topically applied ointment in the treatment of mild to moderate psoriasis [6].

Table 1: Comparison of the mean effective and non-effective

| Variable | Effective | Non-Effective | t | P |
|--------------|-------------------------|-------------------------|------|--------|
| | Mean ± SD N = 625 | Mean ± SD N = 232 | | |
| % -reduction | 0.73 ± 0.26 | 0.28 ± 0.033 | 5.57 | < 0.01 |

** H. is significant.

Table 2: Comparison of the mean excellent and good effect

| Variable | Excellent Effective | Good Effective | t | P |
|--------------|---------------------|----------------|-------|--------|
| | Mean ± SD | Mean ± SD | | |
| | N = 531 | N = 205 | ** | |
| % -reduction | 0.87 | 0.38 | 38.24 | < 0.01 |

** H. is significant.

Punch biopsy was taken before application of the treatment and stained to be examined histologically.

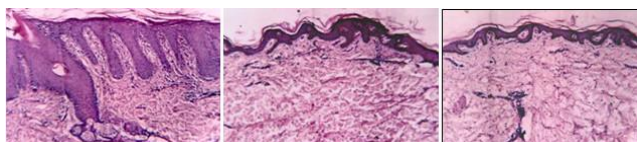


Figure 1: Pre and post Treatment Histology (Biopsy Rt.Sole)

Within the typical plaque, psoriatic epidermis shows marked epidermal acanthosis, hyperkeratosis, and elongation of capillaries, and presence of Munro's microabscesses (to the left).

Table 3: Results of treatment

| Effect | Count % | Result | | | Total |
|------------|---------|--------------|--------------|-------------|----------------------------|
| | | Excellent | Good | No Response | |
| Effect | Count % | 531 72.1% | 206 27.9% | - | 737 100% |
| Non Effect | Count % | - | - | 68 4% | 52 42.9% 120 100% |
| Total | Count % | 531 62% | 206 24% | 68 4% | 52 6% 857 100% |

Chi Square Test =857 **; **H sig.

Parakeratosis changed to orthokeratosis, acanthosis decreased, the rete ridges became shorter, and Munro's microabscesses disappeared (to the right).

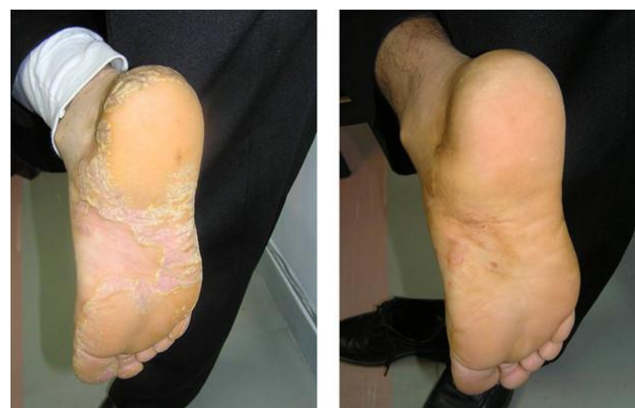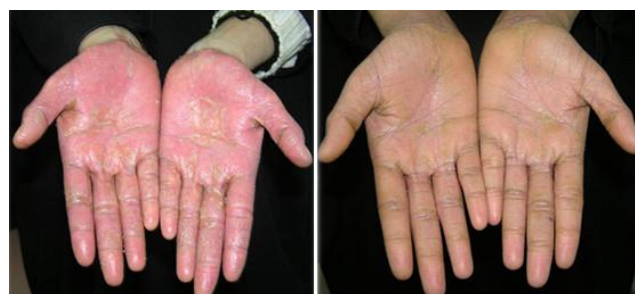Table 4: Results of treatment % reduction of the PASI score

| %- a reduction of PASI score | Cases | Per cent |
|------------------------------|-------|----------|
| Effective 33% ↓↓ | 737 | 86% |
| Non Effective 33% ↑↑ | 120 | 14% |
| Total | 857 | 100% |

In conclusion, patients who have palmoplantar psoriasis, who were treated with a topically applied mixture of propolis (50%) and aloe vera (3%), have shown noteworthy improvement thus proving the efficiency of propolis and aloe vera in the treatment of mild to moderate psoriasis.

Table 5: Results of treatment - effectiveness

| Effective | Cases | Per cent |
|---------------|-------|----------|
| | | |
| Effective | 531 | 62% |
| | 206 | 24% |
| Non-Effective | 52 | 6% |
| | 68 | 8% |
| Total | 857 | 100% |



Pre TTT

Post 3Ms

Figure 2: Pre (left) and post (right) 3 months of treatment

References

- Lotti T, Hercogova J, Prignano F. The concept of psoriatic disease: can cutaneous psoriasis any longer be separated by the systemic comorbidities? *Dermatol Ther.* 2010; 23(2):119-22. <https://doi.org/10.1111/j.1529-8019.2010.01305.x> PMID:20415818
- Hercogová J, Ricceri F, Tripo L, Lotti T, Prignano F. Psoriasis and body mass index. *Dermatol Ther.* 2010; 23(2):152-4. <https://doi.org/10.1111/j.1529-8019.2010.01309.x> PMID:20415822
- Barygina V, Becatti M, Lotti T, Taddei N, Fiorillo C. J Low dose cytokines reduce oxidative stress in primary lesional fibroblasts obtained from psoriatic patients. *Dermatol Sci.* 2016; 83(3):242-4. <https://doi.org/10.1016/j.idermsci.2016.06.002> PMID:27317477
- Barygina V, Becatti M, Soldi G, Prignano F, Lotti T, Nassi P, Wright D, Taddei N, Fiorillo C. Altered redox status in the blood of psoriatic patients: involvement of NADPH oxidase and role of anti-TNF-α therapy. *Redox Rep.* 2013; 18(3):100-6. <https://doi.org/10.1179/1351000213Y.0000000045> PMID:23601139
- Capella GL1, Finzi AF. Complementary therapy for psoriasis. *Dermatol Ther.* 2003; 16(2):164-74. <https://doi.org/10.1046/j.1529-8019.2003.01625.x>
- El- Gammal A. In Medical environmental science: Apitherapy as a new approach in the treatment of psoriasis. *African Journal of Dermatology.* 2006:6-2
- Hashemi SA, Madani SA, Abediankenari S. The Review on Properties of Aloe Vera in Healing of Cutaneous Wounds. *BioMed Research International.* 2015; 714216. <https://doi.org/10.1155/2015/714216>
- Duke EE. Treatment of skin conditions: *Dermatology - an Illustrated Guide.* Canadian Medical Association Journal. 1985; 133(12):1254.