

ID Design Press, Skopje, Republic of Macedonia
 Open Access Macedonian Journal of Medical Sciences. 2018 Jun 20; 6(6):1091-1094.
<https://doi.org/10.3889/oamjms.2018.239>
 eISSN: 1857-9655
Case Report



Endometrioid Adenocarcinoma Arising in Adenomyoma in a Woman with a Genital Prolapse - Case Report

Vesna S. Antovska¹, Iskra Krstevska¹, Milka Trajanova¹, Jasmina Chelebieva^{1*}, Irena Gosheva¹, Pance Zdravkovski², Slavica Kostadinova-Kunovska², Vesna Janevska²

¹University Clinic for Gynecology and Obstetrics, Department for Urogynaecology and Pelvic Floor Disorders, Ss Cyril and Methodius University of Skopje, Skopje, Republic of Macedonia; ²Institute of Pathology, Faculty of Medicine, Ss Cyril and Methodius University of Skopje, Skopje, Republic of Macedonia

Abstract

Citation: Antovska VS, Krstevska I, Trajanova M, Chelebieva J, Gosheva I, Zdravkovski P, Kostadinova-Kunovska S, Janevska V. Endometrioid Adenocarcinoma Arising in Adenomyoma in a Woman with a Genital Prolapse-Case Report. Open Access Maced J Med Sci. 2018 Jun 20; 6(6):1091-1094. <https://doi.org/10.3889/oamjms.2018.239>

Keywords: Endometrial cancer; Uterine leiomyoma; Genital prolapse

***Correspondence:** Jasmina Chelebieva, University Clinic for Gynecology and Obstetrics, Department for Urogynaecology and Pelvic Floor Disorders, Skopje, Republic of Macedonia. E-mail: jasminda_medicine2006@hotmail.com

Received: 14-May-2018; **Revised:** 23-May-2018; **Accepted:** 30-May-2018; **Online first:** 14-Jun-2018

Copyright: © 2018 Vesna S. Antovska, Iskra Krstevska, Milka Trajanova, Jasmina Chelebieva, Irena Gosheva, Pance Zdravkovski, Slavica Kostadinova-Kunovska, Vesna Janevska. This is an open-access article distributed under the terms of the Creative Commons Attribution-NonCommercial 4.0 International License (CC BY-NC 4.0)

Funding: This research did not receive any financial support

Competing Interests: The authors have declared that no competing interests exist

BACKGROUND: Endometrial cancer is the third-ranked genital malignancy in women and includes 3% of cancer deaths. There is a 2.8% chance of a woman developing endometrial cancer during her lifetime. Low-grade endometrioid adenocarcinomas are often seen along with endometrial hyperplasia, but high-grade endometrioid adenocarcinomas have more solid sheets of less-differentiated tumour cells, which are no longer organised into glands, often associated with surrounded atrophic endometrium.

CASE REPORT: We present an unusual case of endometrial adenocarcinoma arising in adenomyoma in 74-year old woman presented with genital prolapse, without other clinical symptoms. Ultrasound evaluation revealed endometrium with 4 mm-thickness and atrophic ovaries. The cervical smear was normal. The patient underwent a total vaginal hysterectomy. The histopathology of the anterior uterine wall revealed an intramural adenomyoma of 4 mm in which some endometrial glands with malignant transformation of well-differentiated endometrioid adenocarcinoma without infiltration in surrounding myometrium and lymphovascular invasion were present. The endometrium lining the uterine cavity was predominantly atrophic, and only one focus of simplex and complex hyperplasia was found, with cell-atypia. According to AJCC/FIGO 2010, the tumour was classified: pTNM = pT1B pNX pMX G1 R0 L0 V0 NG1, Stage I. On dismissal, the near-future oncological consultation was recommended.

CONCLUSION: We would like to point out the rare occurrence of such type of malignancy and the importance of meticulous histopathology evaluation, even after reconstructive surgery for genital prolapse.

Introduction

Endometrial cancer is the third-ranked genital malignancy in women after cervical and ovarian cancer and accounted for 3% of all cancer deaths in women. Endometrial adenocarcinoma occurs mostly in the postmenopausal age. There is a 2.8% chance of a woman developing endometrial cancer during her lifetime.

The cancer cells in endometrioid adenocarcinoma grow in patterns evocative of normal endometrium, with new glands arising from columnar epithelium with some abnormal nuclei. Low-grade endometrioid adenocarcinomas are often seen along

with endometrial hyperplasia and most often do not invade the myometrium. Higher-grade endometrioid adenocarcinomas are characterised with less well-differentiated cells and have more solid sheets of tumour cells no longer organised into glands, and are associated with an atrophied endometrium. Smooth muscle tumors of the uterus consist of a broad family of tumors.

Leiomyomas are the most common gynaecological neoplasm. In this case, we had an unusual case of endometrial adenocarcinoma arising in adenomyoma. Leiomyoma combined with focal adenocarcinoma of the endometrium is the only rare published article found after the persistent search for the same.

Case report

We present an unusual case of endometrial adenocarcinoma arising in adenomyoma in a 74-year-old woman, presented with genital prolapse and no other clinical symptoms. The gynaecological examinations revealed the normal ultrasonographic appearance of the uterus, endometrial lining and ovaries. PAP smear showed normal findings. Her menopause occurred at the age of 49 years, and she never used hormonal therapy. She has no history of previous medical or surgical illnesses, nor family history of malignancies.

She was admitted to our gynaecological department for operative treatment of the genital prolapse. Pelvic examinations revealed subtotal uterine prolapsed (POPQ2) along with supravaginal cervical elongation and predominant cystocele. The ultrasound examination revealed the normal appearance of the uterus, endometrial lining and ovaries, appropriate for the patient's age. Results of urinalysis and blood chemistry tests were within normal range.

A total vaginal hysterectomy without salpingo-oophorectomy was performed. The operative material was sent for final histopathological evaluation.

The gross pathologic examination revealed an intramural leiomyoma of 4mm in diameter in the outer half of the frontal side of the uterus.

The histological analysis of this tumour revealed the morphology of adenomyoma in which there was a malignant transformation of endometrial glands in a well-differentiated endometrioid adenocarcinoma, without infiltration in the surrounding leiomyoma tissue (Figure 1, 6).

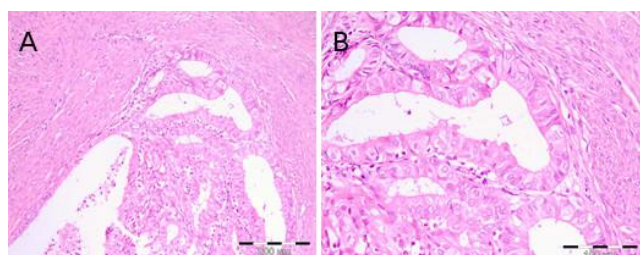


Figure 1: A) G1/NG1 endometrioid adenocarcinoma arising in adenomyoma (HE x100); B) The same lesion on higher magnification (He x200)

The tumour cells stained positive for cytokeratin and progesterone (Figure 2) and the mitotic index examined by the Ki67 immunostaining was about 10% (Figure 3). The lymphovascular invasion was not found.

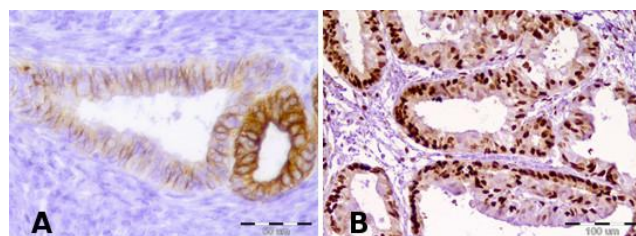


Figure 2: A) Immunostaining with CK7-positive for the epithelial component (x400); B) Immunostaining with Progesterone (Pr x200)

The histopathology also revealed that the endometrium lining uterine cavity was atrophic, except one focus where simplex and complex hyperplasia with cell atypia was found (Figure 4).

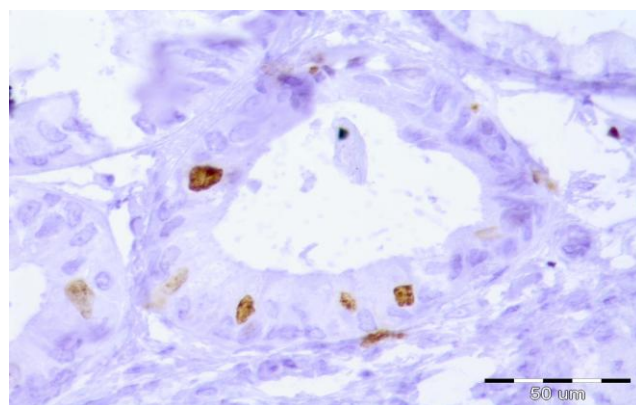


Figure 3: Immunostaining with Ki67 (x400)

Another few areas of adenomyosis in the uterine wall were found with simplex and complex hyperplasia with atypia in the endometrial epithelium.

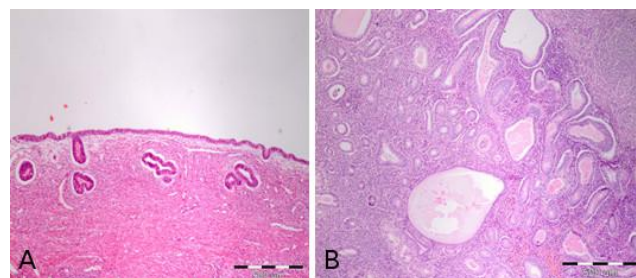


Figure 4: A) Atrophic endometrium (HE x40); B) Hyperplastic endometrium (He x100)

Histologically, the leiomyoma showed well-differentiated tumour cells with abundant eosinophilic cytoplasm, elongated nuclei, and indistinct cell borders. There were no mitotic figures, and the mitotic index examined by Ki67 immunostaining was low. In the silver staining, argyrophilic fibres separated individual cells from each other. The cells stained positive for smooth muscle actin (Figure 5).

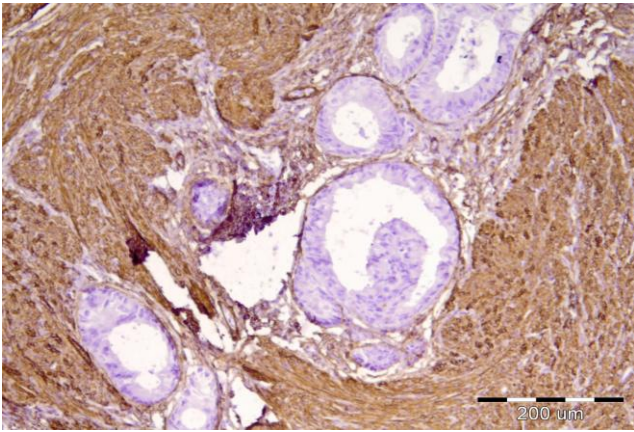


Figure 5: Immunostaining with SMA labelling smooth muscle cells (Smooth Muscle Actin x100)

According to AJCC/FIGO 2010, the tumour is classified: pTNM=pT1B pNX pMX G1 R0 L0 V0 NG1, Stage I.

A topical tumour was composed of epithelial and mesenchymal elements, and the former is completely contained into the latter.

Postoperative period was uneventful, and the patient was discharged 5 days after the operation in satisfactory condition. The patient was referred for oncological consultation.

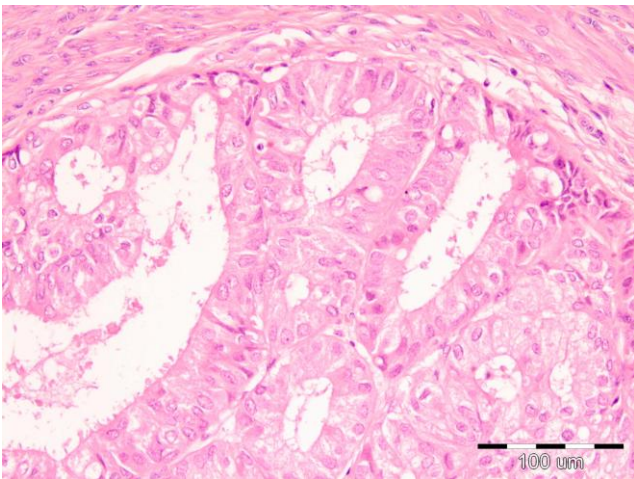


Figure 6: Well differentiated endometrioid adenocarcinoma showing a confluent glandular and cribriform pattern without intervening stroma (HE 10x20)

Discussion

Both, the endometrial adenocarcinoma and adenomyomas are common pathological findings that can develop in the uterus. Adenocarcinoma arising from adenomyoma is a rare entity. There are some cases described with endometrial adenocarcinoma

arising from adenomyosis, as well as few reports of adenocarcinoma developing in adenomyotic areas without endometrial involvement, similar to the case that we present. Kurotaki et al., [1] reported a case of adenocarcinoma of the endometrium extending into the leiomyoma of the uterus in a rabbit. Qury et al., [2] reported for Endometrioid carcinoma infiltrating atypical leiomyoma and pointed the necessity of ruling out carcinosarcoma as it has an ominous prognosis. Toshiki et al., [3] reported a similar case of adenocarcinoma arising in adenomyosis without endometrial involvement, but there were already lymph node metastasis and serous uterine involvement by the time of the diagnosis. They made an immunohistochemical analysis of the growth factors, including estrogen receptor (ER), progesterone receptor (PR), p53, bcl-2 protein and Ki-67 antigen, and found no expression of ER, PR or bcl-2 in the carcinoma cells. However, there was a focal expression of p53 and prominent expression of Ki-67. These results suggest that some biological factors, including oncogenes and tumour suppressor genes, may play a role in the carcinogenesis of endometrial carcinoma arising from adenomyosis without surface endometrial changes. In our case, the adenocarcinoma arose from an adenomyoma focus situated in the outer half of the anterior uterine wall, endometrium in the most of its parts was atrophic and only in one focus simplex, and complex hyperplasia with cell-atypia was found.

The histological features of this tumour in our case may be misdiagnosed as a composite mixed Müllerian tumour, which is characterized by an admixture of epithelial and mesenchymal elements and could be categorized as adenofibroma, adenosarcoma, carcinosarcoma or carcinosarcoma, depending on whether epithelial and mesenchymal components are benign or malignant. Malignant mixed Müllerian tumours of the uterus are composite tumours and are believed by many, to behave like metaplastic carcinomas. On the other hand, collision tumours are defined by co-existence of two tumours in the same or adjacent organs which are topographically and histologically distinct with minimal or no histological admixture. Collision tumor should be viewed as the occurrence of multiple synchronous tumours in the same organ or two adjacent organs. The components are separated from each other by normal stroma with little or no histological admixture. On the other hand, the composite tumors are characterized by the individual components, which are intimately admixed with each other, and it is not possible to separate them topographically. The two divergent lineages in composite tumors originate from the same neoplastic clonal proliferation. In contrast, the prognosis and management of collision tumors is dictated by the histology of its individual components [4]. Collision tumors of the uterus are rare with only a few such cases reported till date [5]. Most of these are composed of adenocarcinoma (endometrioid or

papillary serous) colliding with a sarcoma (leiomyosarcoma or endometrial stromal sarcoma) [6].

Based on the distinct topographical location and limited areas of tumour admixture of the two tumours, a diagnosis of collision tumour of a uterus comprising of endometrial adenocarcinoma and leiomyoma in our case was made. This case may be misdiagnosed as a carcinofibroma due to an admixture of adenocarcinoma and benign mesenchymal tumour, a leiomyoma. The leiomyoma-cells were well-differentiated and were not relevant to the stromal cells. Collision tumours have been described in various tissues, but they are rare in the female genital tract. Collision is generally used for the tumor where two kinds of malignant tumors collided. In our case, the tumor was composed of two distinct and separated parts and was considered to be a collision of two neoplasms rather than a malignant transformation of the benign mixed mesenchymal tumor.

Nadeem et al., [7] reported a case of a 60-year-old lady who presented with complaints of post-menopausal bleeding. A cervical biopsy was performed which showed a non-keratinizing squamous cell carcinoma of the cervix. In 1986, Woodruff et al., [8] reported two more cases of adenocarcinoma arising in adenomyosis without surface endometrial changes. Both patients were postmenopausal women who underwent a total hysterectomy with bilateral adnexectomy because of persistent atypical cytology, despite negative findings on biopsies obtained by curettage. The accurate diagnosis was made only after the histological examination of the surgical specimens. In our case was the same situation. None suspicion for endometrial carcinoma before the operation was present because of the absence of any clinical symptoms, such as vaginal discharge or abnormal uterine bleeding, as well as ultrasound findings of endometrial thickness >4mm.

In conclusion, collision tumours compound of endometrial adenocarcinoma arising in adenomyosis or leiomyoma are very rare events, and they generally represent pathologic findings of a surgical specimen. Diagnosis is often delayed because of the absence of a lesion in eutopic endometrium and is often made usually when the tumour has grown to involve the endometrium, causing abnormal uterine bleeding or

has spread outside of the uterus. Reporting this case, we would like to point out the rare occurrence of such type of malignancy and the importance of strict protocols for histopathologic evaluation, even after reconstructive surgery for genital prolapse.

However, further researches should be made to clarify the pathogenesis of these tumours, namely the genetic abnormalities encountered in those neoplastic areas. Nevertheless, this clinical entity should be kept in mind, especially when these conditions persist after the menopause.

References

1. Kurotaki T, Kokoshima H, Kitamori F, Kitamori T, Tsuchitani M. A case of adenocarcinoma of the endometrium extending into the leiomyoma of the uterus in a rabbit. *J Vet Med Sci.* 2007; 69(9):981-4. <https://doi.org/10.1292/jvms.69.981> PMID:17917388
2. Mahapatra QS, Ajay M, Kavita S. Endometrioid carcinoma infiltrating atypical leiomyoma: A mimicker of malignant mixed Mullerian tumor. *Indian Journal of pathology and Microbiology.* 2014; 57(2): 317-319. <https://doi.org/10.4103/0377-4929.134729> PMID:24943777
3. Sasaki T, et al. Endometrioid adenocarcinoma arising from adenomyosis: report and immunohistochemical analysis of an unusual case. *Pathol Int.* 2001; 51:308-13. <https://doi.org/10.1046/j.1440-1827.2001.01200.x>
4. McCluggage WG. Malignant biphasic uterine tumours: carcinosarcomas or metaplastic carcinomas? *J Clin Pathol.* 2002; 55(5):321-25. <https://doi.org/10.1136/jcp.55.5.321>
5. Jang K-S, Lee W-M, Kim Y-J, Cho S-H. Collision of three histologically distinct endometrial cancers of the uterus. *J Korean Med Sci.* 2012; 27:89-92. <https://doi.org/10.3346/jkms.2012.27.1.89> PMID:22219620 PMID:PMC3247781
6. Lam KY, Khoo US, Cheung A. Collision of endometrioid carcinoma and stromal sarcoma of the uterus: a report of two cases. *Int J Gynecol Pathol.* 1999; 18:77-81. <https://doi.org/10.1097/00004347-199901000-00012> PMID:9891246
7. Nadeem T, Bindiya G, Abhishek P, Shalini R, Neerja G. A Rare Collision Tumour of Uterus- Squamous Cell Carcinoma and Endometrial Stromal Sarcoma. *J Clin Diagn Res.* 2017; 11(2): ED20-ED22.
8. Woodruff JD, Erozan YS, Genadry R. Adenocarcinoma arising in adenomyosis detected by atypical cytology. *Obstet Gynecol.* 1986; 67:145-8. PMID:3940328