

ID Design Press, Skopje, Republic of Macedonia  
 Open Access Macedonian Journal of Medical Sciences. 2018 Apr 15; 6(4):663-665.  
<https://doi.org/10.3889/oamjms.2018.191>  
 eISSN: 1857-9655  
**Case Report**



# Pretibial Located Stewart-Treves Syndrome: Uncommon Presentation in a Bulgarian Patient!

Georgi Tchernev<sup>1,2\*</sup>, Irina Yungareva<sup>3</sup>, Hristo Mangarov<sup>4</sup>, Konstantin Stavrov<sup>5</sup>, Ilija Lozev<sup>6</sup>, Ivanka Temelkova<sup>7</sup>, Svetoslav Chernin<sup>8</sup>, Ivan Pidakev<sup>9</sup>, Michael Tronnier<sup>10</sup>

<sup>1</sup>Medical Institute of Ministry of Interior (MVR), Department of Dermatology, Venereology and Dermatologic Surgery, General Skobelev Nr 79, Sofia 1606, Bulgaria; <sup>2</sup>Onkoderma - Polyclinic for Dermatology and Dermatologic Surgery, General Skobelev 26, Sofia 1407, Bulgaria; <sup>3</sup>Medical Institute of the Ministry of Interior, Department of Dermatology and Venereology, Skobelev bul. 79, Sofia 1606, Bulgaria; <sup>4</sup>Medical Institute of the Ministry of Interior, Department of Dermatology, Venereology and Dermatologic Surgery, Lozenets Plachkovica number 5, Sofia 1164, Bulgaria; <sup>5</sup>Medical Institute of the Ministry of Interior, Dermatology and Dermatologic Surgery, Sofia, Bulgaria; <sup>6</sup>Medical Institute of the Ministry of Interior, Surgery, Sofia, Bulgaria; <sup>7</sup>Medical Institute of the Ministry of Interior, Dermatology, Venereology and Dermatologic Surgery Sofia, Sofia, Bulgaria; <sup>8</sup>Medical Institute of the Ministry of Interior, Common, vascular and abdominal Surgery Stoletov #2, Sofia, Sofia 1612, Bulgaria; <sup>9</sup>Medical Institute of Ministry of Interior, Department of Common, Vascular and Abdominal Surgery, General Skobelev 79, 1606 Sofia, Bulgaria; <sup>10</sup>Helios Klinikum GMBH - Dermatology, Venereology and Allergology, Hildesheim, Germany

## Abstract

**Citation:** Tchernev G, Yungareva I, Mangarov H, Stavrov K, Lozev I, Temelkova I, Chernin S, Pidakev I, Tronnier M. Pretibial Located Stewart-Treves Syndrome: Uncommon Presentation in a Bulgarian Patient!. Open Access Maced J Med Sci. 2018 Apr 15; 6(4):663-665. <https://doi.org/10.3889/oamjms.2018.191>

**Keywords:** (HHV-8); Angiosarcoma; Epithelioid variant; Stewart Treves syndrome; Surgery; Amputation

**\*Correspondence:** Georgi Tchernev, Medical Institute of Ministry of Interior (MVR-Sofia), Department of Dermatology, Venereology and Dermatologic Surgery General Skobelev Nr 79, Sofia 1606 Bulgaria; Onkoderma - Polyclinic for Dermatology and Dermatologic Surgery General Skobelev 26, Sofia 1606, Bulgaria. E-mail: [georgi\\_tchernev@yahoo.de](mailto:georgi_tchernev@yahoo.de)

**Received:** 06-Mar-2018; **Revised:** 02-Apr-2018; **Accepted:** 03-Apr-2018; **Online first:** 14-Apr-2018

**Copyright:** © 2018 Georgi Tchernev, Irina Yungareva, Hristo Mangarov, Konstantin Stavrov, Ilija Lozev, Ivanka Temelkova, Svetoslav Chernin, Ivan Pidakev, Michael Tronnier. This is an open-access article distributed under the terms of the Creative Commons Attribution-NonCommercial 4.0 International License (CC BY-NC 4.0)

**Funding:** This research did not receive any financial support

**Competing Interests:** The authors have declared that no competing interests exist

**BACKGROUND:** The Stewart-Treves syndrome with localisation in the region of the lower extremities is not something unusual as clinical pathology, but the clinical diagnostics is rather difficult, and it can be further complicated maximally because of the similar locoregional findings in patients with other cutaneous malignancies.

**CASE REPORT:** Presented is a rare form of an epithelioid variant of the Stewart Treves syndrome in a woman, aged 81, localised in the region of the lower leg and significantly advanced only for 2 months. The diagnosis was confirmed histologically and immunohistochemically. Amputation of the affected extremity was planned. Discussed are important etiopathogenetic aspects regarding the approach in patients with lymphedema and possibility for development of the Stewart Treves syndrome.

**CONCLUSION:** Analyzing the evidence from the literature worldwide, we concluded that perhaps the only reliable (to some extent) therapeutic option in patients with Stewart Treves Syndrome is 1) the early diagnostics and 2) the following inevitable radical excision or amputation with the maximal field of surgical security in the proximal direction.

## Introduction

Sarcomas are connective tissue tumours, comprising approximately 1% of all malignant tumours [1]. Stewart Treves syndrome is a skin variant of angiosarcoma which has developed based on chronic lymphedema [1].

The disease affects women predominantly, with a higher incidence in the fifth and seventh decades as in the patient described by us [1].

Interestingly, the syndrome could also develop by congenital lymphedema, which implies the need for a serious reflection on the "active" or more aggressive approach in affected groups of patients (at an early age) [2].

## Case Report

An 81-year old female was admitted in the Dermatology and Dermatological Surgery department because of pain, edema and burning sensation of 2 months duration in the left lower limb (Fig. 1a). She is under treatment for hypertension and cardiac ischemia and there is a past history of hysterectomy due to multiple myomatous nodules (Fig. 1a).

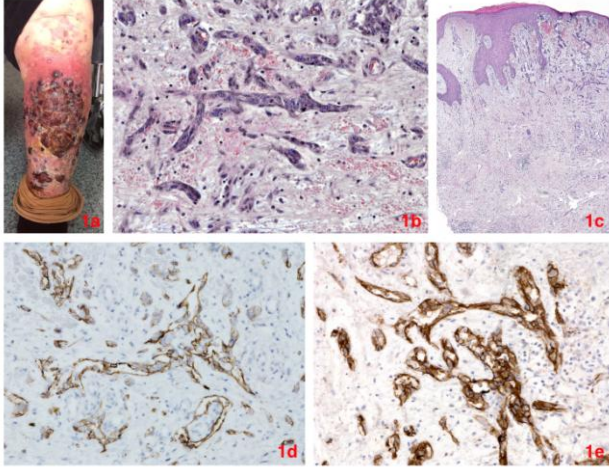


Figure 1: 1a) multiple solitary nodules, 2-3.8 cm in diameter and tendency for confluence and endophyte growth resulting in the formation of a bigger endophyte tumour growth and forming a single tumour lesion with dimensions of about 22 to 16 cm. Perilesional area of erythema around the tumours. Presence of multiple satellite lesions in all directions around the tumour plaque; 1b) vessels with irregular branching consisting of large atypical endothelial cells. Mitotic figures and extravascular red blood cells, H&E x200; 1c) irregular acanthosis. In the upper dermis increased number of vessels. Extravasated red blood cells and oedema. H&E x25; 1d) atypical vessels expressing D2-40. Promontory sign, IHC x200; 1e) 3b CD31 in the atypical cells, IHC x200

General examination revealed marked pallor of the mucous membranes and skin, no other findings could detect. On the other hand, local examination of the lower limbs revealed. Bilateral progressive lymphedema on the lower legs, more pronounced on the left. Edematous left lower leg and foot. Pretibially located tumour conglomerates with dimensions 22/11 cm and with black to dark blue colour, partially confluent with one another. Presence of multiple satellite tumour lesions on an erythemic base near the main tumour formation (Fig. 1a). HIV-1 P24 antigen and HIV-1, 2 antibodies: negative. TPHA test negative, Hb S-Ag, Anti HCV autoantibodies: negative. From the paraclinical and microbiological tests were established: the microbiological smear from lesional smear showed significant bacterial growth of *Acinetobacter* Spp., *E faecalis*. LDH: 269 IU/l, CKMB: 30 IU/l, Granulocytes 72.5%, blood sugar 6.4 mmol/l, sediment urine-massively leukocytes and bacteria. Urine culture: significant concentration of *Klebsiella pneumoniae*. X-ray of the lung is with evidence of thickening of the pleura with unclear genesis, on the

left, axillary. X-ray of left lower leg and ankle joint: osteoporosis of the visible bones, inhomogeneous structures with areas of thickening and increase in the transparency of the soft tissues of the examined extremity. Doppler of arterial and venous vessels was without evidence of thrombosis or chronic arterial insufficiency as a result of compression by the tumour masses. Histopathological assessment of a biopsy of the lesional tissue: large lobes, dermally based, a malignant vessel-forming tumour with prevailing epithelioid, pleomorphic cells with prominent nucleoli (Figures 1b and 1c). Immunohistochemistry: CD34 positive expression in the malignant population, CD 31 positive (Fig. 1e), D2-40 positive (Fig. 1d), HHV8 negative, S-100 negative, Anti CKA-1, -3 negative. Based on the anamnestic evidence of hysterectomy in the past, the histological and immunohistochemical assessments, the patient was diagnosed with an epithelioid variant of angiosarcoma with lymphedema or Stewart Treves syndrome. Amputation of the lower leg was also planned at a later stage. Due to the patient's refusal to undergo surgical treatment, she was referred to the Oncology for planned chemotherapy and/or eventually radiotherapy.

## Discussion

The pathogenesis concerning the origin of cells in angio or lymphangiosarcoma is controversial [3] [4]. Lymphangiosarcoma is a controversial term because a tumour itself originates from the vessels and hence, according to some authors, the definition hemangiosarcoma should be more accurate [1] [2]. Other studies have suggested that a tumour expresses markers characteristic of both lymphatic and vascular capillaries [3] [4].

Stewart-Treves Syndrome is characterised by the presence of lymphangiosarcoma on limb extremities [1] [2]. Rare, it occurs in 0.5% of patients who have undergone radical mastectomy with axillary node dissection [1].

The main cause of the disease seems to be the chronic lymphedema with the subsequent endothelial and lymphatic differentiation, with no direct relationship to other types of cancer [4]. The main etiopathogenesis is chronic lymphedema, and it is believed to occur a neoplastic proliferation with blood and lymphatic endothelial differentiation, but it's not possible to determine definitely which predominates [1] [3].

The extent to which a lymphostasis is capable of leading to a reduced local immunity, followed by degeneration of the cell matrix, and hence to the uncontrollable production of growth/angiogenic factors, is unclear. But at least the hypothesis seems reasonable, though it is speculative. The chronic

lymphostasis is likely to lead to cellular changes and possibly to an early onset of malignant transformation [5] [6]. It is because of this fact that many authors advise that the radiotherapy in the early stages of the illness should be rather avoided hence it can 1) potentiate the DNA changes in the cells and 2) even worsen the lymph flow. These two factors could further trigger the onset of the Stewart Treves syndrome [5] [6]. No racial preponderance has been observed in this syndrome [7]. It has not been shown to be more prevalent in patients with AIDS or any other immunodeficiency disorders, as compared with Kaposi's sarcoma (KS) [7].

Interestingly, some authors postulate that mutations in the DNA repair genes BRCA1 and BRCA2 predispose to angiosarcomas after treatment for breast cancer [8]. Three phases in the development of STS have been reported in the literature: (1) prolonged lymphedema, (2) angiomatosis, and subsequently (3) angiosarcoma [8]. Prolonged lymphedema (lymphostasis) is observed in KS as well as angiosarcoma, resulting in localised immunosuppression and vascular oncogenesis in the presence of human herpesvirus 8 (HHV-8) infections and immunosuppression [9].

Interestingly, lymphedema has also been reported in other cutaneous malignancies including cutaneous melanoma, basal cell carcinoma, squamous cell carcinoma, Merkel cell carcinoma, and cutaneous lymphomas [9] [10].

The most important differential diagnosis of Stewart Treves Syndrome is Kaposi sarcoma (KS). (KS) Differs from (STS), because it does not require the presence of lymphedema for its development [7]. Immunohistochemical testing for the presence of HHV-8 is the primary way to distinguish STS from KS (7). KS is associated with this virus, while STS is not [8].

In conclusion, unclear as a whole is the contribution of the different histological, immunohistological and molecular-biological characteristics (as markers) in this tumour regarding its pathogenesis and its course. This is what makes the rapid diagnosis as well as the choice of treatment regimen rather problematic than standard and easy to apply.

Perhaps the only method to guarantee better survival or a chance for survival of the affected patients is radical surgery or amputation of the affected limb with the maximal field of surgical security in the proximal direction. The aim is to avoid creating new lymphedema, which will prove to be a beneficial basis for reactivation or new Stewart Treves

Syndrome (STS).

Chemotherapy is reserved for patients with unresectable disease or refusal of amputation (as in our patient). Radiotherapy could be used as adjuvant therapy in selected advanced cases with Stewart Treves syndrome [7]. The general prognosis of patients with Stewart-Treves syndrome is poor. Local recurrence rate is relatively high, with frequent need for amputation of the limbs [7].

## References

1. Pereira ES, Moraes ET, Siqueira DM, Santos MA. Stewart Treves Syndrome. *An Bras Dermatol*. 2015; 90(3 Suppl 1):229-31. <https://doi.org/10.1590/abd1806-4841.20153685> PMID:26312725 PMCid:PMC4540559
2. Sharma A, Schwartz RA. Stewart Treves syndrome: pathogenesis and management. *J Am Acad Dermatol*. 2012; 67:1342-1348. <https://doi.org/10.1016/j.jaad.2012.04.028> PMID:22682884
3. Stanczyk M, Gewartowska M, Swierkowski M, Grala B, Maruszynski M. Stewart Treves syndrome angiosarcoma express phenotypes of both blood and lymphatic capillaries. *Chin Med J (Engl)*. 2013; 126:231-237.
4. Aguiar Bujanda D, Camacho Galán R, Bastida I-area J, Aguiar Morales J, Conde Martel A, Rivero Suárez P, et al. Angiosarcoma of the abdominal wall after dermolipectomy in a morbidly obese man. A rare form of presentation of Stewart Treves syndrome. *Eur J Dermatol*. 2006; 16:290-292. PMID:16709497
5. Iga N, Endo Y, Fujisawa A, Matsumura Y, Kabashima K, Tanioka M, et al. Two cases of cutaneous angiosarcoma developed after breast cancer surgery. *Case Rep Dermatol*. 2012; 4:247-249. <https://doi.org/10.1159/000345559> PMID:23275768 PMCid:PMC3531937
6. Kunkel T, Mylonas I, Mayr D, Friese K, Sommer HL. Recurrence of secondary in a patient with postirradiated breast for breast cancer. *Arch Gynecol Obstet*. 2008; 278:497-501. <https://doi.org/10.1007/s00404-008-0605-8> PMID:18305948
7. Berebichez-Fridman R, Deutsch YE, Joyal TM, Olvera PM, Benedetto PW, Rosenberg AE, Kett DH. Stewart-Treves Syndrome: A Case Report and Review of the Literature. *Case Rep Oncol*. 2016; 9(1): 205-211. <https://doi.org/10.1159/000445427> PMID:27099606 PMCid:PMC4836142
8. Young RJ, Brown JN, Reed MW, Hughes D, Woll PJ. Angiosarcoma. *Lancet Oncol*. 2010; 11:983-991. [https://doi.org/10.1016/S1470-2045\(10\)70023-1](https://doi.org/10.1016/S1470-2045(10)70023-1)
9. Tabareau F, de Muret A, Miquelstorena E, Decouvelaere AV, de Pinieux G. Cutaneous epithelioid clear cells angiosarcoma in a young woman with congenital lymphedema. *Case Rep Pathol*. 2013; 1:1-6. <https://doi.org/10.1155/2013/931973> PMID:24078891 PMCid:PMC3776547
10. Shon W, Ida CM, Boland-Froemming JM, Rose PS, Folpe A. Cutaneous angiosarcoma arising in massive localized lymphedema of the morbidly obese: a report of five cases and review of the literature. *J Cutan Pathol*. 2011; 38:560-564. <https://doi.org/10.1111/j.1600-0560.2011.01703.x> PMID:21518378