

Ameliorative Effect of Silymarin on Scopolamine-induced Dementia in Rats

Salma A. El-Marasy^{1*}, Reham M. Abd-Elsalam², Omar A. Ahmed-Farid³

¹Pharmacology Department, National Research Centre, Giza, Egypt; ²Pathology Department, Faculty of Veterinary Medicine, Giza, Cairo University, Cairo, Egypt; ³Physiology Department, National Organization for Drug Control and Research, Giza, Egypt

Abstract

Citation: El-Marasy SA, Abd-Elsalam RM, Ahmed-farid OA. Ameliorative Effect of Silymarin on Scopolamine-induced Dementia in Rats. Open Access Maced J Med Sci. <https://doi.org/10.3889/oamjms.2018.257>

Keywords: Silymarin; Scopolamine; Object recognition test; Dementia; Donepezil; Rats

***Correspondence:** Salma A. El-Marasy, Pharmacology Department, National Research Centre, Giza, Egypt. E-mail: salma_el_marasy@hotmail.com

Received: 12-Mar-2018; **Revised:** 23-May-2018; **Accepted:** 25-May-2018; **Online first:** 17-Jul-2018

Copyright: © 2018 Salma A. El-Marasy, Reham M. Abd-Elsalam, Omar A. Ahmed-Farid. This is an open-access article distributed under the terms of the Creative Commons Attribution-NonCommercial 4.0 International License (CC BY-NC 4.0)

Funding: This research did not receive any financial support

Competing Interests: The authors have declared that no competing interests exist

AIM: This study aims to elucidate the possible ameliorative effect of silymarin on scopolamine-induced dementia using the object recognition test (ORT) in rats.

METHODS: The study was extended to demonstrate the role of cholinergic activity, oxidative stress, neuroinflammation, brain neurotransmitters and histopathological changes in the anti-amnesic effect of silymarin in demented rats. Wistar rats were pre-treated with silymarin (200, 400, 800 mg/kg) or donepezil (10 mg/kg) orally for 14 consecutive days. Dementia was induced after the last drug administration by a single intraperitoneal dose of scopolamine (16 mg/kg). Then behavioural, biochemical, histopathological, and immunohistochemical analyses were then performed.

RESULTS: Rats pre-treated with silymarin counteracted scopolamine-induced non-spatial working memory impairment in the ORT and decreased acetylcholinesterase (AChE) activity, reduced malondialdehyde (MDA), elevated reduced glutathione (GSH), restored gamma-aminobutyric acid (GABA) and dopamine (DA) contents in the cortical and hippocampal brain homogenates. Silymarin reversed scopolamine-induced histopathological changes. Immunohistochemical analysis showed that silymarin mitigated protein expression of the glial fibrillary acidic protein (GFAP) and nuclear factor kappa-B (NF- κ B) in the brain cortex and hippocampus. All these effects of silymarin were similar to that of the standard anti-amnesic drug, donepezil.

CONCLUSION: This study reveals that the ameliorative effect of silymarin on scopolamine-induced dementia in rats using the ORT maybe in part mediated by, enhancement of cholinergic activity, anti-oxidant and anti-inflammatory activities as well as mitigation in brain neurotransmitters and histopathological changes.

Introduction

Dementia is characterised by impairments in memory and other cognitive abilities [1]. Dementia of Alzheimer's type (DAT) is the most common type of dementia. Alzheimer's disease (AD) is characterised by the accumulation of amyloid plaques, hyperphosphorylation of tau protein, oxidative stress, neuroinflammation leading to neuronal death [2]. Deficiency in cholinergic neurotransmission in the cerebral cortex and hippocampus accounts for dementia in AD patients [3].

Object recognition test (ORT), measures non-spatial working memory in rodents, which is severely

impaired in patients suffering from DAT [4] [5]. The test depends on the spontaneous exploratory behaviour of rodents, exposed to the novel environment. In comparison to other cognitive parameters, ORT does not involve reinforcement/response interaction and therefore resembles procedures used in humans and have a predictive validity [6] [7].

Scopolamine, a muscarinic receptor blocker that disrupts cholinergic neurotransmission leading to memory impairment associated with DAT [8]. Scopolamine-induced dementia is a widely used animal model for investigating cognitive enhancing drugs [9] [10].

Acetylcholinesterase inhibitors (AChEIs) are

the most common drugs used for DAT. However, these drugs may cause peripheral cholinergic side effects that may restrict their use [11]. Therefore, efforts have been directed towards the use of alternative anti-amnestic therapies with lower side effects [12].

Silymarin is a flavonoid isolated from the seeds and fruits of Milk Thistle plant. Therapeutically, silymarin is used for the treatment of liver diseases [13] [14]. It possess anti-cancer [15] [16] anti-apoptotic effects [17], in addition to its renoprotective [18] and cardioprotective [19] activities.

Silymarin is a potent anti-oxidant agent, being able to cross the blood-brain barrier and exerts a neuroprotective effect in various neurodegenerative disorders like Parkinson's disease, stroke, and ageing [20] [21] [22]. Although it has been demonstrated that silymarin suppresses the accumulation of amyloid plaques in an animal model of AD [23], according to the author's knowledge its possible memory-enhancing the effect on scopolamine-induced dementia has not been investigated.

Therefore, the present study aims to elucidate the possible ameliorative effect of silymarin on scopolamine-induced dementia using the ORT. The study was extended to demonstrate the role of cholinergic activity, oxidative stress, neuroinflammation, neurotransmitters and histopathological changes in the anti-amnestic effect of silymarin in demented rats. Donepezil, an AChEI, was used as an anti-amnestic standard drug for comparison.

Material and Methods

Animals

Male albino Wistar rats weighing 120–150 g were used throughout the experiment. They were obtained from the animal house colony of the National Research Centre (Dokki, Cairo, Egypt) and were housed for at least one week in the laboratory room before testing under a 12 h alternating light/dark cycle. Animals were fed standard laboratory pellets with water ad libitum. All animal procedures were performed by the Ethics Committee of the National Research Centre, Egypt (registration number 17/004) which is by the Guide for the Care and Use of Laboratory Animals of the National Institutes of Health and complied with the guidelines from the Canadian Council on Animal Care.

Drugs and chemicals

Scopolamine hydrobromide was purchased from Sigma–Aldrich (MO, USA) and was dissolved in

saline (0.9% NaCl). Donepezil hydrochloride was purchased from Pfizer (Giza, Egypt) and was freshly prepared in 1% tween 80 in water. Silymarin was supplied by CID pharmaceutical company (Giza, Egypt) and was freshly prepared in 1% tween 80 in water.

Treatments

Rats were randomly allocated into 6 groups (8 rats/group in the object recognition test) as follows: group I received saline (0.9% NaCl solution) and served as normal while group II received scopolamine (16 mg/kg, i.p.) [24] and served as control. Both groups received saline for 14 days. Groups III–V rats orally received Silymarin (200, 400, 800 mg/kg/day), respectively; Group VI rats orally received Donepezil (10 mg/kg/day) for 14 consecutive days. Scopolamine was administered as a single dose 30 min after the last administration in groups II–VI.

The selection of the doses of silymarin was based on the previously published data of Galhardi, Mesquita [25]. The dose of donepezil was selected according to the previously published data of Schreiber, Vivian [26].

Behavioral test

Object recognition test

The test apparatus was designed as described by Ennaceur and Delacour [27]. Three days before testing, each rat was allowed to explore the apparatus for 2 min, while on the testing day, 30 min following scopolamine injection, a session of two trials, 2-min each was allowed. In the "sample" trial (T1), two identical objects were placed in two opposite corners of the apparatus. A rat was placed in the apparatus and was left to explore these two identical objects. After T1, the rat was placed back in its home cage, and an inter-trial interval of 1h was given. Subsequently, the "choice" trial (T2) was performed. In T2, a new object (N) replaced one of the objects that were presented in T1; then rats have exposed again to two different objects: the familiar (F) and the new one (N).

Exploration was defined as follows: directing the nose toward the object at a distance of no more than 2 cm and/or touching the object with the nose.

From this measure, a series of variables were then calculated: the total time spent in exploring the two identical objects in T1, and that spent in exploring the two different objects, F and N in T2. The discrimination between F and N in T2 was measured by comparing the time spent in exploring the F with that spent in exploring the N. DI is the discrimination index and represents the difference in exploration time expressed as a proportion of the total time spent exploring the two objects in T2. DI was then

calculated; $DI = N-F/N+F$.

Brain homogenate preparation for biochemical analysis

Rats were euthanised by decapitation following the ORT. The whole brain was carefully excised, cortical and hippocampal brain tissues were isolated, immediately weighed to avoid any effects from drying, and stored at -80°C .

Cortical and hippocampal brain tissues were homogenised (MPW-120; Medical Instruments) in 10% (w/v) ice-cold phosphate buffer. Then, the homogenate was centrifuged using a cooling centrifuge (2k15; Sigma/Laborzentrifugen) at 4000 rpm for 5 min, and the resulting supernatant was used for determining the brain contents of Acetylcholinesterase activity (AChE), malondialdehyde (MDA), and reduced glutathione (GSH) in addition to brain neurotransmitters namely norepinephrine (NE), dopamine (DA), serotonin (5-HT), and gamma-aminobutyric acid (GABA) were also assessed.

Determination of Acetylcholinesterase (AChE) activity

Acetylcholinesterase activity was determined in cortex and hippocampus according to the method described [28] [29], the developed colour was read spectrophotometrically immediately at 412 nm, and the AChE activity was determined in μM per SH group (μMSH) from a standard curve.

Determination of lipid peroxidation content

Lipid peroxidation was assayed by measuring cortical and hippocampal MDA content according to the method described before [30]. The supernatant was read spectrophotometrically at 532 nm, and the MDA content is expressed in nanomoles of MDA per milligram tissue.

Determination of reduced glutathione (GSH) content

The cortical and hippocampal GSH contents were determined according to the method described before by Ellman [31]. Calculation of GSH was based on a standard glutathione curve and is expressed in micromoles of GSH per gram tissue.

Determination of norepinephrine (NE), dopamine (DA), and serotonin (5-HT) contents

Brain monoamines, namely, NE, DA, and 5-HT, were estimated using HPLC (Agilent 1200 series;

Agilent Technologies, California, USA) as described previously [32]. Cortical and hippocampal contents of monoamines are expressed in micrograms of monoamine per gram tissue, and were calculated as follows:

$$\text{Monoamine content } (\mu\text{g/g tissue}) = \text{AT/AS} \times \text{CS} \times \text{dilution factor}$$

Where: AT = area under the curve for the sample, AS = area under the curve for the standard, CS = concentration of the standard ($\mu\text{g/mL}$), and the dilution factor = 10.

Determination of Gamma-aminobutyric acid (GABA) content

Cortical and hippocampal GABA content ($\mu\text{mol/g}$ tissue) was estimated using HPLC (Agilent 1200 series; Agilent Technologies, California, USA) according to the precolumn phenylisothiocyanate derivatisation technique described by Heinrikson and Meredith [33]. Cortical and hippocampal contents of GABA are expressed in micrograms per gram tissue.

Histopathological examination

The brain tissues were collected from different groups and fixed in 10% neutral buffered formalin then processed for obtaining 4 μm paraffin-embedded sections. The sections were stained with hematoxylin, and eosin stain then examined under the microscope [34].

Immunohistochemistry analysis of GFAP and NF-KB p65

The immunohistochemistry was performed according to methods described before [35]. Brain tissue sections were deparaffinized in xylene and rehydrated in graded alcohol. Hydrogen Peroxide Block (Thermo scientific, USA) was added to block the endogenous peroxidase activity. Antigen retrieval was done by pretreated tissue sections with 10 mM citrate in a microwave oven for 10 minutes. Sections were incubated for 2 hours with one of the following primary antibodies: rabbit anti-GFAP polyclonal antibody (ab7260; Abcam, Cambridge, UK) at dilution 1:2000 and rabbit anti-NF-KB P65 polyclonal antibody (ab16502; Abcam, Cambridge, UK) diluted 1 $\mu\text{g/ml}$. The sections were rinsed with PBS then incubated with Goat anti-rabbit IgG H&L (HRP) (ab205718; Abcam, Cambridge, UK) for 10 min. The sections were rinsed again with PBS. Finally, sections were incubated 3, 3'-diaminobenzidine tetrahydrochloride (DAB, Sigma). The slides were counterstained with haematoxylin then mounted. Primary antibodies were replaced by PBS for negative controls.

Evaluation of GFAP and NF- κ B p65 immunostaining

The quantitative immunoreactivity of GFAP and NF- κ B was evaluated in the brain cortex and hippocampus region. In each group, five brain sections were examined. The GFAP immunoreactivity was analysed in 10 microscopical fields per each section under high-power microscopical field (x 400) and represented as a percentage of the positively stained area. NF- κ B positive cells and total cell number were counted in 10 microscopical fields per each section under high-power microscopical field (x 400), and the percentage of positively stained cells (%) was calculated. The image analysis was performed by Leica Qwin 500 Image Analyzer (Leica, Cambridge, England).

Statistical Analysis

Data concerning the ORT, biochemical analysis are presented as the mean \pm SEM for 8 rats per group in the behavioural tests and 6 rats per group in the biochemical tests. Comparisons between more than 2 groups in the ORT and biochemical were carried out using one-way analysis of variance (ANOVA) followed by Tukey's multiple comparisons test, except for the comparison of total exploration time in T1 and T2 in the ORT which was carried out using 2-way ANOVA followed by Tukey's multiple comparisons test and when comparing the exploration times of the F and N objects in T2, Student's t-test was used. Immunohistochemical analysis was carried out by one-way analysis of variance (ANOVA) followed by Newman Keuls multiple comparison tests. All analyses utilised GraphPad Prism 6.0 statistical package for Windows (GraphPad, San Diego, Calif.). Statistical significance was set at $P < 0.05$.

Results

Figure 1a reveals that dementia induced by a single i.p. dose of scopolamine (16 mg/kg) 30 min before starting T1 in the ORT did not significantly affect the total exploration time in T1 and T2. Oral administration of silymarin (200, 400, 800 mg/kg), and donepezil (10 mg/kg) for 14 consecutive days, before scopolamine, did not also show any difference in the total exploration time in T1 and T2. During T2, Scopolamine-induced demented rats did not reveal any significant difference in the exploration time of N as compared to their exploration time of F. Scopolamine-induced demented rats explored N and F objects similarly. Rats pre-treated with silymarin (200, 400, 800 mg/kg) were similar to donepezil and explored the N object significantly more than F (Figure 1b). DI indicated that all rats, except scopolamine

treated rats, discriminated N significantly better than F (Figure 1c).

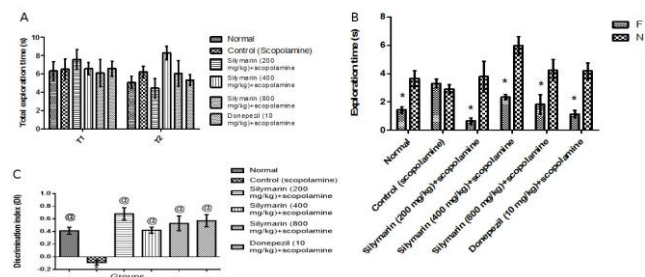


Figure 1: Effect of Silymarin on scopolamine-induced dementia in rats using the object recognition test; A) Total exploratory time in T1 and T2; b) Exploration time of familiar (F) vs the novel object (N) in T2; c) Discrimination index (DI). Results are expressed as mean \pm SEM (n = 8). Statistical analyses were carried out in a) by two-way ANOVA followed by Tukey's multiple comparison tests, in b) by using Student's t-test, while in c) by one-way ANOVA followed by Tukey's multiple comparison tests. *Significant difference versus correspondent N group at $P < 0.05$. *Significant difference from the normal group at $P < 0.05$. @Significant difference from control (scopolamine) group at $P < 0.05$

As depicted in Figure 2a and b, demented rats showed a significant increase in cortical and hippocampal AChE activity to be 14.19 and 11.39 μ mol SH/g/min as compared to normal rats. Pre-treatment with silymarin (200, 400, 800 mg/kg) significantly decreased AChE to be 75.83, 52.36, 50.74%, respectively in cortical tissue and 52.94, 43.2, 35.21%, respectively in hippocampal tissue as compared to control group. Similarly, donepezil administration resulted in significant decrease in AChE activity to be 47.71 and 45.23% respectively in cortical and hippocampal tissue as compared to control group.

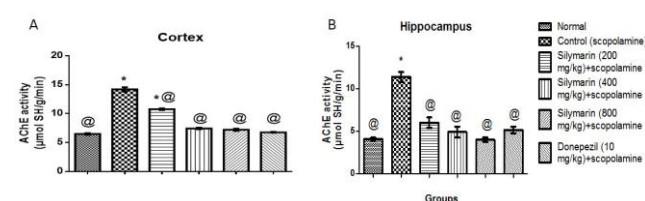


Figure 2: Effect of Silymarin on A) cortical and B) hippocampal acetylcholinesterase (AChE) activity in scopolamine-induced dementia in rats. Results are expressed as mean \pm SEM (n = 6). Statistical analysis was carried out by one-way ANOVA followed by Tukey's multiple comparison tests. *Significant difference from the normal group at $P < 0.05$. @Significant difference from control (scopolamine) group at $P < 0.05$

Results demonstrated in Figure 3 a, b reveals that demented rats increased significantly cortical and hippocampal MDA content to be 163.22% and 149.48% of normal rats, respectively. Preventive treatment with silymarin in doses of 200 and 400 and 800 mg/kg restored cortical MDA content to be 69.62%, 64.70% and 67.06% of demented rats, respectively. Oral administration of silymarin (200 and 400 mg/kg) restored hippocampal MDA content to be 62.30% and 63.96% of demented rats, respectively.

Silymarin in a dose of 800 mg/kg significantly reduced hippocampal MDA content to be 53.68% and 80.25% of the scopolamine control group and normal group, respectively. Also, Donepezil restored cortical and hippocampal MDA content to be 67.37% and 65.02% of control rats, respectively.

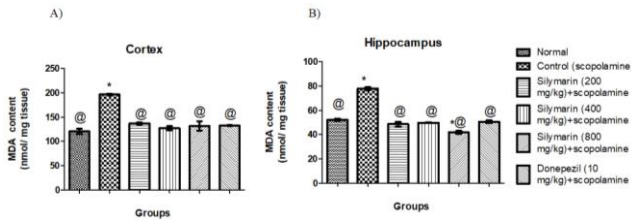


Figure 3: Effect of Silymarin on A) cortical and B) hippocampal reduced malondialdehyde (MDA) activity in scopolamine-induced dementia in rats. Results are expressed as mean ± SEM (n = 6). Statistical analysis was carried out by one-way ANOVA followed by Tukey's multiple comparison tests. *Significant difference from the normal group at P < 0.05. @Significant difference from control (scopolamine) group at P < 0.05

Regarding GSH content, Scopolamine administration significantly reduced cortical and hippocampal GSH contents to be 83.28% and 88.64%, respectively as compared to normal rats. Silymarin administration in doses of 200, 400 and 800 mg/kg significantly restored cortical GSH contents to be 111.69%, 121.53% and 123.77% respectively. Preventive administration of silymarin (200 and 400 mg/kg) restored hippocampal GSH contents to be 113.83% and 111.17% respectively. The results were similar to donepezil as it significantly restored cortical GSH contents to be 124.16% and hippocampal GSH contents to be 111.55% of the control group (Figure 4 a, b).

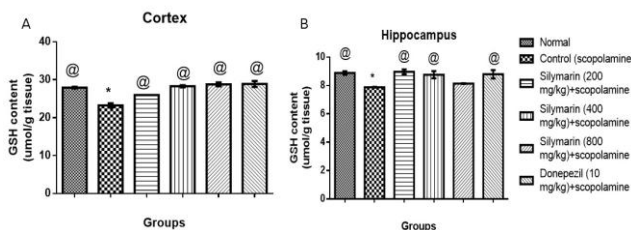


Figure 4: Effect of Silymarin on A) cortical and B) hippocampal reduced glutathione (GSH) activity in scopolamine-induced dementia in rats. Results are expressed as mean ± SEM (n = 6). Statistical analysis was carried out by one-way ANOVA followed by Tukey's multiple comparison tests. *Significant difference from the normal group at P < 0.05. @Significant difference from control (scopolamine) group at P < 0.05.

The effect of silymarin on cortical and hippocampal neurotransmitters in scopolamine-induced demented rats was summarised in Tables 1 & 2. Demented and treated rats did not show any significant change in cortical and hippocampal NE and 5-HT contents. Scopolamine-induced demented rats showed a significant decrease in cortical and hippocampal DA contents to be 58.36% and 22.92% of normal rats, respectively. Demented rats also

significantly reduced cortical and hippocampal GABA contents to be 62.69% and 48.41% of normal rats, respectively. Silymarin in doses of 400 and 800 mg/kg significantly elevated cortical DA content to be 142.04% and 145.86% of control rats, respectively and cortical GABA content to be 145.86% and 144.52% of control rats, respectively.

Table 1: Effect of silymarin on cortical neurotransmitters content in scopolamine-induced dementia in rats

Parameters Treatment	Cortical neurotransmitters (µg/g tissue)			
	Brain Monoamines			GABA
	NE	DA	5-HT	
Normal	0.95 ± 0.07	2.69 ± 0.07 [@]	0.57 ± 0.03	7.13 ± 0.29 [@]
Control (scopolamine)	0.65 ± 0.05	1.57 ± 0.09*	0.59 ± 0.05	4.47 ± 0.46*
Silymarin (200 mg/kg) +scopolamine	0.91 ± 0.18	2.11 ± 0.22	0.65 ± 0.03	5.90 ± 0.40
Silymarin (400 mg/kg) +scopolamine	0.87 ± 0.09	2.23 ± 0.11 [@]	0.64 ± 0.07	6.52 ± 0.20 [@]
Silymarin (800 mg/kg) +scopolamine	0.91 ± 0.05	2.29 ± 0.18 [@]	0.65 ± 0.04	6.46 ± 0.31 [@]
Donepezil (10 mg/kg) + scopolamine	0.97 ± 0.01	2.35 ± 0.13 [@]	0.64 ± 0.05	6.18 ± 0.58 [@]

Results are expressed as mean ± SEM (n = 6). Statistical analysis was carried out by one-way ANOVA followed by Tukey's multiple comparison tests. *Significant difference from normal group at P < 0.05. @Significant difference from control (scopolamine) group at P < 0.05.

Silymarin in doses of 200, 400, and 800 mg/kg restored hippocampal DA contents to be 433.33%, 396.97%, and 472.73% of control rats, respectively and restored hippocampal GABA contents to be 288.47%, 192.52%, and 217.88% of control rats, respectively. Similarly, donepezil restored cortical and hippocampal DA contents to be 149.68% and 433.33% of control scopolamine group, respectively in addition to cortical and hippocampal GABA contents to be 138.26% and 177.92% of control scopolamine group, respectively.

Table 2: Effect of silymarin on hippocampal neurotransmitters content in scopolamine-induced dementia in rats

Parameters Treatment	Hippocampal Neurotransmitters (µg/g tissue)			
	Brain Monoamines			GABA
	NE	DA	5-HT	
Normal	0.67 ± 0.04	1.44 ± 0.06	0.64 ± 0.03	11.32 ± 0.32
Control (scopolamine)	0.65 ± 0.06	0.33 ± 0.02	0.71 ± 0.04	5.48 ± 0.15
Silymarin (200 mg/kg) +scopolamine	0.63 ± 0.05	1.43 ± 0.06	0.70 ± 0.06	12.52 ± 1.11
Silymarin (400 mg/kg) +scopolamine	0.65 ± 0.05	1.31 ± 0.07	0.65 ± 0.06	10.55 ± 0.85
Silymarin (800 mg/kg) +scopolamine	0.63 ± 0.04	1.56 ± 0.06	0.69 ± 0.04	11.94 ± 0.52
Donepezil (10 mg/kg) + scopolamine	0.63 ± 0.04	1.43 ± 0.06	0.73 ± 0.01	9.75 ± 0.55

Results are expressed as mean ± SEM (n = 6). Statistical analysis was carried out by one-way ANOVA followed by Tukey's multiple comparison tests. *Significant difference from the normal group at P < 0.05. @Significant difference from control (scopolamine) group at P < 0.05.

The control group revealed normal histological finding (Figure 5A, 6A). The scopolamine treated group showed marked thickening of the endothelium lining blood vessels with clear perivascular oedema, degenerative neuronal changes in the form of central chromatolysis and neuronal swelling in the brain cortex. Moreover, some neuron was shrunken with pyknotic or lytic nuclei (Fig. 5B)

and neuronophagia. In the hippocampus region, the scopolamine treated group showed thickening of the endothelium lining blood vessels with perivascular and pericellular oedema; some pyramidal cells degenerate with neuronophagia and gliosis (Fig. 6B).

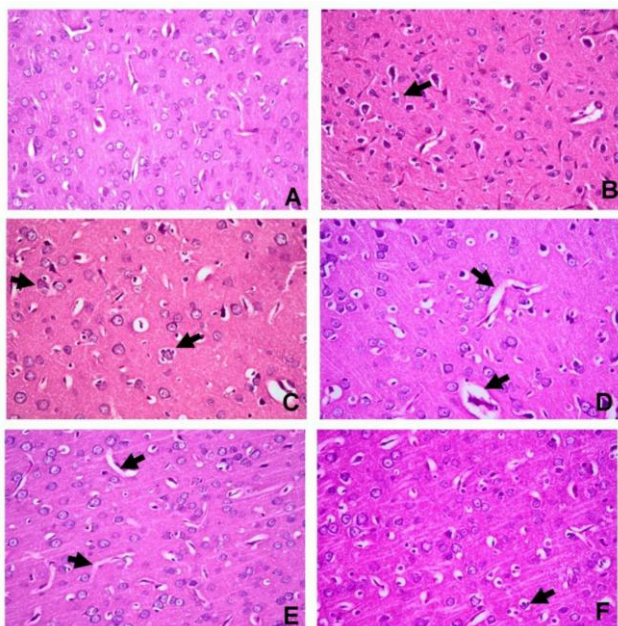


Figure 5: Histopathological changes in the brain cortex of the different treated groups (H&E x400). A. Normal control group showing normal histological finding; B. Scopolamine treated group showing marked neuronal degeneration (arrow) with neurophagia and gliosis; C. Silymarin (200 mg/kg) + scopolamine showing moderate neuronal degeneration with neurophagia (arrow); D. Silymarin (400 mg/kg) + scopolamine showing moderate perivascular edema (arrow) with mild neuronal degeneration; E. Silymarin (800 mg/kg) + scopolamine showing slight perivascular edema (arrow); F. Donepezil (10 mg/kg)+ scopolamine group showing mild neuronal degeneration (arrow) and neurophagia

Swelling of the pyramidal cells was also observed. The previous described histopathological changes were markedly attenuated in all treated group with donepezil (Fig. 5F, 6F) and silymarin in a dose-dependent manner (Fig. 5 & 6 C, D, E) compared to the scopolamine treated group.

Figure 9 summarised the results of immunohistochemical evaluation of GFAP and NF-kB expression in the different experimental groups. In GFAP immunostaining, the astroglia cell in the control group appeared with thin processes and lightly stained cell body (Figure 7A). While the astroglia cell in the scopolamine treated group appeared with thick, dense processes and darkly stained cell body (Figure 7B). The scopolamine treated group showed a significant increase in GFAP immunostaining comparing to control group (Figure 7B). The Donepezil (Figure 7F) and silymarin-treated groups (Figure 7C, D, E) showed a significant reduction in GFAP immunostaining compared to the scopolamine treated group (Figure 9A).

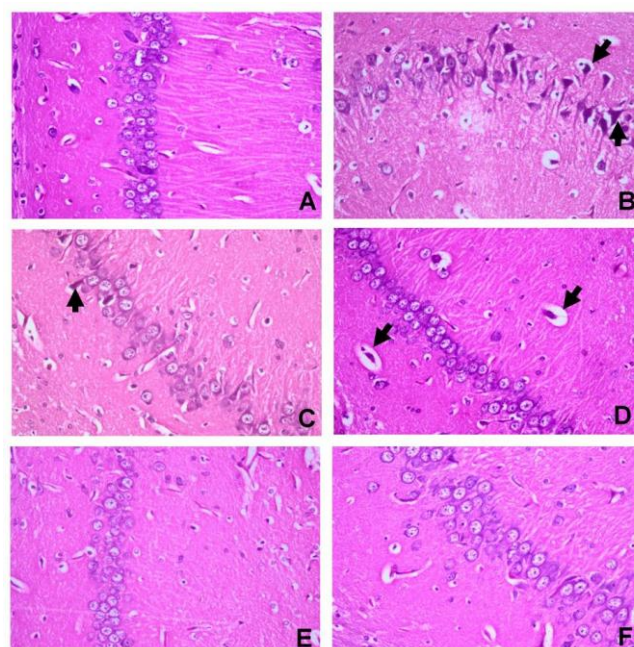


Figure 6: Histopathological changes in the hippocampus of the different treated groups (H&E X400). A. Normal control group showing normal histological picture; B. Scopolamine treated group showing marked degeneration of pyramidal cells (arrow) with neuronophagia and pericellular edema; C. Silymarin (200 mg/kg) + scopolamine showing mild degeneration of pyramidal cells (arrow); D. Silymarin (400 mg/kg) + scopolamine showing thickening of the endothelial lining blood vessels with perivascular edema (arrow); E. Silymarin (800 mg/kg) + scopolamine showing normal histological finding.; F. Donepezil (10 mg/kg) + scopolamine showing mild pyramidal cells swelling

NF-kB immunostaining was detected in cytoplasm and or nucleus of the neuron and glial cells. The cytoplasmic staining of the cells represented in the active form of NF-kB. While nuclear staining of the cells represented the active form of the NF-kB. So, the nuclear-stained cells were only counted as the immunopositive cells. The percentage of immunopositive cells for NF-kB immunostaining of the scopolamine treated group (Figure 8B) was significantly elevated than the control group (Figure 8A). The donepezil (Figure 8F) and silymarin-treated groups (Figure 8 C, D, E) showed a significant reduction in the percentage of NF-kB immunopositive stained cells in dose-dependent manner compared to the scopolamine treated group (Fig. 9B).

Discussion

This study adds new information on the memory-enhancing the effect of silymarin (200, 400, 800 mg/kg), which was similar to donepezil in scopolamine-induced demented rats using the ORT. To the best of the authors' knowledge, this is the first report that highlighted the involvement of cholinergic activity, oxidative stress biomarkers namely (MDA and

GSH), inflammatory biomarkers such as NF-KB and GFAP, brain neurotransmitters as well as histopathological changes in the anti-amnestic effect of silymarin in scopolamine-induced demented rats using the ORT.

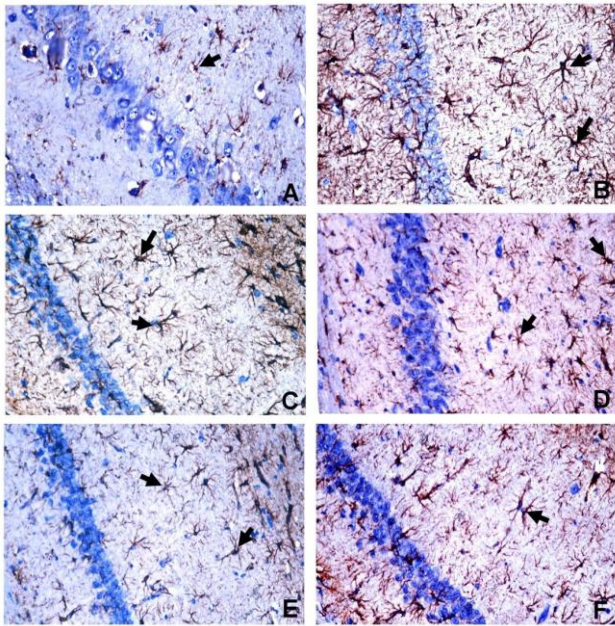


Figure 7: Representative GFAP immunohistochemistry in the hippocampus region of different treated groups (X400). A. Control group showing weak immunostaining of astroglia cells (arrow); B. Scopolamine treated group showing strong immunostaining of astroglia cells with thick, dense processes and darkly stained cell body (arrow); C. Silymarin (200 mg/kg) + scopolamine and D. Silymarin (400 mg/kg) + scopolamine showing moderate immunostaining of astroglia cells (arrow); E. Silymarin (800 mg/kg) + scopolamine showing thin processes and lightly stained cell body of astroglia cells (arrow); F. Donepezil (10 mg/kg) + scopolamine group showing reduction in the immunostaining of astroglia cells (arrow)

In this study, scopolamine-induced demented rats impaired recognition memory in the ORT, as demented rats explored both F and N objects similarly and were not able to discriminate between both objects. These results are in harmony with prior studies [36] [37].

Silymarin-treated rats reversed scopolamine-induced non-spatial working memory impairment in the ORT as they were able to discriminate between the F and N objects and increased the time spent in identifying the N object concerning the F object. These effects are similar to the standard drug, donepezil.

Since the total exploration time within T1 and T2 were similar in demented, silymarin and donepezil-treated rats, therefore it can be deduced that attentional and sensorimotor activities did not influence rats' performance in the ORT. This indicates that memory enhancing effects of silymarin and donepezil was independent on non-specific factors of rats.

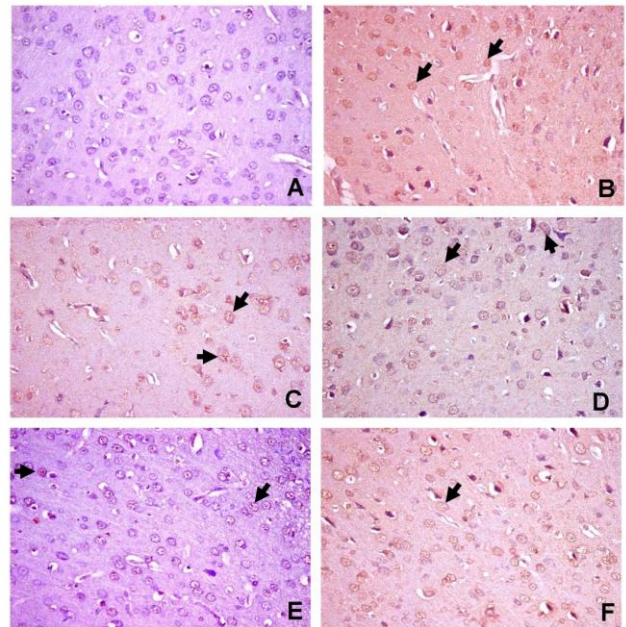


Figure 8: Representative NF-kB immunohistochemistry in the brain cortex of different treated groups (x 400). A. Control group showing very weak nuclear reaction; B. Scopolamine treated group showing strong and numerous nuclear staining (arrow); C. Silymarin (200 mg/kg) + scopolamine and D. Scopolamine + S400 showing moderate nuclear immunoreaction (arrow); E. Scopolamine + S800 showing weak nuclear immunostaining (arrow); F. Donepezil treated group showing reduction in the immunopositive cells (arrow)

In this work, donepezil, which is a potent AChEI, administered orally at 10mg/kg/day for 14 consecutive days before scopolamine ameliorated cholinergic deficits, oxidative stress, inflammation, and histopathological changes in the brain of scopolamine-induced demented rats. These findings are in concordance with prior studies [38][39] and emphasize the effectiveness of donepezil as standard anti-amnestic agent for screening novel therapeutics for treating cognitive deficit.

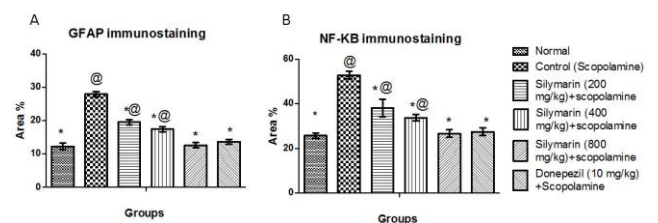


Figure 9: Immunohistochemical evaluation of GFAP and NF-kB expression in the different treated groups. A. The bar chart of GFAP immunostaining expressed as area %. B. The bar chart of NF-kB immunostaining expressed as the percentage of positively stained cells. Statistical analysis was carried out by one-way ANOVA followed by Newman Keuls multiple comparison tests. *Significant difference from the normal group at $P < 0.05$. @Significant difference from control (scopolamine) group at $P < 0.05$

In this study, Scopolamine-induced dementia resulted in cholinergic system dysfunction as evidenced by elevation in AChE activity, an important enzyme which hydrolyses ACh, an essential neurotransmitter involved in learning and memory.

This finding is in line with prior studies [40] [41].

Preventive treatment with silymarin and donepezil decreased cortical and hippocampal AChE activity, indicating that silymarin might have ameliorated cognitive, cognitive deficit in the ORT partly via enhancing cholinergic neurotransmission. Prior studies have reported that silymarin has also protected against high fat diet-induced dementia and manganese-induced neurotoxicity via restoration of AChE activity [42] [43].

Oxidative stress has been implicated in the pathogenesis of DAT. This is apparent in the current investigation as scopolamine-induced dementia resulted in the elevation of cortical and hippocampal MDA content, the final product of lipid peroxidation and subsequent reduction of the endogenous antioxidant namely GSH, due to elevated Reactive Oxygen Species (ROS). This finding is inconsistent with prior studies [44] [45] and implies that scopolamine associated oxidative stress accounts for memory impairment in the study.

Preventive treatment with silymarin reversed scopolamine associated oxidative stress to be similar to that of donepezil as it reduced cortical and hippocampal MDA content, lipid peroxides formation by elevating the ROS scavenging activity of cortical and hippocampal GSH content. This reveals that ameliorative effect of silymarin on scopolamine-induced dementia in rats may be partly due to its antioxidant activity. Several studies have also demonstrated the neuroprotective of silymarin against oxidative stress associated with experimentally-induced Parkinson's disease and cerebral ischemia [46] [47].

Neurotransmitters such as GABA and dopamine have a greater impact on memory retrieval and consolidation than 5-HT and NE [48]. GABAergic and DAergic deficits contribute to memory impairment in patients suffering from AD [49] [50].

In line with this notion, scopolamine-induced pathological changes were coupled with deficits in cortical and hippocampal GABA and dopamine contents. This finding is inconsistent with that of [51] [52].

Pretreatment with silymarin restored GABA and DA contents to be similar to donepezil. This implies that anti-oxidant effect of silymarin may contribute to the preservation of neurotransmitters, and thereby memory-enhancing effect in amnesic rats. Previous studies reported that silymarin restored DA content in 1-Methyl-4-phenyl-1,2,3,6-tetrahydropyridine (MPTP)-induced Parkinson's disease and stress-induced depression in mice [53] [54].

As mentioned before, elevated AChE activity in DAT aggravates the formation of A β plaques which in turn activates astrocytes and upregulate GFAP, an indicator of neuroinflammation [55] [56].

Scopolamine-induced dementia in this work showed an elevation in hippocampal and cortical protein expression of GFAP when compared to normal rats. This finding is in harmony with a prior study [57] and implies that scopolamine upregulated inflammatory cascade via astrocytic activation.

Silymarin administration counteracted scopolamine-induced elevation in protein expression of GFAP, by suppressing astrocyte activation. This reveals that inhibition of astrocytic activation might have resulted from suppression of inflammatory cascade and oxidative stress.

Oxidative stress contributes to the elevation of ROS which results in activation of NF- κ B, a transcription factor responsible for regulation of pro-inflammatory genes such as, cytokines and chemokines [58] [59] [60].

In this work, scopolamine-induced dementia increased protein expression of NF- κ B in the brain cortex and hippocampus, indicating that elevated inflammatory response resulting from oxidative stress might account for cognitive deficit in amnesic rats.

Prior treatment with silymarin combated the elevated protein expression of NF- κ B in the brain cortex and hippocampus of demented rats; this suggests that silymarin ameliorated cognitive deficit via suppression of inflammatory cascade probably through its anti-oxidant effect in demented rats. This finding is inconsistent with other studies [61] [62] [63] [64].

It can be concluded that the memory-enhancing the effect of silymarin in scopolamine-induced demented rats using the ORT may be partly mediated by, attenuating cholinergic deficits, anti-oxidant and anti-inflammatory effects as well as amelioration in DAergic, GABAergic neurotransmission and histopathological changes. Further pre-clinical studies are warranted to investigate other mechanisms that may underlie the anti-amnesic effect of silymarin. Clinical studies are needed to address the validity of silymarin to prevent or slow down the progression of DAT.

References

1. Crawford TJ, Higham S. Distinguishing between impairments of working memory and inhibitory control in cases of early dementia. *Neuropsychologia*. 2016; 81: 61-7. <https://doi.org/10.1016/j.neuropsychologia.2015.12.007> PMID:26687733
2. Duan H, Jiang J, Xu J, Zhou H, Huang Z, Yu Z, al. Differences in Abeta brain networks in Alzheimer's disease and healthy controls. *Brain Res*. 2017; 1655:77-89. <https://doi.org/10.1016/j.brainres.2016.11.019> PMID:27867033
3. Walsh C, Drinkenburg WH, Ahnaou A. Neurophysiological assessment of neural network plasticity and connectivity: Progress towards early functional biomarkers for disease interception therapies in Alzheimer's disease. *Neurosci Biobehav Rev*. 2017; 73:340-58.

- <https://doi.org/10.1016/j.neubiorev.2016.12.020> PMID:28027953
4. Hajilou BB, Done DJ. Evidence for dissociation of structural and semantic knowledge in dementia of the Alzheimer type (DAT). *Neuropsychologia*. 2007; 45(4):810-6. <https://doi.org/10.1016/j.neuropsychologia.2006.08.008> PMID:17034821
 5. Pitsikas N, Gravanis A. The novel dehydroepiandrosterone (DHEA) derivative BNN27 counteracts delay-dependent and scopolamine-induced recognition memory deficits in rats. *Neurobiol Learn Mem*. 2017; 140:145-53. <https://doi.org/10.1016/j.nlm.2017.03.004> PMID:28274826
 6. Pitsikas N. The role of nitric oxide in the object recognition memory. *Behav Brain Res*. 2015; 285: 200-7. <https://doi.org/10.1016/j.bbr.2014.06.008> PMID:24933185
 7. Palmer D, Creighton S, Prado VF, Prado MAM, Choleris E, Winters BD. Mice are deficient for striatal Vesicular Acetylcholine Transporter (VACHT) display impaired short-term but normal long-term object recognition memory. *Behav Brain Res*. 2016; 311:267-78. <https://doi.org/10.1016/j.bbr.2016.05.050> PMID:27233822
 8. Navarro NM, Krawczyk MC, Boccia MM, Blake MG. Extinction and recovery of an avoidance memory impaired by scopolamine. *Physiol Behav*. 2017; 171:192-8. <https://doi.org/10.1016/j.physbeh.2016.12.042> PMID:28069463
 9. Hwang ES, Kim HB, Lee S, Kim MJ, Lee SO, Han SM, al. Logan in enhances long-term potentiation and recovers scopolamine-induced learning and memory impairments. *Physiol Behav*. 2017; 171:243-8. <https://doi.org/10.1016/j.physbeh.2016.12.043> PMID:28069458
 10. Liu W, Rabinovich A, Nash Y, Frenkel D, Wang Y, Youdim MB, al. Anti-inflammatory and protective effects of MT-031, a novel multitarget MAO-A and AChE/BuChE inhibitor in scopolamine mouse model and inflammatory cells. *Neuropharmacology*. 2017;113:445e456.
 11. Godyn J, Jonczyk J, Panek D, Malawska B. Therapeutic strategies for Alzheimer's disease in clinical trials. *Pharmacol Rep*. 2016; 68(1): 127-38. <https://doi.org/10.1016/j.pharep.2015.07.006> PMID:26721364
 12. Yuan Q, Wang CW, Shi J, Lin ZX. Effects of Ginkgo biloba on dementia: An overview of systematic reviews. *J Ethnopharmacol*. 2017; 195:1-9. <https://doi.org/10.1016/j.jep.2016.12.005> PMID:27940086
 13. Younis N, Shaheen MA, Abdallah MH. Silymarin-loaded Eudragit(R) RS100 nanoparticles improved the ability of silymarin to resolve hepatic fibrosis in bile duct ligated rats. *Biomed Pharmacother*. 2016; 81:93-103. <https://doi.org/10.1016/j.biopha.2016.03.042> PMID:27261582
 14. Younis NN, Shaheen MA, Mahmoud MF. Silymarin preconditioning protected insulin resistant rats from liver ischemia-reperfusion injury: the role of endogenous H2S. *J Surg Res*. 2016; 204(2):398-409. <https://doi.org/10.1016/j.jss.2016.04.069> PMID:27565076
 15. Svobodova A, Zdarilova A, Maliskova J, Mikulkova H, Walterova D, Vostalova J. Attenuation of UVA-induced damage to human keratinocytes by silymarin. *J Dermatol Sci*. 2007; 46(1):21-30. <https://doi.org/10.1016/j.jdermsci.2006.12.009> PMID:17289350
 16. Khorsandi L, Saki G, Bavarsad N, Mombeini M. Silymarin induces a multi-targeted cell death process in the human colon cancer cell line HT-29. *Biomed Pharmacother*. 2017; 94:890-7. <https://doi.org/10.1016/j.biopha.2017.08.015> PMID:28810529
 17. Raza SS, Khan MM, Ashafaq M, Ahmad A, Khuwaja G, Khan A, al. Silymarin protects neurons from oxidative stress associated damages in focal cerebral ischemia: a behavioral, biochemical and immunohistological study in Wistar rats. *J Neurol Sci*. 2011; 309(1-2):45-54. <https://doi.org/10.1016/j.jns.2011.07.035> PMID:21840019
 18. Senturk H, Kabay S, Bayramoglu G, Ozden H, Yaylak F, Yucel M, al. Silymarin attenuates the renal ischemia/reperfusion injury-induced morphological changes in the rat kidney. *World J Urol*. 2008; 26(4): 401-7. <https://doi.org/10.1007/s00345-008-0256-1> PMID:18408933
 19. Rao PR, Viswanath RK. Cardioprotective activity of silymarin in ischemia-reperfusion-induced myocardial infarction in albino rats. *Exp Clin Cardiol*. 2007; 12(4):179-87. PMID:18651002 PMID:PMC2359609
 20. Borah A, Paul R, Choudhury S, Choudhury A, Bhuyan B, Das Talukdar A, al. Neuroprotective potential of silymarin against CNS disorders: insight into the pathways and molecular mechanisms of action. *CNS Neurosci Ther*. 2013; 19(11):847-53. <https://doi.org/10.1111/cns.12175> PMID:24118806
 21. Hirayama K, Oshima H, Yamashita A, Sakatani K, Yoshino A, Katayama Y. Neuroprotective effects of silymarin on ischemia-induced delayed neuronal cell death in rat hippocampus. *Brain Res*. 2016; 1646:297-303. <https://doi.org/10.1016/j.brainres.2016.06.018> PMID:27312091
 22. Sarubbo F, Ramis MR, Kienzer C, Aparicio S, Esteban S, Miralles A, al. Chronic Silymarin, Quercetin and Naringenin Treatments Increase Monoamines Synthesis and Hippocampal Sirt1 Levels Improving Cognition in Aged Rats. *J Neuroimmune Pharmacol*. 2017; 2017.
 23. Yaghmaei P, Azarfar K, Dezfulian M, Ebrahim-Habibi A. Silymarin effect on amyloid-beta plaque accumulation and gene expression of APP in an Alzheimer's disease rat model. *Daru*. 2014; 22(1): 24. <https://doi.org/10.1186/2008-2231-22-24> PMID:24460990 PMID:PMC3904165
 24. El-Marasy SA, El-Shenawy SM, El-Khatib AS, El-Shabrawy OA, Kenawy SA. Effect of Nigella sativa and wheat germ oils on scopolamine-induced memory impairment in rats. *Bulletin of Faculty of Pharmacy, Cairo University*. 2012; 50:81-8. <https://doi.org/10.1016/j.bfopcu.2012.05.001>
 25. Galhardi F, Mesquita K, Monserrat JM, Barros DM. Effect of silymarin on biochemical parameters of oxidative stress in aged and young rat brain. *Food Chem Toxicol*. 2009; 47(10):2655-60. <https://doi.org/10.1016/j.fct.2009.07.030> PMID:19647779
 26. Schreiber R, Vivian J, Hedley L, Szczepanski K, Secchi RL, Zuzov M, al. Effects of the novel 5-HT(6) receptor antagonist RO4368554 in rat models for cognition and sensorimotor gating. *Eur Neuropsychopharmacol*. 2007; 17(4):277-88. <https://doi.org/10.1016/j.euroneuro.2006.06.009> PMID:16989988
 27. Ennaceur A, Delacour J. A new one-trial test for neurobiological studies of memory in rats. 1: Behavioral data. *Behav Brain Res*. 1988; 31(1): 47-59. [https://doi.org/10.1016/0166-4328\(88\)90157-X](https://doi.org/10.1016/0166-4328(88)90157-X)
 28. Ellman GL, Courtney KD, Andres V, Jr., Feather-Stone RM. A new and rapid colorimetric determination of acetylcholinesterase activity. *Biochem Pharmacol*. 1961; 7: 88-95. [https://doi.org/10.1016/0006-2952\(61\)90145-9](https://doi.org/10.1016/0006-2952(61)90145-9)
 29. Gorun V, Proinov I, Baltescu V, Balaban G, Barzu O. Modified Ellman procedure for assay of cholinesterases in crude enzymatic preparations. *Anal Biochem*. 1978; 86(1): 324-6. [https://doi.org/10.1016/0003-2697\(78\)90350-0](https://doi.org/10.1016/0003-2697(78)90350-0)
 30. Ruiz-Larrea MB, Leal AM, Liza M, Lacort M, de Groot H. Antioxidant effects of estradiol and 2-hydroxyestradiol on iron-induced lipid peroxidation of rat liver microsomes. *Steroids*. 1994; 59(6): 383-8. [https://doi.org/10.1016/0039-128X\(94\)90006-X](https://doi.org/10.1016/0039-128X(94)90006-X)
 31. Ellman GL. Tissue sulfhydryl groups. *Arch Biochem Biophys*. 1959; 82(1): 70-7. [https://doi.org/10.1016/0003-9861\(59\)90090-6](https://doi.org/10.1016/0003-9861(59)90090-6)
 32. Pagel P, Blome J, Wolf HU. High-performance liquid chromatographic separation and measurement of various biogenic compounds possibly involved in the pathomechanism of Parkinson's disease. *J Chromatogr B Biomed Sci Appl*. 2000; 746(2): 297-304. [https://doi.org/10.1016/S0378-4347\(00\)00348-0](https://doi.org/10.1016/S0378-4347(00)00348-0)
 33. Heinrikson RL, Meredith SC. Amino acid analysis by reverse-phase high-performance liquid chromatography: precolumn derivatization with phenylisothiocyanate. *Anal Biochem*. 1984; 136(1): 65-74. [https://doi.org/10.1016/0003-2697\(84\)90307-5](https://doi.org/10.1016/0003-2697(84)90307-5)
 34. Bancroft JD, Stevens A. The haematoxylin and eosin. Theory and Practice of Histological Techniques. fourth ed. Churchill Livingstone, London, New York & Tokyo, 1996: 99-112 (Ch 6).
 35. Ogaly HA, Khalaf AA, Ibrahim MA, Galal MK, Abd-Elsalam RM. Influence of green tea extract on oxidative damage and apoptosis induced by deltamethrin in rat brain. *Neurotoxicol Teratol*. 2015; 50: 23-31. <https://doi.org/10.1016/j.ntt.2015.05.005> PMID:26013673
 36. de Bruin NM, Prickaerts J, van Loevezijn A, Venhorst J, de Groot L, Houba P, et al. Two novel 5-HT6 receptor antagonists ameliorate scopolamine-induced memory deficits in the object recognition and object location tasks in Wistar rats. *Neurobiol Learn Mem*. 2011; 96(2): 392-402. <https://doi.org/10.1016/j.nlm.2011.06.015> PMID:21757018
 37. Li J, Gao L, Sun K, Xiao D, Li W, Xiang L et al. Benzoate fraction from *Gentiana rigescens* Franch alleviates scopolamine-induced impaired memory in mice model in vivo. *J Ethnopharmacol*. 2016; 193: 107-16. <https://doi.org/10.1016/j.jep.2016.08.001> PMID:27492328
 38. Zaki HF, Abd-El-Fattah MA, Attia AS. Naringenin protects against scopolamine-induced dementia in rats. *Bulletin of Faculty of Pharmacy, Cairo University*. 2014; 52: 15-25. <https://doi.org/10.1016/j.bfopcu.2013.11.001>
 39. Haider A, Inam W, Khan SA, Hifza, Mahmood W, Abbas G. Beta-glucan attenuated scopolamine induced cognitive impairment via

- hippocampal acetylcholinesterase inhibition in rats. *Brain Res.* 2016; 1644: 141-8. <https://doi.org/10.1016/j.brainres.2016.05.017> PMID:27180103
40. Yang W, Yu J, Zhao L, Ma N, Fang Y, Pei F, et al. Polysaccharides from *Flammulina velutipes* improve scopolamine-induced impairment of learning and memory of rats. *Journal of Functional Foods.* 2015; 18: 411-22. <https://doi.org/10.1016/j.jff.2015.08.003>
41. Qu Z, Zhang J, Yang H, Gao J, Chen H, Liu C et al. *Prunella vulgaris* L., an Edible and Medicinal Plant, Attenuates Scopolamine-Induced Memory Impairment in Rats. *J Agric Food Chem.* 2017; 65(2): 291-300. <https://doi.org/10.1021/acs.jafc.6b04597> PMID:28001065
42. Chtourou Y, Fetoui H, Garoui el M, Boudawara T, Zeghal N. Improvement of cerebellum redox states and cholinergic functions contribute to the beneficial effects of silymarin against manganese-induced neurotoxicity. *Neurochem Res.* 2012; 37(3): 469-79. <https://doi.org/10.1007/s11064-011-0632-x> PMID:22033861
43. Neha, Kumar A, Jaggi AS, Sodhi RK, Singh N. Silymarin ameliorates memory deficits and neuropathological changes in mouse model of high-fat-diet-induced experimental dementia. *Naunyn Schmiedeberg's Arch Pharmacol.* 2014; 387(8): 777-87. <https://doi.org/10.1007/s00210-014-0990-4> PMID:24866499
44. Asgharzade S, Rabiei Z, Rafieian-Kopaei M. Effects of *Matricaria chamomilla* extract on motor coordination impairment induced by scopolamine in rats. *Asian Pac J Trop Biomed* 2015; 5(10). <https://doi.org/10.1016/j.apjtb.2015.06.006>
45. Rabiei Z, Mokhtari S, Asgharzade S, Gholami M, Rahnama S, Rafieian-kopaei M. Inhibitory effect of *Thymus vulgaris* extract on memory impairment induced by scopolamine in rat. *Asian Pac J Trop Biomed.* 2015; 5(10): 845-51. <https://doi.org/10.1016/j.apjtb.2015.07.006>
46. Baluchnejadmojarad T, Roghani M, Mafakheri M. Neuroprotective effect of silymarin in 6-hydroxydopamine hemi-parkinsonian rat: involvement of estrogen receptors and oxidative stress. *Neurosci Lett.* 2010; 480(3):206-10. <https://doi.org/10.1016/j.neulet.2010.06.038> PMID:20600617
47. Muley MM, Thakare VN, Patil RR, Bafna PA, Naik SR. Amelioration of cognitive, motor and endogenous defense functions with silymarin, piracetam and protocatechuic acid in the cerebral global ischemic rat model. *Life Sci.* 2013; 93(1): 51-7. <https://doi.org/10.1016/j.lfs.2013.05.020> PMID:23743171
48. Myhrer T. Neurotransmitter systems involved in learning and memory in the rat: a meta-analysis based on studies of four behavioral tasks. *Brain Res Brain Res Rev.* 2003; 41(2-3): 268-87. [https://doi.org/10.1016/S0165-0173\(02\)00268-0](https://doi.org/10.1016/S0165-0173(02)00268-0)
49. Gueli MC, Taibi G. Alzheimer's disease: amino acid levels and brain metabolic status. *Neurol Sci.* 2013; 34(9):1575-9. <https://doi.org/10.1007/s10072-013-1289-9> PMID:23354600
50. Kumar A, Singh A, Ekavali. A review on Alzheimer's disease pathophysiology and its management: an update. *Pharmacol Rep.* 2015; 67(2): 195-203. <https://doi.org/10.1016/j.pharep.2014.09.004> PMID:25712639
51. Abd-El-Fattah MA, Abdelakader NF, Zaki HF. Pyrrolidine dithiocarbamate protects against scopolamine-induced cognitive impairment in rats. *Eur J Pharmacol.* 2014; 723:330-8. <https://doi.org/10.1016/j.ejphar.2013.11.008> PMID:24315930
52. Salat K, Podkowa A, Mogilski S, Zareba P, Kulig K, Salat R et al. The effect of GABA transporter 1 (GAT1) inhibitor, tiagabine, on scopolamine-induced memory impairments in mice. *Pharmacol Rep.* 2015; 67(6):1155-62. <https://doi.org/10.1016/j.pharep.2015.04.018> PMID:26481535
53. Perez HJ, Carrillo SC, Garcia E, Ruiz-Mar G, Perez-Tamayo R, Chavarria A. Neuroprotective effect of silymarin in a MPTP mouse model of Parkinson's disease. *Toxicology.* 2014; 319: 38-43. <https://doi.org/10.1016/j.tox.2014.02.009> PMID:24607817
54. Thakare VN, Dhakane VD, Patel BM. Potential antidepressant-like activity of silymarin in the acute restraint stress in mice: Modulation of corticosterone and oxidative stress response in cerebral cortex and hippocampus. *Pharmacol Rep.* 2016; 68(5):1020-7. <https://doi.org/10.1016/j.pharep.2016.06.002> PMID:27428764
55. Singh M, Kaur M, Kukreja H, Chugh R, Silakari O, Singh D. Acetylcholinesterase inhibitors as Alzheimer therapy: from nerve toxins to neuroprotection. *Eur J Med Chem.* 2013; 70:165-88. <https://doi.org/10.1016/j.ejmech.2013.09.050> PMID:24148993
56. Ghumatkar PJ, Patil SP, Jain PD, Tambe RM, Sathaye S. Nootropic, neuroprotective and neurotrophic effects of phloretin in scopolamine induced amnesia in mice. *Pharmacol Biochem Behav.* 2015; 135:182-91. <https://doi.org/10.1016/j.pbb.2015.06.005> PMID:26071678
57. Xu T, Shen X, Yu H, Sun L, Lin W, Zhang C. Water-soluble ginseng oligosaccharides protect against scopolamine-induced cognitive impairment by functioning as an antineuroinflammatory agent. *J Ginseng Res.* 2016; 40(3):211-9. <https://doi.org/10.1016/j.jgr.2015.07.007> PMID:27635118
58. Zhang L, Wu C, Zhao S, Yuan D, Lian G, Wang X et al. Demethoxycurcumin, a natural derivative of curcumin attenuates LPS-induced pro-inflammatory responses through down-regulation of intracellular ROS-related MAPK/NF-kappaB signaling pathways in N9 microglia induced by lipopolysaccharide. *Int Immunopharmacol.* 2010; 10(3):331-8. <https://doi.org/10.1016/j.intimp.2009.12.004> PMID:20018257
59. Soetikno V, Sari FR, Lakshmanan AP, Arumugam S, Harima M, Suzuki K, et al. Curcumin alleviates oxidative stress, inflammation, and renal fibrosis in remnant kidney through the Nrf2-keap1 pathway. *Mol Nutr Food Res.* 2013; 57(9): 1649-59. <https://doi.org/10.1002/mnfr.201200540> PMID:23174956
60. Ahmed SM, Luo L, Namani A, Wang XJ, Tang X. Nrf2 signaling pathway: Pivotal roles in inflammation. *Biochim Biophys Acta.* 2017; 1863(2): 585-97. <https://doi.org/10.1016/j.bbadis.2016.11.005> PMID:27825853
61. Hou YC, Liou KT, Chern CM, Wang YH, Liao JF, Chang S et al. Preventive effect of silymarin in cerebral ischemia-reperfusion-induced brain injury in rats possibly through impairing NF-kappaB and STAT-1 activation. *Phytomedicine.* 2010; 17(12):963-73. <https://doi.org/10.1016/j.phymed.2010.03.012> PMID:20833521
62. Ashkavand Z, Malekinejad H, Amnattalab A, Rezaei-Golmisheh A, Vishwanath BS. Silymarin potentiates the anti-inflammatory effects of Celecoxib on chemically induced osteoarthritis in rats. *Phytomedicine.* 2012; 19(13):1200-5. <https://doi.org/10.1016/j.phymed.2012.07.008> PMID:22925727
63. Atawia RT, Tadros MG, Khalifa AE, Mosli HA, Abdel-Naim AB. Role of the phytoestrogenic, pro-apoptotic and anti-oxidative properties of silymarin in inhibiting experimental benign prostatic hyperplasia in rats. *Toxicol Lett.* 2013; 219(2): 160-9. <https://doi.org/10.1016/j.toxlet.2013.03.002> PMID:23500659
64. Heeba GH, Mahmoud ME. Therapeutic potential of morin against liver fibrosis in rats: modulation of oxidative stress, cytokine production and nuclear factor kappa B. *Environ Toxicol Pharmacol.* 2014; 37(2): 662-71. <https://doi.org/10.1016/j.etap.2014.01.026> PMID:24583409