

Unusual Signs and Symptoms in HIV-Positive Patients Coinfected with *Leishmania spp.*: The Importance of Neglected Tropical Disease in Differential Diagnosis

Manuela Ceccarelli^{1*}, Emmanuele Venanzi Rullo¹, Fabrizio Condorelli², Fabrizio Vitale³, Vincenzo Di Marco⁴, Giuseppe Nunnari¹, Giovanni Francesco Pellicano⁵

¹Department of Clinical and Experimental Medicine, Unit of Infectious Diseases, University of Messina, Italy; ²Department of Pharmacological Sciences, Università del Piemonte Orientale "A. Avogadro", Novara, Italy; ³Zoo-prophylactic Experimental Institute of Sicily, Palermo (PA), Italy; ⁴Zoo-prophylactic Experimental Institute of Sicily, Barcellona Pozzo di Gotto (ME), Italy; ⁵Department of Human Pathology of the Adult and the Developmental Age "G. Barresi", Unit of Infectious Diseases, University of Messina, Italy

Abstract

Citation: Ceccarelli M, Venanzi Rullo E, Condorelli F, Vitale F, Di Marco V, Nunnari G, Pellicano GF. Unusual Signs and Symptoms in HIV-Positive Patients Coinfected with *Leishmania spp.*: The Importance of Neglected Tropical Disease in Differential Diagnosis. Open Access Maced J Med Sci. 2018;186:1-6. <https://doi.org/10.3889/oamjms.2018.186>

Keywords: Leishmania; HIV; Visceral Leishmania; CD4: CD8 ratio; Coinfection

***Correspondence:** Manuela Ceccarelli, Department of Clinical and Experimental Medicine, Unit of Infectious Diseases, University of Messina, Italy. E-mail: manuela.ceccarelli86@gmail.com

Received: 28-Jan-2018; **Revised:** 25-Feb-2018; **Accepted:** 27-Mar-2018; **Online first:** 25-Apr-2018

Copyright: © 2018 Manuela Ceccarelli, Emmanuele Venanzi Rullo, Fabrizio Condorelli, Fabrizio Vitale, Vincenzo Di Marco, Giuseppe Nunnari, Giovanni Francesco Pellicano. This is an open-access article distributed under the terms of the Creative Commons Attribution-NonCommercial 4.0 International License (CC BY-NC 4.0)

Funding: This research did not receive any financial support

Competing Interests: The authors have declared that no competing interests exist

BACKGROUND: Leishmaniasis is a parasitic disease affecting both animals and humans, acquired with the bite of sand flies or, in Injection Drug Users (IDUs), with contaminated needles, still hypoendemic in Sicily and the Mediterranean basin. Even though it is responsible for 20,000 to 40,000 deaths per year, this parasitic infection is still considered a neglected tropical disease. People Living with HIV (PLWH) are considered at high-risk of developing Leishmaniasis and, despite the introduction of Highly Active Anti-Retroviral Therapy (HAART), mortality rate and relapses prevalence are still high in coinfecting people.

CASE REPORT: We present a case of HIV-Leishmania coinfection, posing the attention on the atypical signs and symptoms and the importance of thinking about other causes than the HIV infection progression when the patient presents with a worsening of his immune status during HAART.

CONCLUSION: This parasitic disease has a high mortality rate, so it is mandatory to think about it in all the patients having a low CD4+ T-cell count and an inverted CD4/CD8 ratio under HAART.

Introduction

After the introduction of Highly Active Anti-Retroviral Therapy (HAART) mean age and comorbidities related to ageing, immune suppression, coinfections and persistent inflammation increased in People Living with HIV (PLWH) [1] [2] [3] [4] [5] [6] [7] [8] [9] [10] [11] [12] [13] [14] [15] [16] [17] [18] [19] [20] [21] [22] [23] [24] [25] [26] [27].

Among the coinfections commonly observed in PLWH, there is Leishmaniasis, which is still considered a neglected tropical disease, affecting immunocompromised people, and especially PLWH,

more than the immunocompetent population, being responsible for 20,000 to 40,000 deaths per year [28].

PLWH are considered at high-risk of developing Leishmaniasis because of the two infections geographical distribution: areas, where the HIV infection have a high prevalence, are usually also areas where the Leishmania infection is widespread [29].

Despite the introduction of HAART significantly reduced the coinfection prevalence, mortality rate and relapses prevalence are still high in immunocompromised people [29][31]. Prognosis is also affected by the nutritional status of the patient [29].

Treatment is difficult in immunocompromised people, because of the role of both constitutive immunodepression and Leishmania-related immunodepression on the response to the infection [28] [31] [32] [33] [34].

Here we present a case of HIV-Leishmania coinfection during which the patient developed some atypical signs before the appearance of a more typical Leishmaniasis clinical presentation allowed the diagnosis.

Case Report

A 52-years-old HIV-positive man, followed in our outpatient clinic since 1999 for his infection, came to the Emergency Ward of our University Hospital in August 2017, complaining of diarrhoea (defined as defecation of yellow liquid faeces at least five times per day) for two months. He lived in a poor health condition setting, and he was a smoker. He always lived in Sicily and never left the island.

Until November 2015 he was on combined anti-retroviral therapy (cART) with emtricitabine/tenofovir disoproxil (FTC/TDF) and raltegravir (RAL), with successful virologic (HIV-RNA not detectable) and partially successful immunological (CD4+ 491/ μ l, 24%) control, but he was lost to follow-up for a year. In January 2017 he was admitted to the Thoracic Surgery Unit of our hospital for a massive left pleural effusion, drained through a chest tube. An incomplete immunological control was highlighted (CD4+ T-cells 62/ μ l, 7%; CD8+ T-cells 630/ μ l, 71%, CD4/CD8 0.09) at that time. Therefore, he started a cART with darunavir/cobicistat (DRV/COBI) and RAL, with a successful virologic control (HIV-RNA not detectable), and a slight improvement of his immunological control (CD4+ 82/ μ l, 11 %) at the last blood testing, which took place in May.

At the admission, he complained of asthenia. He reported that he had autonomously suspended cART, thinking that the diarrhoea was an adverse effect of the therapy, with no improvement. The physical examination revealed extreme dehydration and moderate hepatosplenomegaly. Moreover, a hyperemic hyperthermic painful lesion was highlighted on his left side, around the area where the chest tube was positioned in January. He was feverish (37.5 °C), while blood pressure and heart rate were normal. Blood tests showed anemia (Hb 9.9 g/dl), leukopenia (WBC 3,260/ μ l) and thrombocytopenia (PLTS 109,000/ μ l); hypoalbuminemia (1.7 g/dl); monoclonal hypergammaglobulinemia (65.58%, normal 10.5 - 19.5%). He began an intravenous (IV) therapy with albumin and IV hydration, and a cART with DRV/COBI and RAL was started again.

During the admission his conditions worsened, making it necessary to perform a blood transfusion on August, 5th. Table 1 resumes altered results of the blood tests performed on our patient during the admission.

Table 1: Blood test results during the admission

	Aug, 2 nd	Aug, 4 th	Aug, 5 th	Aug, 6 th	Aug, 8 th	Aug, 11 th	Aug, 16 th
WBC/ μ l	3.280	1.990	2.170	2.080	2.460	1.860	2.140
N (%)	55	56	52	56	50	61	54
N/ μ l	1.810	1.114	1.128	1.165	1.230	1.135	1.156
L (%)	38	37	43	37	44	33	40
L/ μ l	1.250	736	933	770	1.082	614	856
CD3 (%)		87					
CD3/ μ l		641					
CD4 (%)		8					
CD4/ μ l		59					
CD8 (%)		71					
CD8/ μ l		523					
CD4/CD8		0,11					
CD19 (%)		7					
CD19/ μ l		52					
CD20 (%)		5					
CD20/ μ l		37					
CD34 gated (%)		0,02					
CD34 vital/ μ l		1,96					
PLTS	109,000	91,000	71,000	74,000	87,000	103,000	138,000
Hb (g/dl)	9,9	8,2	7,6	8,4	9,7	8,7	8,6
CRP (mg/dl)	12,80		6,30		6,70	6,30	1,50
PCT (ng/ml)		0,44					0,3
Albumin (g/dl)	1,7				2,02	2,34	2,8
γ -globulin (%)	65,58				61,4	58,66	

As it can be seen, his immunological control had worsened, revealing a CD4+ T-cell count of 59/ μ l (8%), with a CD8+ T-cell count of 523/ μ l (71%) and a resulting CD4+/CD8+ ratio of 0.11.

Stool examinations (research of the *Clostridium difficile* toxin, parasitic infections and stool cultures, faecal occult blood) were performed, resulting in negative. Suspecting multiple myeloma, the patient underwent a bone marrow biopsy to determine the cause of the pancytopenia. No biopsy was performed on the flank skin lesion.

Indirect immunofluorescence assay (IFAT) and Polymerase Chain Reaction (PCR) for the research of a *Leishmania* infection were performed on the 4th day after the admission, resulting in positive (PCR 11,500 *Leishmania*/ml; IFAT 1:5120) on the 8th day after the admission.

He then began a treatment with Liposomal Amphotericin B (L-AMB) 4 mg/kg/day on days 1 to 5, according to the *Italian guidelines for the diagnosis and management of HIV infection (2016 edition)* of the Italian Society of Infectious and Tropical Diseases (ISITD), and he repeated the treatment on days 10, 17, 24, 31 and 38, completing the cycle [35]. He was discharged on the 14th day after the admission and completed the treatment as an outpatient. Diarrhoea and the hyperemic lesion on his flank completely disappeared after the fifth day of therapy with L-AMB. Figure 1 shows the Serum Protein Electrophoresis (S-PEP) trend before, during and at the end of the therapy. Secondary prophylaxis was not started, and the patient is still in follow up for the possibility of VL relapses.

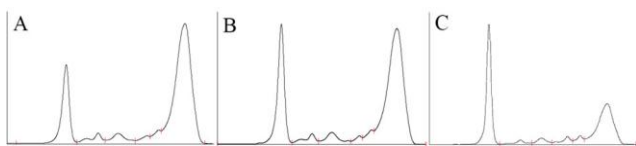


Figure 1: S-PEP before (A); during (B) and after completing (C) the therapy with L-AMB

Discussion

Leishmaniasis is a parasitic disease affecting both animals and humans, acquired with the bite of sand flies or, in Injection Drug Users (IDUs), with contaminated needles, still hypoendemic in Sicily and the Mediterranean basin [34] [36].

It is a known opportunistic disease in People Living with HIV (PLWH), whose immunodeficiency promotes visceral localisation, even though the coinfection prevalence reduced after the introduction of HAART [33] [36] [37]. Moreover, *Leishmania spp* can promote viral replication and enhance progression to Acquired Immuno-Deficiency Syndrome (AIDS) [34]. As a result, despite the introduction of HAART, relapses are still common, and mortality is three times higher in HIV-Leishmania coinfection than in HIV-negative people affected by Leishmania infection [30] [31].

Cota and al [33] reported in 2017 that CD4 T-cell count at the moment of the diagnosis is not able to foresee the patient's prognosis. However, resolution of the infection depends on an efficient CD4+ T-cell response, and it was observed that a higher incidence of symptoms is related to a lower CD4+ T-cell count [31] [32].

The most frequent signs and symptoms of this infection are fever, asthenia, weight loss and splenomegaly; unspecific symptoms that could often lead to a delay in the diagnosis [31] [34]. Also, PLWH can complain of misleading non-classical symptoms [29].

In our case, the patient came to our attention in January, after more than a year of likely therapeutic vacation, with a seriously impaired immunological control. At the time he did not have any classical sign of the infection (normal S-PEP, no signs of pancytopenia, no hepatosplenomegaly), but it has been reported that Leishmaniasis can be related to pleural effusion, especially in PLWH with a very low CD4+ T-cell count [38]. Moreover, Infectious Diseases Society of America (IDSA) 2016 guidelines report that in PLWH the number of asymptomatic carriers of Leishmania seems to be higher than in the immunocompetent host [39]. Therefore, it can be

supposed that our patient's disease began some time before the classical signs appeared.

An active response to Leishmania, leading to the infection control, is associated to host adaptive immunity, but, at the same time, to natural immunity [40]. The most influential factor in the immune response in Leishmaniasis seems to be the early interaction of the parasite with macrophages and dendritic cells [41].

Moreover, it has been observed an enhanced secretion of Th2 cytokines, and in particular IL-10, in Visceral Leishmaniasis associated to HIV-infection, which can promote the dissemination of both the virus and the parasite [28] [32] [40] [41] [42] [43].

Our patient presented to our attention, both in January and August, with a profoundly impaired immunological control, defined as a very low CD4+ T-cell count and an inverted CD4/CD8 ratio, despite having a suppressed VL, a common sign during visceral Leishmaniasis [42]. However, the fact the patient came from a period of therapeutic vacation made difficult to think to other causes of severe immunodepression than his HIV infection, leading to the possibility of a diagnostic delay.

The CD4/CD8 ratio is a marker of immune dysfunction leading to persistent inflammation in PLWH, and a low ratio can predict an impaired CD4+ T-cell count recovery before the start of the HAART [44]. During visceral leishmaniasis, CD8+ T-cells, and especially those expressing CD38, or activated CD8+ T-cells, increase, leading to a status of chronic inflammation which results in a T cell depletion, establishing a vicious circle that worsens the immunodepression [42].

Although both IDSA and ISITD guidelines recommend secondary prophylaxis with L-AMB in patients with a CD4+ T-cell count lower than 200/ μ l, our patient refused it [35] [39]. He is still in follow up for the possibility of relapses and recently completed his 5th month from the end of the therapy with L-AMB.

In conclusion, visceral Leishmaniasis is an important opportunistic disease in PLWH, with a complicated differential diagnosis because of its unspecific symptoms and signs. It is even more difficult because of the possibility of atypical manifestations.

However, this parasitic disease has a high mortality rate, so it is mandatory to think about it in all the patients having a low CD4+ T-cell count and an inverted CD4/CD8 ratio under HAART.

Further studies are needed to clear the pathogenesis of the infection and to establish the duration of the secondary prophylaxis.

References

1. Lai V, Zizi B, Calia GM, Bagella P, Fiore V, Peruzzo F, Caruana G, Babudieri S, Mura MS, Madeddu G. Fib-4 values and neurocognitive function in hiv-infected patients without hepatic coinfections. *Infect Dis Trop Med.* 2016; 2:e293.
2. La Ferla L, Lo Presti Costantino MR, Mondello P. Kaposi's sarcoma in HIV-infected patients: a review of the literature. *Infect Dis Trop Med.* 2016; 2:e239.
3. Bruno R, Scuderi D, Locatelli ME, Pampaloni A, Pinzone MR. Prevalence of micronutrients deficiencies in a cohort of HIV-positive individuals on ART. *Infect Dis Trop Med.* 2017; 3:e431.
4. Pinzone MR, Di Rosa M, Celesia BM, Condorelli F, Malaguarnera M, Madeddu G, Martellotta F, Castronuovo D, Gussio M, Coco C, Palermo F, Cosentino S, Cacopardo B, Nunnari G. LPS and HIV gp120 modulate monocyte/macrophage CYP27B1 and CYP24A1 expression leading to vitamin D consumption and hypovitaminosis D in HIV-infected individuals. *Eur Rev Med Pharmacol Sci.* 2013; 17:1938–1950. PMID:23877860
5. Celesia BM, Nigro L, Pinzone MR, Coco C, La Rosa R, Bisicchia F, Mavilla S, Gussio M, Pellicanò G, Milioni V, Palermo F, Russo R, Mughini MT, Martellotta F, Taibi R, Cacopardo B, Nunnari G. High prevalence of undiagnosed anxiety symptoms among HIV-positive individuals on cART: A cross-sectional study. *Eur Rev Med Pharmacol Sci.* 2013; 17:2040–2046. PMID:23884824
6. Scarpino M, Santoro M, Pellicanò G. HIV infection and kidney disease: literature review. *Infectious Diseases and Tropical Medicine.* 2015; 1:e195.
7. Facciola A, Venanzi Rullo E, Ceccarelli M, D'Aleo F, Di Rosa M, Pinzone MR, Condorelli F, Visalli G, Picerno I, Fisichella R, Nunnari G, Pellicanò GF. Kaposi's sarcoma in HIV-infected patients in the era of new antiretrovirals. *Eur Rev Med Pharmacol Sci.* 2017; 21:5868–5879. PMID:29272026
8. Montrucchio C, Biagini R, Alcantarini C, Calcagno A, Barco A, Ferrara M, Milesi M, Costa C, Trentalange A, Trunfio M, Tettoni MC, Grosso Marra W, D'Ascenzo F, Ballocca F, Lonni E, Gili S, Vai D, Imperiale D, Gaita F, Bonora S, Di Perri G. Cardiovascular risk and neurocognitive deficits in HIV-positive individuals. *Infect Dis Trop Med.* 2017; 3:e370.
9. Castronuovo D, Cacopardo B, Pinzone MR, Di Rosa M, Martellotta F, Schioppa O, Moreno S, Nunnari G. Bone disease in the setting of HIV infection: update and review of the literature. *Eur Rev Med Pharmacol Sci.* 2013; 17:2413–2419. PMID:24089217
10. Di Rosa M, Tibullo D, Vecchio M, Nunnari G, Saccone S, Di Raimondo F, Malaguarnera L. Determination of chitinases family during osteoclastogenesis. *Bone.* 2014; 61:55–63. <https://doi.org/10.1016/j.bone.2014.01.005> PMID:24440516
11. Visalli G, Bertuccio MP, Currò M, Pellicanò G, Sturniolo G, Carnevali A, Spataro P, Ientile R, Picerno I, Cavallari V, Piedimonte G. Bioenergetics of T cell activation and death in HIV type 1 infection. *AIDS Res Hum Retroviruses.* 2012; 28:1110–1118. <https://doi.org/10.1089/aid.2011.0197>
12. Pinzone MR, Nunnari G. Prevalence of comorbidities in a cohort of women living with HIV. *Infect Dis Trop Med.* 2015; 1:e165.
13. Kulkosky J, Bouhamdan M, Geist A, Nunnari G, Phinney DG, Pomerantz RJ. Pathogenesis of HIV-1 infection within bone marrow cells. *Leukemia and Lymphoma.* 2000; 37:497–515. <https://doi.org/10.3109/10428190009058502> PMID:11042510
14. Bellissimo F, Pinzone MR, Cacopardo B, Nunnari G. Diagnostic and therapeutic management of hepatocellular carcinoma. *World J Gastroenterol.* 2015; 21:12003–12021. <https://doi.org/10.3748/wjg.v21.i42.12003> PMID:26576088 PMID:PMC4641121
15. Nunnari G, Otero M, Dornadula G, Vanella M, Zhang H, Frank I, Pomerantz RJ. Residual HIV-1 disease in seminal cells of HIV-1 infected men on suppressive HAART: Latency without on-going cellular infections. *AIDS.* 2002; 16:39. <https://doi.org/10.1097/00002030-200201040-00006> PMID:11741161
16. D'Aleo F, Ceccarelli M, Venanzi Rullo E, Facciola A, Di Rosa M, Pinzone MR, Condorelli F, Visalli G, Picerno I, Berretta M, Pellicanò GF, Nunnari G. Hepatitis C-related hepatocellular carcinoma: diagnostic and therapeutic management in HIV-patients. *Eur Rev Med Pharmacol Sci.* 2017; 21:5859–5867. PMID:29272025
17. Squillace N, Pellicanò GF, Ricci E, Quirino T, Bonfanti P, Gori A, Bandera A, Carenzi L, De Socio GV, Orofino G, Martinelli C, Madeddu G, Rusconi S, Maggi P, Celesia BM, Cordier L, Vichi F, Calza L, Falasca K, Di Biagio A, Pellicanò GF, Bonfanti P. Safety and tolerability of Elvitegravir/Cobicistat/Emtricitabine/Tenofovir Disoproxil fumarate in a real life setting: Data from surveillance cohort long-term toxicity antiretrovirals/antivirals (SCOLTA) project. *PLoS ONE.* 2017; 12:e0179254. <https://doi.org/10.1371/journal.pone.0179254> PMID:28632758 PMID:PMC5478131
18. Pomerantz RJ, Nunnari G. HIV and GB Virus C - Can Two Viruses be Better Than One? *N Engl J Med.* 2004; 350:963–965. <https://doi.org/10.1056/NEJMp048004> PMID:14999105
19. Colafigli M, Bonadies A, Ferraresi V, Tonachella R, Cristaudo A, Latini A. Kaposi Sarcoma in HIV-infected patients: an infectious-dermatological outpatient service experience. *Infect Dis Trop Med.* 2017; 3:e410.
20. Ceccarelli G, Vassalini P, Corano Scheri G, Cavallari EN, Bianchi L, Di Girolamo G, Fratino M, Vullo V, D'Ettoire G. Improvement of neuropsychological performances and reduction of immune-activation markers after probiotic supplementation and change of life-style in an HIV positive male: targeting the microbiota to act on gut-brain axis. *Infect Dis Trop Med.* 2017; 3:e404.
21. Scarpino M, Pinzone MR, Di Rosa M, Madeddu G, Focà E, Martellotta F, Schioppa O, Ceccarelli G, Celesia BM, D'Ettoire G, Vullo V, Berretta S, Cacopardo B, Nunnari G. Kidney disease in HIV-infected patients. *Eur Rev Med Pharmacol Sci.* 2013; 17:2660–2667. PMID:24142615
22. Visalli G, Paiardini, Chirico C, Cervasi B, Currò M, Ferlazzo N, Bertuccio MP, Favaloro A, Pellicanò G, Sturniolo G, Spataro P, Ientile R, Picerno I, Piedimonte G. Intracellular accumulation of cell cycle regulatory proteins and nucleolin re-localization are associated with pre-lethal ultrastructural lesions in circulating T lymphocytes: The HIV-induced cell cycle dysregulation revisited. *Cell Cycle.* 2010; 9:2130–2140. <https://doi.org/10.4161/cc.9.11.11754> PMID:20505329
23. Trovato M, Ruggeri RM, Sciacchitano S, Vicchio TM, Picerno I, Pellicanò G, Valenti A, Visalli G. Serum interleukin-6 levels are increased in HIV-infected patients that develop autoimmune disease during long-term follow-up. *Immunobiology.* 2017.
24. Nunnari G, Coco C, Pinzone MR, Pavone P, Berretta M, Di Rosa M, Schnell M, Calabrese G, Cacopardo B. The role of micronutrients in the diet of HIV-1 infected individuals. *Front Biosci.* 2012; e4:2442–2456.
25. Castronuovo D, Pinzone MR, Moreno S, Cacopardo B, Nunnari G. HIV infection and bone disease: a review of the literature. *Infect Dis Trop Med.* 2015; 1:e116.
26. Malaguarnera M, Vacante M, Motta M, Giordano M, Malaguarnera G, Bella R, Nunnari G, Rampello L, Pennisi G. Acetyl-L-carnitine improves cognitive functions in severe hepatic encephalopathy: a randomized and controlled clinical trial. *Metabolic Brain Disease.* 2011; 26:281–289. <https://doi.org/10.1007/s11011-011-9260-z> PMID:21870121
27. Calcagno A, Simiele M, Alberione MC, Bracchi M, Marinaro L, Ecclesia S, Di Perri G, D'Avolio A, Bonora S. Cerebrospinal Fluid Inhibitory Quotients of Antiretroviral Drugs in HIV-Infected Patients Are Associated With Compartmental Viral Control. *Clin Infect Dis.* 2015; 60:311–317. <https://doi.org/10.1093/cid/ciu773> PMID:25281609
28. Pagliano P, Esposito S. Visceral leishmaniasis in immunocompromised host: an update and literature review. *J*

- Chemother. 2017; 29:261–266.
<https://doi.org/10.1080/1120009X.2017.1323150> PMID:28490252
29. Pagliano P, Ascione T, Di Flumeri G, Boccia G, De Caro F. Visceral leishmaniasis in immunocompromised: Diagnostic and therapeutic approach and evaluation of the recently released IDSA guidelines. *Infez Med*. 2016; 24:265. PMID:28011960
30. Madeddu G, Fiori ML, Ena P, Riu F, Lovigu C, Nunnari G, Bagella P, Maida I, Babudieri S, Mura MS. Mucocutaneous leishmaniasis as presentation of HIV infection in Sardinia, insular Italy. *Parasitol Int*. 2013; 63:35–36.
<https://doi.org/10.1016/j.parint.2013.10.002> PMID:24126182
31. de Sousa-Gomes ML, Romero GAS, Werneck GL. Visceral leishmaniasis and HIV/AIDS in Brazil: Are we aware enough? *PLoS Negl Trop Dis*. 2017; 11:e0005772.
<https://doi.org/10.1371/journal.pntd.0005772> PMID:28945816
PMCID:PMC5612457
32. Ezra N, Ochoa MT, Craft N. Human immunodeficiency virus and leishmaniasis. *J Glob Infect Dis*. 2010; 2:248–257.
<https://doi.org/10.4103/0974-777X.68528> PMID:20927287
PMCID:PMC2946682
33. Cota GF, de Sousa MR, de Assis TSM, Pinto BF, Rabello A. Exploring prognosis in chronic relapsing visceral leishmaniasis among HIV-infected patients: Circulating Leishmania DNA. *Acta Trop*. 2017; 172:186–191.
<https://doi.org/10.1016/j.actatropica.2017.05.011> PMID:28501450
34. Guarneri C, Tchernev G, Bevelacqua V, Lotti T, Nunnari G. The unwelcome trio: HIV plus cutaneous and visceral leishmaniasis. *Dermatol Ther*. 2016; 29:88–91. <https://doi.org/10.1111/dth.12303> PMID:26555699
35. Linee Guida Italiane sull'utilizzo dei farmaci antiretrovirali e sulla gestione diagnostico-clinica delle persone con infezione da HIV-1. <http://www.simit.org/medias/1047-Ig-hiv-2016-c17pubblicazioni2545allegato.pdf> Accessed 14 January 2018.
36. Lindoso JAL, Cunha MA, Queiroz IT, Moreira CHV. Leishmaniasis-HIV coinfection: current challenges. *HIV AIDS (Auckl)*. 2016; 8:147–156. <https://doi.org/10.2147/HIV.S93789> PMID:27785103
PMCID:PMC5063600
37. Cocuzza S, Strazzulla A, Pinzone MR, Cosentino S, Serra A, Caltabiano R, Lanzafame S, Cacopardo B, Nunnari G. Isolated laryngeal leishmaniasis in immunocompetent patients: an underdiagnosed disease. *Case Rep Infect Dis*. 2013; 2013:165409.
<https://doi.org/10.1155/2013/165409>
38. Chenoweth CE, Singal S, Pearson RD, Betts RF, Markovitz DM. Acquired Immunodeficiency Syndrome-Related Visceral Leishmaniasis Presenting in a Pleural Effusion. *Chest*. 1993; 103:648-649. <https://doi.org/10.1378/chest.103.2.648> PMID:8432183
39. Aronson N, Herwaldt BL, Libman M, Pearson R, Lopez-Velez R, Weina P, Carvalho EM, Ephros M, Jeronimo S, Magill A. Diagnosis and Treatment of Leishmaniasis: Clinical Practice Guidelines by the Infectious Diseases Society of America (IDSA) and the American Society of Tropical Medicine and Hygiene (ASTMH). *Clin Infect Dis*. 2016; 63:e202–e264.
<https://doi.org/10.1093/cid/ciw670> PMID:27941151
40. Strazzulla A, Cocuzza S, Pinzone MR, Postorino MC, Cosentino S, Serra A, Cacopardo B, Nunnari G. Mucosal leishmaniasis: an underestimated presentation of a neglected disease. *Biomed Res Int*. 2013; 2013:805108.
<https://doi.org/10.1155/2013/805108> PMID:23853773
PMCID:PMC3703408
41. Khadem F, Uzonna JE. Immunity to visceral leishmaniasis: implications for immunotherapy. *Future Microbiol*. 2014; 9:901–915. <https://doi.org/10.2217/fmb.14.43> PMID:25156379
42. Santos-Oliveira JR, Giacoia-Gripp CBW, de Oliveira PA, Amato VS, Lindoso JÂL, Goto H, Oliveira-Neto MP, Mattos MS, Grinsztejn B, Morgado MG, Da-Cruz AM. High levels of T lymphocyte activation in Leishmania-HIV-1 co-infected individuals despite low HIV viral load. *BMC Infect Dis*. 2010; 10:358.
<https://doi.org/10.1186/1471-2334-10-358> PMID:21171992
PMCID:PMC3022832
43. Celesia BM, Cacopardo B, Massimino D, Gussio M, Tosto S, Nunnari G, Pinzone MR. Atypical Presentation of PKDL due to Leishmania infantum in an HIV-Infected Patient with Relapsing Visceral Leishmaniasis. *Case Rep Infect Dis*. 2014; 2014:370286.
44. Lu W, Mehraj V, Vyboh K, Cao W, Li T, Routy J-P. CD4:CD8 ratio as a frontier marker for clinical outcome, immune dysfunction and viral reservoir size in virologically suppressed HIV-positive patients. *J Int AIDS Soc*. 2015; 18:20052.
<https://doi.org/10.7448/IAS.18.1.20052> PMID:26130226
PMCID:PMC4486418