

Mucoepidermoid Carcinoma (MEC) of Parotid Gland with Massive Cutaneous Involvement: Bilateral Pedicle Advancement Flap (U - Plasty) As Adequate Surgical Approach

Ilia Lozev¹, Sonya Ruseva², Ivan Pidakev¹, José Carlos Cardoso³, Uwe Wollina⁴, Torello Lotti⁵, Georgi Konstantinov Maximov², Ivan Terziev⁶, Georgi Tchernev^{1,7*}

¹Medical Institute of Ministry of Interior Department of General, Vascular and Abdominal Surgery, Sofia, Bulgaria; ²"Onkoderma" - Polyclinic for Dermatology, Venereology and Dermatologic Surgery, Sofia, Bulgaria; ³Dermatology Department, Coimbra Hospital and University Center, Praceta Mota Pinto, Coimbra, Portugal; ⁴Städtisches Klinikum Dresden - Department of Dermatology and Allergology, Dresden, Sachsen, Germany; ⁵University G. Marconi of Rome - Dermatology and Venereology, Rome, Italy; ⁶Department of Common and Clinical Pathology, University Hospital Tsaritsa Ioana, Sofia, Bulgaria ⁷Medical Institute of Ministry of Interior Department of General, Vascular and Abdominal Surgery, Sofia, Bulgaria

Abstract

Citation: Lozev I, Ruseva S, Pidakev I, Cardoso JC, Wollina U, Lotti, Maximov GK, Terziev I, Tchernev G. Mucoepidermoid Carcinoma (MEC) of Parotid Gland with Massive Cutaneous Involvement: Bilateral Pedicle Advancement Flap (U - Plasty) As Adequate Surgical Approach. Open Access Maced J Med Sci. 2018 Jan 25; 6(1):134-136. <https://doi.org/10.3889/oamjms.2018.014>

Keywords: mucoepidermoid ca; carcinoma; U plasty; radiation; outcome

***Correspondence:** Georgi Tchernev. Department of Dermatology, Venereology and Dermatologic Surgery, Medical Institute of Ministry of Interior (MVR-Sofia), General Skobelev 79, 1606 Sofia, Bulgaria; Onkoderma - Polyclinic for Dermatology, Venereology and Dermatologic Surgery, General Skobelev 26, 1606, Sofia, Bulgaria. E-mail: georgi_tchernev@yahoo.de

Received: 30-Aug-2017; **Revised:** 02-Sep-2017; **Accepted:** 19-Oct-2017; **Online first:** 13-Jan-2018

Copyright: © 2018 Ilia Lozev, Sonya Ruseva, Ivan Pidakev, José Carlos Cardoso, Uwe Wollina, Torello Lotti, Georgi Konstantinov Maximov, Ivan Terziev, Georgi Tchernev. This is an open-access article distributed under the terms of the Creative Commons Attribution-NonCommercial 4.0 International License (CC BY-NC 4.0)

Funding: This research did not receive any financial support

Competing Interests: The authors have declared that no competing interests exist

Neoplasms of the major and minor salivary glands are morphologically and a clinically diverse group of neoplasms which lead the clinician to diagnostic and management challenges. This article aims to report a case of mucoepidermoid carcinoma in 83 – year - old woman who presented in the dermatology clinic with a tumour mass in the left auricular area. The patient complained of pain and abnormal bleeding of the mass. The lesion was examined, and surgical treatment was performed. A tumour was extirpated, and partial resection of both the parotid gland and the sternocleidomastoid muscle was done. Lymphatic dissection was performed. Post recovery was uneventful with no functional defects and abnormalities. The pathohistological result confirmed the diagnosis of mucoepidermoid carcinoma of the parotid gland with massive infiltration of the skin and the subcutaneous tissue. Lymph nodules with total metastasis of mucoepidermoid carcinoma and capsular invasion were additionally presented. Postoperative radiation therapy was planned.

Introduction

Cancers of salivary glands are rare malignancies. They represent only 5% of all head and neck malignancies [1]. The most common cancer among salivary glands' tumours and especially the major salivary glands is the mucoepidermoid carcinoma of the parotid gland (75%) [2] Mucoepidermoid carcinoma is a malignant epithelial neoplasm [2]. It is composed of multiple cell types

which include: epidermoid cells, mucous producing cells and intermediate type cells [3]. It presents with a prominent cystic growth. Based on its histology characteristics, including the cell types, cellular differentiation, growth and invasion, cytologic atypia, mucoepidermoid carcinoma are graded as low, intermediate or high grade [3]. It is more common in women than men and usually affects women in their fifth decade [4].

Also, it is thought that there is a clear predilection for white race [5]. Little is known about the

aetiology of mucoepidermoid carcinoma, but low-dose radiotherapy used for benign diseases as acne and obstructive lesions of the lymphoid tissue is probably involved in its pathogenesis [5].

Case report

We report a case of an 83 – year - old female patient with a painful and easily bleeding mass in the left auricular area present for one year. The lesion was examined preoperatively, and surgical management was planned. Patient history included: arterial hypertension. On physical examination: a firm five/ 5cm mass was palpated in the left auricular region. The mass was painful and easily bleeding by touch (Fig. 1a).

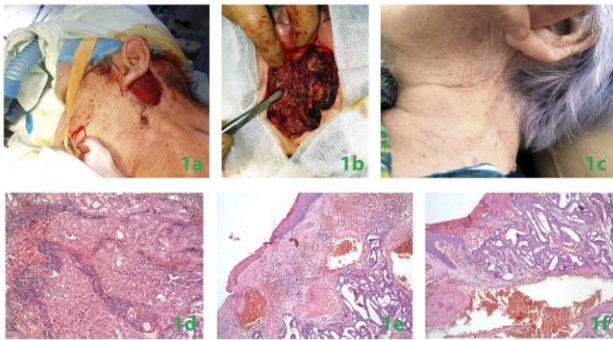


Figure 1: A - Preoperative aspect before the excision of the tumor; B - Intraoperative aspect after the excision of the tumor; C - Immediate post-operative result; D - Lobules of cells with abundant eosinophilic cytoplasm with one focus of keratinization (on the left) representing one area of squamous differentiation; multiple areas of ductal and glandular differentiation are also seen; E - Detail of the tumour in the the superficial reticular dermis in an area of glandular differentiation composed of multiple interconnected lumina lined by smaller cells with more scant cytoplasm than those seen in the squamous areas

No lymphadenopathy was clinically detected. The results of routine blood tests were within normal ranges. General anaesthesia was performed. After cleaning and disinfection of the surgical field, an incision was performed. The cutaneous incision was made preauricular near the mandibular border, and the tumour was surrounded by healthy tissue. Tumor extirpation and partial resection of the parotid gland has been performed. After hemostasis, a platysma myocutaneous flap was made. The mandibular ramus of the facial nerve in the area of the posterior facial vein was reached and after that following the pathway of the mandibular nerve the main trunk of the facial nerve was reached (Fig 1b).

Once the main trunk of the facial nerve was exposed, the tumour mass was completely extirpated, and both the sternocleidal muscle and the parotid gland were partially resected because of the massive

tumour infiltration. The neoplasm was extirpated with reached negative surgical borders using the bilateral pedicle advancement flap. Two pathologically changed lymph nodules in the area of the digastricus muscle were removed. After partial removal of the superficial parotid gland and the tumour, the cut surface of the parotid remnant was sutured. Hemostasis was achieved. The subcutaneous tissue and the skin incision were closed. Closed suction drainage was maintained. A thin layer of gauze was placed on the wound. The sutures were removed ten days after the operation.

Discussion

Histologically, MEC is a tumour composed of three types of cells: epidermoid, mucous producing and intermediate cells [3][4][5]. Based on its histological findings it is classified as low, intermediate or a high-grade tumour [5]. Low grade and intermediate grade appear as well - demarcated with pushing margins, but in difference, the intermediate one more often presents with a perineural invasion [5].

High-grade tumours are being characterised by the infiltrative border, diverse of cell abnormalities as anaplasia, necrosis and atypical mitoses and invasion: perineural and angiolymphatic [5].

MEC of the parotid gland clinical manifestation includes very often asymptomatic swelling [5]. There is an average latency period which is one year or may vary widely [6].

All grade of MEC is treated with surgical resection as a definitive treatment [5][6][7][8][9]. A low and intermediate grade of tumours often undergoes primary surgical excision [5][6][7][8][9][10]. High-grade tumours treatment course includes surgical excision with wide margins followed by radiotherapy [5][6][7][8][9][10]. Neck dissection is necessary if there are local metastasis as in our case [5][6][7][8][9][10]. It is known that low-grade tumours behave with more benign nature and the high grade are highly aggressive [6][7]. Intermediate grade presents more like a low grade, but they should be treated as high grade because they demonstrate predilection to nodal metastasis like the high-grade tumours [6][7].

Prognosis depends on three main factors: clinical stage, histological grade and treatment [6]. Distant MEC metastases relate to a poor prognosis [3]. The survival rate for patients with distant metastases is 2.3 - 2.6 years [3].

The differential diagnoses spectrum is wide and includes necrotising sialometaplasia, mucocele, inverted papilloma or cystadenoma, cystadenocarcinoma, primary or metastatic epidermoid carcinoma, and low-grade polymorphic

adenocarcinoma [6].

It seems that genetic factors of MEC appear to do not have a prognostic meaning [3]. Many MEC's have been reported in cytogenetical analyses to have the t(11:19), (q21 p13.1) translocation [3]. Immunological factors like a high proliferating cell nuclear antigen score lead to a less surviving percentage of the patients [11].

Post-operative radiotherapy has been shown to have an advantage in the survival of patients with tumours larger than 4 cm, and it is not shown as it for patients with smaller tumours [5]. Post-operative radiotherapy is indicated in patients with tumours which are larger than 4 cm [5].

MEC is a challenge to the clinicians because of its biological behaviour [7]. In our clinical case, we present one of its many different behaviours. As firstly, it was assumed as a cutaneous tumour involving the parotid gland, but it turned out to be the opposite like MEC of the parotid gland with massive infiltration in the skin of the head.

However, cutaneous metastases occur in 0.7 - 10 % of all patients with cancer [12]. ¼ of these percentages is for the skin of the head and neck [12]. Any malignant neoplasm could have potential to metastasize to the head and neck [12].

Patients who were treated with MEC should be followed up closely for life to prevent late recurrence [13]. The morphological manifestation of MEC has some similarities with clear cell bronchogenic squamous carcinoma [14]. The cell proliferation is important criteria for measuring the MEC aggressiveness [14].

In conclusion, mucoepidermoid carcinoma is the most common malignant tumour of the salivary glands. It is a challenge to the clinicians and especially for the dermatologists. According to the literature, it apperas to be a treatable disease. The prognosis is in a great relation on not only the tumor stage, but also the histological grade of the lesion.

References

1. Ho K, Lin H, Yen Chu and Y. An overview of the rare parotid gland cancer. *Head and Neck Oncol.* 2011; 3(1):40. <https://doi.org/10.1186/1758-3284-3-40> PMID:21917153
PMCID:PMC3197557

2. Kofi D, Boahene O, Olsen K, Lewis J. Mucoepidermoid Carcinoma of the parotid gland. *Arch Otolaryngol. Head Neck Surg.* 2004; 130(7):849 - 856. <https://doi.org/10.1001/archotol.130.7.849> vPMid:15262762
3. Luna MA. Salivary mucoepidermoid carcinoma: revisited. *Adv Anat Pathol.* 2006; 13:293 - 307. <https://doi.org/10.1097/01.pap.0000213058.74509.d3> PMID:17075295
4. Kokemueller H, Brueggemann N, Swennen G, Eckardt A. Mucoepidermoid carcinoma of the salivary glands, clinical review of 42 cases. *Oral Oncol.* 2005; 41(3):10. <https://doi.org/10.1016/j.oraloncology.2004.01.017>
5. Guevara-Canales J, Morales-Vadillo R, Guzman-Arias G, Cava - Vergiu C, Guerra - Miller H, Montes- Gil J. Mucoepidermoid carcinoma of the salivary glands. A retrospective study of 51 cases and review of the literature. *Acta Odontol Latinoam.* 2016; 29(3):230 - 238. PMID:28383603
6. Nance MA, Seethala RR, Wang Y, Chiosea SI, Myers EN, Johnson JT, Lai SY. Treatment and survival outcomes based on histologic grading in patients with head and neck mucoepidermoid carcinoma. *Cancer.* 2008; 113(8):2082 - 9. <https://doi.org/10.1002/cncr.23825> PMID:18720358
PMCID:PMC2746751
7. Darling R, McCammon S, Resto V, Quin F. Carcinoma in head and neck. Grand Rounds Presentation, The University of Texas Medical Branch at Galveston, Department of Otolaryngology. 2014; 5: 1 - 10.
8. Arrangoiz R, Papavasiliuo P, Sarcu D, Galloway T, Ridge J, Lango M. *Journal of Cancer Treatment and Research.* Current thinking on malignant salivary gland neoplasms. 2013; 1(1):8 - 24.
9. Olsen M, Mitchell A, Milles E. Postoperative Radiation Therapy for Parotid Mucoepidermoid Cancer. *Case Rep Oncol Med.* 2014; 1 - 4. <https://doi.org/10.1155/2014/345128> PMID:25580323
PMCID:PMC4279126
10. Kaszuba SM, Zafereo ME, Rosenthal DI, El -Naggar AK, Weber RS. Effect of initial treatment on disease outcome for patients with submandibular gland carcinoma. *Arch Otolaryngol Head Neck Surg.* 2007; 133(6):546 - 50. <https://doi.org/10.1001/archotol.133.6.546> PMID:17576904
11. Frankenthaler RA, El-Naggar AK, Ordonez NG. High correlation with survival of proliferating nuclear antigen expression in mucoepidermoid carcinoma of the parotid gland. *Otolaryngol Head Neck Surg.* 1994; 11:460 - 466. <https://doi.org/10.1177/019459989411100412> PMID:7936679
12. Barnes L. Metastases to the Head and Neck: an overview. *Head and Neck Pathol.* 2009; 3(3):217 - 224. <https://doi.org/10.1007/s12105-009-0123-4> PMID:20596975
PMCID:PMC2811631
13. Yook JI, Lee SA, Chun YC, Huh J, Cha IH, Kim J. The myoepithelial cell differentiation of mucoepidermoid carcinoma in a collagen gel-based coculture model. *J Oral Pathol Med.* 2004; 33:237 - 42. <https://doi.org/10.1111/j.0904-2512.2004.00056.x> PMID:15061712
14. Purohit J, Desai V, Sharma R, Sharma A. Mucoepidermoid carcinoma of parotid gland: A case report. 2015; 2(2):106 -109.