

# Segmental Erythema Multiforme-Like Drug Eruption by Aromatase Inhibitor Anastrozole – First Case Report and another Example of an Immunocompromised District

Uwe Wollina<sup>1\*</sup>, Jacqueline Schönlebe<sup>2</sup>, Birgit Heinig<sup>3</sup>, Georgi Tchernev<sup>4,5</sup>, Katlein França<sup>6</sup>, Torello Lotti<sup>7</sup>

<sup>1</sup>Department of Dermatology and Allergology, Städtisches Klinikum Dresden, Friedrichstrasse 41, 01067 Dresden, Germany; <sup>2</sup>Städtisches Klinikum Dresden - Institute of Pathology "Georg Schmorl", Dresden, Germany; <sup>3</sup>Städtisches Klinikum Dresden - Center of Physical and Rehabilitative Medicine, Dresden, Germany; <sup>4</sup>Department of Dermatology, Venereology and Dermatologic Surgery, Medical Institute of Ministry of Interior, Sofia, Bulgaria; <sup>5</sup>Onkoderma Policlinic for Dermatology and Dermatologic Surgery, Sofia, Bulgaria; <sup>6</sup>Department of Dermatology and Cutaneous Surgery, Department of Psychiatry & Behavioral Sciences; Institute for Bioethics and Health Policy, University of Miami Miller School of Medicine, Miami, FL, USA; <sup>7</sup>Università Degli Studi "G. Marconi", Rome, Italy

## Abstract

**Citation:** Wollina U, Schönlebe J, Heinig B, Tchernev G, França K, Lotti T. Segmental Erythema Multiforme-Like Drug Eruption by Aromatase Inhibitor Anastrozole – First Case Report and another Example of an Immunocompromised District. Open Access Maced J Med Sci. <https://doi.org/10.3889/oamjms.2018.026>

**Keywords:** Erythema multiforme; Adverse skin reaction; Aromatase inhibitors; Anastrozole; Breast cancer

**\*Correspondence:** Uwe Wollina, Department of Dermatology and Allergology, Städtisches Klinikum Dresden, Friedrichstrasse 41, 01067 Dresden, Germany. E-mail: [wollina-uw@khdf.de](mailto:wollina-uw@khdf.de)

**Received:** 25-Aug-2017; **Revised:** 07-Sep-2017; **Accepted:** 29-Sep-2017; **Online first:** 03-Jan-2018

**Copyright:** © 2018 Uwe Wollina, Jacqueline Schönlebe, Birgit Heinig, Georgi Tchernev, Katlein França, Torello Lotti. This is an open-access article distributed under the terms of the Creative Commons Attribution-NonCommercial 4.0 International License (CC BY-NC 4.0)

**Funding:** This research did not receive any financial support

**Competing Interests:** The authors have declared that no competing interests exist

Anastrozole is a non-selective aromatase inhibitor for adjuvant breast cancer therapy in postmenopausal women. Cutaneous adverse events have been reported. We observed a 64-year-old female patient with a medical history of locally advanced breast cancer of her right breast that was treated with radiotherapy and adjuvant drug therapy with anastrozole. She developed a segmental bullous eruption limited to the cancer-affected breast. Cessation of the aromatase inhibitor and systemic therapy with prednisolone cleared the lesions completely. This is the first report of a segmental erythema multiforme like drug eruption by anastrozole and another example of the concept of the immunocompromised district of skin.

## Introduction

Anastrozole is a non-selective aromatase inhibitor approved for adjuvant treatment of early-stage, hormone receptor-positive breast cancer in postmenopausal women or for women after adjuvant tamoxifen therapy for breast cancer. The compound is more effective than tamoxifen in the reduction of breast cancer relapse after surgery. Studies demonstrated that overall survival with anastrozole was better than with tamoxifen [1][2]. The most important adverse effects are an increased risk of bone fractures and myalgia/arthralgia. Other adverse events include fatigue, diarrhoea, xerostomia,

xerophthalmia, and head ache. Dry skin, alopecia, pruritus, allergic reactions, skin rash, and acne have also been reported [3][4].

We report unusual, localised, cutaneous side effects of anastrozole.

## Case report

A 64-year-old female patient was referred to us for localised skin blisters on her right breast.

Her medical history was positive for an invasive lobular breast cancer with a diffuse infiltration of the pectoralis muscle (May 2015), pT4a, pN0, M0, L0, V0, Pn0, Rx, G2. She had been treated with radiotherapy and docetaxel. Since March 2016, she had been treated with aromatase inhibitor anastrozole. First skin eruptions occurred in August 2016. A skin biopsy at that time excluded both malignancy and an autoimmune bullous disease. One week before the first presentation to the Department of Dermatology and Allergology, larger hemorrhagic blisters developed with a maximum diameter of 5 cm.

On examination, the breast was edematous, slightly erythematous (Fig. 1 a-c). No palpable lymph nodes were found. Diagnostic ultrasound of axillary, supra- and infraclavicular lymph nodes and abdomen remained unremarkable.

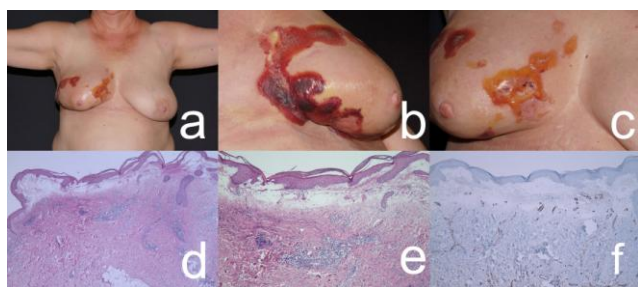


Figure 1: (a) Segmental erythema multiforme-like eruption due to anastrozole; (b) and (c) details with bullous, partly hemorrhagic eruptions; (d-f) histopathology; (d) overview (Hematoxylin-eosin, x2); (e) Detail with massive subepidermal edema and inflammatory infiltrate (hematoxylin-eosin, x4); (f) absence of atypical vascular proliferations (CD34, immunoperoxidase, x2)

Microbiology from blister fluid demonstrated minimal amounts of *Acinetobacter ursingii*, *Moxarella osloensis*, *Staphylococcus capitis*, and coagulase-negative *Staphylococci*.

Routine laboratory investigations revealed no signs of inflammation. C-reactive protein was 1.8 mg/L (normal range < 5 mg/L).

The blister fluid was subjected to cytological analysis. No malignant cells were identified. A skin biopsy was taken. A massive subepidermal oedema was observed with a superficial perivascular, and interstitial lymphomonocytic inflammatory infiltrate (Fig. 1d,e). Atypical vascular proliferations could be excluded by immunohistochemistry (CD31 and CD34) (Fig. 1 f).

The final diagnosis of erythema multiforme-like skin eruption due to anastrozole was confirmed.

The patient was treated initially with 100 mg prednisolone and 20 mg pantoprazole per day. Prednisolone was tapered down. For topical treatment, bethametasone/ fusidic acid ointment was applied. The blisters healed and oedema regressed. A medical bra was subscribed. Close follow-up was advised since aromatase inhibitor therapy was ceased.

## Discussion

Anastrozole is a non-selective aromatase inhibitor for the adjuvant treatment of breast cancer. Skin rash, pruritus and dry skin have been reported to occur in 10%, 10%, and 2% respectively [2].

Rare cutaneous adverse events are lichen sclerosus vulvae, erythema nodosum, subacute cutaneous lupus erythematosus, micropapular pruritic eruption, and cutaneous vasculitis [6][7][8][9].

Our patient presented with hemorrhagic bullae in a segmental arrangement, localised only to the breast that was affected by breast cancer and exposed to radiotherapy before. The histological diagnosis was an erythema multiforme-like eruption.

Erythema multiforme is a mucocutaneous hypersensitivity reaction showing varying degrees of blistering and ulceration. The aetiology includes herpes simplex virus and other infections, food additives, and drugs. Genetic factors can predispose individuals to severe drug reactions [10][11].

Anastrozole is known to induce cutaneous adverse events, but why was the eruption limited to the right breast? The explanation comes from the concept of immunocompromised districts of skin [12]. The immunocompromised district of skin is an area more vulnerable than the rest of the body mainly due to a local dysregulation of skin associated immune system. Several possible factors can be responsible for this, but radiotherapy and lymphedema are definitively involved in the present case. Another case was reported in the literature, with disseminated erythema multiforme after radiotherapy and anastrozole therapy [13].

For differential diagnosis, cutaneous lymphomas [14], atypical pityriasis rosea [15], bullous pemphigoid [16], and lupus erythematosus [17] must be considered. Histopathology and immune serology allow differentiation.

To the best of our knowledge, this is the first report on segmental bullous erythema multiforme-like drug eruption to anastrozole.

## References

- Sanford M, Plosker GL. Anastrozole: a review of its use in postmenopausal women with early-stage breast cancer. *Drugs*. 2008; 68(9):1319-40. <https://doi.org/10.2165/00003495-200868090-00007> PMID:18547136
- Cristofanilli M, Valero V, Mangalik A, Royce M, Rabinowitz I, Arena FP, Kroener JF, Curcio E, Watkins C, Bacus S, Cora EM, Anderson E, Magill PJ. Phase II, randomised trial to compare anastrozole combined with gefitinib or placebo in postmenopausal women with hormone receptor-positive metastatic breast cancer. *Clin Cancer Res*. 2010; 16(6):1904-14. <https://doi.org/10.1158/1078-0432.CCR-09-2282> PMID:20215537

3. Moscetti L, Agnese Fabbri M, Sperduti I, Fabrizio N, Frittelli P, Massari A, Pompei L, D'Auria G, Pofi E, Ruggeri EM. Adjuvant aromatase inhibitor therapy in early breast cancer: what factors lead patients to discontinue treatment? *Tumori*. 2015; 101(5):469-73. <https://doi.org/10.5301/tj.5000376> PMID:26108239
4. Tryfonidis K, Basaran G, Bogaerts J, Debled M, Dirix L, Thery JC, Tjan-Heijnen VC, Van den Weyngaert D, Cufer T, Piccart M, Cameron D; EORTC-Breast Cancer Group. A European Organisation for Research and Treatment of Cancer randomized, double-blind, placebo-controlled, multicentre phase II trial of anastrozole in combination with gefitinib or placebo in hormone receptor-positive advanced breast cancer (NCT00066378). *Eur J Cancer*. 2016; 53:144-54. <https://doi.org/10.1016/j.ejca.2015.10.012> PMID:26724641
5. Shoda H, Inokuma S, Yajima N, Tanaka Y, Setoguchi K. Cutaneous vasculitis developed in a patient with breast cancer undergoing aromatase inhibitor treatment. *Ann Rheum Dis*. 2005; 64(4):651-2. <https://doi.org/10.1136/ard.2004.023150> PMID:15769928 PMCID:PMC1755449
6. Jhaveri K, Halperin P, Shin SJ, Vahdat L. Erythema nodosum secondary to aromatase inhibitor use in breast cancer patients: case reports and review of the literature. *Breast Cancer Res Treat*. 2007; 106(3):315-8. <https://doi.org/10.1007/s10549-007-9518-7> PMID:17972174
7. Wong M, Grossman J, Hahn BH, La Cava A. Cutaneous vasculitis in breast cancer treated with chemotherapy. *Clin Immunol*. 2008; 129(1):3-9. <https://doi.org/10.1016/j.clim.2008.07.001> PMID:18640073 PMCID:PMC2579274
8. Bremec T, Demsar J, Luzar B, Pavlović MD. Drug-induced pruritic micropapular eruption: anastrozole, a commonly used aromatase inhibitor. *Dermatol Online J*. 2009; 15(7):14. PMID:19903442
9. Santoro S, Santini M, Pepe C, Tognetti E, Cortelazzi C, Ficarelli E, De Panfilis G. Aromatase inhibitor-induced skin adverse reactions: exemestane-related cutaneous vasculitis. *J Eur Acad Dermatol Venereol*. 2011; 25(5):596-8. <https://doi.org/10.1111/j.1468-3083.2010.03803.x> PMID:21492245
10. Wolf R, Orion E, Marcos B, Matz H. Life-threatening acute adverse cutaneous drug reactions. *Clin Dermatol*. 2005; 23(2):171-81. <https://doi.org/10.1016/j.clindermatol.2004.06.012> PMID:15802211
11. Su SC, Hung SI, Fan WL, Dao RL, Chung WH. Severe cutaneous adverse reactions: The pharmacogenomics from research to clinical implementation. *Int J Mol Sci*. 2016;17(11). pii: E1890.
12. Ruocco V, Ruocco E, Piccolo V, Brunetti G, Guerrero LP, Wolf R. The immunocompromised district in dermatology: A unifying pathogenic view of the regional immune dysregulation. *Clin Dermatol*. 2014; 32(5):569-76. <https://doi.org/10.1016/j.clindermatol.2014.04.004> PMID:25160098
13. Nakatani K, Matsumoto M, Ue H, Nishioka A, Tanaka Y, Kodama H, Sasaguri S, Ogawa Y. Erythema multiforme after radiotherapy with aromatase inhibitor administration in breast-conservation treatment for breast cancer. *Breast Cancer*. 2008; 15(4):321-3. <https://doi.org/10.1007/s12282-008-0041-4> PMID:18278432
14. Aiempanakit K, Amatawet C, Chiratikarnwong K, Auepemkiate S, Kayasut K, Suwiwat S, Apinatriyo B. Erythema multiforme-like cutaneous lesions in monomorphic epitheliotropic intestinal T-cell lymphoma: a rare case report. *J Cutan Pathol*. 2017; 44(2):183-88. <https://doi.org/10.1111/cup.12864> PMID:27862162
15. Das A, Sarkar TK, Chandra S, Ghosh A, Gharami RC. A case series of erythema multiforme-like pityriasis rosea. *Indian Dermatol Online J*. 2016; 7(3):212-5. <https://doi.org/10.4103/2229-5178.182374> PMID:27294066 PMCID:PMC4886603
16. Imberón-Moya A, Aguilar A, Burgos F, Gallego MÁ. Erythema multiforme-like bullous pemphigoid. *Actas Dermosifiliogr*. 2016; 107(8):689-91. <https://doi.org/10.1016/j.ad.2016.02.008> PMID:27048923
17. Wollina U, Hein G. Lupus erythematosus: uncommon presentations. *Clin Dermatol*. 2005; 23(5):470-9. <https://doi.org/10.1016/j.clindermatol.2005.01.017> PMID:16179181