

The Effect of Vascular Graft and Human Umbilical Cord Blood-Derived CD34+ Stem Cell on Peripheral Nerve Healing

Ali Yilmaz¹, Abdullah Topcu¹, Cagdas Erdogan², Barbaros Sahin³, Gulcin Abban⁴, Erdal Coskun⁵, Ayca Ozkul^{1*},

¹Adnan Menderes University, Neurosurgery Department, Aydin, Turkey; ²Pamukkale University, Neurology Department, Denizli, Turkey; ³University Medicine Faculty, Animal Laboratory, Denizli, Turkey; ⁴Pamukkale University Medicine Faculty, Histology and Embryology Department, Denizli, Turkey; ⁵Pamukkale University, Medicine Faculty, Neurosurgery Department, Denizli, Turkey

Abstract

Citation: Yilmaz A, Topcu A, Erdogan C, Bir LS, Sahin B, Abban G, Ozkul A, The Effect of Vascular Graft and Human Umbilical Cord Blood-Derived CD34+ Stem Cell on Peripheral Nerve Healing. Open Access Maced J Med Sci. <https://doi.org/10.3889/oamjms.2018.417>

Keywords: Human umbilical cord blood; Stem cell; CD34+; Peripheral nerve injury; Healing

***Correspondence:** Ayca Ozkul, Adnan Menderes University, Aydin, Turkey. E-mail: ozkulayca@hotmail.com

Received: 17-Dec-2017; **Revised:** 10-Sep-2018; **Accepted:** 13-Oct-2018; **Online first:** 29-Oct-2018

Copyright: © 2018 Ali Yilmaz, Abdullah Topcu, Cagdas Erdogan, Levent Sinan Bir, Barbaros Sahin, Gulcin Abban, Erdal Coskun, Ayca Ozkul. This is an open-access article distributed under the terms of the Creative Commons Attribution-NonCommercial 4.0 International License (CC BY-NC 4.0)

Funding: This research did not receive any financial support

Competing Interests: The authors have declared that no competing interests exist

AIM: There are many trials concerning peripheral nerve damage causes and treatment options. Unfortunately, nerve damage is still a major problem regarding health, social and economic issues. On this study, we used vascular graft and human cord blood derived stem cells to find an alternative treatment solution to this problem.

MATERIAL AND METHODS: We used 21 female Wistar rats on our study. They were anesthetized with ketamine and we studied right hind limbs. On Group 1, we did a full layer cut on the right sciatic nerve. On Group 2, we did a full layer cut on the right sciatic nerve, and we covered synthetic vascular graft on cut area. On Group 3, we did a full layer cut on right sciatic nerve, and we covered the area with stem cell applied vascular graft.

RESULTS: At the end of postoperative 8. weeks, we performed EMG on the rats. When we compared healthy and degenerated areas as a result of EMG, we found significant amplitude differences between the groups on healthy areas whereas there was no significant difference on degenerated areas between the groups. Then we re-opened the operated area again to reveal the sciatic nerve cut area, and we performed electron microscope evaluation. On the stem cell group, we observed that both the axon and the myelin sheet prevented degeneration.

CONCLUSION: This study is a first on using synthetic vascular graft and cord blood derived CD34+ cells in peripheral nerve degeneration. On the tissues that were examined with electron microscope, we observed that CD34+ cells prevented both axonal and myelin sheath degeneration. Nerve tissue showed similar results to the control group, and the damage was minimal.

Introduction

Direct nerve repair with epineural micro sutures is still the gold Standard surgical treatment for severe axonotmesis and neurotmesis injuries. Epineural repair is performed when a tension free coaptation, otherwise autologous nerve grafts are mainly used [1] [2]. These autologous nerve grafts provide structural support to guide axonal regeneration, preventing neuroma formation and fibrous tissue invasion. However, there are some disadvantages for autologous nerve grafts as a limited source of the nerve grafts, permanent loss of the

sensation at donor site [2]. Also, it may increase the donor site infection.

These problems bring out the need of new therapeutic approaches to nerve injury. An effective nervous construct may require some combination of three primary components. However, scaffolds' results are not better than an autograft [1].

Schwann cells (SCs) are peripheral glial cells that play a crucial role in the endogenous repair of the peripheral nervous system (PNS) by reconstructing myelin, which is necessary for functional recovery [3] [4]. For these reasons, SCs and Schwann-like cells are one of the most widely studied cells for axonal regeneration and functional repair in PNS. In these studies the stem cells obtained from many SCs or

Schwann-like cells' sources including human umbilical cord blood-derived stem cells (HUCB), adipose-derived stem cells, bone marrow-derived mesenchymal stem cells, and embryonic stem cells [3] [5] [6] [7] [8]. Although adipose-derived stem cells have been mainly used for PNS regeneration in previous studies, we preferred using HUCB CD34 positive (CD34+) stem cell because of its greater availability, weak immunogenicity, lower risk of graft-versus host diseases and pluripotent differentiation, besides HUCBSC raises far less ethical controversies than ESC [9] [10] [11] [12].

In this study our aim was to examine and compare the effects of HUCB CD34+ stem cell and synthetic graft on peripheral nerve healing in an experimentally induced sciatic nerve injury.

Material and Method

The study was carried out in Experimental Research Laboratory of Faculty of Medicine at Pamukkale University. Approval forms were taken from parents of newborns from whom cord blood was collected. All experiments were performed in accordance with the guidelines for care and local ethical regulations established by the National Institutes of Health. The study used six-month-old 210 ± 30 gram (gr) Sprague-Dawley female rats. The rats were kept at room temperature of $22 \pm 2^\circ\text{C}$ in 50% humid environment at 12:12 day/dark cycle during the experimental procedure. The subjects were divided into 3 groups. Group I: Control group ($n = 7$), sciatic nerve full thickness incision; Group II: vascular graft group ($n = 7$) sciatic nerve full thickness incision and covering lesion area with polytetrafluoroethylene (PTFE) type synthetic graft; Group III: stem cell group ($n = 7$) transplantation of HUCB-derived 3×10^4 CD34+ stem cell into sciatic full thickness incision and covering the lesion with PTFE synthetic graft.

All surgical interventions were carried out by the same surgeon using standard microsurgery methods on the sciatic nerve. Surgical operations were performed under anaesthesia by 50 mg/kg Ketamine-HCL (Alfamine®-im) and 9 mg/kg Ksilazin HCL (Rompun®-im) mixture. The subjects were kept at appropriate positions on special fixing boards for surgical intervention, and the operations were carried out under operation microscope (107 Series, Seiler Instrument, St. Louis, Missouri). Operation area (gluteal and femur region) was shaved and surgically cleaned with povidone-iodine. An oblique incision was made in the right lower extremity in such a way to follow hip joint movement removing the skin and reaching biceps femoralis muscle. Muscle tissue was opened by blunt dissection, and sciatic nerve was exposed. The right sciatic nerve was full thickness incised at 1 cm proximal of separation point of tibial

and peroneal nerves using microscissors. In all groups, right hind extremity was used for the study, while un-operated left hind extremity was kept as control.

Collection of newborn umbilical cord blood, separation of CD34+ stem cells and transplantation

A total of 50 ml of umbilical cord blood samples were collected from pregnant women who gave birth recently. It was seen that the umbilical cord taken was normal. Umbilical cord blood was taken from an umbilical vein using heparinised syringes immediately after leaving from newborn. Obtaining CD34+ stem cells by positive selection from the cord blood via using of Magnet (Magnet EasSep, StemCell Technologies) and magnetic nanoparticles (EasySep Magnetic nanoparticles 1ml, StemCell Technologies) was performed in 7 steps. The cells selected by position selection were treated with trypan blue and counted by hemocytometer under a light microscope. It was found that there were 3×10^4 cells in $2\mu\text{l}$.

Nerve tissue sections were kept in 5% glutaraldehyde solution prepared with Millonig's phosphate buffer for 1 hour and was dissected of 1 mm^3 on Petri covered with dental wax with glutaraldehyde on top using a razor. Tissue sections were again taken to glutaraldehyde solution and were fixed for 3 hours. The tissues were then shaken in Millonig's phosphate buffer for 10 minutes. After taking the tissues in Millonig's phosphate buffer for the second time, they were kept in the same tampon for a night. The next day, the tissues were fixed for a second time in 1% osmium tetroxide solution prepared with Millonig's phosphate buffer and were washed with phosphate tampon for 10 minutes 2 times. Dehydrated tissue sections were then immersed in propylene oxide+ embedding material for 30 minutes. Newly prepared embedding material in tissue sections was taken to tubes containing resin and was mixed in the rotator for a night. The next day, tissue sections were embedded into 00 polyethene capsules using freshly prepared embedding material and were polymerised at the 60°C incubator for 48 hours. The blocks were then removed from the incubator and let to cool. Cross-sections of 500 A° thickness were taken from the blocks using Reichert Ultracut ultramicrotome. The crosssections were collected in 200-300 meshed copper grids and stained with uranyl acetate saturated in 70% ethyl alcohol and Reynold's lead citrate solutions. Stained cross-sections were analyzed in Zeiss E.M. 10 B electron microscope.

In postoperative 8. Week, all rats were electrophysiologically evaluated using TecaMedelec Premiere Plus device. Active electrode was placed on gastrocnemius muscle of subjects, while the reference electrode was placed on Achilles tendon. Similar to the first surgical operation, the sciatic nerve was freed

from surrounding tissues, and sciatic nerve incision line was found. Nerve body was directly stimulated with monopolar Teflon-coated electrodes. During stimulation procedure, 10 mm distance was kept between active and reference stimulation electrodes. As stimulation points, the best possible distal and proximal points were selected in such a way to leave the repair line of nerve. The distance between proximal and distal stimulation points was measured with a caliper. Supra-maximal voltage was used for stimulation. Following the stimulation, the point where the first deviation from isoelectric line was marked as initial latency [millisecond (msn)]; peak point of axon was marked as peak latency [millisecond (msn)]; distance between positive and negative highest peaks was marked as amplitude [microvolt (μ V)]. Compound muscle action potentials recorded after stimulation first in distal than in proximal were overlapped. The transmission rate of action potentials between proximal and distal points; peak-peak amplitude and area in compound muscle action potential were calculated. Values in experimented right and healthy left (control) legs were statistically compared by computing experimental leg/control leg ratios.

SPSS for Windows (version 13.00) computer package program was used for statistical analysis. P value ≤ 0.05 was considered as significant. One-Sample Kolmogorov-Smirnov Test was used to test the suitability of data for normal distribution. It was found that data was fit for normal distribution. One Way ANOVA Test was used to compare data.

Results

Comparison of degenerate side latency and amplitude values in the three groups showed no statistically significant difference (Table 1 and 2). Comparison of intra-group health and degenerated side latency and amplitude values showed a statistically significant difference.

Table 1: EMG findings showing amplitude decrease in groups II and III with peripheral nerve injury

Groups	Healthy side amplitude values			Degenerated side amplitude values		
	X \pm SD	f	*p	X \pm SD	f	p
Group 1	26.42 \pm 7.11			23.14 \pm 7.92		
Group 2	25.85 \pm 7.33	0.012	0.988	12.28 \pm 9.06	3.723	0.044*
Group 3	26.28 \pm 7.06			16.14 \pm 5.08		

* Oneway ANOVA Test; SD: standard deviation.

Axon and myelin sheath degeneration was significant in lesion and untreated group (Group 1). In the majority of myelinated nerve fibres, the integration between axon and myelin sheath was lost, and gaps appeared. Myelin sheath was observed to be thicker than normal in some fibres; while the sheath was observed to be quite thin in others.

In nerve fibres with thick myelin, oedema between the fibres was increased creating gaps in the myelin sheath. In degenerated nerve fibres, myelin sheath lost its normal order parallel array and took a lamellar shape in some regions.

Table 2: EMG findings showing increased latency values in groups 2 and 3 with peripheral nerve injury without any statistically significant group

Groups	Healthy side Latency values			Degenerated side Latency Values		
	X \pm SD	f	p	X \pm SD	f	p
Group 1	1.22 \pm 0.94			1.33 \pm 0.55		
Group 2	1.20 \pm 0.67	0.256	0.777	1.55 \pm 0.20	2.461	0.114
Group 3	1.22 \pm 0.04			1.49 \pm 0.26		

* Oneway ANOVA Test; SD: standard deviation.

Nerve fibres with no myelin were significant in some regions Collagen fibres observed in latitudinal and longitudinal sections between the axons indicated an increase in connective tissue (Figure 1).

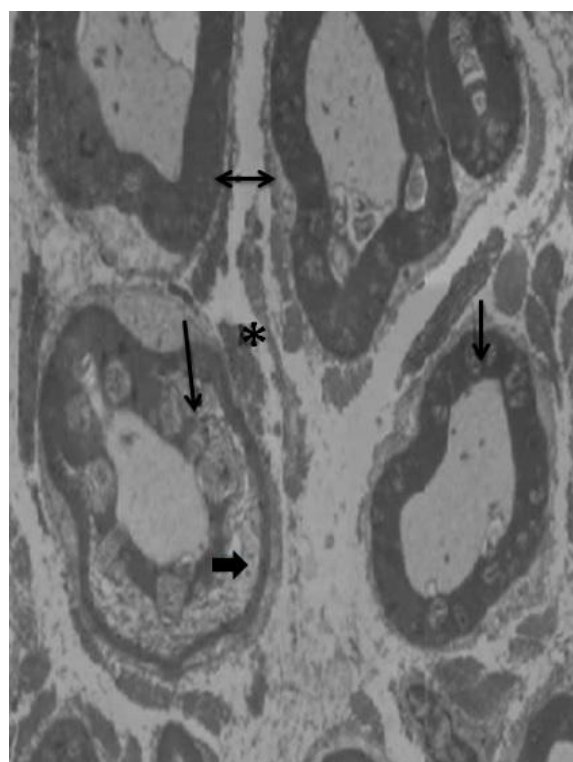


Figure 1: Electron microscopic image of the untreated group. Arrow: the abnormal appearance of the myelin sheath, thick arrow: myelin sheath openings star: astrocytes, double-headed arrow: a cross-section of collagen fibrils

In-lesion group with PTEF graft application (Group 2), it was observed that degeneration continued in myelin sheath and axons, however significantly decreased when compared to the untreated group. Gaps between the myelin sheath in the untreated group were found to decrease in group 3. Similarly, nerve fibres with thick myelin sheath observed in the untreated group were not observed in this group. On the other hand, connective tissue fibres and demyelinated nerve fibres were significant also in

this group. However they were relatively decreased (Figure 2).

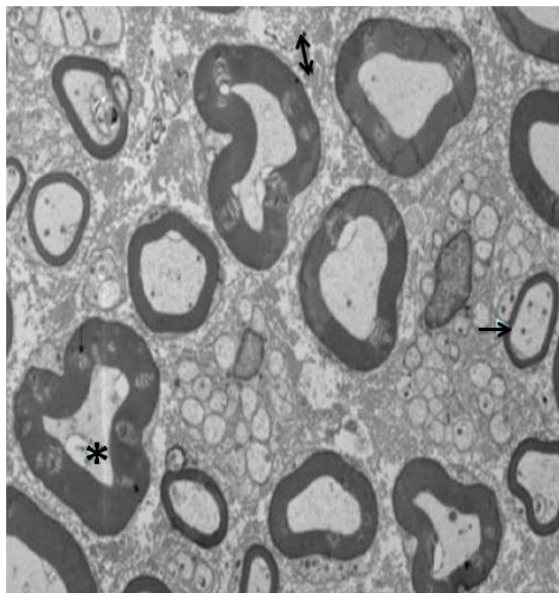


Figure 2: Electron microscopic image of vascular graft group. Arrow: the abnormal appearance of the myelin sheath, star: astrocytes, double-headed arrow: a cross-section of collagen fibrils

In the group with the lesion, PTEF graft and human cord blood-derived CD34⁺ stem cell (Group 3), general outlook was significantly positive than the group which was treated with vascular graft only. In this group, gaps observed between myelin sheath were lost. Nerve fibres began to take their normal look. Connective tissue fibres were very low in amount. Myelin coated nerve fibres and demyelinated nerve fibers were also visible in this group. Axonal degeneration was still present in some fibers, however pathological findings were significantly less found (Figure 3 and 4).

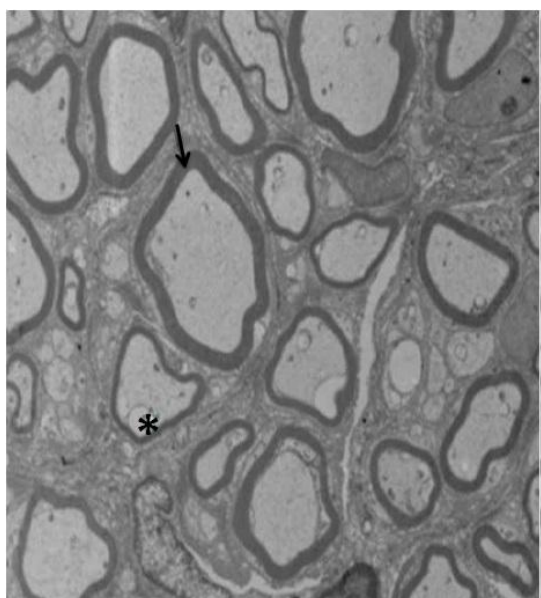


Figure 3: Electron microscopic image of vascular grafts and cord blood-derived stem cells group. Arrow: myelin sheath, star, astrocytes

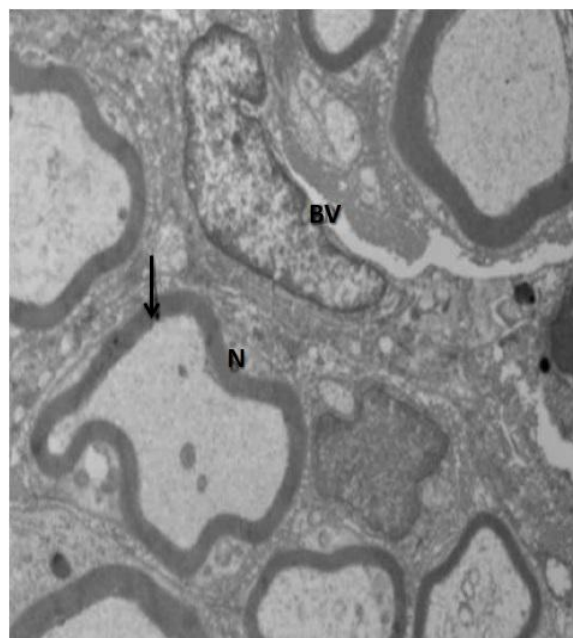


Figure 4: Electron microscopic image of the control group. Arrow: myelin sheath, NE: blood vessel, S; cross-sectional nerve

Discussion

Analysis of electron microscope images of the groups revealed that axon and myelin sheath degeneration was significant in injured peripheral nerve in the control group, with disintegration between axon and myelin sheath; gaps in majority of myelinous nerve fibers; edema between thick myelinous nerve fibers with loss of myelinous sheath in degenerated nerve fibers. These findings indicate that axon integration was damaged and endogenous repair mechanisms were inadequate in peripheral nerve injuries. In group 2 where synthetic vascular graft was used as treatment, it was found that degeneration in myelin sheath and axons continued, however all these findings were significantly decreased when compared to the control group. Gaps observed in myelin sheath in the control group were decreased in this group. In group 3 which was treated with vascular graft with CD34⁺ cells, we found that both axon and myelin sheath degeneration were prevented. It was observed that nerve tissue looked like the original tissue and damage decreased to a minimum. These findings support the view that umbilical cord blood-derived CD34⁺ stem cell transplantation can have positive effects on peripheral nerve injuries.

In our study, the results obtained in the Control Group and the Synthetic Graft Group are actually not a surprise; because when the literature is examined it is observed that, when the axons are separated from the peripheric tissue with vascular

autograft or synthetic neural tubes, it facilitates the cleaning of the debris tissue which is formed due to the injury via SCs and macrophages in a coordination; then the neurotropic factors, which support the axonal growth, are accumulated in the tube intensely, and supports the healing [1] [2] [4].

The situation in our study that creates the difference is that the CD34⁺ hemopoietic stem cells obtained from HUCB have been used in vivo in neurotmesis type injuries for the first time and the results are positive. When the stem cell sources used in the repair of peripheral nerves are examined, it is observed that these sources are mostly in the form of adipose tissue, skin, bone marrow, cells that are similar to SCs produced with the activity of various growth factors in culture medium stemming from mesenchymal stem cells of the HUCB or the mesenchymal cells that contain SCs [13] [14] [15] [16] [17]. Recently mesenchymal stromal cells (MSC), have become the focus of attention for the treatment of nerve injury, owing to their positive effects in the regeneration process [18] [19]. In a recent study Sanchez et al. showed that murine and canine Ad-MSC associated with decellularized vein scaffold had positive effects on sciatic nerve regeneration in a rat model [18]. The most proper time for repairing the damage after peripheral nerve injuries are the shortest time possible after the injury [1] [20]. The conversion of stem cells obtained from various sources into Schwann-like stem cells in culture medium requires time, and obtaining stem cell from bone marrow originating from mesenchyme is an extremely invasive method posing another disadvantage [2] [3] [9]. Also, to repair the injury in peripheral nerve injuries as soon as possible, the stem cell to be obtained must be quick to obtain, must be able to be used freshly, must be easily available in big amounts and not pose any risks in the donor during or after the process. The stem cells obtained from the HUCB blood may be considered as the most suitable source for the above mentioned criteria.

CD34⁺ hemopoietic stem cells obtained from the HUCB were examined both in vitro and in vivo media many times regarding their central system stroke models and spinal cord trauma models. In such study conducted by Nishino et al., [21]. It was reported that the CD34⁺ stem cells obtained from HUCB were used in spinal cord trauma models and that these transplanted cells lived for at least 3 weeks; however, disappeared completely after 5 weeks. Also, it was also reported in the same study that the transplanted CD34⁺ stem cells increased functional healing in rats. In addition to these findings, the transplanted CD34⁺ stem cells did not express the neuronal lineage markers. Kao et al., [12]. Conducted another study with spinal cord trauma and reported that when the CD34⁺ stem cells stemming from HUCB were given systemically, the Glial delivered neurotropic factor (GDNF) and the Vascular Endothelial Growth Factor (VEGF) amount in the cord; and that when the

opposite practice was applied with CD34⁺ stem cells obtained from the HUCB and saline, there were no significant increase observed in the GDNF and VEGF in the injured cord. In the light of these findings, they reported that the CD34⁺ stem cells obtained from HUCB increased the hind leg functions of the rats with the restoration of the injured cord and with the GDNF and VEGF production. It is known that the GDNF has a potent survival factor characteristics for mesencephalic dopaminergic neurons and motor neurons; and that the VEGF increases the neovascularization in the ischemic zone [12].

There have been many in vitro studies conducted to examine the effects of the CD34⁺ stem cells on the recovery of nerves. The CD34⁺ hemopoietic stem cells stemming from the HUCB were used in these studies. In one of these in vitro studies conducted by Fan et al., [22], CD34⁺ stem cells obtained from the HUCB were used, and it was reported that the fibronectin (Fn) accelerated the endothelial cell (EC) differentiation which has the Flk-1, vWF surface markers of the CD34⁺ stem cells. Bracci-Laudiero et al. [23]. Conducted a two-color flow cytometry study and reported that CD34⁺ stem cells obtained from the HUCB expressed the NGF and the TrkA which is its specific receptor; however, they also reported that these stem cells did not express the P75 which is known as the pan-neurotrophin receptor and which is a member of the Tumour Necrosis Factor (TNF) receptor superfamily. However, the P75 receptor binds with all neurotrophins in a similar affinity but in different kinetics. On the contrary, the Trk family receptors are highly specific [24].

In our study, the CD34⁺ hemopoietic stem cells obtained from the HUCB protected the axon and myelin sheath from degeneration. We consider that this regeneration occurs with the stem cells producing various neurotrophic factors and neurotrophins, minimizing the effect of the injury in the PNS, and supporting the SCs, and this situation is not contrary to the literature, because it is known that after neurotmesis type injury, in order to repair the wound, the SCs express neurotrophin and extracellular matrix protein such as NGF, BDNF, Neurotrophin-3 (NT-3), Neurotrophin 4/5 (NT-4/5), CTNF, TGF-1b, and bFGF; provided extracellular matrix products such as fibronectin, laminin, tenascin-C, type IV and type V collagen, heparin sulfate and chondroitin sulfate proteoglycan and also express adhesion molecules such as NCAM, L1 and N-cadherin [2] [4] [24]. Also, in a study conducted by Fan et al., [25]., it was reported that the mononuclear cells obtained from HUCB expressed BDNF, NGF, GDNF, NT-3 and NT-5 mRNA. In addition to this, the fact that the CD34⁺ stem cells obtained from the HUCB including many different subgroup cells like multi-potent and lineage-committed progenitor cell type support this viewpoint.

Another interesting situation is that although the end-to-end anastomosis or SCs obtained from different sources or stem cells are planted to the injury

area after PNS injury, the growth speed in the injured nerves does not change. Although this situation seems like a paradox, in fact, it coincides with the hypothesis that the stem cells express various growth factors and support the SCs, because the injury in peripheral nerve injuries occur not in the nerve body but the axon in the nerve extension; and when it is considered that the growth of the axons is under the control of the genes which are in the cell nucleus, the situation which seems like a paradox is in fact not contrary to the literature. This situation supports the hypothesis that the stem cells support the SCs.

In our study, it was observed that this healing effect was not reflected in the amplitude and latency values in the EMG. The results of the EMG having been obtained like this in our study may be due to one reason. The EMG having been performed without reaching the end organ after the recovery of the nerve. We believe EMG findings may reveal the effect of healing process in the chronic phase. Further studies about stem cell treatment both in acute and chronic phase of peripheral nerve injury may also show better EMG findings suggesting lower axonal loss.

There are limitations of our study. First of all we didn't study any biochemical markers and neurotrophic factors to examine the effect of stem cell and underlying mechanism of the healing process. Additionally not only the acute but also the chronic phase EMG findings may be helpful.

In conclusion, although how the CD34⁺ stem cells obtained from the HUCB support the regeneration and prevent the degeneration is not clear much, the findings makes us consider that the CD34⁺ stem cells obtained from the HUCB support this via various neurotrophic factors. To determine the mechanisms clearly, further studies are necessary. Obtaining stem cells from HUCB in a fast and easy way may provide an advantage in repairing the PNS injuries in the early period.

References

- Grinsell D, Keating CP. Peripheral nerve reconstruction after injury: a review of clinical and experimental therapies. *BioMed research international*. 2014; 2014.
- Faroni A, Mobasser SA, Kingham PJ, Reid AJ. Peripheral nerve regeneration: experimental strategies and future perspectives. *Advanced drug delivery reviews*. 2015; 82:160-7. <https://doi.org/10.1016/j.addr.2014.11.010> PMID:25446133
- Matsuse D, Kitada M, Kohama M, Nishikawa K, Makinoshima H, et al. Human umbilical cord-derived mesenchymal stromal cells differentiate into functional Schwann cells that sustain peripheral nerve regeneration. *J Neuropathol Exp Neurol*. 2010; 69(9):973-85. <https://doi.org/10.1097/NEN.0b013e3181eff6dc> PMID:20720501
- Pabari A, Lloyd-Hughes H, Seifalian AM, Mosahebi A. Nerve conduits for peripheral nerve surgery. *Plast Reconstr Surg*. 2014; 133(6):1420-30. <https://doi.org/10.1097/PRS.0000000000000226> PMID:24867724
- Faroni A, Smith RJ, Reid AJ. Adipose derived stem cells and nerve regeneration. *Neural Regen Res*. 2014; 9(14):1341-6. <https://doi.org/10.4103/1673-5374.137585> PMID:25221589 PMCid:PMC4160863
- Dezawa M, Takahashi I, Esaki M, Takano M, Sawada H. Sciatic nerve regeneration in rats induced by transplantation of in vitro differentiated bone-marrow stromal cells. *European Journal of Neuroscience*. 2001; 14(11):1771-6. <https://doi.org/10.1046/j.0953-816x.2001.01814.x> PMID:11860471
- Schäfer S, Berger JV, Deumens R, Goursaud S, Hanisch UK, Hermans E. Influence of intrathecal delivery of bone marrow-derived mesenchymal stem cells on spinal inflammation and pain hypersensitivity in a rat model of peripheral nerve injury. *Journal of neuroinflammation*. 2014; 11(1):157. <https://doi.org/10.1186/s12974-014-0157-8> PMID:25212534 PMCid:PMC4172959
- Lee EJ, Xu L, Kim GH, Kang SK, Lee SW, Park SH, Kim S, Choi TH, Kim HS. Regeneration of peripheral nerves by transplanted sphere of human mesenchymal stem cells derived from embryonic stem cells. *Biomaterials*. 2012; 33(29):7039-46. <https://doi.org/10.1016/j.biomaterials.2012.06.047> PMID:22795857
- McGuckin CP, Forraz N, Allouard Q, Pettengell R. Umbilical cord blood stem cells can expand hematopoietic and neuroglial progenitors in vitro. *Experimental cell research*. 2004; 295(2):350-9. <https://doi.org/10.1016/j.yexcr.2003.12.028> PMID:15093735
- Domanska-Janik K, Buzanska L, Lukomska B. A novel, neural potential of non-hematopoietic human umbilical cord blood stem cells. *International Journal of Developmental Biology*. 2003; 52(2-3):237-48. <https://doi.org/10.1387/ijdb.072315kd> PMID:18311714
- Sanberg PR, Willing AE, Garbuzova-Davis SV, Saporta S, Liu G, Sanberg CD, Bickford PC, Klasko SK, El-Badri NS. Umbilical cord blood-derived stem cells and brain repair. *Annals of the New York Academy of Sciences*. 2005; 1049(1):67-83. <https://doi.org/10.1196/annals.1334.008> PMID:15965108
- Kao CH, Chen SH, Chio CC, Lin MT. Human umbilical cord blood-derived CD34⁺ cells may attenuate spinal cord injury by stimulating vascular endothelial and neurotrophic factors. *Shock*. 2008; 29(1):49-55. PMID:17666954
- Kingham PJ, Kolar MK, Novikova LN, Novikov LN, Wiberg M. Stimulating the neurotrophic and angiogenic properties of human adipose-derived stem cells enhances nerve repair. *Stem cells and development*. 2013; 23(7):741-54. <https://doi.org/10.1089/scd.2013.0396> PMID:24124760
- McKenzie IA, Biernaskie J, Toma JG, Midha R, Miller FD. Skin-derived precursors generate myelinating Schwann cells for the injured and dysmyelinated nervous system. *Journal of Neuroscience*. 2006; 26(24):6651-60. <https://doi.org/10.1523/JNEUROSCI.1007-06.2006> PMID:16775154
- Dezawa M, Takahashi I, Esaki M, Takano M, Sawada H. Sciatic nerve regeneration in rats induced by transplantation of in vitro differentiated bone-marrow stromal cells. *European Journal of Neuroscience*. 2001; 14(11):1771-6. <https://doi.org/10.1046/j.0953-816x.2001.01814.x> PMID:11860471
- Matsuse D, Kitada M, Kohama M, Nishikawa K, Makinoshima H, Wakao S, Fujiyoshi Y, Heike T, Nakahata T, Akutsu H, Umezawa A. Human umbilical cord-derived mesenchymal stromal cells differentiate into functional Schwann cells that sustain peripheral nerve regeneration. *Journal of Neuropathology & Experimental Neurology*. 2010; 69(9):973-85. <https://doi.org/10.1097/NEN.0b013e3181eff6dc> PMID:20720501
- Kizilay Z, Aktas S, Kahraman Cetin N, Bakay Ilhan D, Ersoy G, Erken HA. Effect of systemic application of bone marrow-derived mesenchymal stem cells on healing of peripheral nerve injury in an experimental sciatic nerve injury model. *Turk Neurosurg*. 2017. <https://doi.org/10.5137/1019-5149.JTN.20811-17.1>
- Sanchez DNR, Bertanha M, Fernandes TD, Resende LAL, Deffune E, Amorim RM. Effects of Canine and Murine Mesenchymal Stromal Cell Transplantation on Peripheral Nerve Regeneration. *Int J Stem Cells*. 2017; 10(1):83-92. <https://doi.org/10.15283/ijsc16037> PMID:28446003 PMCid:PMC5488780
- Caseiro AR, Pereira T, Ivanova G, Luís AL, Maurício AC. Neuromuscular Regeneration: Perspective on the Application of

- Mesenchymal Stem Cells and Their Secretion Products. *Stem Cells Int.* 2016; 2016:9756973. <https://doi.org/10.1155/2016/9756973> PMID:26880998 PMCID:PMC4736584
20. Hart AM, Terenghi M, Wiberg M. Neural death after peripheral nerve injury and experimental strategies for neuroprotection. *Neurol Res.* 2008; 30(10):999-1011. <https://doi.org/10.1179/174313208X362479> PMID:19079974
21. Nishio Y, Koda M, Kamada T, Someya Y, Yoshinaga K, Okada S, Harada H, Okawa A, Moriya H, Yamazaki M. The use of hemopoietic stem cells derived from human umbilical cord blood to promote restoration of spinal cord tissue and recovery of hindlimb function in adult rats. *J Neurosurg Spine* 2006; 5(5):424-433. <https://doi.org/10.3171/spi.2006.5.5.424> PMID:17120892
22. Fan CL, Li Y, Gao PJ, Liu JJ, Zhang XJ, Zhu DL. Differentiation of endothelial progenitor cells from human umbilical cord blood CD 34+ cells in vitro. *Acta Pharmacol Sin.* 2003; 24(3):212-8. PMID:12617768 PMID:12617768
23. Bracci-Laudiero L, Celestino D, Starace G, Antonelli A, Lambiase A, Procoli A, Rumi C, Lai M, Picardi A, Ballatore G, Bonini S. CD34 positive cells in human umbilical cord blood express nerve growth factor and its specific receptor TrkA. *Journal of neuroimmunology.* 2003; 136(1-2):130-9. [https://doi.org/10.1016/S0165-5728\(03\)00007-9](https://doi.org/10.1016/S0165-5728(03)00007-9)
24. Boyd JG, Gordon T. Neurotrophic factors and their receptors in axonal regeneration and functional recovery after peripheral nerve injury. *Molecular neurobiology* 2003; 27(3):277-323. <https://doi.org/10.1385/MN:27:3:277>
25. Fan CG, Zhang QJ, Tang FW, Han ZB, Wang GS, Han ZC. Human umbilical cord blood cells express neurotrophic factors. *Neuroscience letters.* 2005; 380(3):322-325. <https://doi.org/10.1016/j.neulet.2005.01.070> PMID:15862910