

ID Design 2012/DOOEL Skopje, Republic of Macedonia  
 Open Access Macedonian Journal of Medical Sciences. 2017 Dec 15; 5(7):1011-1015.  
<https://doi.org/10.3889/oamjms.2017.191>  
 eISSN: 1857-9655

Public Health



# The Value of Mobile Ultrasound Services in Rural Communities in South-South Nigeria

Anthonia Ikpeme<sup>1\*</sup>, Nchiewe Ani<sup>1</sup>, Boniface Ago<sup>2</sup>, Emmanuel Effa<sup>3</sup>, Omofolasade Kosoko-Lasaki<sup>4</sup>, Andrew Ekpenyong<sup>5</sup>

<sup>1</sup>Department of Radiology, University of Calabar Teaching Hospital, Calabar, Nigeria; <sup>2</sup>Department of Obstetrics and Gynaecology, University of Calabar Teaching Hospital, Calabar, Nigeria; <sup>3</sup>Department of Internal Medicine, University of Calabar Teaching Hospital, Calabar, Nigeria; <sup>4</sup>Creighton University School of Medicine, Omaha, NE 681 78, USA; <sup>5</sup>Department of Physics, Creighton University, Omaha, NE 681 78, USA

## Abstract

**Citation:** Ikpeme A, Ani N, Ago B, Effa E, Kosoko-Lasaki O, Ekpenyong A. The Value of Mobile Ultrasound Services in Rural Communities in South-South Nigeria. Open Access Maced J Med Sci. 2017 Dec 15; 5(7):1011-1015. <https://doi.org/10.3889/oamjms.2017.191>

**Keywords:** Mobile ultrasound; Abdomino-pelvic scans; Uterine fibroids; Prostatic enlargement.

**\*Correspondence:** Anthonia Asanye Ikpeme. Radiology Department, University of Calabar, Calabar, Nigeria. E-mail: [ikpemeanthonia@yahoo.com](mailto:ikpemeanthonia@yahoo.com)

**Received:** 12-Aug-2017; **Revised:** 25-Sep-2017; **Accepted:** 29-Sep-2017; **Online first:** 26-Oct-2017

**Copyright:** © 2017 Anthonia Ikpeme, Nchiewe Ani, Boniface Ago, Emmanuel Effa, Omofolasade Kosoko-Lasaki, Andrew Ekpenyong. This is an open-access article distributed under the terms of the Creative Commons Attribution-NonCommercial 4.0 International License (CC BY-NC 4.0).

**Funding:** This work was partially supported by Friends of Joseph Ukpo Hospitals and Research Institutes, a nonprofit corporation and a public charity with Tax Exempt Status under section 501(c) [3] of the Internal Revenue Code of the United States of America, whose mission is to bring the benefits of modern medical science to individuals in South-South Nigeria.

**Competing Interests:** The authors have declared that no competing interests exist.

**AIM:** This paper examines the activities of mobile services units including ultrasound services in rural and urban communities in the Calabar region of South-South, Nigeria.

**MATERIALS AND METHODS:** Consenting individuals were invited and attended five medical outreach activities in rural and urban areas of the Calabar region between January and June 2016. Abdomino-pelvic scans were done. Subsequently the results were analyzed.

**RESULTS:** Five hundred and seventy-four (574) individuals had Abdomino-pelvic scans done, using a curvilinear probe to assess the abdomino-pelvic organs. The female to male ratio was 1.46:1. The age ranged from 1-78 years with a mean of 40.63 (standard deviation of 17.5). The commonest sonographic finding was uterine fibroids, 21 (8.1%). Fifty-four percent of the scans were normal. The commonest sonographic finding in men was prostatic enlargement.

**CONCLUSION:** Medical outreach activities provided by mobile units provide much needed ultrasound services in poor resource settings in Nigeria. Significant clinical pathologies were identified at fairly high rates.

## Introduction

The benefits of diagnostic ultrasound are no longer debatable [1]. Since the practice of diagnostic ultrasound became established and popular in the 1950s [2] the field of medicine and medical care worldwide has been greatly revolutionized. Compared with the earlier imaging modalities, diagnostic ultrasound is safe, uses sound waves with no ionizing radiation, is cheap, simple to operate and widely available [2, 3]. It can be used both for diagnosis and therapeutic purposes [3].

In developing countries such as Nigeria, the rural communities have limited access to diagnostic centres [1]. Besides the unavailability of ultrasound and other diagnostic facilities, misconceptions, fears and poverty have further limited access to medical care [4]. Over the past decade however, the use of

clinician performed, hand-carried bed side ultrasound has gained increasing popularity as a useful imaging modality worldwide, helping to boost the diagnostic capacity of rural district hospitals in resource-limited settings [5]. Many new lap-top-based machines (mobile ultrasound machines) are now available [5]. Improvements in battery life for hand-carried machines and the lack of film, chemical developers and dedicated technicians allow for use of ultrasound in health care missions to remote areas of the developing world [5-8].

The use of mobile health care services and mobile ultrasound services is not new in the world and even within the country [7-10]. West D et al. [11] reported that the use of mobile devices and mobile ultrasound services help with maternal care, chronic disease management and disease epidemics. They improve the efficiency and effectiveness of the medical system through patient tracking and reporting

and they extend critically needed health services to underserved areas [10-12]. The report also showed that the mobile ultrasound patrol program in Morocco uses portable ultrasound machines and 3D smart phones to improve diagnostic times for expectant mothers [11]

Nigeria is the most populous country in Africa and many areas have little or no access to adequate healthcare, well below that of other African countries. The country represents a potentially important example of mobile health solution with more than 174 million residents [10-12].

The aim of this study is to examine the medical outreach activities of portable mobile ultrasound services units, donated by Joseph Ukpo Hospital and Research Institute (JUHRI) in rural and urban communities in the Calabar region of South-South Nigeria.

## Materials and Methods

This is a descriptive study of clinical outreach activities that took place in January, March and June 2016 in five Cross River State rural and urban communities. Two portable ultrasound systems (Mindray DP-30, each with 12.1 inch LED monitor, high-resolution 1024 x 768 control panel, dual transducer ports, enabling THI (Tissue Harmonic Imaging) and transducer dependent TSI (Tissue Specific Imaging).

The ultrasound systems included two convex probes (Mindray 35C50EA, 2.0/3.5/6.0 MHz convex array transducer). The two mobile ultrasound systems were donated by Joseph Ukpo Hospital and Research Institute (JUHRI) with the aim of setting up mobile clinics and hospitals with emphasis on the rural/urban settings who do not have access to medical care. Other items donated to set up the mobile clinics included two Ambulance vehicles (Ford E 350 Super duty Type II Ambulance), a medical library, first aid equipment, drugs, clinical thermometers, blood pressure equipment, glucometers, urinalysis kits and haemoglobinometers [13]. This year (2016) mobile clinics have been set up in three rural communities including Akpabuyo, Akamkpa and Mfamosing. Urban centres were Saint Patrick's Catholic Church, Ikot Ansa, Calabar and a correctional facility in the city of Calabar.

The St. Patrick's Church, Ikot Ansa is located along the Old Odukpani Road, one of the major Roads in Calabar, it has a population of 1410 families. Akamkpa Local Government Area has a population of 151,125 people. Akamkpa has a land mass of 4,300 km<sup>2</sup>, bounded by Odukpani and Akpabuyo Local Government Areas to the west and south. There are

260 villages including Mfamosing and is serviced by one Primary Health Center at Oban, one General Hospital at the headquarters and several private health clinics. Akpabuyo, also a local Government Area of Cross River State, Nigeria, has an area of 1,241 km<sup>2</sup> and a population of 271,395 [14, 15]. These go to show how massively populated these areas are and how underserved they are in terms of healthcare. The correctional facility had 800 in-mates as at the time of the medical outreach. All communities involved in the outreaches were duly informed by their parish priests two to three weeks before each exercise. The correctional facility outreach exercise was requested for by their Chaplain in-charge, the date and time was agreed upon. Consent was obtained from the correctional facility authorities, the Cross River State ethical committee and the individual in-mates. Formal letters were written to the correctional facility authorities and to the village or town heads of these communities for this purpose and this included seeking consent from them for the ultrasound examination.

A verbal consent was also obtained from the individuals just before commencement of the medical outreach by explaining to them what was to be done and by whom as well as the overall benefit of this exercises. All the outreaches were carried out within the parish premises or within the correctional facility. Four other parishes were invited to each community outreach and subjects were encouraged to come along with their sick family members.

The medical personnel consisted of a consultant radiologist who specializes in ultrasonography, senior residents in radiology and internal medicine as well as hematology. They assisted the consultant in doing the scans, consulting with the subjects and carried out the basic laboratory investigations respectively. Others included senior nurses and laboratory scientists whose roles were to ensure that proper records were kept, vital signs and laboratory investigations accurately documented.

With the aid of a detailed questionnaire, subject data such as age, sex, body mass index clinical history, examination and diagnosis were recorded on paper initially before transferring them to a computer. Some of the outreaches were purely for screening and the others based on clinical presentation of the participants. Ultrasound scans were carried out on all participants using the portable ultrasound systems for the screening activities. For the selective treatment activities, scans were carried out on individuals with clinical indications such as abdominal pain, infertility, pregnancy and undiagnosed chronic illness.

Data were entered into Excel format and analyzed using SPSS v. 20 (SPSS Inc. Chicago. IL, USA). Frequency tables, histograms and bar charts were used to analyze the data.

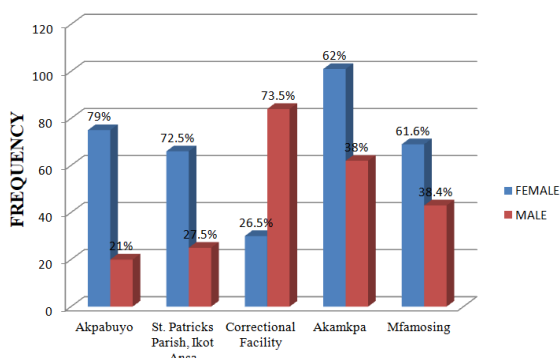
## Results

Five Hundred and Seventy Four (574) patients were seen in Five (5) different Medical outreaches and five (5) different communities in Cross River, South South Nigeria (Table 1).

**Table 1: Participating communities and female/male ratio**

Communities	Frequency (%)	Female (%)	Male (%)
Akpabuyo Local Government Area	95 (16.5)	75 (79)	20 (21)
St. Patrick's Parish Ikot Ansa	91 (15.8)	66 (72.5)	25 (27.5)
Correctional facility	113 (19.7)	30 (26.5)	84 (73.5)
Akamkpa	163 (28.5)	101 (62)	62 (38)
Mfamosing	112 (19.5)	69 (61.6)	43 (38.4)
Total	574 (100)	341 (59.4)	233 (40.6)
Female/male ratio 1.46:1			

The female to male ratio was 1.46:1, with females 341 and males 233 (Table 1 and Figure 1). The ages ranged from 1-78 years with a mean of  $40.63 \pm 17.15$  (standard deviation).



*Figure 1: Participating Communities and Female/Male Ratio*

The five communities and their frequencies included; Akpabuyo 95 (17.6%), St Patrick's, Ikot Ansa 91 (16.8%), Correctional facility 113 (19.7%), Akamkpa 163 (28.4%), Mfamosing 112 (19.5%). (Table 1), (Figure 1).

**Table 2: Common sonographic findings**

Sonographic findings	Frequency	Percentage (%)
Normal study	140	54
Uterine fibroids	21	8.1
Fatty liver	16	6.2
Pelvic inflammatory disease	14	6.2
Prostatic enlargement	8	3.1
Splenic enlargement	5	1.9
Normal pregnancy	4	1.5
Increased bladder wall thickness (cystitis)	4	1.5
Nephrocalcinosis	4	1.5
Epigastric hernia	3	1.2
Liver calcification	3	1.2
Renal parenchymal disease	3	1.2
Renal cysts	3	1.2
Ovarian cysts	3	1.2
Small uterus for age	2	0.7
Pyelonephritis	2	0.7
Inguinal hernia	2	0.7
Umbilical hernia	2	0.7
Abdominal malignancy	2	0.7
Utero-vaginal prolapse	2	0.7
Polycystic ovary disease	1	0.4
Pelvi-ureteric junction obstruction	1	0.4
Lipoma (upper limb)	1	0.4
Intestinal obstruction	1	0.4
Renal calculus	1	0.4
Early onset menopause	1	0.4
Ectopic pregnancy	1	0.4
Kidney enlargement	1	0.4
Post surgical, Abdominal incisional hernia	1	0.4

The commonest sonographic finding over all by far was uterine fibroids 21 (8.1%) (Table 2),

whereas more than 50% of scans done were normal (54%).

**Table 3: Gender with common sonographic findings**

Sonographic findings	Female (%)	Male (%)
Normal	65 (46.4)	75 (54.6)
Uterine fibroids	20 (100)	-
Fatty liver	14 (87.5)	2 (12.5)
Pelvic Inflammatory Disease	14 (100)	-
Prostate enlargement	-	8 (100)
Renal pathology	7 (100)	-
Normal cyesis	4 (100)	-
Splenic enlargement	3 (60)	2 (40)
Ovarian cysts	3 (100)	-
Small uterus for age	3 (100)	-
Liver calcification	-	3 (100)
Abdominal hernias	2 (50)	2 (50)
Utero-vaginal prolapse	2 (100)	-
Polycystic ovaries	2 (100)	-
Renal cysts	1 (33)	2 (66)
Post surgical incisional hernias	1 (50)	1 (50)
Abdominal malignancy	1 (50)	1 (50)
Ectopic pregnancy	1 (100)	-

The commonest sonographic finding in the females was uterine fibroids while in the males it was prostatic enlargement (Table 3).

A typical sonographic scan being carried out is shown in Figure 2.



*Figure 2: Pelvic-Ultrasound scanning during the medical outreach*

## Discussion

In much of Sub-Saharan Africa, diagnostic imaging in patient care is limited to urban settings and lack of adequate healthcare facilities, personnel and diagnostic tools remain a major barrier to healthcare delivery. The use of Ultrasound and x-rays are ideal diagnostic tools because they can meet 70-80% of all clinical diagnostic needs [15] Their absence increases the risk of misdiagnoses, treatment delays, and negative healthcare outcomes [15]. Few prior studies of ultrasound services in remote settings exist. With non-governmental organizations efforts to strengthen and scale-up existing public sector health care models in rural international settings, attention has focused on appropriate placement of cost effective, durable technology that will assist local care providers in the clinical care of their patients [16].

This motive is seen in this initiative by the

Joseph Ukpo Hospital and Research Institute (JUHRI), through their provision of ambulances, drugs and mobile ultrasound machines in order to reach rural settings with little or no access to medicare. JUHRI is a faith-based charity in Nigeria funded by Friends of Joseph Ukpo Hospital and Research Institute, a nonprofit corporation and a public charity with Tax Exempt Status under section 501(c) [3] of the Internal Revenue Code of the United States of America, whose mission is to bring the benefits of modern medical science to individuals in South South Nigeria and beyond.

The number of scans done was determined by whether or not health screening was carried out. Scans were therefore limited to those who required them in the first instance. On the other hand screening exercises were carried out in two of these communities and hence all participants were scanned. Types of scans were limited to the abdomen and pelvis because of unavailability of other transducers. The commonest finding was uterine fibroids in women and prostate enlargement in men. Majority of scans done turned out to be normal during the screening exercises.

Uterine fibroids were the commonest pelvic tumor in women [17, 18]. Several studies have documented increased incidence of uterine leiomyoma in black women and women of African descent [18, 19]. This probably explains why it is the commonest finding in the women in the index study. Our study reveals that the age bracket commonly affected was 40-59 years. This is quite unlike other studies conducted within and outside Nigeria where the younger age groups were most affected [17, 20, 21].

Prostatic enlargement is a common disease of aging men worldwide [22]. Men in the seventh decade are most commonly affected [22-24]. The index study showed that majority of men affected were in the 40th and 50th decades, in younger age groups when compared with the above mentioned studies done within the country [22-24].

Comparison of past medical history and ultrasound findings could not be accurately done. Past medical history such as tuberculosis, sickle cell disease, human deficiency virus, bronchial asthma and glaucoma were probed for. We could not however rely on the clinical history given because a good number of them had not sought any form of medical care before and if they did, it was from a local primary health care center or general hospitals which are not well equipped to evaluate and handle such severe and chronic illnesses. The general healthcare status in these areas is quite poor and basically similar. The overall healthcare facilities include a primary healthcare center, a non-functional general hospital, several small private health clinics and patent drug stores. The only tertiary healthcare institution, a teaching hospital, is in the city of Calabar which is

about 35 to 44 km (about three to five hours drive by road considering the bad roads) from these aforementioned towns or villages. Basically any proper and affordable healthcare can only be obtained from the teaching hospital in Calabar. However, the far distance, the fact that access to treatment is not free and the long period of waiting to be attended to, make these new mobile healthcare services preferable since it is free of charge, they do not have to travel far for it and the waiting time is drastically reduced.

Some literature have attempted to measure the impact of ultrasound services in these low resource settings and innovations in teleradiology and portable ultrasound have been shown to offer opportunity for improved ultrasound access in these areas [25, 26].

Sachita P. Shah et al., [16] suggests that ultrasound is a useful modality that particularly benefits women's health and obstetrical care in the developing world. They also believe that ultrasound services significantly impact patient management plans especially with regards to potential surgical interventions.

In conclusion, these outreaches have indicated the need for ultrasound services in these communities as significant pathologies were identified at fairly high rates. It is recommended that other ultrasound transducers be acquired to further increase the scope of diagnoses made in these outreaches and further the advantage therefrom.

## Acknowledgements

The author wish to thank Professors Emmanuel Ekanem and Ikpeme Ikpeme of the University of Calabar Teaching Hospital, Nigeria (UCTH) for reading and correcting the manuscript as well as Marcus Iyama (UCTH) and Theresa Ekpenyong (General Hospital, Calabar, Nigeria) who assisted during the outreaches. The authors also thank Akan Otu (UCTH) who helped with the initial planning of the mobile clinics.

## References

- Ostensen H. Developing Countries. *Ultrasound Med Biol.* 2000; (26 Suppl 1): 159-61. [https://doi.org/10.1016/S0301-5629\(00\)00194-0](https://doi.org/10.1016/S0301-5629(00)00194-0)
- Goldberg BB, Gramiak R, Freimans AK. Early History of Diagnostic Ultrasound. *The Role of American Radiologists. AJR.* 1993; 160: 189-197. <https://doi.org/10.2214/ajr.160.1.8416623> PMID:8416623
- Carovac A, Smajlovic F, Junuzovic D. Application of Ultrasound in Medicine. *Acta Inform Med.* 2001; 19(3): 168-171. <https://doi.org/10.5455/aim.2011.19.168-171> PMID:23408755

PMCID:PMC3564184

4. Iliyasu G, Ogoina D, Otu AA, Dayyab FM, Habib AG. Multi-Site Knowledge Attitude and Practice Survey of Ebola Virus Disease in Nigeria. *PLoS One*. 2015;10(8). <https://doi.org/10.1371/journal.pone.0135955> PMID:26317535 PMCID:PMC4552659
5. Sippel S, Muruganandan K, Shah S. Review article: Use of Ultrasound in the Developing World. *Int J Emerg Med*. 2011; 4:7. <https://doi.org/10.1186/1865-1380-4-72> PMID:22152055 PMCID:PMC3285529
6. Ault MJ, Rosen BT. Portable Ultrasound; the next generation arrives. *Crit Ultrasound J*. 2010;2(1): 39-42. <https://doi.org/10.1007/s13089-010-0031-6> PMID:21151494 PMCID:PMC2994643
7. Liang D, Schnittger I. Accuracy of hand-carried Ultrasound. *Echocardiography*. 2003; 20(5): 487-490. <https://doi.org/10.1046/j.1540-8175.2003.03072.x> PMID:12848872
8. Gorcsan J. Hand-carried Ultrasound for Consultative Cardiology. *Echocardiography*. 2003; 20(5): 463-469. <https://doi.org/10.1046/j.1540-8175.2003.03082.x>
9. Director General, World Health Organization: World Health Report: Fighting Disease, Fostering Development. WHO, Geneva vi, 1996.
10. World Health Organization. Baseline Country Survey on Medical Devices 2010. Geneva: WHO press, 2011.
11. West DM. Using Mobile Technology to Improve Maternal Health and Fight Ebola: A case study of mobile innovation in Nigeria, 2015.
12. Filkins M, Halliday S, Daniels B, Bista R, Thapa S, Schwarz R, Schwars D, Guuchan BK, Maru D. Implementing Diagnostic Imaging Services in a Rural Setting of Extreme Poverty: five years of x-ray and ultrasound service delivery in Achham Nepal *J Glob Radiol*. 2015; 1(1): Article 2.
13. Wright EE, Schellekens O. Achieving Universal Health coverage in Nigeria one State at a time. *Brookings Global Economy and Development*, June, 2013.
14. Ekpenyong A, Effa E, Ikpeme A, Inyama M, Ago B, Ekpenyong T, Out A, Ani N, Egbe W, Tom EA, Prathivadhi S, Nichols M, Kosoko-Lasaki S. Mobile Clinics Deployed in Rural Nigeria for free Patient Care and Clinical Research. *Global Health Conference Midwest Research Symposium*. Omaha, NE. 2016;pg. 18.
15. "Institutions". National Board for Technical Education. Retrieved 2010-03-20.
16. Nwabueze BO. A constitutional History of Nigeria. C Hurst and Co LTD, UK, 1982.
17. Baird DD, Dunson DB, Hill MC, Cousins D, Schectman JM. High cumulative incidence of uterine leiomyoma in black and white women: ultrasound evidence. *Am J Obstet Gynecol*. 2003;188(1):100. <https://doi.org/10.1067/mob.2003.99> PMID:12548202
18. Shah SP, Epino H, Bukhman G, Umulisa I, Dushimiyimana JM, Reichman A, Noble VE. Impact of the introduction of ultrasound services in a limited resource setting: rural Rwanda 2008. *BMC international health and human rights*. 2009;9(1):4. <https://doi.org/10.1186/1472-698X-9-4> PMID:19327157 PMCID:PMC2667437
19. Eze JC, Ugwu AC, Ohagwu CC, Imoh OC. The value of ultrasonography in the diagnosis leiomyoma in the South East Nigeria. *Journal of Asian Scientific Research*. 2013; 3(2): 151-156.
20. Szlark JE, Choi TH, Vithya VV. Imaging of common and uncommon large pelvic masses. *Radiographics*. 2003; 23:403-424. <https://doi.org/10.1148/rq.232025089> PMID:12640156
21. Taran FA, Brown HL, Stewart EA. Racial diversity in uterine leiomyoma clinical studies. *Fertile Steril*. 2010; 94:1500-1503. <https://doi.org/10.1016/j.fertnstert.2009.08.037> PMID:19969296
22. Zimmermann A, Bernuit D, Gerlinger C, Schaeffers M, Geppert K. Prevalence, symptoms and management of uterine fibroids: An International Internet-based survey of 21,746 women. *BMC Women's Health*. 2012; 12:6. <https://doi.org/10.1186/1472-6874-12-6> PMID:22448610 PMCID:PMC3342149
23. Shah SP, Epino H, Bukhman G, Umulisa I, Dushimiyimana JM, Reichman A, Noble VE. Impact of the introduction of ultrasound services in a limited resource setting: rural Rwanda 2008. *BMC international health and human rights*. 2009;9(1):4. <https://doi.org/10.1186/1472-698X-9-4> PMID:19327157 PMCID:PMC2667437
24. Ma'aji SM, Adamu B. Transabdominal Ultrasonographic assessment of prostate size and volume in Nigerians with Clinical diagnosis of benign prostatic hyperplasia. *Niger J Ilin Pract*. 2013; 16:404. <https://doi.org/10.4103/1119-3077.113476> PMID:23771473
25. Ajayi I, Aremu A, Olajide A, Bello T, Olajide F, Adetiloye V. Correlation of transrectal and transabdominal ultrasound measurement of transition zone volume with post-operative enucleated adenoma volume in benign prostatic hypertrophy. *The Pan African Medical Journal*. 2013;16. <https://doi.org/10.11604/pamj.2013.16.149.2532>
26. Tahir A, Ahidjo A. Variation of prostatic volume with advancing adult Nigerians. *Arch Nig Med*. 2004; 1:12-14.
27. Stanton K, Mwanri L. Global Maternal and Child Health Outcomes: the role of obstetric ultrasound in low resource settings. *World Journal of Preventive Medicine*. 2013;1(3):22-9.
28. Ali QN, Roth J, Abdel-Rahum IM, Franke D, Kardoff R, Schwasforth H, Doehring E. Cost saving with ultrasonography in a developing country district hospital. *East Afr Med. J*. 1999; 76(5):272-4. PMID:10750508