

# Penile Melanosis Associated with Lichen Sclerosus et Atrophicus: First Description in the Medical Literature

Georgi Tchernev<sup>1,2\*</sup>, Anastasiya Atanasova Chokoeva<sup>2</sup>, Hristo Mangarov<sup>3</sup>

<sup>1</sup>Medical Institute of Ministry of Interior (MVR-Sofia), Department of Dermatology, Venereology and Dermatologic Surgery, Sofia, Bulgaria; <sup>2</sup>"Onkodema"- Polyclinic for Dermatology and Dermatologic Surgery, Sofia, Bulgaria; <sup>3</sup>Medical Institute of Ministry of Interior (MVR), Department of Dermatology and Dermatologic Surgery, General Skobelev 79, 1606 Sofia, Bulgaria

## Abstract

**Citation:** Tchernev G, Chokoeva AA, Mangarov H. Penile Melanosis Associated with Lichen Sclerosus et Atrophicus: First Description in the Medical Literature. Open Access Maced J Med Sci. 2017 Aug 15; 5(5):692-693. <https://doi.org/10.3889/oamjms.2017.152>

**Keywords:** lichen sclerosus; lichen genitalis; penile macular melanosis; melanoma; sporadic.

**\*Correspondence:** Professor Georgi Tchernev, PhD. 1"Onkodema"- Polyclinic for Dermatology and Dermatologic Surgery, Sofia, Bulgaria; 2Medical Institute of Ministry of Interior (MVR-Sofia), Department of Dermatology, Venereology and Dermatologic Surgery, Sofia, Bulgaria. Tel.: 00359885588424. E-mail: georgi\_tchernev@yahoo.de

Received: 04-Jun-2017; Revised: 10-Jun-2017; Accepted: 11-Jun-2017; Online first: 10-Aug-2017

**Copyright:** © 2017 Georgi Tchernev, Anastasiya Atanasova Chokoeva, Hristo Mangarov. This is an open-access article distributed under the terms of the Creative Commons Attribution-NonCommercial 4.0 International License (CC BY-NC 4.0).

**Funding:** This research did not receive any financial support.

**Competing Interests:** The authors have declared that no competing interests exist.

We present a 74-year-old male patient with 3-years history of visible discoloration of the glans penis, without subjective complaints. Histopathological examination after incision biopsy revealed a moderate increase in the number of melanocytes in the basal layer with irregular distribution, without melanocytic nests, melanophages in the superficial dermis, and subepidermal sclerosis. No cytologic atypia of melanocytes was detectable. The diagnosis of melanosis of the genitalia in association with lichen sclerosus was made. The importance of the presented cases implicated the unique clinical manifestation of penile melanosis, associated with lichen sclerosus of the penis in one hand, the essential differentiation between malignant melanoma via careful histological examination for diagnosis confirmation in other, in order to optimize the therapeutic behavior.

We present a 74-year-old male patient presented with 3-years history of visible discoloration of the glans penis, without subjective complaints. Arterial hypertension, glaucoma and asthma were also reported. An irregularly bordered hyper pigmented macule, unequally coloured, was clinically observed in the peripheral part of the glans penis, while apigmented macule was established in the central area. An erythematous macule with irregular borders was also presented (Fig. 1a, 1b). Histopathological examination after incision biopsy revealed a moderate increase in the number of melanocytes in the basal layer with irregular distribution, without melanocytic nests, melanophages in the superficial dermis, and subepidermal sclerosis. No cytologic atypia of melanocytes was detectable. (Fig. 1c, 1d). The diagnosis of melanosis of the genitalia in association with lichen sclerosus was

made. Topical application of tacrolimus 0.1% ointment was initiated in a therapeutic regimen twice daily, while systemic administration of chloroquine was planned to be initiated in one month.

Mucosal melanoses always require exclusion of malignant melanoma, via excisional or incisional biopsy, because it is usually not possible to differentiate them on clinical inspection alone [1]. Despite superficial spreading melanoma, a lentigo maligna should also be considered as differential diagnoses in cases with penile hyperpigmentations, because of their atypical clinical manifestation [2].

In contrast, lichen sclerosus et atrophicus is not unusual findings in the genital area, and usually, do not dare diagnostic difficulties [3]. As a chronic inflammatory disorder with a predilection for the anogenital area, lichen sclerosus play a key role in the

arising of a human papilloma virus – negative neoplasms, which makes its early detection and treatment beneficial to the further prognosis [3]. Turnbull N. et al. described three cases of a primary melanoma of the penis in patients with lichen sclerosus, which highlight the importance of the chronic inflammation in all-kind of malignant transformations with penile localization [4]. The aggressive management of pigmented penile macules is based on the principle that they represent junctional naevi and hence, have a higher incidence of malignant change [5]. In contrast, some authors highlight the statement that most cases of penile and urethral melanomas arise de novo and precursor lesions are not identified which makes the prophylactic excision unnecessary [5]. We support the view of Barnhill et al. which require individualized therapeutic behaviour with multiple biopsies when needed [5].

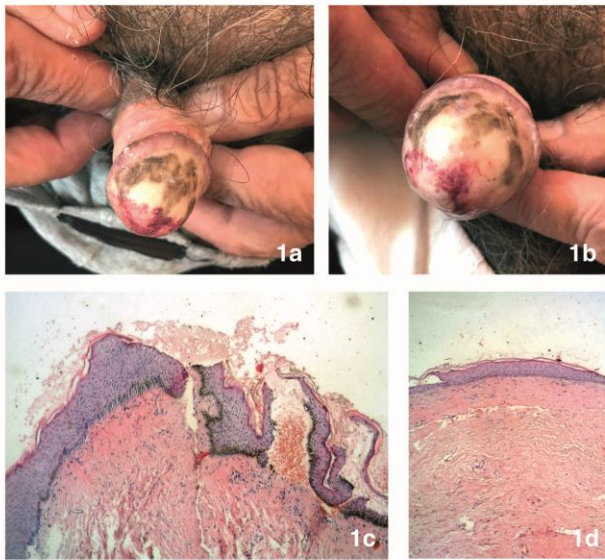


Figure 1: 1a, 1b) – Clinical manifestation of a discolored macules, located on glans penis - an irregularly bordered hyperpigmented macule, an apigmented macule in the central area and erythematous macule with irregular borders. 1c, 1d) – Histopathological findings - moderate increase in the number of melanocytes in the basal layer with irregular distribution, no cytologic atypia, neither melanocytic nests, melanophages in the superficial dermis, and subepidermal sclerosis

The importance of the presented cases implicated the unique clinical manifestation of penile melanosis, associated with lichen sclerosus of the penis in one hand (Fig. 1a, 1b), the essential differentiation between malignant melanoma via careful histological examination for diagnosis confirmation in other, in order to optimize the therapeutic behavior.

We treated the presented patient with topical tacrolimus 0.1% ointment twice daily, while systemic administration of chloroquin was planned to be initiated in one month. Further regular screening and monitoring is mandatory, regarding the high malignant transformational potential of genital lichen sclerosus, as well as the higher incidence of malignant changes of the pigmented naevi on the palms, soles and genitalia [5].

## References

1. Maize JC. Mucosal melanosis. *Dermatol Clin.* 1988; 6(2):283-93. PMID:3378373
2. Laguna C, Pitarch G, Roche E, Fortea JM. Atypical pigmented penile macules. *Actas Dermosifilogr.* 2006; 97(7):470-2. [https://doi.org/10.1016/S0001-7310\(06\)73444-5](https://doi.org/10.1016/S0001-7310(06)73444-5)
3. Kacerovska D, Michal M, Hora M, Hadravsky L, Kazakov DV. Lichen sclerosus on the penis associated with striking elastic fibers accumulation (nevus elasticus) and differentiated penile intraepithelial neoplasia progressing to invasive squamous cell carcinoma. *JAAD Case Rep.* 2015;1(3):163-5. <https://doi.org/10.1016/j.jidcr.2015.03.004> PMID:27051718 PMID: PMC4808714
4. Turnbull N, Shim T, Patel N, Mazzon S, Bunker C. Primary Melanoma of the Penis in 3 Patients With Lichen Sclerosus. *JAMA Dermatol.* 2016; 152(2):226-7. <https://doi.org/10.1001/jamadermatol.2015.3404> PMID:26536280
5. Mahto M, Woolley PD, Ashworth J. Pigmented penile macules. *Int J STD AIDS.* 2004; 15(11):717-9. <https://doi.org/10.1258/0956462042395276> PMID:15537454