

ID Design 2012/DOOEL Skopje, Republic of Macedonia  
Open Access Macedonian Journal of Medical Sciences. 2017 Jul 25; 5(4):473-475.  
**Special Issue: Global Dermatology**  
<https://doi.org/10.3889/oamjms.2017.135>  
eISSN: 1857-9655  
**Case Report**



## A Misleading Anamnesis: Learning To Suspect

Claudio Guarneri<sup>1\*</sup>, Georgi Tchernev<sup>2</sup>, Uwe Wollina<sup>3</sup>, Torello Lotti<sup>4</sup>

<sup>1</sup>Università degli Studi di Messina, Clinical and Experimental Medicine, Section of Dermatology, Messina 98122, Italy; <sup>2</sup>Medical Institute of the Ministry of Interior, Dermatology, Venereology and Dermatologic Surgery; Onkoderma, Private Clinic for Dermatologic Surgery, Dermatology and Surgery, Sofia 1407, Bulgaria; <sup>3</sup>Krankenhaus Dresden-Friedrichstadt, Department of Dermatology and Venereology, Dresden, Sachsen, Germany; <sup>4</sup>Universitario di Ruolo, Dipartimento di Scienze Dermatologiche, Università degli Studi di Firenze, Facoltà di Medicina e Chirurgia, Dermatology, Via Vittoria Colonna 11, Rome 00186, Italy

### Abstract

Leishmaniasis represents a complex, globally widespread opportunistic infection ranging from the visceral form, also called *kala-azar*, to the mucocutaneous and cutaneous disease. It is endemic in the Mediterranean Basin, *Leishmania infantum* being demonstrated as the main causative agent of autochthonous cases in Sicily, Italy. The long-term use of systemic antipsoriatic agents, including biotechnological drugs, may cause a higher susceptibility to opportunistic infections, so physicians maintain a high level of suspicion with treated patients. However, some skin tumours, because of the rare occurrence and/or the atypical clinical features, may mimic another kind of disease thus leading to a delay in diagnosis and treatment. An exemplary case is reported herein.

**Citation:** Guarneri C, Tchernev G, Wollina U, Lotti T. A Misleading Anamnesis: Learning To Suspect. Open Access Maced J Med Sci. 2017 Jul 25; 5(4):473-475. <https://doi.org/10.3889/oamjms.2017.135>

**Keywords:** Amelanotic melanoma; Leishmaniasis; Psoriasis; Malignant Melanoma; Biopsy.

**\*Correspondence:** Claudio Guarneri. Università degli Studi di Messina, Clinical and Experimental Medicine, Section of Dermatology, Messina 98122, Italy. E-mail: [cguarneri@unime.it](mailto:cguarneri@unime.it)

Received: 28-Apr-2017; Revised: 01-May-2017; Accepted: 02-May-2017; Online first: 21-Jul-2017

**Copyright:** © 2017 Claudio Guarneri, Georgi Tchernev, Uwe Wollina, Torello Lotti. This is an open-access article distributed under the terms of the Creative Commons Attribution-NonCommercial 4.0 International License (CC BY-NC 4.0).

**Funding:** This research did not receive any financial support.

**Competing Interests:** The authors have declared that no competing interests exist.

### Case report

A 57-year-old Caucasian man, who was a farmer affected by psoriasis and treated with cyclosporine A periodically in the last two years, presented for the first time to our Unit with a one-year history of an asymptomatic, approximately round, well-demarcated lesion on the second finger of the left hand, reported as the possible consequence of a previous trauma or insect bite. In anamnesis, the patient revealed that indeed he had subsequently noticed a small bump, gradually increasing in size and elevating, but never experiencing pain in the affected area. Apart from psoriasis, medical history was also notable for the chronic obstructive pulmonary disease.

The lesion was initially treated with topical gentamycin/betamethasone cream for about one month, and then the patient commenced oral amoxicillin/clavulanate (2g/day) for two months. Because of the lack of any improvement, together with the further ulceration of the nodule, and having cutaneous leishmaniasis in mind as suspect

diagnosis, general physician empirically prescribed rifampicin (600 mg/day for two months) and then oral itraconazole (200 mg/day for one month) with no significant changes of the clinical picture. He also proposed possible intralesional therapy with meglumine antimoniate, but the patient sought dermatological consultation.

Cutaneous examination revealed a firm, flesh-coloured, slightly erythematous eroded nodule, measuring 9 mm in diameter, located on the medial surface of the medial phalange, close to the interphalangeal joint. The skin surrounding the tumour was normal, except for xerosis with light scaling (Fig. 1 and 2).

An x-ray film of the hand in two projections showed no evidence of bone abnormality. A biopsy specimen was obtained: hematoxylin-eosin staining revealed an ulcerated surface epithelium with hyperkeratosis and acanthosis and nests of non-pigmented atypical epithelioid cells at the dermo-epidermal junction; also, nests and trabeculae of neoplastic cells extended down to the reticular dermis.

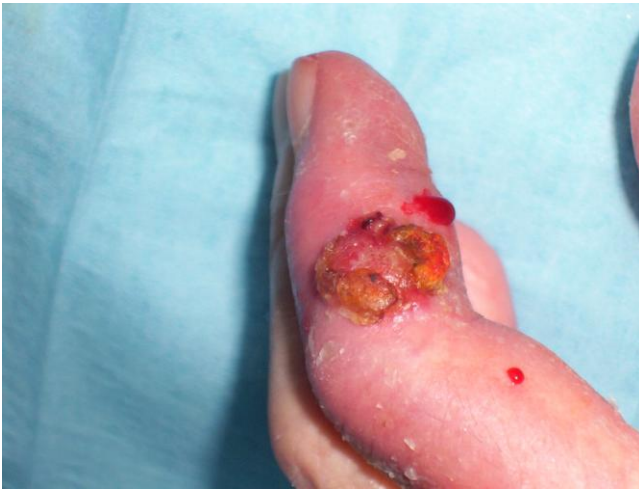

Figure 1: Ulcerated amelanotic nodule of the second finger, left hand

Frequent mitotic activity was present, with poor intra- or perilesional inflammation and no vascular involvement (Fig. 3 and 4); immunohistochemical staining, revealing strong S-100 and HMB-45 protein expression (Fig. 5), confirmed the diagnosis of amelanotic melanoma.

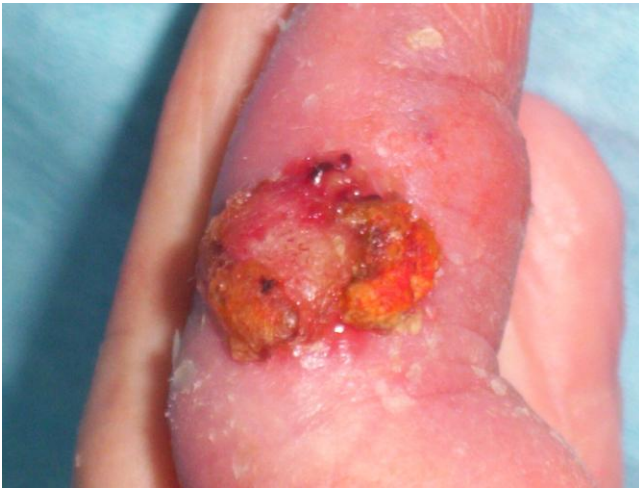

Figure 2: Particular of the lesion

Surgical excision of the neoplasm was requested, and the patient decided to continue the diagnostic and therapeutic procedure at another centre.

## Discussion

Malignant melanoma (MM) is one of the most aggressive malignant neoplasms with a steadily increasing incidence in the last 30 years as well as mortality, despite the advances in treatment [1, 2]. When localised at acral body sites, it is much more frequent in dark-skinned and Oriental populations [3].

Typically, the clinical hallmark of cutaneous MM is the presence of pigment, varying from black to blue, to the shades of brown, tan, pink and white, within lesions with irregular contours on clinical examination [4].

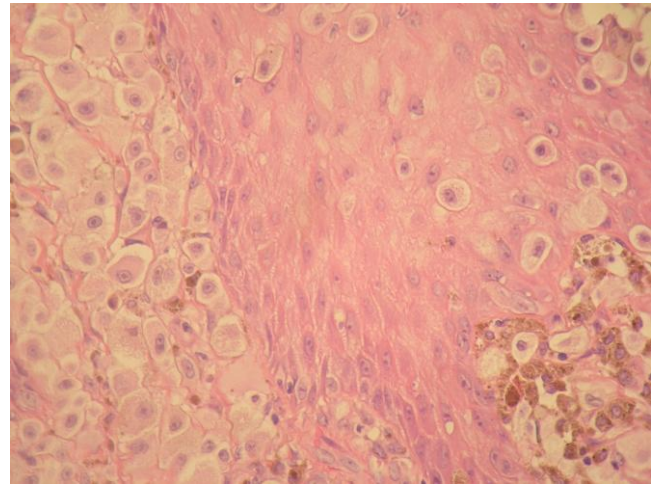


Figure 3: Histological view, H&E stain, original magnification x100 (detailed in the text)

On the contrary, amelanotic melanoma shows little or no pigment on visual inspection. Although the incidence of amelanotic melanoma among MM is low (2% to 8% of cases), the digits (and the subunguals) seem to be an area of predilection, a rate of about 25% of MM being amelanotic at these sites [5, 6]. In dermatologic consultation, the skilled eye of the specialized observer as well as dermoscopy, if applicable, are the unique instruments to make an often difficult diagnosis [7, 8], whereas radiographic studies of the part are useful to exclude bone lesions [9].

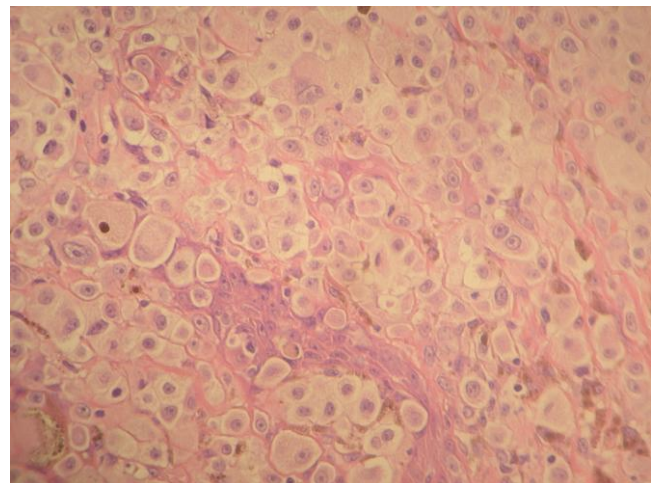


Figure 4: Histological view, H&E stain, original magnification x100 (detailed in the text)

In fact, there is still no evidence that amelanotic melanomas behave more aggressively than their pigmented counterpart, but the lack of pigmentation obviously adds further difficulties to an



already hard diagnosis. As in all types of MM, there is a direct relationship between increasing tumour thickness and decreasing survival time. Due to its atypical presentation, with consequent late detection, amelanotic melanoma is often diagnosed at a late stage of the disease with a worsened prognosis [4, 10].

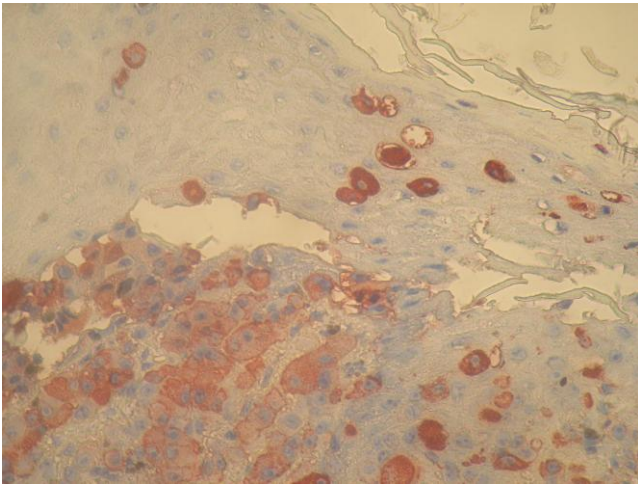


Figure 5: Immunohistochemical staining (HMB-45)

About our case, the confounding anamnesis represented an additional misleading, as the patient came from a rural area endemic for cutaneous leishmaniasis [11, 12] and the clinical picture of the condition was also evocative [13].

Also, immunosuppression in patients treated for the chronic autoimmune disease could theoretically facilitate the occurring of opportunistic infections [14]. This concern has to be dramatically stressed nowadays with the growing use of biotechnological drugs [15].

In conclusion, we presented the case with the aim of underlining the importance for physicians of performing incisional biopsies in the presence of clinically featureless cutaneous lesions. In particular, although asymptomatic, clearly growing amelanotic papules and nodules, with no of diagnostic criteria at imaging (e.g., Dermoscopy or x-ray) and with ulceration, should be histologically evaluated to exclude malignant melanoma at a first stage. Local or systemic prolonged medical treatments should be avoided in the absence of immediate improvement.

## References

1. Thompson JT, Scolyer RA, Kefford RF. Cutaneous melanoma. *Lancet*. 2005;365(9460):687-701. [https://doi.org/10.1016/S0140-6736\(05\)70937-5](https://doi.org/10.1016/S0140-6736(05)70937-5)

2. Bevelacqua V, Bevelacqua Y, Candido S, Skarmoutsou E, Amoroso A, Guarneri C, Strazzanti A, Gangemi P, Mazzarino MC, D'Amico F, McCubrey JA, Libra M, Malaponte G. Nectin like-5 overexpression correlates with the malignant phenotype in cutaneous Melanoma. *Oncotarget*. 2012;3(8):882-92. <https://doi.org/10.18632/oncotarget.594> PMID:PMC3478464
3. Russo A, Ficili B, Candido S, Pezzino FM, Guarneri C, Biondi A, Travali S, McCubrey JA, Spandidos DA, Libra M. Emerging targeted therapies for melanoma treatment (review). *Int J Oncol*. 2014;45(2):516-24. <https://doi.org/10.3892/ijo.2014.2481>
4. Wada M, Ito T, Tsuji G, Nakahara T, Hagihara A, Furue M, Uchi H. Acral lentiginous melanoma versus other melanoma: A single-center analysis in Japan. *J Dermatol*. 2017. <https://doi.org/10.1111/1346-8138.13834>
5. Guarneri C, Valenti G. Question: can you identify this condition? *Can Fam Physician*. 2008;54(12):1697, 1698.
6. Kato T, Suetake T, Sugiyama Y, Tabata N, Tagami H. Epidemiology and prognosis of subungual melanoma in 34 Japanese patients. *Br J Dermatol*. 1996;134:383-387. <https://doi.org/10.1111/j.1365-2133.1996.tb16218.x> PMID:8731657
7. McClain SE, Mayo KB, Shada AL, Smolkin ME, Patterson JW, Slingluff CL Jr. Amelanotic melanomas presenting as red skin lesions: a diagnostic challenge with potentially lethal consequences. *Int J Dermatol*. 2012;51(4):420-6. <https://doi.org/10.1111/j.1365-4632.2011.05066.x> PMID:22435430 PMID:PMC4465919
8. Guarneri C, Cannavò SP, Bevelacqua V, Urso C. A false diabetic foot ulcer. *J Am Geriatr Soc*. 2011;59(10):1964-6. [https://doi.org/10.1111/j.1532-5415.2011.03610\\_3.x](https://doi.org/10.1111/j.1532-5415.2011.03610_3.x) PMID:22091511
9. Guarneri C, Guarneri F, Risitano G, Lentini M, Vaccaro M. Solitary asymptomatic nodule of the great toe. *Int J Dermatol*. 2005;44(3):245-7. <https://doi.org/10.1111/j.1365-4632.2004.02475.x> PMID:15807738
10. Koch SE, Lange JR. Amelanotic melanoma: the great masquerader. *J Am Acad Dermatol*. 2000;42(5 Pt 1):731-4. <https://doi.org/10.1067/mjd.2000.103981> PMID:10775846
11. Guarneri C, Guarneri F. Symmetrical cutaneous leishmaniasis. *Acta Derm Venereol*. 2005;85(3):281-2. <https://doi.org/10.1080/00015550510026596>
12. Alvar J, Velez ID, Bern C, herrero M, Desieux P. WHO Leishmaniasis Control Team: leishmaniasis worldwide and global estimates of its incidence. *PLoS ONE*. 2012;7:e35671. <https://doi.org/10.1371/journal.pone.0035671> PMID:22693548 PMID:PMC3365071
13. Guarneri C, Tchernev G, Bevelacqua V, Lotti T, Nunnari G. The unwelcome trio: HIV plus cutaneous and visceral leishmaniasis. *Dermatol Ther*. 2016;29(2):88-91. <https://doi.org/10.1111/dth.12303> PMID:26555699
14. Ali T, Bronze MS, Kaitha S, Mahmood S, Ftaiis A, Stone J. Clinical use of anti-TNF therapy and increased risk of infections. *Drug Health Patient Saf*. 2013; 5:79-99. <https://doi.org/10.2147/DHPS.S28801> PMID:23569399 PMID:PMC3615849
15. Piaserico S, Conti A, Lo Console F, De Simone C, Prestinari F, Mazzotta A, Gualdi G, Guarneri C, Borsari S, Cassano N. Efficacy and safety of systemic treatments for psoriasis in elderly patients. *Acta Derm Venereol*. 2014;94(3):293-7. <https://doi.org/10.2340/00015555-1719> PMID:24158307