



ID Design 2012/DOOEL Skopje, Republic of Macedonia
 Open Access Macedonian Journal of Medical Sciences. 2017 Jul 25; 5(4):480-482.
Special Issue: Global Dermatology
<https://doi.org/10.3889/oamjms.2017.116>
 eISSN: 1857-9655
Case Report

Subungual Squamous Cell Carcinoma Associated with Long Standing Onychomycosis: Aggressive Surgical Approach with a Favourable Outcome

Yavor Grigorov¹, Stanislav Philipov², James Patterson³, Georgi Tchernev⁴, Serena Gianfaldoni⁵, Torello Lotti⁶, Uwe Wollina⁷*

¹University Hospital Lozenetz, Department of Orthopedics and Traumatology, Sofia, Bulgaria; ²Sofia University St. Kliment Ohridski - Faculty of Medicine, Department of General and Clinical Pathology, Sofia, Bulgaria; ³University of Virginia Health System, Pathology, Charlottesville, Virginia, United States; ⁴Medical Institute of the Ministry of Interior, Dermatology, Venereology and Dermatologic Surgery; Onkoderma, Private Clinic for Dermatologic Surgery, Dermatology and Surgery, Sofia 1407, Bulgaria; ⁵University G. Marconi of Rome, Dermatology and Venereology, Rome 00192, Italy; ⁶Chair of Dermatology, University of Rome G. Marconi, Rome 00186, Italy; ⁷Department of Dermatology and Allergology at the Academic Teaching Hospital Dresden-Friedrichstadt in Dresden, Germany

Abstract

Citation: Grigorov Y, Philipov S, Patterson J, Tchernev G, Gianfaldoni S, Lotti T, Wollina U. Subungual Squamous Cell Carcinoma Associated with Long Standing Onychomycosis: Aggressive Surgical Approach with a Favourable Outcome. Open Access Maced J Med Sci. 2017 Jul 25; 5(4):480-482. <https://doi.org/10.3889/oamjms.2017.116>

Keywords: Subungual squamous cell carcinoma; nail neoplasms; HPV; viral wart; surgery; onychomycosis.

***Correspondence:** Uwe Wollina, Department of Dermatology and Allergology, Academic Teaching Hospital Dresden-Friedrichstadt, Friedrichstr. 41, 01067 Dresden, Germany. E-mail: wollina-uw@khdf.de

Received: 15-Apr-2017; Revised: 26-Apr-2017; Accepted: 27-Apr-2017; Online first: 21-Jul-2017

Copyright: © 2017 Yavor Grigorov, Stanislav Philipov, James Patterson, Georgi Tchernev, Serena Gianfaldoni, Torello Lotti, Uwe Wollina. This is an open-access article distributed under the terms of the Creative Commons Attribution-NonCommercial 4.0 International License (CC BY-NC 4.0).

Funding: This research did not receive any financial support.

Competing Interests: The authors have declared that no competing interests exist.

BACKGROUND: Tumours of the nail bed are rare. Squamous cell carcinoma is the most frequent among them. Chronic infection, chemical or physical trauma/microtrauma, genetic disorders such as congenital ectodermal dysplasia, radiation, tar, arsenic or exposure to minerals, sun exposure, immunosuppression, and previous HPV infection have all been discussed as etiologic factors. The diagnosis is often delayed because of the variety of clinical manifestations, often resembling benign or common infectious processes. Rapidly growing ulcerative lesions should also be considered as potential malignancy. Furthermore, a lack of antifungal or antibacterial treatment response is the most indicative symptom, always requiring subungual biopsy. Early diagnosis is of great importance for therapeutic effectiveness.

CASE PRESENTATION: We present a case of subungual squamous cell carcinoma, associated with long-lasting onychomycosis in a 76-year-old female patient, treated with amputation of the distal phalanx and the distal part of the proximal phalanx.

CONCLUSION: Although there are no available data in the literature to confirm or reject the contribution of the chronic nail infection to the malignant process, we emphasise the importance of this co-existence regarding the possible disguising of the malignant process. An early biopsy of a chronic persistent nail lesion may be preventive and beneficial regarding avoiding more aggressive treatments and achieving a favourable prognosis.

Introduction

Subungual squamous cell carcinoma (SSCC) is a rare malignancy, with few reported cases affecting the toe reported in the medical literature [1]. The aetiology of these lesions is poorly understood, and although this location is associated with low risk for metastasis, cases with inguinal lymph node metastasis after amputation of the affected toe have also been described [1]. The diagnosis is often delayed because of the variety of clinical manifestations, often resembling benign or common infectious processes [2]. For that reason, the real incidence of this tumour is difficult to determine [2, 3]. Although a standardised therapeutic approach does

not currently exist, early diagnosis is essential for treatment effectiveness [3].

Case report

We present a 76-year-old Caucasian female patient who presented to the dermatology unit with a 3-year history of chronic, persistent ulceration on the left great toenail (Figure 1a). The diagnosis of onychomycosis was made three years ago, based on the clinical manifestation of yellowish discoloration of the nail, dystrophy of the nail, confirmed by direct

microscopy with KOH. No trauma was remembered by the patient, nor was there a history of viral warts. Arterial hypertension and arrhythmia were reported as comorbidities, well controlled with medications (Enalapril 10 mg 1-0-0, metoprolol 12.5 mg 1-0-0, and torasemid 20 mg 0-1-1). The initial symptoms were treated as an ordinary fungal infection with systemic administration of itraconazole and topical application of 40% urea cream, without significant effectiveness during the following year. Because of the lack of improvement, the nail bed was biopsied, and the diagnosis of SSCC was confirmed by histological examination (Figures 2a to d).

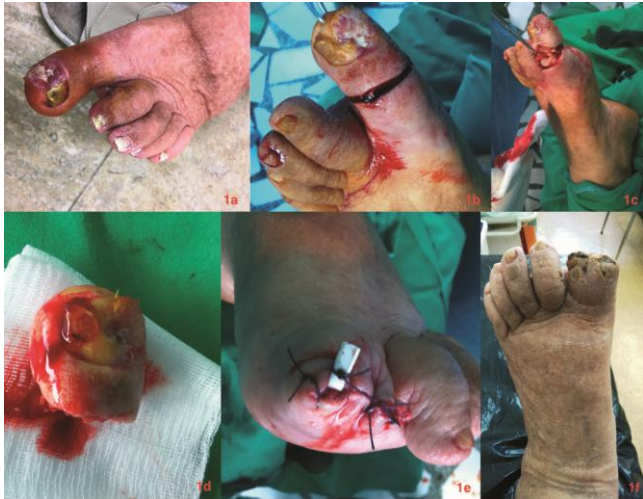

Figure 1: Clinical presentation: 1a - Chronic persistent ulceration in the left toe; 1b - Intraoperative findings. Skin incision; 1c - Disarticulation of the interphalangeal joint; 1d - The resected distal phalanx; 1e - Disarticulation completed - single layer suture and drainage; 1f - Clinical findings on the 16th postoperative day

Radiographic findings revealed cancer-mediated osteolysis. The patient underwent amputation of the distal phalanx of the left great toe and the distal part of the proximal phalanx (Figures 1a to d). Histopathological evaluation revealed low grade (moderately differentiated) invasive squamous cell carcinoma with vertical growth phase, multifocal superficial epidermal ulceration and non-invasive intraepidermal tumour component with histological degree - G2 and pathological staging - pT2NxMxV0L0R0. Image screening and laboratory testing did not show any evidence of disease progression or dissemination. At 17 months-follow-up the patient showed no signs of relapse.

Discussion

Disorders of the nail and nail bed are most frequently benign, and fungal infections account for approximately 50 % of them [3]. The remainder includes benign solid or cystic lesions and malignant neoplasms [3]. These conditions frequently resemble

one another clinically, making the early and correct diagnosis of nail disorders a challenge [1,3]. Subungual tumours are rare [2]. SSCC is the most frequent among all of the histological variants, in contrast to basal cell carcinoma, which almost never affects this location [2]. Bowen's disease of the nail apparatus is an important differential diagnosis [4]. Nevertheless, SSCC is a rare entity compared to SCC in other locations [3]. It can arise either from the nail bed, nail matrix, nail groove, or lateral folds [3, 5]. SSCC often affects a single digit, with the thumb and the great toe being most frequently involved [1-3]. Multiple finger involvement has also been described [5]. The incidence is higher in men between the fifth and seventh decades of life [1, 2, 6, 7]. The rare occurrence and indolent natural history of SSCC, along with the higher prevalence of other benign conditions affecting the unguis apparatus, often mislead the physician with a subsequent delay in the correct diagnosis and therapy, potentially leading to disease progression [2].

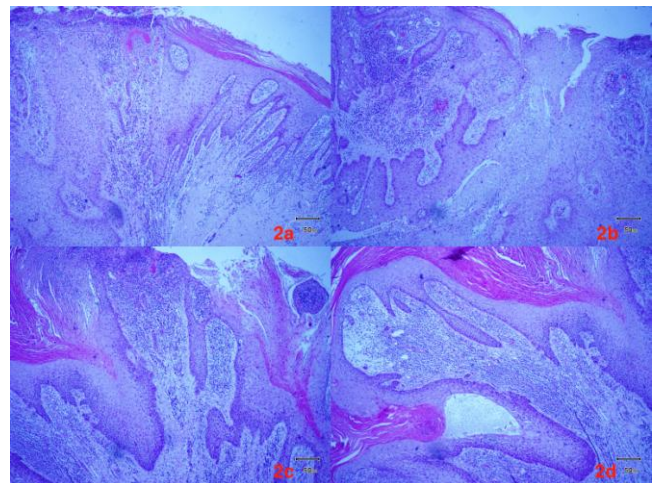


Figure 2: Histopathological findings (H-E staining, magnification 40x): 2a- Atypical keratinocytes extend from the epidermis into the dermis. Focal epidermal ulceration; 2b: Atypical cells have enlarged hyperchromatic nuclei with mitotic activity. Variable depth of dermal invasion. The stromal background consists of lymphocytes, plasma cells, and neutrophils; 2c: Epidermal papillomatosis and finger-like epidermal hyperplasia; 2d: Hyperkeratosis and keratin pearl formation. The non-specific inflammatory infiltrates with lymphocytes and plasma cells.

Chronic infection, chemical or physical trauma/microtrauma, genetic disorders such as congenital ectodermal dysplasia, radiation, tar, arsenic or exposure to minerals, sun exposure, immunosuppression, and previous HPV infection have all been discussed as etiologic factors that may contribute to malignant transformation [2]. HPV DNA has been recovered from 60% to 90% of cases of SSCC, and it has been stated that >60% are related to HPV 16 [2]. Although viral warts of the hands are also implicated as possible triggering factors for the development of SSCC, chronic HPV infection remains probably the most important factor, with or without the clinical presentation of conventional warts, which are rarely seen in patients with SSCC [2, 3].

In contrast to other locations, SSCC can cause very mild subjective symptoms, while at the same time presenting a variety of clinical manifestations [3]. Nonspecific ulcerative lesions or not significant swelling under the distal lateral edge of the nail can sometimes be the only presentations of the disease [3, 5]. Subungual, pigmented SCC presenting as grey longitudinal melanonychia has also been reported [6]. Late symptoms usually associated with an advanced process, including nodular lesions of the nail, bleeding, ulceration, or a large exophytic mass, are highly suggestive of malignancy [5, 6]. In particular, in any rapidly growing ulcerative lesion, a potential malignancy should be considered, especially SSCC [7]. Also, a lack of response to antifungal or antibacterial therapy is strongly suggestive of malignancy, virtually always requiring a subungual biopsy [6, 7].

Early diagnosis is of great importance for therapeutic effectiveness and to reduce the risk of recurrence or metastasis [8]. Although there is no standardised treatment for SSCC, wide local excision and simple excision are usually effective in early stages [1, 2, 8, 9]. The therapy of choice depends on the extent of the tumour and the presence or absence of underlying bone involvement [9, 10]. While lesions without bone involvement can be locally excised, amputation of the distal phalanx is usually the recommended treatment option for patients with bone infiltration [6]. Radiation therapy has also been reported as effective, depending on the tumour size and depth of invasion [9]. Possible bone involvement can be detected via imaging procedures [2, 6]. Exploratory nail plate removal and subsequent biopsy are advised in all patients with chronic nail conditions that fail to respond to conventional treatment for common infections [2]. Because of the high recurrence rate of SSCC, long-term follow-up is mandatory [2].

In conclusion, although chronic inflammation has been suggested as an etiological factor in SCC, it is still unclear whether chronic inflammation and in that case - persistent onychomycosis could trigger a malignant transformation of the nail bed, or such

association is just an occasional finding. While there are no available data in the literature to confirm or reject the contribution of the chronic subungual or periungual infection to the malignant transformation, we emphasise the importance of this co-existence regarding the possible disguising of the malignant process.

References

1. Kelly KJ, Kalani AD, Storrs S, Montenegro G, Fan C, Lee MH, Wallack MK. Subungual squamous cell carcinoma of the toe: working toward a standardised therapeutic approach. *J Surg Educ.* 2008;65: 297-301. <https://doi.org/10.1016/j.jsurg.2008.05.013> PMID:18707664
2. Batalla A, Feal C, Rosón E, Posada C. Subungual squamous cell carcinoma: a case series. *Indian J Dermatol.* 2014; 59: 352-354. <https://doi.org/10.4103/0019-5154.135480> PMID:25071252 PMCid:PMC4103269
3. Bui-Mansfield LT, Pulcini JP, Rose S. Subungual squamous cell carcinoma of the finger. *AJR Am J Roentgenol.* 2005; 185: 174-175. <https://doi.org/10.2214/ajr.185.1.01850174> PMID:15972419
4. Wollina U. Bowen's disease of the nail apparatus: a series of 8 patients and a literature review. *Wien Med Wochenschr.* 2015; 165: 401-405. <https://doi.org/10.1007/s10354-015-0383-4> PMID:26376982
5. Meesiri S. Subungual squamous cell carcinoma masquerading as chronic common infection. *J Med Assoc Thai.* 2010; 93: 248-251. PMID:20302009
6. Gatica-Torres M, Arguello-Guerra L, Manuel Ruiz-Matta J, Dominguez-Cherit J. Subungual pigmented squamous cell carcinoma presenting as a grey longitudinal melanonychia in a young patient. *BMJ Case Rep.* 2016: pii: bcr2016215390. <https://doi.org/10.1136/bcr-2016-215390>
7. Wessendorf U, Bruch-Gerharz D, Homey B, Schulte KW. Subungual squamous cell carcinoma. An important differential diagnosis of subungual tumors. *Hautarzt.* 2009; 60: 282-283. <https://doi.org/10.1007/s00105-009-1742-0> PMID:19296058
8. Kaksi SA, Ozdemir M, Balevi A, Cakir A, Tavh Y. Early diagnosis of subungual squamous cell carcinoma of the hallux. *Dermatol Online J.* 2015: pii: 13030/qt428217hj.
9. Wong KY, Ching DL, Gateley D. Subungual squamous cell carcinoma. *BMJ Case Rep.* 2015: pii: bcr2014207565, 2015. <https://doi.org/10.1136/bcr-2014-207565>