

ID Design 2012/DOOEL Skopje, Republic of Macedonia
Open Access Macedonian Journal of Medical Sciences. 2017 Jun 15; 5(3):335-339.
<https://doi.org/10.3889/oamjms.2017.073>
eISSN: 1857-9655
Clinical Science



Comparison of Diagnostic Value of Sonourethrography with Retrograde Urethrography in Diagnosis of Anterior Urethral Stricture

Reza Shahsavari¹, Seyed Morteza Bagheri^{2*}, Hamed Iraj¹

¹Resident of Radiology, Iran University of Medical Sciences, Tehran, Iran; ²Department of Radiology, Hasheminejad Kidney Center (HKC), Iran University of Medical Sciences, Tehran, Iran

Abstract

Citation: Shahsavari R, Bagheri SM, Iraj H. Comparison of Diagnostic Value of Sonourethrography with Retrograde Urethrography in Diagnosis of Anterior Urethral Stricture. Open Access Maced J Med Sci. 2017 Jun 15; 5(3):335-339. <https://doi.org/10.3889/oamjms.2017.073>

Keywords: Retrograde urethrography; Sonourethrography; Anterior urethral stricture.

***Correspondence:** Seyed Morteza Bagheri, Department of Radiology, Hasheminejad Kidney Center (HKC), Iran University of Medical Sciences, Tehran, Iran. Tel: +98912115 0807. E-mail: smb_53@yahoo.com

Received: 12-Mar-2017; Revised: 22-Mar-2017; Accepted: 04-Apr-2017; Online first: 11-Jun-2017

Copyright: © 2017 Reza Shahsavari, Seyed Morteza Bagheri, Hamed Iraj. This is an open-access article distributed under the terms of the Creative Commons Attribution-NonCommercial 4.0 International License (CC BY-NC 4.0).

Funding: This paper was an extract of Radiology PhD dissertation titled "Comparison of Diagnostic value of sonourethrography with retrograde urethrography in diagnosis of anterior urethral stricture among the patients resorting to Hasheminejad Hospital in 2012" presented in 2013 with the kind supports of Tehran University of Medical Sciences.

Competing Interests: The authors have declared that no competing interests exist.

BACKGROUND: In spite of the advanced imaging methods, MRI and CT-Scan, the role of ultrasonography is still unique in some fields of genitourinary tract diseases.

AIM: This study was aimed at assessing this role in the evaluation of male urinary stricture, and comparison with standard retrograde urethrography (SUG).

METHODS: This was a cross-sectional study. The patients include those who were suspected of anterior urethral stricture and were introduced assessed with imaging techniques (RUG). The patient underwent ultrasonography too. The results of both methods were compared. RUG was considered as the gold standard for this comparison.

RESULT: Ninety-seven patients were studied. The mean age was 46.9 ± 11.7 years (range 21-88 years), in RUG, 22 patients (22.8%) and SUG 23 patients (23.7%) had a stricture, 3 cases with a stricture in RUG had not evidenced of stenosis in SUG. The mean length of urethral stricture in RUG was 12.9 ± 8.1 mm and in SUG was 8.1 ± 7.3 mm. The estimated length in RUG way was significantly higher than SUG way ($P=0.025$). The sensitivity and specificity in using of SUG were 86.6% and 94.6%, respectively.

CONCLUSION: The result of this study showed stricture length measured by ultrasound is shorter than the length measured by RUG and the sensitivity and specificity in using of SUG was 86.6% and 94.6% respectively that due to the advantages it is an acceptable way.

Introduction

Urethral stricture is one of the common urethral tracts disorders among patients, especially male patients, with symptoms ranging from no symptom at all to decreased urine flow, increased the pressure required for urinating, urinating drop by drop, a feeling of incomplete urination and intense stricture symptoms such as urinary retention [1].

Obstructing the lower urinary tract is the obvious consequence of urethral stricture and it' continuance certainly impresses the life quality of involved patients. This disorder might be caused as a result of inflammatory, traumatic (pathogenic or not-pathogenic), ischemic or congenital processes [2, 3].

These processes result in the formation of scar tissue along the tract and reduce the calibre of the tract and cause resistance against the urine flow [4]. The term urethral stricture usually applies to stricture of anterior urethra. It is, in fact, a stricture in the urethral tracts which is second to Urothelium damage and formation of scar tissue in the urethral tracts (surrounded by corpus spongiosus) [5].

It is noteworthy that about 30% of urethral strictures are idiopathic; however, it seems that the little damage of the lining of the urethra causes urine to pass into spongy tissue and leads to fibrotic reactions within the spongy tissue. The narrowing of the urethra is estimated between 200 and 1200 cases per 100 thousand people, and it will be dramatically increased within people over 55 years. In estimation,

the prevalence of urethral stricture in industrial countries is around 0.9%.

Concerning the congenital disorders, these disorders are usually spotted in the fusion of anterior and posterior urethra [6]. Urethral stricture is usually diagnosed through clinical symptoms, and the diagnostic methods based upon imaging are confirmed through clinical diagnosis [7]. Currently, retrograde urethrogram (RUG) is the main diagnostic method to find anterior urethra stricture [8]. Further to diagnosing the stricture, this method helps us find the length of the stricture as well. Utilising a catheter which enters urethra through distal, the contrast material is injected inside the urethra, and its stricture and length are determined through oblique imaging and X-ray [9]. Although this method has a high degree of precision in identifying the stricture, it is not without deficits. In this method, Foley catheter gets inside the urethra which is no pleasant to most of the patients, and other side effects such as higher chances of infection might threaten the patient. On the other hand, using X-ray is inevitable, and patients and particularly testicles are exposed to X-ray radiation. Furthermore, just the inner area of the urethra is observed, and the periphery of the urethra and the strictures outside it cannot be diagnosed [1]. Thus doctors and researchers have sought to find simpler and more acceptable methods (for patients) that do not require X-ray radiation.

One of the alternative methods used for this purpose is the utilization of sonography to diagnose and find urethral strictures which are known as Sonourethrograph (SUG) [10]. SUG utilises surface probe along the genital to study the strictures. This method helps us check for the presence of stricture, the length of stricture, and her intensity and if there are any complications outside the urethra which cause the stricture [1]. However, the diagnostic value of this method has not been studied against that of RUG, and we need to determine the accuracy of this method against RUG.

Considering the great prevalence of urethral stricture and the necessity of using accurate, simple, cheap and acceptable methods, this study was designed so that her results might be to enhance the awareness of the experts, assistants and doctors who can use the results of utilizing SUG to diagnose urethral stricture and come up with better plans to treat the patients suffering from urethral stricture.

Material and Method

This is a cross-sectional test analysis study conducted in the imaging unit of Hasheminejad Hospital from 2012 to 2013. Having made the

necessary administrative arrangements and gained the necessary permits, all of the patients qualified for our research were made fully aware of the methodology, and goals of the research and then their formal and informed consent was gained to participate in our research. Then, other information such including age, the duration of the symptoms and other clinical backgrounds such as trauma, infection or congenital disorders was recorded. The patients included those suspected of urethral stricture that had resorted to the centre to be diagnosed by RUG. At the same time, the patients also underwent Sonourethrography. To conduct RUG, a sterilised Foley catheter was pushed 2 to 3 cm inside their urethra, and then meglumine contrast material was injected inside their urethra and graphic radiology was taken in the oblique position so as to diagnose stricture, site of the stricture and its length. Sonourethrography was also conducted. For this purpose, the tip of the syringe without a needle was inserted into the urethra to inject normal saline. After the urethra had been filled with normal saline, the urethral output was pressed so as to block the liquid from flowing out. Then, using the surface probe on the ventral surface of the genital up to the perineum area, the whole urethra was examined by sonography to determine the existence or absence of stricture, site of the stricture and its length. Sonourethrography was conducted in the sonography unit of Hasheminejad Hospital using Voluson 730 Pro device through its surface probe – with a frequency of 6 to 12 MHz. The results of both methods were compared against one another. RUG methods were set as the golden standard for this comparison, and the results of Sonourethrography were compared with it.

The convenient method was used for sampling, and all the patients qualified for the research entered the study so as to complete the volume of sample.

Considering the average sonography sensitivity based on the study of Akano (91%) [21], the error of the first type was set to 0.05, and the accuracy was set to 0.06 of the research sample (consisting of 97 people).

The research population included all the patients suspected of anterior urethra stricture based on the clinical symptoms who were introduced from the urology unit for imaging.

The inclusion criteria allowed only male patients suspected of anterior urethral stricture to be a candidate for imaging to diagnose stricture.

The exclusion criteria included the impossibility of conducting any RUG methods or Sonourethrography.

Mean, and the Standard deviation was used to represent quantitative variables, while frequency and ratio were selected to represent qualitative variables. The means were compared with T-test

Paired, and ratios were compared against the chi-2 test. Sensitivity, speciality, positive predictive value and negative predictive value were used to determine the diagnostic value of Sonourethrography against RUG. The agreement level between RUG and Sonourethrography was measured using Kappa test. The data was then analysed using SPSS version 16.

Results

The present research was conducted to compare the diagnostic value of Sonourethrography with retrograde urethrography (RUG) in diagnosing the anterior urethra stricture where 97 patients were studied. The average age of the participants was 46.95 ± 11.7 , and they all ranged from 21 to 88 years old (Figure1).

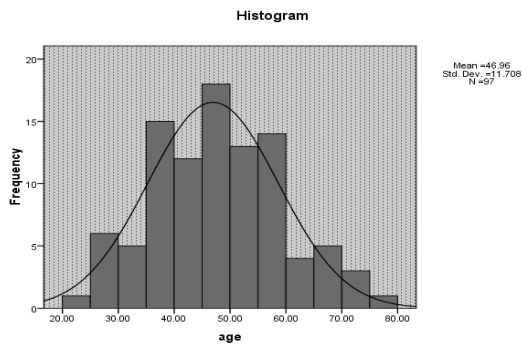


Figure 1: The age-frequency chart of the patients

Twenty-two patients (22.8%) were diagnosed with urethra stricture by RUG (Figure 2).

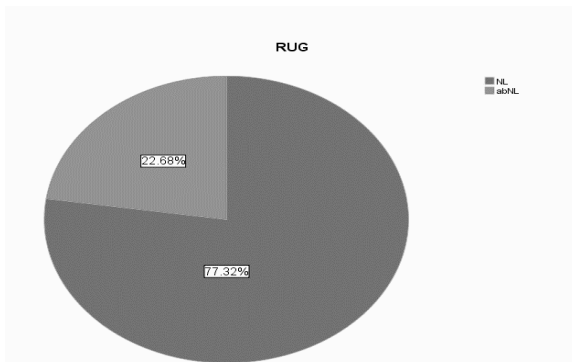


Figure 2: The frequency of stricture in RUG

Twenty-two patients (23.7%) were diagnosed with urethra stricture by Sonourethrography (Figure 3).

The patients were divided into 2 groups regarding the length and the number of strictures.

There was a group with local stricture whose length of single stricture was 1 cm or less. There was also another group with distributed stricture whose length of the single stricture was more than 1 cm or had multiple strictures.

According to the results of RUG, 11 patients (50%) were suffering from local stricture, and 11 (50%) were diagnosed with distributed stricture. In Sonourethrography imaging, 13 (56.6%) were diagnosed with local stricture, and 10 (43.5%) were suffering from distributed stricture.

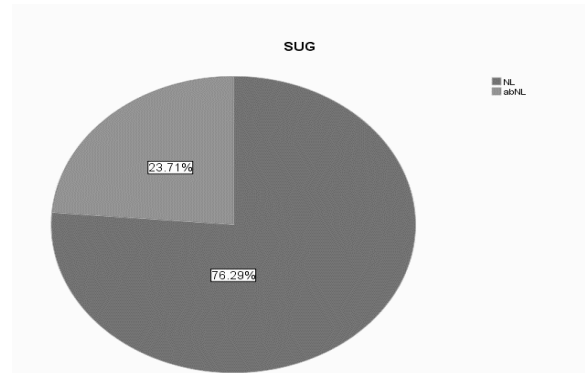


Figure 3: The frequency of stricture in SUG

Tree strictures reported in RUG were not diagnosed by Sonourethrography. There were also 4 strictures diagnosed by Sonourethrography which were not confirmed by RUG.

The average length of the urethra measured by RUG method was 12.96 ± 8.19 mm, and the average length of urethra stricture measured through Sonourethrography was 8.16 ± 7.39 mm. The length of the stricture measured through RUG method was significantly longer than the stricture measured through Sonourethrography ($P = 0.025$).

The results exclusively achieved through sonography were mostly concerned with the existence of heterogeneous and echogenic masses outside the urethra and the irregularities of the inner wall of the urethra.

Considering the Gold Standard and keeping in mind the RUG as a method to investigate the urethra stricture and with a view of the results of sonography, there were 19 true positives, 71 true negatives, 4 false positives and 3 false negative cases (Table 1).

Table 1: Sensitivity, speciality, positive declarative value and negative declarative value

Sensitivity	86.63%
Specialty	94.66%
Positive declarative value	82.6%
Negative declarative value	95.94%

Among the 4 false positive cases, 1 had

distributed stricture, and 3 were diagnosed with local stricture. Among the 3 false negative cases in Sonourethrography, 1 had distributed stricture, and 2 were suffering from local stricture.

Discussion

Perfect detection of urethral strictures is critical and determinative for preoperative decisions and reconstruction management. Currently, the retrograde urethrography (RUG), as standard gold technique, is utilised for diagnosis. The current gold standard is also recruited for delicate illustration of urethral strictures disease in the most accurate way. Sonourethrography (SU) is another powerful alternative method for three-dimensional (3-D) evaluation of stricture location and structure, and can be a reliable intraoperative applicable device; nevertheless, it is coupled with some limitations.

Although there are several reports concerning the initial successful applications of ultrasonography in checking and diagnosing the anterior urethra stricture among men [12-14] and this method is completely safe and tolerable and easily affordable, it has not routinely attracted the attention of the urologists at least in Iran. The present research seeks to compare its strengths and weaknesses against retrograde urethrography by repeating this experience. This research studied 97 patients suspicious of urethra stricture with the average age of 47, and they all ranged from 21 to 88 years old.

Further to eliminating the adverse effects of X-ray radiation on gonads, sonography can be easily expanded to the bladder and kidneys and reveals the accompanying pathologies.

Based on the results of the studies, using sonography in measuring the stricture of the anterior urethra is as accurate as retrograde urethrography in determining the length of the stricture, particularly local strictures further to providing us with good information about selecting the appropriate therapeutic method and its pre-awareness by determining the scar anatomy of the stricture site and diagnosing cases such as urethra stones or pre-urethral abscess.

In the research conducted by Heinrich et al., a sensitivity of 98% and a speciality of 96% was reported for Sonourethrography in diagnosing the urethra strictures [18].

Maciejewski and colleagues in 2015 in a literature review regarding the different techniques in the diagnosis of urethral stricture disease reported that RUG has 75 - 100% sensitivity and 72 - 97% specificity. They declared that RUG has a Positive

predictive values (PPV) in the range of 50 to 93% and negative predictive values (NPV) between 76 to 100%. They also reported that SU has 66 - 100% sensitivity, about 97 - 98% specificity. In their study, the PPV and NPV of SU are estimated 50 - 80% and 96 - 98% respectively.

As for the present research, the sensitivity and speciality of sonography in diagnosing strictures was 86% and 94% respectively with the value of its negative prediction being more than the value of positive prediction (96% vs. 82%).

In another study conducted by Peskar et al., the accuracy of sonography compared to retrograde urethrography in diagnosing urethra stricture was 92% [19]. Other researches have also reported that the accuracy of sonography in diagnosing stricture is equal to or more than retrograde urethrography [11, 15].

In this research, the results exclusively achieved through sonography were mostly concerned with the existence of heterogeneous and echogenic masses outside the urethra and the irregularities of the inner wall of the urethra.

In the present study, 3 of the stricture reported in RUG were not diagnosed in sonography. Non-diagnosis of stricture in retrograde urethrography might be due to the inappropriate angle [20] where correcting this angle in some researches resulted in higher diagnostic precision.

There are different reports concerning the accuracy of sonography in determining the length of the stricture. The length of the stricture in some researches measured through Sonourethrography was more than the value measure through retrograde urethrography, while other researches have reported longer or equal lengths for both methods.

The average length of the urethra stricture measured through the RUG method was 12.96 mm, while Sonourethrography reported a length of 8.16 mm. The length measured through RUG method was significantly more than the value reported through Sonourethrography method.

Another study conducted by Morey et al. reported that the length of the stricture measured through Sonourethrography was twice or even more as long as the value reported through urthrography [16].

In the research conducted by Peskar, the length of the stricture in Sonourethrography was 22% shorter than the value reported through retrograde urethrography. Keeping in mind the radiographic magnification which was later corrected, there was no difference between the sizes [17].

Reports of bigger sizes through Sonourethrography despite the exaggeration by retrograde urethrography can be attributed to the

existence of fibrosis in the two ends of the stricture which urethrography is usually unable to account for them.

In sum, the results of the present research showed that the length of the stricture measure through sonography is shorter than the length measured through RUG. The sensitivity and speciality of this method compared to RUG in diagnosing strictures was 86% and 94% respectively which are acceptable levels keeping in mind its advantages. We may finally come up with the conclusion that Sonourethrography is a simple, convenient and repeatable method that does not expose the patient to the ionising radiation. To achieve more accurate results, these findings need to be compared to the results of surgeries so that we can precisely decide which method is more accurate.

Acknowledgement

This paper was an extract of Radiology PhD dissertation titled "Comparison of Diagnostic value of sonourethrography with retrograde urethrography in diagnosis of anterior urethral stricture among the patients resorting to Hasheminejad Hospital in 2012" presented in 2013 with the kind supports of Tehran University of Medical Sciences.

References

- Jordan GH, Schlossberg SM. Surgery of the penis and urethra. In: Wein AJ, et al, eds. Campbell-Walsh Urology. Vol 1. 9th ed. Philadelphia, Pa: WB Saunders Co., 2007:1023-97.
- Morey AF, Metro MJ, Carney KJ, et al. Consensus of genitourinary trauma: External genitalia. *BJU Int.* 2004;94:507-15. <https://doi.org/10.1111/j.1464-410X.2004.04993.x> PMID:15329102
- Mundy AR. Management of urethral strictures. *Postgrad Med J.* 2006;82(970):489-9. <https://doi.org/10.1136/pgmj.2005.042945> PMID:16891437 PMCID:PMC2585709
- Aboushwareb T, Atala A. Stem cells in urology. *Nat Clin Pract Urol.* 2008;5(11):621-31. <https://doi.org/10.1038/ncpuro1228> PMID:18852709
- Angermeier KW, Jordan GH, Schlossberg SM. Complex urethral reconstruction. *Urol Clin North Am.* 1994;21(3):567-81. PMID:8059509
- Shah DK, Paul EM, Badlani GH. North American Study Group: recurrent bulbar urethral stricture. *J Urol.* 2003;170(4 Pt 1):1255-8. <https://doi.org/10.1097/01.ju.0000087623.82024.f2> PMID:14501736
- Kawashima A, Sandler CM, Wasserman NF, LeRoy AJ, King BF, Goldman SM. Imaging of urethral disease: a pictorial review. *Radio Graphics.* 2005;24:S145-S216.
- Breyer BN, Cooperberg MR, McAninch JW, Master VA. Improper retrograde urethrogram technique leads to incorrect diagnosis. *J Urol.* 2009;182:716-717. <https://doi.org/10.1016/j.juro.2009.04.060> PMID:19539321
- Zhang XM, Hu WL, He HX, et al. Diagnosis of male posterior urethral stricture: comparison of 64-MDCT urethrography vs. standard urethrography. *Abdom Imaging.* 2011;36(6):771-5. <https://doi.org/10.1007/s00261-010-9676-7> PMID:21165616
- Kawashima A, Vrtiska TJ, LeRoy AJ, et al. CT urography. *Radiographics.* 2004;24:S35-S58. <https://doi.org/10.1148/rq.24si045513> PMID:15486248
- McAninch JW, Laing FC, Jeffery RB. Sonourethrography in the evaluation of urethral stricture: a preliminary report. *J Urol.* 1999; 139:294-297.
- García-Medina V, Berna JD, Llerena J, Garcia-Medina J, Genoves JL. Urethral sonography in the diagnosis of penile and bulbar urethral stenosis. *Eur J Radiol.* 1992;14(1):31-6. [https://doi.org/10.1016/0720-048X\(92\)90058-H](https://doi.org/10.1016/0720-048X(92)90058-H)
- Mc Aninch JW, Laing FC, Jeffery RB. Sonourethrography in the evaluation of urethral strictures:A preliminary study. *J Urol.* 1988;139:294.
- Merkle W, Wagner W. Sonography of the distal male urethra:A new diagnosis procedure for urethral strictures: Results of Retrospective study. *Urol.*1988; 40: 1409.
- Pushikarna R, Bhargava SK, Jain M. Ultrasonographic evaluation of abnormalities of the male anterior urethra. *Ind J Radiol Image.* 2006; 10(2): 89-91.
- Morey AF, McAninch JW. Role of preoperative sonourethrography in bulbar urethral reconstruction. *J Urol.* 2012; 158(4): 1376- 9. [https://doi.org/10.1016/S0022-5347\(01\)64219-8](https://doi.org/10.1016/S0022-5347(01)64219-8)
- Gallentin ML, Morey AF. Imaging of the male urethra for stricture disease. *Urol Clin North Am.* 2012; 29(2): 361-72. [https://doi.org/10.1016/S0094-0143\(02\)00028-9](https://doi.org/10.1016/S0094-0143(02)00028-9)
- Heinerich A, Derschum W, Bonfig R, Wilbert DM. Ultrasound of urethral stricture disease: a prospective study in 175 patients. *British Journal of urology.* 2011; 74: 93-98.
- Peskar DB, Perovic AV. Stricture of the male urethra: how to perform and evaluate radiourethrography and sonourethrography to avoid mistakes. *Radiol Oncol.* 2008; 34(2): 175-84.
- Jordan GH, Schlossberg SM. Surgery of the penis and urethra: In Walsh P.C., Petik A.B., Vaughan E.D., et al (eds): Campbell's urology, 8th edition, Philadelphia, Saunders company, 2002; 3918.
- Akano AO. Evaluation of male anterior urethral strictures by ultrasonography compared with retrograde urethrography. *West Afr J Med.* 2007;26(2):102-5. PMID:17939309