

Open Access Maced J Med Sci electronic publication ahead of print,
published on December 13, 2016 as <http://dx.doi.org/10.3889/oamjms.2016.140>

ID Design 2012/DOOEL Skopje, Republic of Macedonia
Open Access Macedonian Journal of Medical Sciences.
<http://dx.doi.org/10.3889/oamjms.2016.140>
eISSN: 1857-9655
Stomatology



Can Low Level Laser Therapy Benefit Bone Regeneration in Localized Maxillary Cystic Defects? - A Prospective Randomized Control Trial

Ahmed Abbas Zaky¹, Hanaa Mohamed Mohamed El Shenawy^{2*}, Tarek Abdel Hamed Harhsh¹, Mahmoud Shalash³, Noha Mohamed Ismael Awad³

¹National Institute of Laser Enhanced Sciences, Cairo University, Cairo, Egypt; ²Surgery and Oral Medicine Department, National Research Center, Cairo, Egypt; ³Oral Surgery and Medicine Department, National Research Center, Cairo, Egypt

Abstract

Citation: Zaky AA, El Shenawy HMM, Harhsh TAH, Shalash M, Awad NMI. Can Low Level Laser Therapy Benefit Bone Regeneration in Localized Maxillary Cystic Defects? - A Prospective Randomized Control Trial. Open Access Maced J Med Sci. 2016;140:1-6. <http://dx.doi.org/10.3889/oamjms.2016.140>

Keywords: LLLT; low intensity pulsed ultrasound; cystic lesion; digital radiograph.

***Correspondence:** Associate Prof. Dr Hanaa Mohamed Elshenawy, Surgery and Oral Medicine Department, National Research Center, Cairo, Egypt. E-mail: dr.hanaa.shenawy@gmail.com

Received: 20-Nov-2016; **Revised:** 24-Nov-2016; **Accepted:** 26-Nov-2016; **Online first:** 13-Dec-2016

Copyright: © 2016 Ahmed Abbas Zaky, Hanaa Mohamed Mohamed El Shenawy, Tarek Abdel Hamed Harhsh, Mahmoud Shalash, Noha Mohamed Ismael Awad. This is an open-access article distributed under the terms of the Creative Commons Attribution-NonCommercial 4.0 International License (CC BY-NC 4.0).

Funding: This research did not receive any financial support.

Competing Interests: The authors have declared that no competing interests exist.

AIM: The aim of the study was to evaluate the effect of Low-Level Laser Therapy (LLLT) on bone formation in cystic defects following cyst enucleation.

PATIENTS AND METHODS: The sample was composed of sixteen patients with enucleated maxillary bony cystic lesions. With an age range from 20 - 44 grouped as eight Laser and eight Control patients. Laser group was subjected to low intensity diode laser immediately after surgery and then for three times per week for two weeks using a therapeutic laser irradiation. Group B (control group): patients were not subjected laser therapy.

RESULTS: The predictor variable was exposure of bone defect to LLLT or none. The outcome variable was bone density changes measured by digital radiographs at day 1 and days 90 postoperatively. Descriptive and bivariate statistics were computed. There were no statistically significant differences between the 2 groups for the bone density at day 1. There was a statistically significant difference in bone density changes in each group at day 90: Significant at $P \leq 0.05$. After adjusting for differences in day 1 for bone density, the estimated mean change in bone density changes at day 90 was significantly larger for Laser compared with control.

CONCLUSION: The results of this study suggested that LLLT can enhance bone healing in maxillary cystic defects. This can serve as an adjunct method in preventing possible delayed healing and pathological fractures This also will be helpful for more researchers in early loading in case of dental implants to accelerate osseointegration.

Introduction

A standout among well-known issues confronted by oral and maxillofacial specialists are the osseous defects and dead spaces and how can be obliterated and augmented in the facial regions. unerupted tooth and bone loss after its removal, remaining roots and enucleation of cysts. all of these makes prosthetic rehabilitation and implant application more complicated [1].

Bone is undergoes remodelling via cycles of bone resorption and bone formation which is considered a mineralized connective tissue [2], an inflammatory immune reaction which is triggered by local injury which is thought to highly influence the

outcome of the bone healing process [3]. Low-Level Laser Therapy (LLLT) is a form of phototherapy that involves the application of low power monochromatic and coherent light to areas of injuries and lesions. It has been shown to induce wound healing in non-healing bone defects [4].

The bone healing is a multidimensional process of reconstruction of the bone tissue with an overlapping timeline. Because of the regeneration ability of the bone, bone defects can heal spontaneously under suitable physiological environmental conditions. The healing process of the bone defect is time-consuming, and new bone generation takes place slowly because of diminished of blood supply to the fracture site and insufficiency of calcium and phosphorus to strengthen and harden

new bone [5].

The low-level laser therapy (LLLT) has a positive effect on bone tissue metabolism and on fracture consolidation [6, 7]. 980-nm GaAlAs low-intensity diode laser irradiation is beneficial for the initial stages of alveolar bone healing and for further calcification. In both diabetic and normal rats under histological observations and gene expression analyses when applied every day at a dose of 13.95 J/cm² for 60 sec [8].

The purpose of this study was to evaluate the effect of LLLT on bone healing. The investigators hypothesised that LLLT will have an effect on stimulation of bone healing, more than in control group. The specific aims of the study were: measuring the bone density by assessing the bone density changes after applying LLLT using direct digital radiography (Diogra).

Patients and Methods

This research was approved by National Research Center (Medical Research ethical Committee).

The study included sixteen healthy patients with an age range of 20-44 years presenting with intrabody maxillary cystic lesions that were blindly divided into two equal groups, eight patients each; Laser group, where patients were subjected to low-intensity diode laser application after surgery to the area of the enucleated lesion and Control group where patients were not subjected to low-level laser therapy.

Patients were assessed radiographically for changes in bone density using direct digital images that were obtained by means of size 2 photostimulable plate (PSP) using the Digora Optime imaging system (Soredex, Tuusula, Finland) at day 1 postoperative and at day 90.

The study population was composed of all patients presenting to National Research Center, Giza, Egypt for evaluation and management of painful maxillary anterior teeth with a cystic lesion to be included in the study sample cystic lesion with maximum size 3 x 4 cm. Patients were excluded as study subjects if they have any systemic disease that interferes with bone healing.

Following a thorough preoperative assessment, patients were scheduled for enucleation of the cystic lesions (Fig. 1) and were randomly divided into 2 equal groups.

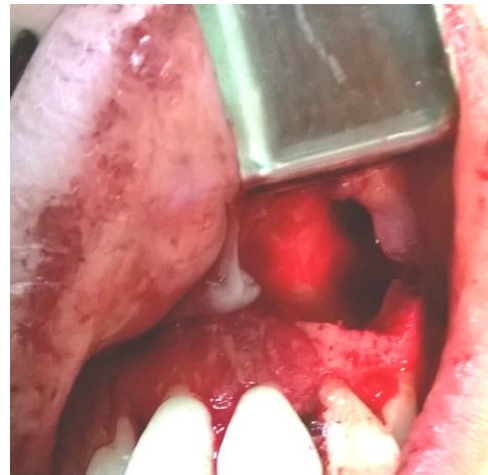

Figure 1: Photograph showing the bony cavity after removal of the cyst

Group A (Laser group): Patients were subjected to low intensity diode laser "soft-laser-SL202" ("PERTO LASER", pr. Stachek, 47, Saint-Petersburg, 198097, Russia) immediately after surgery and then for three times per week for two weeks. The method of irradiation is scanning uniformly over a surface of the lesion. The spot diameter 2mm. with the intensity 1591 mW/cm² and the dosage 24 J/cm², that corresponds to action by continuously modulated radiation (CW mode) of power 50 mW with an 870nm wavelength and exposure time 60 sec (Fig. 2).

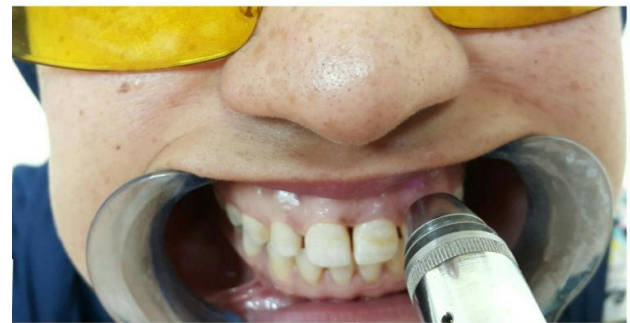

Figure 2: Photograph showing application of LLLT

Group B (control group): patients were not subjected to low-level laser therapy.

Data was analysed by Descriptive and Method of Density Measurement with Area measurement (area density index) (Fig. 3).

A rectangle area was marked included the area of enucleated cyst and apices of the affected teeth to take the mean of density in the bone area, but digora software does not allow hands-free measurements - only rectangle measurements.

Patients were evaluated at day 1 and day 90 for changes in bone density using digital radiography (Soredex, Tuusula, Finland) operating with tube voltage 70 kVp and tube current 7 mA at 0.08 second.

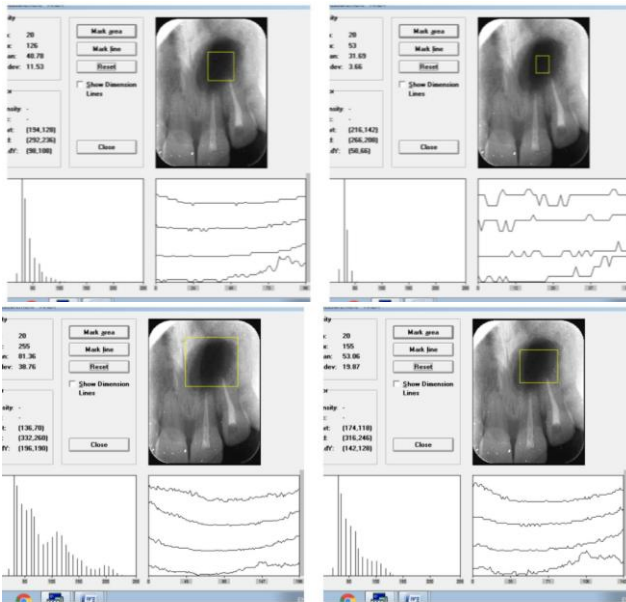


Figure 3: A digital radiograph of one of the investigated cases demonstrating rectangles drawn to calculate the mean of area density measurement

Results

Descriptive statistics of (bone density) for different experimental factors (time and treatment groups)

The results of bone density for different experimental factors are shown in Table 1.

Table 1: Descriptive statistics for the primary outcome variable (bone density) for different experimental factors (time and treatment option)

Treatment option	Time	Mean	SD	SE	CI	Max	Min
Laser	Day 1	52.559	8.562	1.211	2.433	65	30.85
	Day 90	98.384	10.956	1.549	3.114	132	87
Control	Day 1	52.99	7.566	1.07	2.15	69.45	40
	Day 90	55.764	7.437	1.052	2.114	71.3	45

SD: Standard deviation; SE=standard error of mean; CI=confidence interval of the mean; Max=Maximum recorded value; Min = Minimum recorded value.

Laser (A) group: The highest Bone density mean value was recorded at (day 90) (98.384). While the least Bone density mean value was recorded within (day 1) (52.559). There was a statistically significant difference between (Day1) and (day 90), 45.825 where p-value < 0.001.

For Control (B) groups: The highest Bone density mean value was recorded at (day 90) (55.764) and the least bone density on day 1 (52.99). There was a statistical significance difference between (Day 1) and day 90, 2.775 where (p = 0.067).

Comparison of (bone density) for different experimental factors (time and treatment option)

The results of comparison for bone density for different experimental factors (time and treatment option) are shown in Table 2.

Table 2: Comparison of (bone density) for different experimental factors (time and treatment option)

	Laser		Control		F- value	P-value
	Mean	SD	Mean	SD		
Day 1	52.559	8.562	52.99	7.566	1.956	0.145
Day 90	98.384	10.956 ^a	55.764	7.437 ^c	332.872	<0.001*
Difference	45.825		2.775			
t-value	23.304		1.849			
P-value	<0.001*		0.067			

SD = standard deviation; Different small letters indicate significant difference according to Tukey test; the subscribed value is the P-value for the Tukey test, * is Significant at P ≤ 0.05.

At day 1 there was no statistical significance difference between (Laser) (52.559) and (Control) (52.99), where p = 0.145.

Table 3: The mean, standard deviation (SD) and percentage of bone density change after different methods of treatments

Variables	Change in bone density		% of change	
	Mean	± SD	Mean	± SD
Groups				
Laser (A)	43.85	±11.06 ^b	77.94 %	±17.94%
Control (B)	13.64	±1.34 ^a	24.18 %	±5.98%
P-value	0.001*			

At day 90 there was a statistically significant in favour of the laser group compared to control group (Table 3).

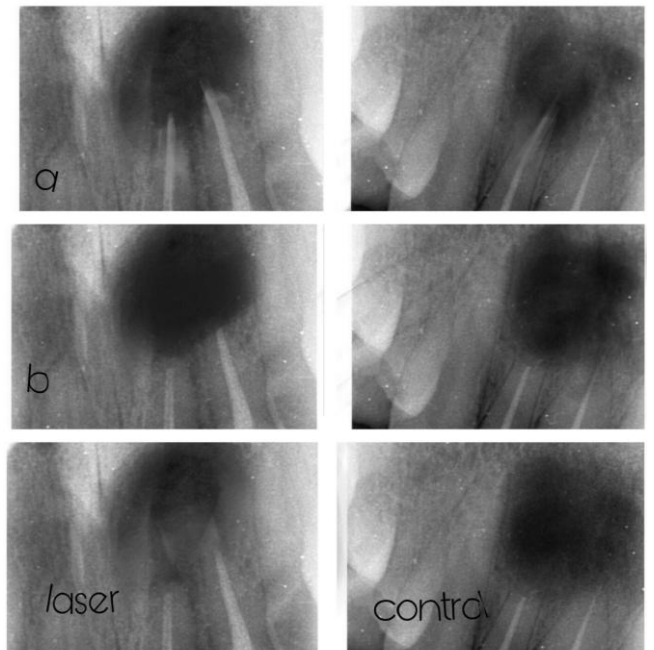


Figure 4: Photo radiographs showing changes in bone density in the two groups where a) preoperative, b) day 1 postoperative and day 90 postoperative the last one

Pain Scores Results

For Laser (A) groups the results showed that there is a significant decrease in pain scores from day 1 (6.5 ± 1) till day 3 (2 ± 0) and day 5 (0.5 ± 0.5) with no pain at all in day 10 (Fig. 5A).

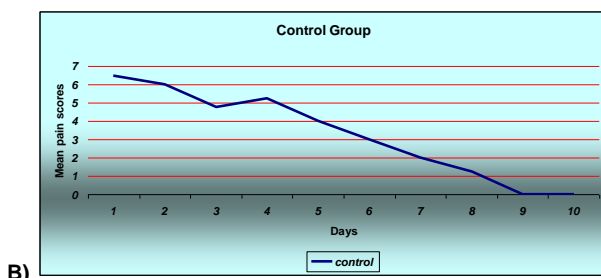
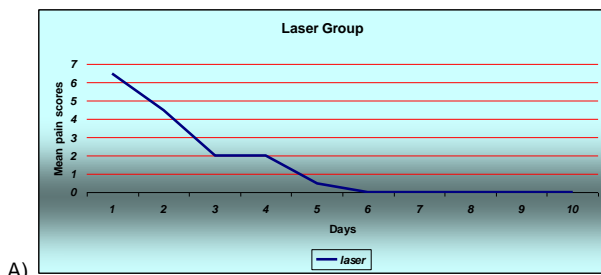


Figure 5: A) Line chart representing pain scores in Laser group; B) Line chart representing pain scores in Control group

For Control (C) groups the results showed that there is a decrease in pain scores from day 1 (6.5 ± 1) but there was an increase again in pain on day 4 (5.25 ± 1.25) then a gradual decrease in pain till day 8 (1.25 ± 0.75) (Fig. 5B).

The results showed that there was a significant decrease in pain scores in Laser group as compared to the control group.

Discussion

After enucleation of jaw cysts, the residual cavity is a common bone defect. Osteogenesis of bone in the cystic cavity begins with the formation of a blood clot, which is later replaced by osteogenic granulation tissue [9]. So, the objective of the current study was to evaluate the stimulatory effect of low-level laser therapy on osteogenesis following enucleation of maxillary cystic lesions. The results showed more superior effects of laser on bone density.

For the preservation of morphological contour, which is obligatory for prohibition the surrounding soft tissue incorporation into the bony defect, restoration of mechanical strength & function, and prevention of infection is very important. The applying new modalities for promoting bone repair are very

important [10-12].

LLLT and its biostimulation effect were studied in different fields. Most of these studies were directed towards the effect of LLLT on wound healing. But its effect on bone remodelling and repair is deficient in the literature [13-15].

Results of many studies seem to depend on delivery of appropriate energy levels, the type of laser (wavelength) used, the frequency of session and duration of exposure. Several of these studies did not describe the levels of laser energy used to stimulate stimulatory effects or the exposure parameters. This caused controversy when determining whether or not these lasers influence healing effect [16, 17].

In this study, sixteen patients were presented with intrabody maxillary cystic lesions were divided into two equal groups, eight patients each; Laser group, where patients were subjected to low intensity diode laser with 870 nm wavelength the spot diameter 2mm with the intensity 1.592 mW/cm^2 and the dosage 24 J/cm^2 , that corresponds to action by continuously modulated radiation (CW mode) of power 50 mW and exposure time 60 sec. Application after surgery to the area of the enucleated lesion and a Control group where patients were not subjected to low-level laser therapy.

In this study, enucleation was chosen over marsupialization following the universal agreement to the treatment goals and basic therapeutic principles of surgical enucleation of the cyst and obturation of the root canal of the affected teeth to eliminate the necrotic tissues (bacteria and toxins) and avoid the recurrence [18].

In laser group patients were subjected to low-intensity diode laser immediately after surgery for three times per week for two weeks. This was in accordance with a study which discussed the effect of low-intensity laser on bony cavities after removal of cysts of the jaws and applied low-level laser therapy starting from the second day of the surgery for two weeks, three times per week.

But there was another study [18] which discussed the effect of low-level laser therapy (LLLT), using a GaAlAs diode laser device, on bone healing and growth in rat calvarial bone. Diode laser was applied immediately after surgery and then daily for 6 sequential days. The tissue samples from the experimental animals contained significantly more calcium, phosphorus, and protein with additionally maintained angiogenesis than the control group. Furthermore, connective tissue formation and more advanced bone formation were found in the experimental group than in the controls.

The bone density was measured at day 1 and day 90 postoperatively. This time was chosen in the current study close to the time of a previous study in which the cone beam digital radiographs were

performed to measure the bone density within the bony cavity in groups of study at time intervals of day 1 and 4 months after the surgical procedure.

Comparing both groups regarding the change of bone density throughout the study period showed there was no significant difference between both groups at day 1 post surgically, while the bone density in laser group was statistically highly significant than the control group at four months post-surgically.

Radiography is the major non-surgical method for detecting bone formation in a healing osseous defect. Thus it is useful in clinical situations because of its continuity of measurements, and non-invasive nature. Bone healing is radiographically expressed as an increase in radiopacity, resulting in a higher optical density of the bone image. Computed tomography is a more precise method to evaluate the bone healing process after cyst enucleation, but it produces a relatively high cost for routine follow-up examination [19].

Evaluation of bone density was carried out at the apical area to assess the changes in density within three months from the day of cyst enucleation. The results of the current study revealed an increase in the bone density in laser group throughout the follow-up period. This was the same results revealed in many other studies [13, 14, 20] which found that the area of greatest bone destruction is usually centred around the apex of the tooth with sclerotic pattern located at the periphery. This is an area which has the highest healing activity.

The bone density of the patients in laser group was higher than that the control group three months post-surgically. These results were found to be significant. This could be explained according to the results of several studies [2, 9, 23-25] which detected that, low-intensity laser was found to stimulate microcirculation, enhance fibroblast proliferation, increase osteoblastic activity and stimulate the production of ATP which plays an important role in accelerating mitosis, as well as improving the host immune response. Moreover, the use of low-level laser therapy (LLLT) could enhance callus development in the early stage of the healing process [26], with doubtful improvement in biomechanical properties of the healing bone.

The rate of increase of bone density was significantly higher in the laser group. This enhancement of osteogenesis was thought to be due to the increase of osteoblastic activity induced by laser application [23]. LLLT induces the expression of bone morphogenic protein-2 (BMP-2), transforming growth factor- β (TGF- β) in 1% hypoxic cultured human osteoblasts, osteocalcin, type I collagen and so enhance osteogenesis. That also matched with another study [25] which reported a significance increase in the recorded levels of alkaline phosphatase enzyme, which is a common parameter that measures the differentiation of osteoblasts and

identifies osteogenic activity. It is known to be associated with bone metabolism and differentiation of osteoblasts. This also was in agreement with another study which concluded that soft diode laser has a biostimulation effect in the process of bone formation after surgical bone removal and that it increase bone repair at early bone healing.

These results also were in agreement with several studies [8, 14, 26], which the authors recorded an increase in the percentage of bone density values in the laser groups when compared with the non-laser groups. The low-intensity laser was proven to have a stimulatory effect on bone regeneration and apposition.

Furthermore, these findings have a great support with histological observations, which explained by further studies [8, 18, 27]. By using atomic absorption spectroscopy, colorimetry, and photometry used to determine the levels of calcium, phosphorus, and protein. They found that in the experimental group [GaAlAs (980 nm) diode laser was applied], the tissue samples contained significantly more calcium, phosphorus, and protein than the controls. Similarly, histological analyses disclosed more pronounced angiogenesis and connective tissue formation, and more advanced bone formation in the experimental group than in the controls.

The dose of the laser is still a complicated subject. And any mistake in parameters may give an illusory picture. We have chosen our laser parameters by getting specifications from manufacturers of the entire laser used in the reported trials and we have recalculated all power densities, dose per treatment sessions and time of treatment sessions. Most of the literature on LLLT is full of conflicting reports and this due to lack of dosage unanimity [28]. In one study the authors assessed whether LLLT enhances bone regeneration and osseointegration of dental implants following sinus augmentation, this experimental study in a sheep model using cancellous bone graft. The authors didn't find a positive impact of LLLT on bone regeneration. This is opposite to our findings but in our opinion, this may be due to the authors applied LLLT for only three times during the first postoperative week with a diode laser (75mW-680 nm) and this is a lower wavelength and laser duration of application of LLLT from a current study.

In conclusion: (1) low-level laser therapy has a significant effect on bone healing after enucleation of cystic lesion regarding bone density measured by direct digital radiography; (2) the results from this study will possibly aid in the prevention of pathological bone fracture following enucleation of large cysts and tumours. However, this needs large sample size with larger defect sizes to confirm help in avoiding pathological bone fracture after large cysts or tumour removal; (3) this also will be helpful for more researchers that will help in early loading in case of dental implants as it can accelerate osseointegration.

Acknowledgements

We are grateful to Dr Sally Hieder, assistant lecturer of Oral & Maxillofacial surgery, for her unconditional support and efforts in completing this research.

References

- Von Arx T, Buser D. Horizontal ridge augmentation using autogenous block grafts and the guided bone regeneration technique with collagen membranes: a clinical study with 42 patients. *Clinical Oral Implants Research*. 2006;17(4):359-66. <https://doi.org/10.1111/j.1600-0501.2005.01234.x> PMID:16907765
- Yang X, Qin L, Liang W, Wang W, Tan J, Liang P, Xu J, Li S, Cui S. New bone formation and microstructure assessed by combination of confocal laser scanning microscopy and differential interference contrast microscopy. *Calcified Tissue International*. 2014;94(3):338-47. <https://doi.org/10.1007/s00223-013-9815-6> PMID:24253488
- Schmidt-Bleek K, Schell H, Schulz N, Hoff P, Perka C, Buttgerit F, Volk HD, Lienau J, Duda GN. Inflammatory phase of bone healing initiates the regenerative healing cascade. *Cell and Tissue Research*. 2012;347(3):567-73. <https://doi.org/10.1007/s00441-011-1205-7> PMID:21789579
- Hawkins D, Hourelid N, Abrahamse H. Low level laser therapy (LLLT) as an effective therapeutic modality for delayed wound healing. *Annals of the New York Academy of Sciences*. 2005;1056(1):486-93. <https://doi.org/10.1196/annals.1352.040> PMID:16387711
- Blumenfeld I, Srouji S, Lanir Y, Laufer D, Livne E. Enhancement of bone defect healing in old rats by TGF-beta and IGF-1. *Exp Gerontol*. 2002;37(4):553-65. [https://doi.org/10.1016/S0531-5565\(01\)00215-7](https://doi.org/10.1016/S0531-5565(01)00215-7)
- Renno AC, McDonnell PA, Parizotto NA, Laakso EL. The effects of laser irradiation on osteoblast and osteosarcoma cell proliferation and differentiation in vitro. *Photomed Laser Surg*. 2007;25(4):275-80. <https://doi.org/10.1089/pho.2007.2055> PMID:17803384
- Kazem Shakouri S, Soleimanpour J, Salekzamani Y, Oskuie MR. Effect of low-level laser therapy on the fracture healing process. *Lasers Med Sci*. 2010;25(1):73-7. <https://doi.org/10.1007/s10103-009-0670-7> PMID:19399356
- Park JJ, Kang KL. Effect of 980-nm GaAlAs diode laser irradiation on healing of extraction sockets in streptozotocin-induced diabetic rats: a pilot study. *Lasers Med Sci*. 2012;27(1):223-30. <https://doi.org/10.1007/s10103-011-0944-8> PMID:21732114
- Bodner L. Osseous regeneration in the jaws using demineralized allogenic bone implants. *J Craniomaxillofac Surg*. 1998;26(2):116-20. [https://doi.org/10.1016/S1010-5182\(98\)80051-6](https://doi.org/10.1016/S1010-5182(98)80051-6)
- Bowers G, Feiton F, Middleton C, Glynn D, Sharp S, Mellonig J, Corio R, Emerson J, Park S, Suzuki J, Ma S. Histologic comparison of regeneration in human intrabony defects when osteogenin is combined with demineralized freeze-dried bone allograft and with purified bovine collagen. *Journal of Periodontology*. 1991;62(11):690-702. <https://doi.org/10.1902/jop.1991.62.11.690> PMID:1753322
- Hosny M, Sharawy M. Osteoinduction in young and old rats using demineralized bone powder allografts. *J Oral Maxillofac Surg*. 1985;43(12):925-31. [https://doi.org/10.1016/0278-2391\(85\)90004-7](https://doi.org/10.1016/0278-2391(85)90004-7)
- Costello BJ, Betts NJ, Barber HD, Fonseca RJ. Preprosthetic surgery for the edentulous patients. *Dent Clin North Am*. 1996;40(1):19-38. PMID:8635621
- Dahaba ME, and M. Effect of diode laser therapy on healing of persistent periradicular lesions in endodontically treated teeth. *Egypt Dent J*. 2001;47: 299–309.
- Dörtbudak O, Haas R, Mallath-Pokorny G. Biostimulation of bone marrow cells with a diode soft laser. *Clin Oral Implants Res*. 2000;11(6):540-5. <https://doi.org/10.1034/j.1600-0501.2000.011006540.x> PMID:11168247
- Ninomiya T, Hosoya A, Nakamura H, Sano K, Nishisaka T, Ozawa H. Increase of bone volume by a nanosecond pulsed laser irradiation is caused by a decreased osteoclast number and an activated osteoblasts. *Bone*. 2007;40(1):140-8. <https://doi.org/10.1016/j.bone.2006.07.026> PMID:16978938
- Neiburger EJ. Rapid healing of gingival incisions by the helium-neon diode laser. *J Mass Dent Soc*. 1999;48(1):8-13, 40. PMID:10740521
- Ueda Y, Shimizu N. Pulse irradiation of low-power laser stimulates bone nodule formation. *J Oral Sci*. 2001;43(1):55-60. <https://doi.org/10.2334/josnusd.43.55> PMID:11383637
- Khadra M, Kasem N, Haanaes HR, JE, SL. Enhancement of bone formation in rat clavalial bone defects using low level laser therapy. *Oral Surg Oral Med Oral Pathol*. 2004;97:693–700. <https://doi.org/10.1016/j.tripleo.2003.11.008>
- Chiapasco M, Rossi A, Motta JJ, Crescentini M. Spontaneous bone regeneration after enucleation of large mandibular cysts: a radiographic computed analysis of 27 consecutive cases. *Journal of oral and maxillofacial surgery*. 2000;58(9):942-8. <https://doi.org/10.1053/joms.2000.8732> PMID:10981973
- Miller M, Truhe T. Lasers in dentistry: an overview. *The Journal of the American Dental Association*. 1993;124(2):32-5. <https://doi.org/10.14219/jada.archive.1993.0034> PMID:8429182
- Kim YD, Kim SS, Hwang DS, Kim SG, Kwon YH, Shin SH, Kim UK, Kim JR, Chung IK. Effect of low-level laser treatment after installation of dental titanium implant-immunohistochemical study of RANKL, RANK, OPG: An experimental study in rats. *Lasers in Surgery and Medicine*. 2007;39(5):441-50. <https://doi.org/10.1002/lsm.20508> PMID:17523169
- Kreisner PE, Blaya DS, Gaião L, Maciel-Santos ME, Etges A, Santana-Filho M, de Oliveira MG. Histological evaluation of the effect of low-level laser on distraction osteogenesis in rabbit mandibles. *Med Oral Patol Oral Cir Bucal*. 2010;15(4):e616-8. <https://doi.org/10.4317/medoral.15.e616> PMID:20038884
- Pyo SJ, Song WW, Kim IR, Park BS, Kim CH, Shin SH, Chung IK, Kim YD. Low-level laser therapy induces the expressions of BMP-2, osteocalcin, and TGF-β1 in hypoxic-cultured human osteoblasts. *Lasers Med Sci*. 2013;28(2):543-50. <https://doi.org/10.1007/s10103-012-1109-0> PMID:22552925
- Shakouri SK, Soleimanpour J, Salekzamani Y, Oskuie MR. Effect of low-level laser therapy on the fracture healing process. *Lasers in medical science*. 2010;25(1):73-7. <https://doi.org/10.1007/s10103-009-0670-7> PMID:19399356
- Roodenburg JL, Witjes MJ, de Veld DC, Tan IB, Nauta JM. [Lasers in dentistry 8. Use of lasers in oral and maxillofacial surgery]. *Ned Tijdschr Tandheelkd*. 2002;109(12):470-4. PMID:12572097
- El Desouky G, Mekky M, Salah El Din M, K. Z. and W. A. Radiodensitometric assesment of the effect of diode laser on bone density following loading of lased endosseous implants. *Egypt Dent Assoc*. 2007;53:1223.
- Fukuoka H, Daigo Y, Enoki N, Taniguchi K, Sato H. Influence of carbon dioxide laser irradiation on the healing process of extraction sockets. *Acta Odontol Scand*. 2011;69(1):33-40. <https://doi.org/10.3109/00016357.2010.517556> PMID:20863148
- Jakse N, Payer M, Tangl S, Berghold A, Kirmeier R, Lorenzoni M. Influence of low-level laser treatment on bone

regeneration and osseointegration of dental implants following sinus augmentation: An experimental study on sheep. *Clinical oral implants research*. 2007;18(4):517-24.

<https://doi.org/10.1111/j.1600-0501.2007.01369.x>

PMid:17451409