

Case Report

## Burned-out Prostate Cancer ? Primary Metastatic Cancer Not Detected on Repeat Biopsy

Yosuke Mitsui<sup>a</sup>, Takuya Sadahira<sup>a\*</sup>, Yuki Maruyama<sup>a</sup>, Koichiro Wada<sup>a</sup>,  
Ryuta Tanimoto<sup>a</sup>, Morito Sugimoto<sup>a</sup>, Motoo Araki<sup>a</sup>, Masami Watanabe<sup>a</sup>,  
Hiroyuki Yanai<sup>b</sup>, Toyohiko Watanabe<sup>a</sup>, and Yasutomo Nasu<sup>a</sup>

Departments of <sup>a</sup>Urology and <sup>b</sup>Pathology, Okayama University Graduate School of Medicine,  
Dentistry and Pharmaceutical Sciences, Okayama University Hospital, Okayama 700-8558, Japan

Metastatic prostate cancer (PCa) cases that cannot be detected on repeat prostate biopsy are extremely rare. Our patient was a 51-year-old Japanese man diagnosed as metastatic PCa by histopathological examination of lesions obtained bone biopsy and lymph node dissection. The primary tumor was not detected after repeated prostate biopsy. Metastatic PCa was diagnosed based on immunohistochemical staining: PSA, AR, P504S, and NKX3.1 of bone and lymph node with metastasis. We speculate that the primary PCa was “burned-out,” demonstrating remote metastases with no apparent primary tumor in the prostate. Burned-out PCa may be difficult to diagnose and treat due to its rarity.

**Key words:** prostate cancer, metastasis, unknown primary tumor, repeat biopsy, CRPC

Prostate cancer (PCa) is diagnosed based on the measurement of the patient’s serum prostate-specific antigen (PSA) level and the results of a digital rectal examination (DRE), magnetic resonance imaging (MRI), and prostate biopsy (PB). In cases of metastatic PCa, almost all patients are diagnosed based on the prostate biopsy results. Cases of metastatic PCa that cannot be detected by prostate biopsy are extremely rare.

The term “burned-out prostate cancer” refers to a regressed PCa that is detected only because of the presence of metastases; that is, the metastases persist but the primary tumor is undetectable. There are very few reports of burned-out tumors in other cancers, and to the best of our knowledge there are no reports of burned-out prostate cancer in the literature [1]. Here, we report a rare case of metastatic cancer likely origi-

nating from burned-out prostate cancer.

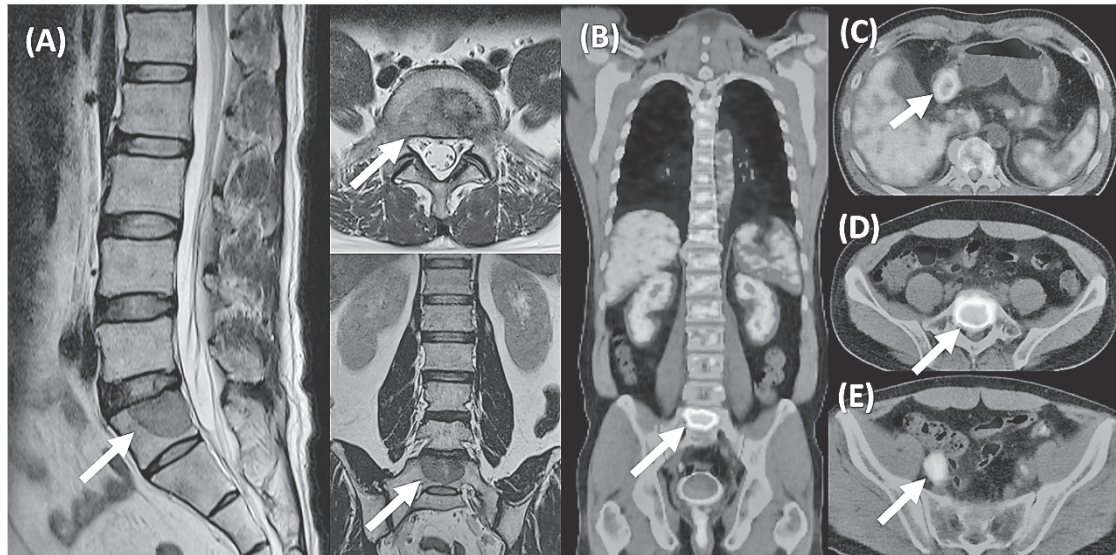
### Case Report

A 51-year-old Japanese man visited a local orthopedic hospital with lumbar back pain. The physical findings and lumbar X-ray were normal. The pain recurred 2 months later, and MRI revealed a metastatic tumor in the spine (Fig. 1A). He was referred to our hospital, where a needle biopsy was performed by an orthopedist. The histopathological findings indicated metastatic adenocarcinoma, and immunohistochemical staining was positive for PSA (Fig. 2A, B). As the primary origin of the bone metastasis was assumed to be the prostate, he was referred to our institution. His serum PSA level was 13.64 ng/ml, and the DRE revealed a soft prostate without hard nodules. MRI showed enlarged obturator lymph nodes and a normal prostate without cancerous

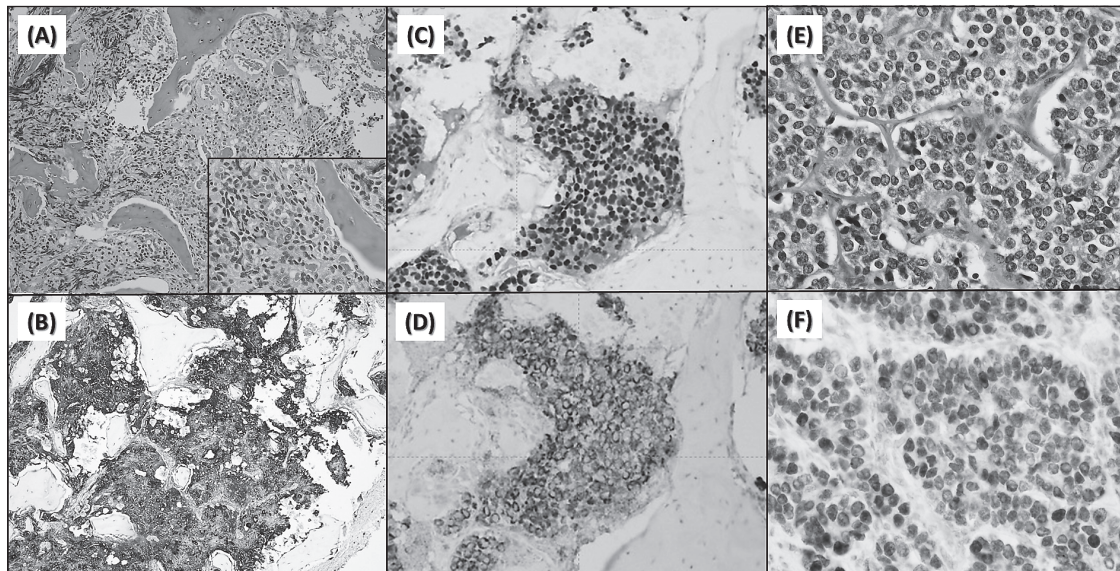
Received January 19, 2018; accepted September 20, 2018.

\*Corresponding author. Phone: +81-86-231-7287; Fax: +81-86-231-3986  
E-mail: t.sadahira@gmail.com (T. Sadahira)

Conflict of Interest Disclosures: No potential conflict of interest relevant to this article was reported.



**Fig. 1** A: MRI images showing bone metastases (*arrows*). PET revealed elevated SUVs in the spine (B, D), antrum of the stomach (C), and right obturator lymph node (E).



**Fig. 2** Immunohistochemical staining of the bone and lymph node metastases. H&E staining in bone metastases. A, Inset is high magnification; B, PSA staining in bone metastases; C, AR staining in bone metastases; D, P504S staining in bone metastases; E, H&E staining of lymph node; F, NKX3.1 staining of lymph node.

lesions.

We next performed a 10-core transrectal prostate biopsy. The biopsy findings did not identify malignant prostate lesions, suggesting that the origin of the primary tumor was not the prostate. A positron emission tomography (PET) study revealed elevated standard

uptake values (SUVs) in the spine, both obturator lymph nodes, and the antrum of the stomach (Fig. 1B-E). He underwent an esophagogastroduodenoscopy, but no malignant findings were detected on stomach biopsy samples. The patient subsequently underwent multiple prostate biopsies, including a six-core transrectal pros-

tate biopsy and a 31-core transperineal-template prostate biopsy, but no malignant tissue was detected by hematoxylin and eosin (HE) stain.

Additional immunohistochemical staining of metastatic tissue revealed positive androgen receptor (AR) and P504S staining (Fig. 2C, D). The pathological diagnosis was thus determined to be prostate cancer. We performed a laparoscopic lymph node dissection to rule out lymphoma and confirm the diagnosis. The histological findings of the right obturator lymph node dissection confirmed moderately differentiated adenocarcinoma (Fig. 2E). Immunohistochemical staining was positive for PSA and NKX3.1, a marker of prostate cancer (Fig. 2F). We diagnosed metastatic PCa, and we administered combined androgen blockade (CAB) therapy including a luteinizing hormone-releasing hormone (LH-RH) antagonist and an anti-androgen agent.

The patient's PSA level was markedly decreased with this therapy; at 1, 2, and 3 months after the completion of the CAB his serum PSA levels were 1.07 ng/ml, 0.485 ng/ml, and 0.327 ng/ml, respectively. At 4 months after the completion of the CAB, the patient reported having a back ache (which was likely due to metastasis), and the metastatic lesion was shown by MRI to have extended slightly. Radiation therapy at L5 was performed to counteract the patient's pain.

## Discussion

Bone metastases are commonly encountered in clinical settings, with 7.8-21.7% originating from an unknown primary tumor [2]. In such cases, the lungs and prostate are the most common sites of origin. In a retrospective study, 286 cases of bone metastases with unknown primary tumors was observed in a group of 2,641 patients with bone metastases [3]. Bone biopsies were performed in 141 of the 286 patients, and 138 biopsies (48%) had positive findings. The origin was suspected to be the prostate in 23 (16.6%) of the 138 cases. All 23 cases had a positive prostate biopsy. In our patient's case, however, despite repeat prostate biopsies including saturation biopsies, the primary tumor site could not be identified.

Immunohistochemical staining can help determine the origin of metastatic tumors. For example, the combined expression patterns of CK7 and CK20 can suggest the primary site [4,5]. CK7 is found in a variety of cancers, including lung, breast, thyroid, pancreas,

ovary, and endometrium. CK20 is expressed in gastrointestinal cancers and urothelial cancer. Of note, both CK7 and CK20 are negative in prostate cancer [5]. Although the immunohistochemical staining of CK7/CK20 is helpful in PCa, it is not enough for a definitive diagnosis. To confirm the diagnosis of PCa, immunohistochemistry markers such as PSA or prostatic-specific acid phosphatase (PSAP) are used. In poorly differentiated prostate cancer, PSA and PSAP may be focally or weakly expressed [6]. PSA and AR are not specific for PCa. It was reported that PSA and AR were present in breast cancer and parotid cancer [7,8]. We had to rule out these cancers in our patient.

P504S (also known as  $\alpha$ -methylacyl-CoA racemase: AMACR) and NKX3.1 were recently reported to be effective for diagnosing PCa with a needle biopsy [9,10]. To identify an unknown primary site, it is important to combine immunohistochemical staining for several markers. In the present case, PSA and P504S were positive in the bone metastases, and NKX3.1 was positive in the lymph node metastases. Despite the absence of malignancy on repeat prostate biopsy, we were able to confirm the diagnosis of metastatic PCa by combining specific immunohistochemistry markers from multiple sites.

An extended biopsy with 10-24 cores is the current gold standard for the initial prostate biopsy. The cancer detection rate of 10-24 transrectal prostate biopsy (TRPB) cores is 20-40% [11]. The detection rate of transperineal prostate biopsy (TPPB) is superior to that of TRPB in the anterior peripheral zone or apex in cases with a large prostate volume, but some studies observed no significant difference in cancer detection rates between TRPB and TPPB on initial biopsy [12]. In repeat biopsy settings, 35-68% of patients whose initial TRPB was negative could be diagnosed with the use of a 40-70 core transperineal template biopsy [13]. In repeat saturation biopsies, TRPB and TPPB have a similar PCa detection rate [14]. Combining TRPB with TPPB or a template-guided saturation biopsy may improve cancer detection [15].

The term "burned-out tumor" was first reported by Prim in 1927 regarding testicular cancer, and only 80 burned-out tumor cases have been reported in the literature [16]. Burned-out tumors make up approx. 1.0% of testicular germ cell tumors [17]. Primary tumor atrophy was observed in these cases, but the size of the testis was unchanged. It may thus be difficult to detect



burned-out tumors in clinical settings. The mechanism of the burned-out phenomenon is not known, but several theories have been proposed. For example, it was suggested that the burned-out phenomenon represents a spontaneous regression of the primary tumor that occurs after metastasis in patients with germ cell tumors. Regression may be due to an immune response at the site of tumor origin or by ischemia caused by the high metabolic rate of a neoplasm that has outgrown its blood supply [18].

In our patient's case, several uncertainties remain. First, it remains unclear whether the origin of the metastasis was the prostate. The patient's increased serum PSA level and the immunohistochemical staining of bone and lymph nodes were consistent with PCa. In addition, the PSA level was markedly decreased after CAB therapy. Therefore, the origin of the primary tumor was most likely the prostate.

Second, it remains unclear why the prostate biopsy samples in our patient's case did not reveal malignancy. In a previous case, invasive PCa was detected as an occult cancer, because the PCa lesion was small [19]. For the detection of small PCa lesions, it is essential to use a saturation biopsy technique such as TRPB or TPPB. In the present case, we performed a saturation biopsy using a combination of TRPB and TPPB with a template. Although a third or fourth biopsy could have been performed, the probability of detecting a malignancy would be low.

The cancer detection rates reported for second through sixth biopsies were 17%, 14%, 11%, 9% and 7%, respectively [20]. In that report, almost all of the prostate cancers were described as detected by the time of the second biopsy, and when cancer was detected on the third biopsy or later, the Gleason score was low and the pathological history was low-grade. In our patient's case, no malignancy was identified on 37 cores of saturation biopsy, indicating the absence of a small invasive tumor. For this reason, we suspect that the primary prostate tumor was burned-out. To the best of our knowledge, only nine cases of metastatic PCa whose primary lesion could not be detected by repeat biopsy have been reported. In one of these cases, docetaxel-based chemotherapy was begun but the patient soon showed resistance to the chemotherapy and died 21 months after the initial prostate biopsy [21].

In our patient's case, the PSA level was low despite the presence of both bone and lymph node metastases.

In addition, at 51 years old the patient was much younger than typical PCa patients. Atypical cases such as the present case should be followed closely with both PSA monitoring and imaging, because these cases can develop into castration-resistant prostatic carcinoma (CRPC). A recent report showed that a combination of docetaxel and androgen-deprivation therapy (ADT) for metastatic PCa resulted in significantly longer overall survival than ADT alone [22]. In light of that finding, we would have started docetaxel for our patient at the beginning of ADT.

In conclusion, we have reported an extremely rare case of metastatic cancer likely originating from burned-out prostate cancer. Prostate cancer should be suspected in cases of bone metastases with an unknown primary cancer, and a bone biopsy is mandatory. Based on the present experience, it may be difficult to diagnose and start of primary treatment for metastatic prostate cancer with an undetectable primary tumor, in light of its rarity.

## References

1. Perimenis P, Athanasopoulos A, Geraghty J and Macdonagh R: Retroperitoneal seminoma with 'burned out' phenomenon in the testis. *Int J Urol* (2005) 12: 115-116.
2. Destombe C, Botton E, Le Gal G, Roudaut A, Jousse-Joulin S, Devauchelle-Pensec V and Saroux A: Investigations for bone metastasis from an unknown primary. *Joint Bone Spine* (2007) 74: 85-89.
3. Takagi T, Katagiri H, Kim Y, Suehara Y, Kubota D, Akaike K, Ishii M, Mukaiharu K, Okubo T, Murata H, Takahashi M, Kaneko K and Saito T: Skeletal Metastasis of Unknown Primary Origin at the Initial Visit: A Retrospective Analysis of 286 Cases. *PLoS One* (2015) 10: e0129428.
4. Varadhachary GR, Abbruzzese JL and Lenzi R: Diagnostic strategies for unknown primary cancer. *Cancer* (2004) 100: 1776-1785.
5. Park SY, Kim HS, Hong EK and Kim WH: Expression of cytokeratins 7 and 20 in primary carcinomas of the stomach and colorectum and their value in the differential diagnosis of metastatic carcinomas to the ovary. *Hum Pathol* (2002) 33: 1078-1085.
6. Chuang AY, DeMarzo AM, Veltri RW, Sharma RB, Bieberich CJ and Epstein JI: Immunohistochemical differentiation of high-grade prostate carcinoma from urothelial carcinoma. *Am J Surg Pathol* (2007) 31: 1246-1255.
7. Yu H, Diamandis EP, Levesque M, Giai M, Ragna R, Ponzoni R, Sismondi P, Monne M and Croce CM: Prostate specific antigen in breast cancer, benign breast disease and normal breast tissue. *Breast Cancer Res Treat* (1996) 40: 171-178.
8. Ishibashi K, Ito Y, Fujii K, Masaki A, Beppu S, Kawakita D, Ijichi K, Shimozato K and Inagaki H: Androgen receptor-positive mucoepithelioid carcinoma: case report and literature review. *Int J Surg Pathol* (2015) 23: 243-247.
9. Evans AJ: Alpha-Methylacyl CoA racemase (P504S): overview and potential uses in diagnostic pathology as applied to prostate

- needle biopsies. *J Clin Pathol* (2003) 56: 892–897.
10. Gurel B, Ali TZ, Montgomery EA, Begum S, Hicks J, Goggins M, Eberhart CG, Clark DP, Bieberich CJ, Epstein JI and De Marzo AM: NKX3.1 as a Marker of Prostatic Origin in Metastatic Tumors. *Am J Surg Pathol* (2010) 34: 1097–1105.
  11. Shen PF, Zhu YC, Wei WR, Li YZ, Yang J, Li YT, Li DM, Wang J and Zeng H: The results of transperineal versus transrectal prostate biopsy: a systematic review and meta-analysis. *Asian J Androl* (2012) 14: 310–315.
  12. Hara R, Jo Y, Fujii T, Kondo N, Yokoyama T, Miyaji Y and Nagai A: Optimal approach for prostate cancer detection as initial biopsy: prospective randomized study comparing transperineal versus transrectal systematic 12-core biopsy. *Urology* (2008) 71: 191–195.
  13. Chang DT, Challacombe B and Lawrentschuk N: Transperineal biopsy of the prostate—is this the future? *Nat Rev Urol* (2013) 10: 690–702.
  14. Abdollah F, Novara G, Briganti A, Scattoni V, Raber M, Roscigno M, Suardi N, Gallina A, Artibani W, Ficarra V, Cestari A, Guazzoni G, Rigatti P and Montorsi F: Trans-rectal versus trans-perineal saturation rebiopsy of the prostate: is there a difference in cancer detection rate? *Urology* (2011) 77: 921–925.
  15. Merrick GS, Gutman S, Andreini H, Taubenslag W, Lindert DL, Curtis R, Adamovich E, Anderson R, Allen Z, Butler W and Wallner K: Prostate cancer distribution in patients diagnosed by transperineal template-guided saturation biopsy. *Eur Urol* (2007) 52: 715–723.
  16. Pym P: Spontanheilung eines bosartigen, wahrscheinlich chorionepitheliomatosen gewachses im hoden. *Virchows Arch Pathol Anat* (1927) 265: 239–258.
  17. Collins DH and Push RC: Classification and frequency of testicular tumours. *Br J Urol Suppl*: 1–11.
  18. Mosillo C, Scagnoli S, Pomati G, Caponnetto S, Mancini ML, Bezzi M, Cortesi E and Gelibter A: Burned-Out Testicular Cancer: Really a Different History? *Case Rep Oncol* (2017) 10: 846–850.
  19. Rich AR: On the frequency of occurrence of occult carcinoma of the prostate. *Int J Epidemiol* (2007) 36: 274–277.
  20. Roehl KA, Antenor JA and Catalona WJ: Serial biopsy results in prostate cancer screening study. *J Urol* (2002) 167: 2435–2439.
  21. Iwamura H, Hatakeyama S, Tanaka Y, Tanaka T, Tokui N, Yamamoto H, Imai A, Yoneyama T, Hashimoto Y, Koie T, Yoshikawa K and Ohyama C: A case of metastatic cancer with markedly elevated PSA level that was not detected by repeat prostate biopsy. *BMC Res Notes* (2014) 7: 64.
  22. Sweeney CJ, Chen YH, Carducci M, Liu G, Jarrard DF, Eisenberger M, Wong YN, Hahn N, Kohli M, Cooney MM, Dreicer R, Vogelzang NJ, Picus J, Shevrin D, Hussain M, Garcia JA and DiPaola RS: Chemohormonal Therapy in Metastatic Hormone-Sensitive Prostate Cancer. *N Engl J Med* (2015) 373: 737–746.