

Role of technetium-99m diphosphonate and gallium-67 citrate bone scanning in the early diagnosis of infectious spondylodiscitis.

A comparative study

Joan Miquel Nolla-Solé, Lourdes Mateo-Soria, Antonio Rozadilla-Sacanell, Jaume Mora-Salvador, José Valverde-García, Daniel Roig-Escofet

Abstract

A comparative study of the parts played by technetium-99m diphosphonate and gallium-67 citrate bone scanning in the early diagnosis of infectious spondylodiscitis is presented. Nineteen patients were included in the study. All patients (11 men aged 19–70 years and eight women aged 18–72 years) had a history of back pain varying in duration from one to 15 weeks. A ^{99m}Tc diphosphonate bone scan was positive in 17 patients. The two patients with negative results had less than two weeks of back pain. The ^{67}Ga citrate bone scan showed uptake in all patients.

^{99m}Tc diphosphonate bone scanning is considered to be the most reliable method to establish the early diagnosis of infectious spondylodiscitis.¹ A normal scan in adults has been used to exclude this diagnosis.

False normal ^{99m}Tc diphosphonate bone scans have been described in children with definite osteomyelitis.² The reason for these normal scans is not clear, but regional ischaemia probably due to thrombosis formation in blood vessels has been suggested.³

Schlaeffer *et al*⁴ have reported two cases of vertebral osteomyelitis in adult patients in whom ^{99m}Tc diphosphonate bone scans were normal when first performed and became abnormal later in the course of the disease.

^{67}Ga citrate scanning seems to be useful in the diagnosis of osteomyelitis.⁵ At least three mechanisms by which ^{67}Ga might be taken up in infectious regions have been postulated. These include leucocyte labelling,⁶ lactoferrin binding at the site of infection,⁷ and direct bacterial uptake.⁸ Uptake of gallium by bone is less affected by regional blood flow⁹ and theoretically ^{67}Ga citrate scanning could be a good alternative when infectious spondylodiscitis is suggested by strong clinical evidence and the ^{99m}Tc diphosphonate bone scan is normal.

No large comparative studies on the sensitivity of ^{99m}Tc diphosphonate and ^{67}Ga citrate bone scans have been reported. We have evaluated prospectively the value of these scintigraphic techniques in 19 adult patients with microbiologically proved infectious spondylodiscitis.

Patients and methods

Nineteen consecutive patients with infectious spondylodiscitis determined microbiologically were included in this study.

The same study strategy was followed for all patients. Six days after admission for suspected infectious spondylodiscitis, the following investigations were carried out.

At least four blood cultures were taken. Two or more positive haemocultures were required to accept the diagnosis of infectious spondylodiscitis. Posterior and lateral views of the thoracic and lumbar spine were obtained radiologically. Posterior spine images were obtained two hours after the intravenous administration of 740 MBq ^{99m}Tc diphosphonate. Posterior spine images were obtained 48 hours after the intravenous administration of 100–150 MBq ^{67}Ga citrate. The tracer was administered just after the ^{99m}Tc diphosphonate investigation had finished. A disc biopsy sample was taken when blood cultures were negative and previous investigations supported the diagnosis of infectious spondylodiscitis.

The radiological criteria used for infectious spondylodiscitis were disc space narrowing or irregular erosion of the vertebral endplates adjacent to the disc spaces, or both. The scintigraphic criterion for infectious spondylodiscitis was increased uptake in the vertebral bodies on either side of the affected disc space.

The sensitivity and 95% confidence intervals were calculated for the radiographic and scintigraphic techniques.

Results

The table gives the clinical data and results of investigations.

The age of the patients varied between 18 and 72 years. The duration of symptoms before diagnosis varied between one and 12 weeks. All patients had inflammatory back pain and 13 had fever. The erythrocyte sedimentation rate was increased in 18 patients.

Infectious spondylodiscitis was confirmed microbiologically in all cases. Blood cultures were positive in nine patients and a disc biopsy sample was taken in 10 patients. *Staphylococcus aureus* was the causative agent in seven patients. *Mycobacterium tuberculosis* in five patients, *Proteus mirabilis* and *Escherichia coli* in two patients, and *Proteus vulgaris*, *Pseudomonas aeruginosa* and *Streptococcus agalactiae* in one patient each.

In six patients the conventional radiographs were normal. In all patients with abnormal radiographs the scintigraphic study showed bone uptake.

Rheumatology Service,
Hospital de Bellvitge
'Prnceps d'Espanya',
University of Barcelona,
L'Hospitalet de
Llobregat, Barcelona,
Spain

J Miquel Nolla-Solé
L Mateo-Soria
A Rozadilla-Sacanell
J Valverde-García
D Roig-Escofet

Nuclear Medicine
Service,
Hospital de Bellvitge
'Prnceps d'Espanya',
University of Barcelona,
L'Hospitalet de
Llobregat, Barcelona,
Spain

J Mora-Salvador

Correspondence to:
Dr J M Nolla-Solé,
Rheumatology Service,
Hospital de Bellvitge
'Prnceps d'Espanya',
Feixa Llarga,
s/n 08907 L'Hospitalet
de Llobregat,
Barcelona, Spain.

Accepted for publication
8 October 1991

Patient profiles. All patients had back pain

Patient No	Age (years)/sex	Duration of symptoms (weeks)	Disc level	Fever	ESR* (mm/h)	Microbiological results†	Predisposing factor	Radiography	^{99m} Tc diphosphonate bone scan	⁶⁷ Ga citrate bone scan
1	70/M	7	L5-S1	+	96	<i>Proteus mirabilis</i> (B)	Diabetes mellitus	+	+	+
2	50/F	4	L2-L3	+	62	<i>Escherichia coli</i> (B)		+	+	+
3	36/M	1.5	T12-L1	+	110	<i>Staphylococcus aureus</i> (D)		-	-	+
4	22/M	3	L3-L4	+	69	<i>Staphylococcus aureus</i> (B)		+	+	+
5	18/F	8	L4-L5	-	90	<i>Staphylococcus aureus</i> (D)		+	+	+
6	71/F	10	L1-L2	-	80	<i>Proteus vulgaris</i> (D)		+	+	+
7	67/M	12	T10-T11	+	44	<i>Staphylococcus aureus</i> (B)		-	+	+
8	24/M	1	L3-L4	+	74	<i>Staphylococcus aureus</i> (B)		-	-	+
9	19/M	2	L2-L3	+	63	<i>Staphylococcus aureus</i> (B)		-	+	+
10	58/M	2	L2-L3	+	55	<i>Pseudomonas aeruginosa</i> (B)	Hepatic cirrhosis	+	+	+
11	72/F	2.5	L5-S1	+	120	<i>Escherichia coli</i> (B)	Urinary infection	+	+	+
12	58/F	8	T11-T12	+	94	<i>Proteus mirabilis</i> (D)		+	+	+
13	34/F	1.5	L5-S1	+	94	<i>Streptococcus agalactiae</i> (D)	SLE treated with glucocorticoids	-	+	+
14	21/M	1	L5-S1	+	52	<i>Staphylococcus aureus</i> (B)		-	+	+
15	23/M	3.5	T11-T12	-	41	<i>Mycobacterium tuberculosis</i> (D)		+	+	+
16	28/M	15	L2-L3	-	32	<i>Mycobacterium tuberculosis</i> (D)	Alcoholism	+	+	+
17	65/F	12	T10-T11	-	45	<i>Mycobacterium tuberculosis</i> (D)	Chronic renal failure	+	+	+
18	24/M	8	L5-S1	+	23	<i>Mycobacterium tuberculosis</i> (D)		+	+	+
19	72/F	6.5	T11-T12	-	36	<i>Mycobacterium tuberculosis</i> (D)	RA treated with glucocorticoids	+	+	+

*ESR=erythrocyte sedimentation rate.

†B=blood culture; D=disc biopsy sample.

^{99m}Tc diphosphonate bone scanning showed bone uptake in 17 patients. The two patients with normal bone scans (patients 3 and 8) had a duration of symptoms shorter than two weeks. In both patients a new ^{99m}Tc diphosphonate bone scan repeated six weeks later showed bone uptake. The ⁶⁷Ga citrate bone scan showed uptake in all patients. Figures 1 and 2 show the results of the two bone scans in patient 8.

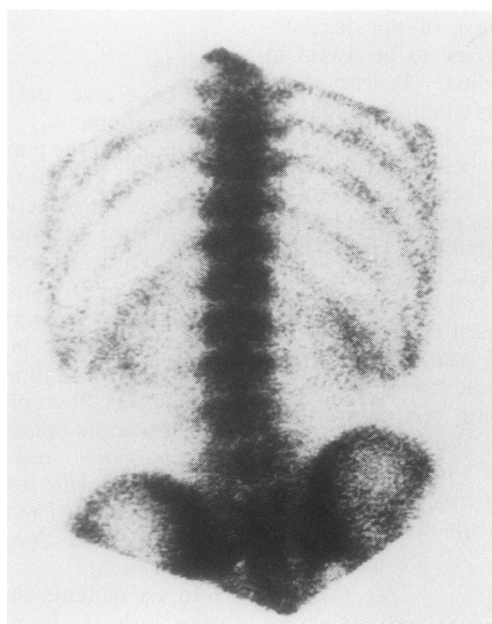


Figure 1 ^{99m}Tc diphosphonate bone scan in patient 8 showing negative uptake.

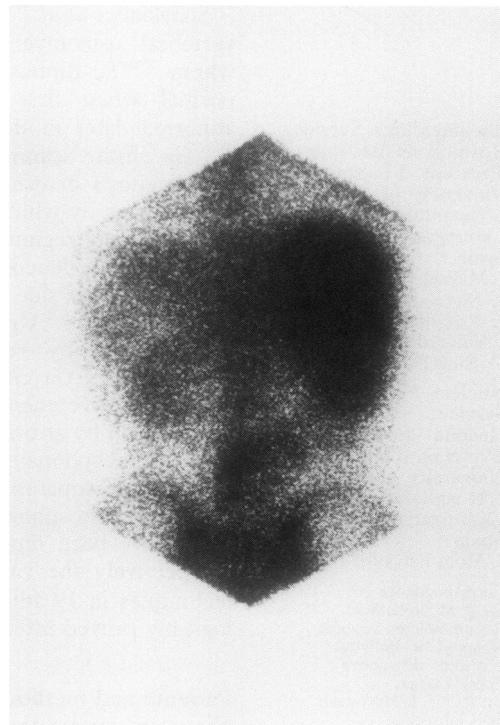


Figure 2 ⁶⁷Ga citrate bone scan in patient 8 showing positive uptake (L3-L4 infectious spondylodiscitis).

Discussion

Infectious spondylodiscitis is no longer a rare disease. There has been an increasing incidence of this disease in the last few decades.¹⁰ Intravenous drug abuse, urinary tract infections, or urinary tract instrumentations and longer life expectations in patients with chronic and debilitating diseases treated with corticosteroids are some of the factors that have contributed to this increase.¹¹ Fever and inflammatory back pain are the cardinal clinical features of infectious spondylodiscitis.¹¹ Often the signs and symptoms of infection are vague and insidious and therefore the diagnosis may be delayed.

Conventional radiographic studies are not available for the diagnosis of infectious spondylodiscitis.¹¹ Radiographic changes do not usually appear until two weeks after infection. ^{99m}Tc diphosphonate bone scanning is a valuable diagnostic procedure for infectious spondylodiscitis.¹² Early bone uptake, a low radiation burden, high sensitivity, and good imaging resolution are the advantages of this method.⁵

This study supports the value of ^{99m}Tc diphosphonate bone scans in the early diagnosis of infectious spondylodiscitis. Only two patients with infectious spondylodiscitis showed negative bone uptake; this finding was probably due to the absence of bone reaction related to the short duration of their disease. In both patients bone uptake became evident when the ^{99m}Tc diphosphonate bone scan was repeated six weeks after the start of their symptoms.

Our study, however, supports the view that ⁶⁷Ga citrate scanning is useful in the early diagnosis of infectious spondylodiscitis. The sensitivity of this scintigraphic technique was greater than the ^{99m}Tc diphosphonate bone scan. All patients with infectious spondylodiscitis showed bone uptake of ⁶⁷Ga.

⁶⁷Ga citrate scanning seems to be useful for the diagnosis of infectious spondylodiscitis even when ^{99m}Tc diphosphonate bone scans are normal. Sullivan *et al* have previously reported this finding in children.²

Dangerous complications that may result from the delay in the diagnosis of infectious spondylodiscitis underline the value of techniques such as ^{99m}Tc diphosphonate and ⁶⁷Ga citrate bone scanning in early diagnosis. ^{99m}Tc diphosphonate bone scanning is probably the scintigraphic technique of choice because the ⁶⁷Ga citrate bone scan gives a larger irradiation dose to the patient, a delay of 24 to 48 hours before the results are available, and has poorer imaging resolution. As our study shows, however, in equivocal cases when infectious spondylodiscitis is suspected and the ^{99m}Tc diphosphonate bone scan is normal, ⁶⁷Ga citrate scanning is a useful alternative diagnostic method. The specificity of this scintigraphic technique should be established in future prospective studies.

- 1 Nelson H T, Taylor A. Bone scanning in the diagnosis of acute osteomyelitis. *Eur J Nucl Med* 1980; 5: 267-9.
- 2 Sullivan D C, Rosenfield N S, Odgen J A, *et al*. Problems in the scintigraphic detection of osteomyelitis in children. *Radiology* 1980; 135: 731-6.
- 3 Odgen J A. Pediatric osteomyelitis and septic arthritis: the pathology of neonatal disease. *Yale J Biol Med* 1979; 52: 423-48.
- 4 Schlaefter F, Mikovich D J, Mates S. Technetium Tc^{99m} diphosphonate bone scan. False-normal findings in elderly patients with hematogenous infectious spondylodiscitis. *Arch Intern Med* 1987; 147: 2024-6.
- 5 Gupta N C, Prezio J A. Radionuclide imaging in osteomyelitis. *Sem Nucl Med* 1988; 4: 287-99.
- 6 Gelrud L G, Arsenan J C, Milder M S, *et al*. The kinetics of ⁶⁷gallium incorporation into inflammatory lesions: experimental and clinical studies. *J Lab Clin Med* 1974; 83: 489-95.
- 7 Wright D G, Pizo P A, Jones A E, *et al*. Studies of ⁶⁷ Ga uptake at sites of neutrophil exudation [abstract]. *Clin Res* 1979; 27: 360A.
- 8 Menon S, Wagner H N, Tsan M F. Studies of gallium accumulation in inflammatory lesions: II. Uptake by *Staphylococcus aureus*. Concise communication. *J Nucl Med* 1979; 19: 44-7.
- 9 Hoffer P. Gallium mechanisms. *J Nucl Med* 1980; 29: 282-5.
- 10 Waldvogel F A, Vasey H. Osteomyelitis: the past decade. *N Engl J Med* 1980; 303: 360-8.
- 11 Sapico F L, Montgomerie J Z. Pyogenic vertebral osteomyelitis. report of nine cases and review of the literature. *Rev Infect Dis* 1979; 1754-66.
- 12 Choong K, Monaghan P, McGuigan L, McLean R. Role of bone scintigraphy in the early diagnosis of discitis. *Ann Rheum Dis* 1990; 49: 932-4.



Role of technetium-99m diphosphonate and gallium-67 citrate bone scanning in the early diagnosis of infectious spondylodiscitis. A comparative study.

J M Nolla-Solé, L Mateo-Soria, A Rozadilla-Sacanell, et al.

Ann Rheum Dis 1992 51: 665-667

doi: 10.1136/ard.51.5.665

Updated information and services can be found at:

<http://ard.bmj.com/content/51/5/665>

Email alerting service

These include:

Receive free email alerts when new articles cite this article. Sign up in the box at the top right corner of the online article.

Notes

To request permissions go to:

<http://group.bmj.com/group/rights-licensing/permissions>

To order reprints go to:

<http://journals.bmj.com/cgi/reprintform>

To subscribe to BMJ go to:

<http://group.bmj.com/subscribe/>