

2013_FraX- tremor_ataxia_Winarni_et_al.pdf

by Anastasia Ediati

Submission date: 03-Aug-2018 08:54AM (UTC+0700)

Submission ID: 987176501

File name: 2013_FraX-tremor_ataxia_Winarni_et_al.pdf (623.05K)

Word count: 3644

Character count: 19565

Short Report

22

The fragile X-associated tremor ataxia syndrome (FXTAS) in Indonesia

Winarni TI, Mundhofir FEP, Ediati A, Belladona M, Nillesen WM, Yntema HG, Hamel BCJ, Faradz SMH, Hagerman RJ. The fragile X-associated tremor ataxia syndrome (FXTAS) in Indonesia. *Clin Genet* 2012. © John Wiley & Sons A/S, 2012

Fragile X-associated disorder caused by the premutation of the *FMR1* gene, includes the fragile X-associated tremor/ataxia syndrome (FXTAS). FXTAS affects more than 40% of premutation males over the age of 50 and 75% over the age of 80. *FMR1* molecular analysis was done using PCR and confirmed by Southern Blot. Three premutation males were diagnosed FXTAS using quantification based on the standard neurological examination. Cognitive impairment was assessed using Raven and WAIS-R test. MRI was done to identify the middle cerebellar peduncle (MCP) sign, white matter disease and/or cerebral atrophy. Three cases of FXTAS are identified, of five individuals older than 50 years in one family tree two met criteria for definite FXTAS and the third with sub-clinical symptoms, although cognitive and radiological criteria are met. These cases are the first identified FXTAS cases in rural Indonesia. In addition with lack of routine medical follow-up, complications of FXTAS, such as hypertension may go unrecognized and untreated, which may further exacerbate the central nervous system (CNS) findings of FXTAS.

Conflict of interest

R. H. has received funding from Novartis, Roche, Seaside Therapeutics, Curemark and Forest Pharmaceuticals for treatment studies in fragile X syndrome or autism. She is also on the Fragile X Advisory Counsel of Novartis as a consultant. There is no conflict of interest to be declared from the other authors.

Premutation *FMR1* carriers are at risk of the fragile X-associated tremor ataxia syndrome (FXTAS) (1), a progressive late-adult-onset neurodegenerative disorder, that occurs in approximately 40% of males (2) and 16.5% of females older than 50 years (3). Premutation alleles of the *FMR1* gene are frequent in general population with a prevalence of 1:178 in females and 1:400 in males (4).

A two- to eightfold elevation of the *FMR1* mRNA is found in premutation carriers (5), leading to a toxic gain

of function mechanism that causes FXTAS (6). The *FMR1* mRNA toxicity in the brain will lead to neuronal cell dysregulation and eventually intranuclear inclusion formation in neurons and astrocytes throughout the brain (7). The penetrance of FXTAS was found much greater in mid-large sized premutations (70–200 CGG repeats) compared to full premutation size (55–69 CGG repeats) (2, 8, 9). The higher the number of CGG repeats, the greater the number of inclusions and the earlier the onset of death, (10) though molecular studies

TI Winarni^a, FEP Mundhofir^{a,d}, A Ediati^c, M Belladona^b, WM Nillesen^d, HG Yntema^d, BCJ Hamel^d, SMH Faradz^a, and RJ Hagerman^e

^aDivision of Human Genetic Center for Biomedical Research, Faculty of Medicine, Diponegoro University, Semarang, Indonesia, ^bDepartment of Neurology, Faculty of Medicine, Diponegoro University, Semarang, Indonesia, ^cFaculty of Psychology, Diponegoro University, Semarang, Indonesia, ^dDepartment of Human Genetics, Radboud University Nijmegen Medical Centre, Nijmegen, Netherlands, and ^eMedical Investigation of Neurodevelopmental Disorder (MIND) Institute, University of California Davis, Medical Center, Sacramento, CA, USA

Key words: *FMR1* – FXTAS – Indonesia – quantitative neurological assessment

Corresponding author: Sultana MH Faradz, Division of Human Genetic Center for Biomedical Research, Faculty of Medicine, Diponegoro University, Jl. Dr. Soetomo no: 14, Semarang, Central Java 50231, Indonesia.
Tel.: +62 24 7460017;
fax: +62 24 8454714;
e-mail: sultana@indosat.net.id

Received 27 February 2012, revised and accepted for publication 4 May 2012

in knock-in mice showed very few and small inclusion formation with CGG repeat length exceeding 150 (11).

On the basis of frequency of mid-sized (≥ 70 CGG repeats) premutation alleles, FXTAS is estimated to occur in 1:4848 in the general population (12). The 24th most common clinical characteristics of FXTAS are intention tremor, gait ataxia, and parkinsonism in addition to neuropathy, cognitive decline and psychological symptoms of mood, and/or anxiety disorders (13, 14). Magnetic resonance imaging (MRI) studies demonstrate global brain atrophy and white matter T2 hyperintensities in the middle cerebellar peduncles (MCP), the pons, periventricular areas and subcortical areas (15). A major criterion of FXTAS is white matter disease in the MCP sign but this is found only in 58% and 13% of affected males and females, respectively (15). Premutation carriers who have intention tremor and ataxia without any imaging anomalies will be diagnosed as probable FXTAS. Those who have core symptoms of intention tremor and/or ataxia with the major radiological finding of the MCP sign will be diagnosed as definite FXTAS (14).

So far, no Indonesian FXTAS case has been published. This study was performed to identify potential FXTAS patients in known FXS family pedigrees. Treatment for symptoms of FXTAS is available in Indonesia, so the identification of FXTAS is essential (16, 17).

Methods

Samples were obtained from a large family with cases of FXS and positive samples were confirmed by Southern blot. All family members signed an informed consent. The following neurological assessment was carried out in premutation over 50 years of age.

The mini mental state examinations (MMSE) was used to screen memory and cognitive function followed by Raven test for cultural and education free cognitive assessment, then the WAIS-R was done for verbal and nonverbal IQ, full scale IQ and short-term memory. Average category according to Raven is percentile range 26th–74th/Grade III (18) and for the Wechsler is IQ range ≥ 90 (19). MRI was carried out to assess cerebral atrophy and white matter disease. A physical and neurological examination was completed by

a neurologist and the examination was videotaped for further assessment by blinded examiners. This examination included the following:

1 Quantification of the tremor

The most common method of measuring tremor is finger-to-nose testing (20), and combined with functional performance tests included picking up a coin and pouring water. Fahn tremor rating (FTR) scale was used to quantify tremor (21).

2 Quantification of the ataxia

Ataxia quantification was adapted from Notermans et al. (22) and combined with the gait and balance scale (GABS) (23). Ataxia testing included (i) tapping test for upper and lower extremities; (ii) quantitative finger-to-nose testing; (iii) quantitative Romberg test; (iv) tandem walk; and (v) postural stability response to sudden posterior displacement by pull on shoulders while patient is erect and alert. Tapping test was done with both dominant and non-dominant upper and lower extremities, scaled quantitatively by using mean result (22) and Modified International Cooperative Ataxia Rating Scale (MICARS) (24).

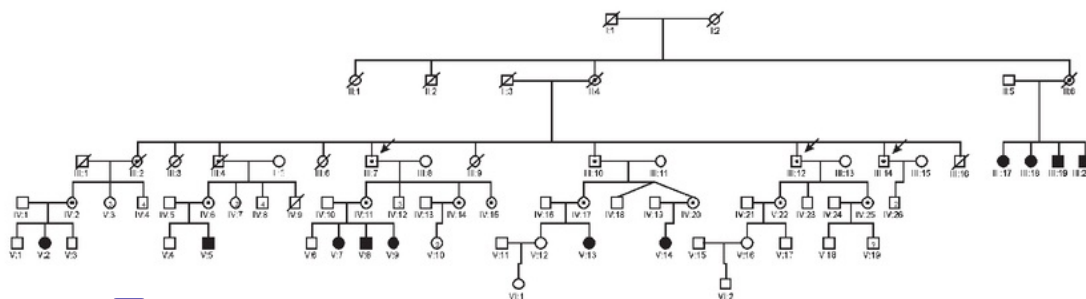
Results

All premutation individuals of one large fragile X family (Fig. 1) older than 50 years were assessed ($N = 5$; four male and one female). Three cases of FXTAS were identified, two met criteria for definite FXTAS and the third had sub-clinical symptoms although cognitive and radiological criteria were met.

The main neurological features of FXTAS and other common medical conditions were observed among all cases (Table 1). MRI imaging was abnormal in all three cases (Fig. 2) The cognitive function test results are presented in Table 2.

20 Case reports

Case 1 is a 74-year-old male with a premutation of 88 CGG repeats. For the last 3 years he worked less



23
Fig. 1. Pedigree of the fragile X-associated tremor ataxia (FXTAS) family. Arrows indicate the affected individuals. Pedigree number III.7 is case 1 and III.12 is case 2 who were diagnosed definite FXTAS. Pedigree number III.14 is case 3 who was diagnosed sub-clinical FXTAS although cognitive deficits and radiological signs were not subclinical.

Table 1. Clinical symptoms and other medical conditions among premutation male cases

Case 1: a 74-year-old male premutation carrier (88 CGG repeats)	Case 2: a 70-year-old male premutation carrier (104 CGG repeats)	Case 3: a 68-year-old male premutation carrier (110 CGG repeats)
Neurological symptoms		
Quantitative tremor: 1. Finger to nose: slight/intermittent tremor (1) 2. Pick up coin (1) 3. Pouring water (spills < 10%/2)	Quantitative tremor: 35 1. Finger to nose: no tremor (0) 2. Pick up coin (0) 3. Pouring water (spills < 10%/2)	Quantitative tremor: 1. Finger to nose: no tremor (0) 2. Pick up coin (0) 3. Pouring water (0)
Quantitative ataxia: 1. 11 ber and lower limb tapping (2) 2. Finger to nose (open and closed eyes): 0 cm 3. Heel to toe Romberg test with eyes closed (failed/4) 4. Tandem walk: unable/2 5. Postural stability test (absence/3)	Quantitative ataxia: 1. Upper and lower limb tapping (1) 2. Finger to nose (open and closed eyes): 0 cm 3. Heel to toe Romberg test with eyes closed (5–10 second/2) 4. Tandem walk: impaired/1 5. Postural stability test (retropulsion recovers unaided/2)	Quantitative ataxia: 1. 11 ber and lower limb tapping (1) 2. Finger to nose (open and closed eyes): 0 cm 3. Heel to toe Romberg test with eyes closed (5–10 second/ 40) 4. Tandem walk: normal/0 5. Postural stability test: normal
Dysdiadochokinesis: positive using cane for 2 years	Dysdiadochokinesis: positive	Dysdiadochokinesis: none
Other medical conditions		
1. 31 hypertension (190/130 mmHg) 2. Hearing impairment 3. Peripheral neuropathy	1. Hypertension (150/100 mmHg) 2. Hearing impairment 3. Peripheral neuropathy	1. Hypertension (160/100 mmHg) 2. Hearing impairment

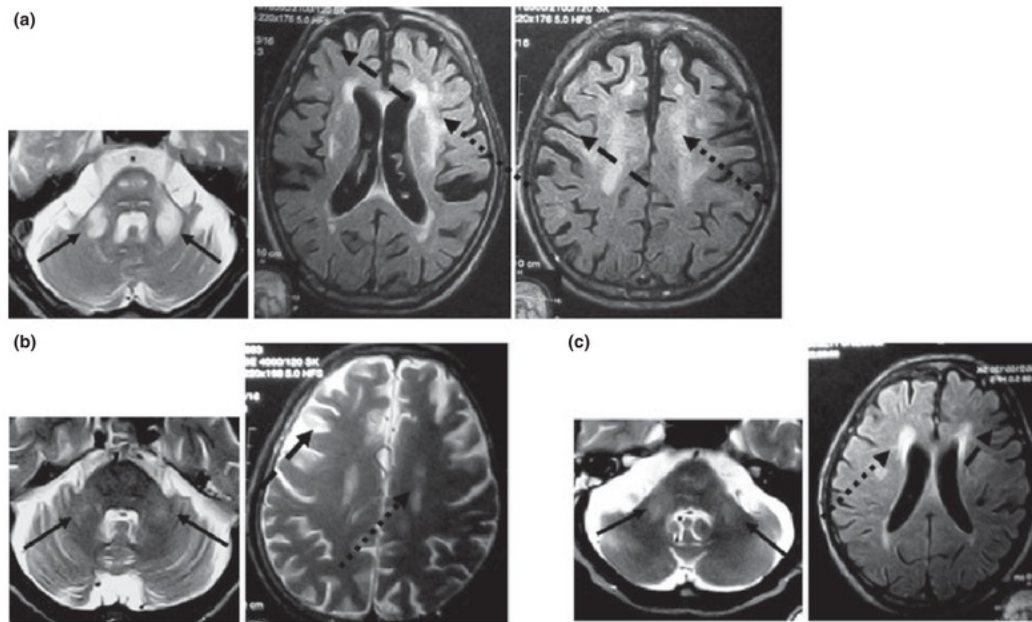


Fig. 2. Radiological imaging of three premutation males. Solid arrow shows middle cerebellar peduncle (MCP) sign, dashed arrow indicate cerebral atrophy, and dotted arrow indicates white matter disease. Radiological imaging case 1 shows obvious MCP sign, severe cerebral atrophy, and extensive white matter disease in cerebrum (a); case 2 shows moderate MCP sign, moderate cerebral atrophy, and limited white matter disease (b); case 3 shows remarkable MCP sign, mild cerebral atrophy, and limited white matter disease (c).

frequently and effectively as a farmer compared to his peers and at 72, he fell off a ladder and used a cane ever since because of instability in walking (ataxia). Cognitive impairment has been reported by his family, especially short-term memory problems. The MCP sign

and significant cerebral atrophy was found on MRI and because of tremor and ataxia on examination he was diagnosed with definite FXTAS. He had hypertension, hearing impairment and numbness, tingling and burning of feet, which were all documented on examination

Table 2. Cognitive function test result of male premutation cases

Case	Formal education	Cognitive function
Case 1	Second grade of elementary school	MMSE test: N/A Raven test: <5th percentile WAIS-R results: - Verbal IQ = 99 - Non-verbal IQ = 93 - Full IQ = 89 (low average) - Digit span/short-term memory = 5 (very low)
Case 2	First grade of elementary school	MMSE test: 15 (definite cognitive impairment) Raven test: <5th percentile WAIS-R results: - Verbal IQ = 71 - Non-verbal IQ = 69 - Full IQ = 68 (mild mental retardation) - Digit span/short term memory = 2 (very low)
Case 3	No formal education	MMSE test: 27 (normal) Raven test: <5th percentile WAIS-R results: - Verbal IQ = 84 - Non-verbal IQ = 75 - Full IQ = 71 (borderline) - Digit span/short-term memory = 6 (low)

MMSE, mini mental state examination; N/A, not available.

(Table 1). He has three sons and three daughters. His first daughter has three children with FXS (one boy, two girls).

Case 2 is a 70-year-old male farmer with a premutation of 104 CGG repeats. His family recognized his cognitive decline 5 years ago and it became particularly problematic over the last 2 years with short-term memory problems interfering with daily activities. Hypertension, hearing impairment and also numbness, tingling and burning feet had been self-reported. He has two daughters and one son, and healthy grandchildren. His examination is outlined in Table 1. He is diagnosed with definite FXTAS and cognitive impairment consistent with dementia and severe hypertension. His MRI showed the MCP sign and significant brain atrophy (Fig. 2).

Case 3 is a 68-year-old male farmer with a premutation of 110 CGG repeats. He complained of cognitive decline beginning 3 years ago, but he is still managing financial matters. Hypertension and hearing impairment had been self-reported. His examination was documented in Table 1; he did not demonstrate tremor and ataxia. Surprisingly, MRI showed a noticeable MCP sign with additional white matter disease. He had cognitive impairment, with Raven test <5th percentile and very low short-term memory test. He has two sons and one granddaughter. His diagnosis is FXTAS presenting with cognitive impairment and severe hypertension but without significant tremor and ataxia.

29

Discussion

We report the first three cases of FXTAS in Indonesia. Progression is age dependent with the oldest affected

the most and the youngest the least. There is also a similar pattern of symptom progression: hypertension, cognitive decline and then tremor and ataxia. Cellular studies showed that the threshold for toxicity lies between 62 and 95 CGG repeat sizes of 95 CGGs and above have an inverse correlation between *FMRI* mRNA concentration and cell viability (25). The CGG repeat lengths reported in our cases ranged from 88 to 110 repeats, the youngest one carrying 110 repeats with the mildest clinical phenotype but the earliest onset. All three cases had obvious cognitive impairment.

Inability to tandem walk is perhaps the best clinical measure to detect ataxia as previously described, and it is the main clinical sign of FXTAS (14, 26). Case 3 had no significant tremor or ataxia but presented with cognitive impairment and radiological signs of FXTAS. A similar phenotype is also reported in rural France (9). Cognitive impairment may be more obvious among people with a low socio-economic and education status and may precede symptoms of tremor and ataxia. All three cases reported here had significant MRI involvement including the MCP sign, brain atrophy and extensive white matter disease. Radiological involvement could be exacerbated by the severe untreated hypertension which is part of the autonomic dysfunction associated with the premutation and more common in FXTAS (27, 28). Similar to case 3, the MCP sign without tremor or ataxia has been reported before in premutation carriers (29) and early brain structural and anatomical abnormalities may occur before the clinical onset of FXTAS (30).

Cognitive impairment is seen in the majority of patients with FXTAS including memory and executive

function deficits (31). However, dementia is seen only in approximately 50% of male patients with FXTAS (32). Our FXTAS cases had cognitive measures consistent with dementia. However, lack of education, living in a rural environment with manual labor does not provide the intellectually stimulating environment, which could counteract cognitive decline. In addition, their hypertension may have exacerbated cognitive decline. In rural France, the relative risk to develop cognitive impairment among males with little education and mid-large size premutation alleles (70–200 CGG repeat) and small premutation alleles (55–69 CGG repeats) was estimated 6.5 and 1.1, respectively, at age 63.5 years compared to controls (9). Hearing loss seen in all three cases and previously reported in FXTAS (2) may also contribute to cognitive impairment because of lack of auditory stimulation.

Conclusions

FXTAS cases are found in the Indonesian FXS family. Screening for FXTAS is an important endeavor for professionals who see families with FXS in poor countries where access to medical care is less than optimal. Treatments are available for many of the symptoms of FXTAS including tremor, ataxia, neuropathy, chronic pain, hypertension, hypothyroidism and parkinsonism (16, 28, 33). Early treatment of hypertension may slow progression of radiological changes and cognitive decline leading to dementia.

Acknowledgments

This work was supported by Hibah Kompetitif Penelitian Berbasis Kerjasama Internasional Batch III, 2010, Directorate of Higher Education of Republic Indonesia. We thank the family who participated to this study. We all address our appreciation to Molecular Laboratory of the Department of Human Genetics of Radboud University Nijmegen Medical Centre, The Netherlands and Centre for Biomedical Research, Faculty of Medicine Diponegoro University (FMDU), Semarang, Indonesia. Our gratitude towards Department of Neurology, FMDU, Semarang Indonesia especially for Prof. Amin Husni, MD, Neurologist for neurological examination training. We also thank Lusi, Wiwik, Nanik, Rita for their help with laboratory work.

References

- Hagerman RJ, Leehey M, Heinrichs W et al. Intention tremor, parkinsonism, and generalized brain atrophy in male carriers of fragile X. *Neurology* 2001; 57: 127–130.
- Jacquemont S, Hagerman RJ, Leehey MA et al. Penetrance of the fragile X-associated tremor/ataxia syndrome in a premutation carrier population. *JAMA* 2004; 291: 460–469.
- Rodriguez-Revenga L, Madrigal I, Pagonabarraga J et al. Penetrance of FMR1 premutation associated pathologies in fragile X syndrome families. *Eur J Hum Genet* 2009; 17: 1359–1362.
- Fernandez-Carvajal I, Walichiewicz P, Xiaosen X, Pan R, Hagerman PJ, Tassone F. Screening for expanded alleles of the FMR1 gene in blood spots from newborn males in a Spanish population. *J Mol Diagn* 2009; 11: 324–329.
- Tassone F, Hagerman RJ, Taylor AK, Gane LW, Godfrey TE, Hagerman PJ. Elevated levels of FMR1 mRNA in carrier males: a new mechanism of involvement in the fragile-X syndrome. *Am J Hum Genet* 2000; 66: 6–15.
- Hagerman PJ, Hagerman RJ. Fragile X-associated tremor/ataxia syndrome (FXTAS). *Ment Retard Dev Disabil Res Rev* 2004; 10: 25–30.
- Greco CM, Hagerman RJ, Tassone F et al. Neuronal intranuclear inclusions in a new cerebellar tremor/ataxia syndrome among fragile X carriers. *Brain* 2002; 125: 1760–1771.
- Jacquemont S, Leehey MA, Hagerman RJ, Beckett LA, Hagerman PJ. Size bias of fragile X premutation alleles in late-onset movement disorders. *J Med Genet* 2006; 43: 804–809.
- Sevin M, Kutalik Z, Bergman S et al. Penetrance of marked cognitive impairment in older male carriers of the FMR1 gene premutation. *J Med Genet* 2009; 46: 818–824.
- Greco CM, Berman RF, Martin RM et al. Neuropathology of fragile X-associated tremor/ataxia syndrome (FXTAS). *Brain* 2006; 129: 243–255.
- Brouwer JR, Huizer K, Severijnen LA et al. CGG-repeat length and neuropathological and molecular correlates in late-onset movement disorders for fragile X-associated tremor/ataxia syndrome. *J Neurochem* 2008; 107: 1671–1682.
- Hantash FM, Goos DM, Crossley B et al. FMR1 premutation carrier frequency in patients undergoing routine population-based carrier screening: insights into the prevalence of fragile X syndrome, fragile X-associated tremor/ataxia syndrome, and fragile X-associated primary ovarian insufficiency in the United States. *Genet Med* 2011; 13: 39–45.
- Bourgeois JA, Seritan AL, Casillas EM et al. Lifetime prevalence of mood and anxiety disorders in fragile X premutation carriers. *J Clin Psychiatry* 2011; 72: 175–182.
- Jacquemont S, Hagerman RJ, Leehey M et al. Fragile X premutation tremor/ataxia syndrome: molecular, clinical, and neuroimaging correlates. *Am J Hum Genet* 2003; 72: 869–878.
- Adams JS, Adams PE, Nguyen D et al. Volumetric brain changes in females with fragile X-associated tremor/ataxia syndrome (FXTAS). *Neurology* 2007; 69: 851–859.
- Hagerman RJ, Hall DA, Coffey S et al. Treatment of fragile X-associated tremor ataxia syndrome (FXTAS) and related neurological problems. *Clin Interv Aging* 2008; 3: 251–262.
- Ortigas MC, Bourgeois JA, Schneider A et al. Improving fragile X-associated tremor/ataxia syndrome symptoms with memantine and venlafaxine. *J Clin Psychopharmacol* 2010; 30: 642–644.
- Raven JC, Court JH, Raven J. *Handbook of the matrices progressive tests*. Madrid: TEA, 1996.
- Matarazzo JD. *Wechsler's measurement and appraisal of adult intelligence*, 5th edn. New York: Oxford University Press, 1972.
- Bain PG. Clinical measurement of tremor. *Mov Disord* 1998; 13 (Suppl. 3): 77–80.
- Feys PG, Davies-Smith A, Jones R et al. Intention tremor rated according to different finger-to-nose test protocols: a survey. *Arch Phys Med Rehabil* 2003; 84: 79–82.
- Notermans NC, van Dijk GW, van der Graaf Y, van Gijn J, Wokke JH. Measuring ataxia: quantification based on the standard neurological examination. *J Neurol Neurosurg Psychiatry* 1994; 57: 22–26.
- Thomas M, Jankovic J, Suteerawattananon M et al. Clinical gait and balance scale (GABS): validation and utilization. *J Neurol Sci* 2004; 217: 89–99.
- Schmahmann JD, Gardner R, MacMore J, Vangel MG. Development of a brief ataxia rating scale (BARS) based on a modified form of the ICARS. *Mov Disord* 2009; 24: 1820–1828.
- Hoem G, Raske CR, Garcia-Arocena D et al. CGG-repeat length threshold for FMR1 RNA pathogenesis in a cellular model for FXTAS. *Hum Mol Genet* 2011; 20: 2161–2170.
- Leehey MA, Berry-Kravis E, Min SJ et al. Progression of tremor and ataxia in male carriers of the FMR1 premutation. *Mov Disord* 2007; 22: 203–206.
- Coffey SM, Cook K, Tartaglia N et al. Expanded clinical phenotype of women with the FMR1 premutation. *Am J Med Genet A* 2008; 146A: 1009–1016.
- Hamlin A, Sukharev D, Campos L et al. Hypertension in FMR1 premutation males with and without fragile X-associated tremor/ataxia syndrome (FXTAS). *Am J Med Genet A* 2012; 158A: 1304–1309.

Winarni et al.

29. Loesch DZ, Cook M, Litewka L et al. A low symptomatic form of neurodegeneration in younger carriers of the FMR1 premutation, manifesting typical radiological changes. *J Med Genet* 2008; 45: 179–181.
30. Hashimoto R-I, Javan AK, Tassone F, Hagerman RJ, Rivera SM. A voxel-based morphometry study of grey matter loss in fragile X-associated tremor/ataxia syndrome. *Brain* 2011; 134: 863–878.
31. Grigsby J, Brega AG, Leehey MA et al. Impairment of executive cognitive functioning in males with fragile X-associated tremor/ataxia syndrome. *Mov Disord* 2007; 22: 645–650.
32. Seritan AL, Nguyen DV, Farias ST et al. Dementia in fragile X-associated tremor/ataxia syndrome (FXTAS): comparison with Alzheimer's disease. *Am J Med Genet B Neuropsychiatr Genet* 2008; 147B: 1138–1144.
33. Berry-Kravis E, Hall DA, Leehey MA, Hagerman RJ. Treatment and management of FXTAS. In: Tassone F, Berry-Kravis EM, eds. *The fragile X-associated tremor ataxia syndrome (FXTAS)*. New York: Springer, 2010: 137–154.

ORIGINALITY REPORT

17%

SIMILARITY INDEX

13%

INTERNET SOURCES

14%

PUBLICATIONS

3%

STUDENT PAPERS

PRIMARY SOURCES

- | | | |
|---|---|----|
| 1 | copac.jisc.ac.uk
Internet Source | 1% |
| 2 | J. Y. Wang, A. M. Trivedi, N. R. Carrillo, J. Yang et al. "Open-Label Allopregnanolone Treatment of Men with Fragile X-Associated Tremor/Ataxia Syndrome", <i>Neurotherapeutics</i> , 2017
Publication | 1% |
| 3 | uad.portalgaruda.org
Internet Source | 1% |
| 4 | www.dtic.mil
Internet Source | 1% |
| 5 | Loftus, Sheree L.. "Qi Gong to Improve Postural Stability (QTIPS) for Parkinson Fall Prevention : A Neuroplasticity Approach", <i>Topics in Geriatric Rehabilitation</i> , 2014.
Publication | 1% |
| 6 | "Patent Application Titled "Methods of Treating Fragile X Syndrome and Related Disorders" Published O", <i>Mental Health Law Weekly</i> , Dec | 1% |

19 2015 Issue

Publication

-
- | | | |
|----|---|----|
| 7 | thieme-connect.com
Internet Source | 1% |
| 8 | Martínez-Cerdeño, Verónica, Mirna Lechpammer, Aisha Lott, Andrea Schneider, and Randi Hagerman. "Fragile X–Associated Tremor/Ataxia Syndrome in a Man in His 30s", <i>JAMA Neurology</i> , 2015.
Publication | 1% |
| 9 | E Husu. "Phenotype in 18 Danish subjects with genetically verified CHARGE syndrome", <i>Clinical Genetics</i> , 04/2012
Publication | 1% |
| 10 | academic.oup.com
Internet Source | 1% |
| 11 | P. Grandjean. "Pesticide Exposure and Stunting as Independent Predictors of Neurobehavioral Deficits in Ecuadorian School Children", <i>PEDIATRICS</i> , 03/01/2006
Publication | 1% |
| 12 | fragilex.org
Internet Source | 1% |
| 13 | www.labome.org
Internet Source | 1% |
-

asea-uninet.org

14

Internet Source

<1%

15

pdfs.semanticscholar.org

Internet Source

<1%

16

C. K. Iwahashi. "Protein composition of the intranuclear inclusions of FXTAS", Brain, 11/29/2005

Publication

<1%

17

www.hal.inserm.fr

Internet Source

<1%

18

lrd.yahooapis.com

Internet Source

<1%

19

www.cdc.gov

Internet Source

<1%

20

De Pablo-Fernandez, E., K. M. Doherty, J. L. Holton, T. Revesz, A. Djamshidian, P. Limousin, K. P. Bhatia, T. T. Warner, A. J. Lees, and H. Ling. "Concomitant fragile X-associated tremor ataxia syndrome and Parkinson's disease: a clinicopathological report of two cases", Journal of Neurology Neurosurgery & Psychiatry, 2014.

Publication

<1%

21

Bourgeois, J.A.. "Cognitive, anxiety and mood disorders in the fragile X-associated

<1%

tremor/ataxia syndrome", General Hospital
Psychiatry, 200707/08

Publication

-
- | | | |
|----|---|-----|
| 22 | search.crossref.org
Internet Source | <1% |
|----|---|-----|
-
- | | | |
|----|---|-----|
| 23 | www.tandfonline.com
Internet Source | <1% |
|----|---|-----|
-
- | | | |
|----|--|-----|
| 24 | Agatino Battaglia. "The behavioral phenotype of FMR1 mutations", American Journal of Medical Genetics Part C Seminars in Medical Genetics, 11/15/2010
Publication | <1% |
|----|--|-----|
-
- | | | |
|----|---|-----|
| 25 | R Willemsen. "CGG repeat in the FMR1 gene: size matters", Clinical Genetics, 09/2011
Publication | <1% |
|----|---|-----|
-
- | | | |
|----|---|-----|
| 26 | topics.sciencedirect.com
Internet Source | <1% |
|----|---|-----|
-
- | | | |
|----|---|-----|
| 27 | research.bangor.ac.uk
Internet Source | <1% |
|----|---|-----|
-
- | | | |
|----|---|-----|
| 28 | "Report Summarizes Human Molecular Genetics Study Findings from University of California.", Drug Week, July 6 2012 Issue
Publication | <1% |
|----|---|-----|
-
- | | | |
|----|---|-----|
| 29 | neurologyasia.org
Internet Source | <1% |
|----|---|-----|
-

30

www.isprm2015.org

Internet Source

<1%

31

116.118.248.187

Internet Source

<1%

32

Laia Rodriguez-Revenga. "Screening for FXTAS in 95 Spanish Patients Negative for Huntington Disease", Genetic Testing, 03/2008

Publication

<1%

33

www.nature.com

Internet Source

<1%

34

Emily Graves Allen, Jessica E. Hunter, Michele Rusin, Jorge Juncos et al. "Neuropsychological findings from older premutation carrier males and their noncarrier siblings from families with fragile X syndrome.", Neuropsychology, 2011

Publication

<1%

35

Bose-O'Reilly, S.. "Health assessment of artisanal gold miners in Indonesia", Science of the Total Environment, 20100115

Publication

<1%

36

Deborah A. Hall, Meghan Hermanson, Emily Dunn, Glenn Stebbins et al. "The Corpus Callosum Splenium Sign in Fragile X-Associated Tremor Ataxia Syndrome", Movement Disorders Clinical Practice, 2017

Publication

<1%

37

DZ Loesch. "Fragile X-associated tremor/ataxia phenotype in a male carrier of unmethylated full mutation in the FMR1 gene", *Clinical Genetics*, 04/2011

Publication

<1%

38

The Fragile X-Associated Tremor Ataxia Syndrome (FXTAS), 2010.

Publication

<1%

39

"Skin Cancer Management", Springer Nature America, Inc, 2010

Publication

<1%

40

Shaywitz, S. E.. "The Yale Neuropsychoeuducational Assessment Scales", *Schizophrenia Bulletin*, 1982.

Publication

<1%

41

J. A. Severin. "Unusually High Prevalence of Panton-Valentine Leukocidin Genes among Methicillin-Sensitive *Staphylococcus aureus* Strains Carried in the Indonesian Population", *Journal of Clinical Microbiology*, 04/09/2008

Publication

<1%

42

Results and Problems in Cell Differentiation, 2012.

Publication

<1%

Exclude quotes On

Exclude matches Off

Exclude bibliography On