

Sains Malaysiana 47(9)(2018): 2113–2118
<http://dx.doi.org/10.17576/jsm-2018-4709-20>

Multi-Disciplinary Approach for Managing Plasmacytoma: A Case Report (Pendekatan Pelbagai Disiplin untuk Menguruskan Plasmasitoma: Laporan Kes)

WINT WINT THU NYUNT, RAHAYU DRAMAN, AIDA WIDURE MOHD MUSTAPHA, NORALISA ABDUL KARIM,
 MOHD RAZIF MOHD IDRIS, NORAIMY ABDULLAH, TANG YEE LOONG, WAN FARIZA WAN JAMALUDIN,
 NORAI DAH MASIR & S FADILAH S ABDUL WAHID*

ABSTRACT

Solitary plasmacytoma (SP) is a tumor with evidence of clonal plasma cells and no other features of multiple myeloma (MM). We report a case of SP which showed multiple recurrences of SP and then evolution into overt MM. A 56-year-old man presented with the 5-month-history of right nasal obstruction and intermittent epistaxis. He had SP (extraosseous) of right nasopharynx (3.5 × 2 × 2.5 cm), with no paraproteinaemia. He received radiotherapy (56 Gy), achieving complete remission. Ten years later, he had recurrence of SP (osseous) in left tibia, presenting with pathological fracture. He received radiotherapy (50 Gy), achieving partial response. Three years later, he had recurrence of SP (osseous) in right tibia, presenting with right leg pain. He received radiotherapy (45 Gy). While receiving treatment, he had progressive swelling in the area around right eye, double vision and headache. Imaging scans showed multiple plasmacytomas. There were presence of monoclonal paraprotein, hypercalcemia and lytic bone lesions. He was diagnosed as MM (at the age of 70 years) and treated with Bortezomib-based therapy. Currently, after one cycle of treatment, clinical improvement is achieved. The importance of multi-disciplinary team approach for managing patients with plasmacytoma is highlighted in order to achieve the holistic approach of management.

Keywords: Multiple myeloma; plasmacytoma; plasma cell proliferative disorder

ABSTRAK

Plasmasitoma bersendirian (SP) adalah tumor yang menunjukkan kewujudan sel plasma klon dan tidak menunjukkan ciri-ciri mieloma multipel (MM). Kami melaporkan kes SP yang berlaku berulang kali dan kemudian berevolusi menjadi MM yang nyata. Seorang pesakit lelaki berusia 56 tahun mengalami halangan hidung kanan selama 5 bulan dan epistaksis berkala. Beliau mempunyai SP (extraosseous) di nasofarinks kanan (3.5 × 2 × 2.5 cm) dan tiada paraproteinemia. Beliau telah menerima rawatan radioterapi (56 Gy) dan mencapai remisi lengkap. Sepuluh tahun kemudian, beliau mengalami keberulangan SP (osseous) di tibia kiri dengan patah patologi. Beliau menerima radioterapi (50 Gy) dan mencapai tindak balas separa. Tiga tahun kemudian, beliau mengalami keberulangan SP (osseous) di tibia kanan, dengan kesakitan pada kaki kanan. Beliau menerima radioterapi (45 Gy). Semasa menerima rawatan, beliau mengalami pembengkakan progresif di kawasan mata kanan, penglihatan berganda dan sakit kepala. Pengimbasan imej menunjukkan plasmasitoma berbilang. Terdapat kehadiran paraprotein monoklon, hiperkalsemia dan lesi tulang lytik. Beliau didiagnosis sebagai MM (pada usia 70 tahun) dan dirawat dengan terapi Bortezomib. Selepas satu kitaran rawatan, beliau menunjukkan peningkatan secara klinikal. Kepentingan pendekatan pelbagai disiplin dalam pengurusan pesakit plasmasitoma perlu difokuskan demi mencapai pendekatan pengurusan yang holistik.

Kata kunci: Gangguan proliferaatif sel plasma; mieloma multipel; plasmasitoma

INTRODUCTION

A plasmacytoma is a discrete, solitary mass of neoplastic monoclonal plasma cells in either bone or soft tissue. Solitary plasmacytoma (SP) is a rare entity of plasma cell proliferative disorder and is a biopsy-proven tumor with evidence of clonal plasma cells and no evidence of other features of multiple myeloma (MM). There are 2 types of SP as determined by the location of the lesions: SP of bone and solitary extramedullary plasmacytoma. Solitary plasmacytoma of bone (solitary osseous plasmacytoma, SPB) is a localized tumor in the bone and occurs most frequently in the vertebral column. Solitary extramedullary

plasmacytoma (solitary extraosseous plasmacytoma, SEP) arises outside the bone in soft tissues and occurs most frequently in the head and neck region, mainly in the upper aerodigestive tract. Multiple plasmacytomas are defined as the presence of more than one plasmacytoma (occurring concurrently or sequentially) in the absence of bone marrow evidence of MM. Extramedullary plasmacytoma can arise in patients with multiple myeloma (MM) at any time during the course of the disease (extramedullary MM, EMM) (Swerdlow et al. 2016).

SPB accounts for approximately 5% of plasma cell malignancies. SEP accounts for approximately 3% of

plasma cell malignancies. The median age at diagnosis is 55 to 65 years in SPB and 55 to 60 years in SEP. In SPB, men are diagnosed twice as frequently as women. Approximately two-thirds of patients with SEP are male (Dores et al. 2009; Frassica et al. 1989; Shih et al. 1995). A little more than half of patients with SPB will eventually develop overt MM and SPB had a poorer prognosis than SEP (Guo et al. 2013). For patients with SPB, median overall survival (OS) was approximately 10 years; 5-year OS rate was 75%; 10-year OS rate was 45%; 5-year disease-free survival (DFS) rate was 45% and 10-year DFS rate was 25% (Frassica et al. 1989). For patients with SEP, the median overall survival was 12.5 years; 5-year OS rate was 88% and 10-year OS rate was 55% (Creach et al. 2009). Patients with SEP involving the head and neck region had superior median survival when compared to patients with other sites of SEP (13 versus 4 years) (Gerry & Lentsch 2013).

Adverse prognostic factors of SP for progression into MM are larger tumor size (≥ 5 cm), serum $\beta 2$ microglobulin > 3.5 mg/L, persistence of serum M-protein after radiation therapy (Galieni et al. 1995) and SEP with minimal marrow involvement. Other reported predictors for progression to MM include the presence of osteopenia, reduction in uninvolved immunoglobulin levels (Jackson & Scarffe 1991) and the presence of high-grade angiogenesis in the tumor sample (Kumar et al. 2003).

The treatment of choice for SEP is radiation therapy, given with curative intent at a dose of 40 to 50 Gy over four weeks (Creach et al. 2009). For patients with an incompletely resected SEP after diagnostic biopsy, local radiation therapy is recommended rather than further surgery, chemotherapy or observation (Grade 1C). For patients with completely resected SEP after diagnostic biopsy, observation is recommended rather than adjuvant radiation therapy or chemotherapy (Grade 2C) (Soutar et al. 2004). The treatment of choice for SPB is localized radiation therapy, given at a dose of 40 to 50 Gy over four weeks, directed at the tumor site (Grade 1C) (Reed et al. 2011), whereas the standard treatment for MM is systemic therapy.

We report an interesting case of solitary plasmacytoma, which showed the classical spectrum of plasma cell proliferative disorder, i.e., recurrences of plasmacytoma and then evolution into multiple plasmacytomas.

CASE REPORT

In 2003, a 56-year-old man, with hypertension and ischemic heart disease, presented with the 5-month-history of right nasal obstruction and intermittent epistaxis. He had solitary extramedullary plasmacytoma of the nasopharynx ($3.5 \times 2 \times 2.5$ cm) (Figure 1), with no paraproteinaemia. He received radical radiotherapy (56 Gy) to the nasopharynx, achieving complete remission.

Ten years later, in 2014, he had recurrence of plasmacytoma (osseous) in left tibia (10×6 cm) (Figures 1 & 2), presenting with pathological fracture. There was monoclonal paraproteinaemia (4.2 g/L, IgG lambda). He received radical radiotherapy (50 Gy) to left tibia, achieving partial response.

In July 2016, he had recurrence of plasmacytoma (osseous) in right tibia (Figure 1), presenting with 2-month-history of right leg pain and swelling. There was presence of monoclonal paraprotein (IgG lambda, 5.5 g/L in serum and 75 mg/L in urine). He received radical radiotherapy (45 Gy) to right tibia.

Just after completing radiotherapy to right tibia, in November 2016, he presented again with increasing in severity of pain in right leg. There was progressive swelling in the area around right eye, double vision and headache.

On examination, there were proptosis of right eye and swelling in right leg. Imaging scans showed multiple plasmacytomas at right frontal ($5.6 \times 4.9 \times 5.3$ cm) (SUV max: 2.7), left frontal ($1.1 \times 1.4 \times 1.4$ cm), left high frontal, left high posterior parietal, right occipital bones, both tibia (SUVmax: right 2.6, left 2.5) and hypermetabolic lytic lesions in both 4th metatarsal bones (SUVmax: right 2.7, left 2.1). The extra-axial mass at right frontal convexity extends inferiorly into the right orbital extraconal space causing proptosis of the right eye globe and displacement of the superior rectus muscle and the optic nerve inferiorly. There was erosion of the adjacent right frontal skull vault and orbital plate (Figure 1). The rest of the marrow metabolic activity was homogenously increased (SUVmax: 3.5). Nasopharynx had normal morphometabolic appearance (liver SUVmax: 3.5). Biopsy of right tibia showed osseous plasmacytoma (Table 1, Figure 2). Monoclonal paraprotein level was increasing in trend (IgG lambda, 6.3 g/L in serum and 104.7 mg/L

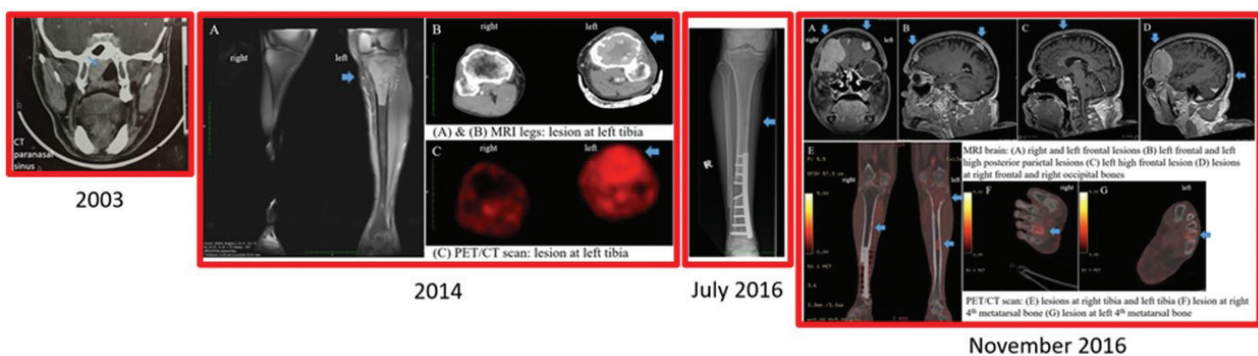


FIGURE 1. Imaging showing plasmacytomas

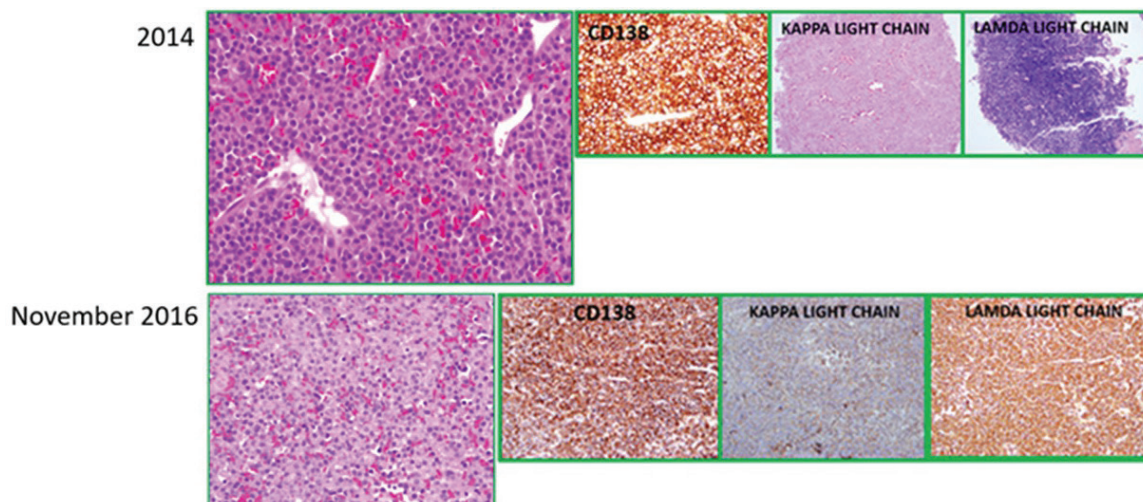


FIGURE 2. Tissue biopsy and histopathological examination (HPE) showing plasmacytomas

in urine). There were hypercalcemia (corrected calcium 2.62 mmol/L) and lytic bone lesions.

Bone marrow aspirate result showed 3% plasma cells with occasional plasma cells showing abnormal morphology such as flame shape and binuclearity. Bone marrow trephine sample was suboptimal. Conventional cytogenetic analysis of bone marrow sample showed normal male chromosome, 46,XY, with no clonal abnormality, however, fluorescence in situ hybridization (FISH) result was not available. He was treated as MM. In 2017, he was 70 years old and had multiple comorbidities such as hypertension, ischemic heart disease, diabetes mellitus and dyslipidemia. His ECOG (The Eastern Cooperative Oncology Group) performance status score (Oken et al. 1982) was 2. He was treated with Bortezomib-based therapy (Bortezomib-Thalidomide-Dexamethasone). Currently after one cycle of treatment, clinical improvement is achieved (serum paraprotein 4.1 g/L, urine paraprotein 20 mg/L, no more headache/ double vision/ proptosis/ hypercalcaemia) (Table 1).

DISCUSSION

SEPs are plasma cell tumors that arise outside of the bone marrow. Diagnosis of SEP is made based on the following features: biopsy-proven extramedullary tumor with evidence of clonal plasma cells; no lytic lesions in metastatic bone survey and either PET/CT or MRI of the spine and pelvis; no clonal plasma cells in bone marrow aspirate and biopsy; no anemia, hypercalcemia or renal insufficiency that could be attributed to a clonal plasma cell proliferative disorder (Rajkumar et al. 2006). The first presentation of our patient, i.e. SEP, demonstrated the typical presentation of SEP for age, gender and presenting symptoms. He received the standard therapy, i.e. radiotherapy, achieving complete remission and prolonged disease-free survival for 10 years.

At initial diagnosis of plasmacytoma, it is important to distinguish SP from other plasma cell dyscrasias,

especially MM, for the purpose of prognosis and treatment. Evaluation of a patient with a suspected SP should include the full diagnostic work-up of MM, i.e. unilateral bone marrow aspiration and biopsy, metastatic bone survey and either a PET/CT scan or an MRI of entire spine and pelvis, blood investigations such as complete blood count and differential with examination of peripheral blood smear, serum calcium, creatinine, albumin, lactate dehydrogenase, beta-2 microglobulin, and serum and urine protein electrophoresis with immunofixation, quantitation of immunoglobulins, serum free light chain assay, in addition to complete history and physical examination and tissue biopsy of the suspected lesion. In our patient, the diagnosis of SEP of the nasopharynx was made after the proper evaluation to exclude MM.

Following the completion of therapy, it is important to have regular follow-up at periodic intervals to monitor for treatment complications and assess for possible relapse. Progression rate of SEP to MM is reported to be between 11 and 33% over 10 years (Cantone et al. 2017). For our patient, even though he achieved complete remission from the very first plasmacytoma, he still had been regular follow-up with the otorhinolaryngology team and haematology team, resulting in early detection and timely management of his recurrences of plasmacytomas. From literature review, there were similar case reports presenting the recurrence of plasmacytoma, highlighting the importance of regular long-term follow up to monitor the disease recurrence or progression to MM (Chang et al. 2014; Corvo et al. 2013).

The recommendation for the frequency of visit is every three months for the first two years, then every six months for an additional three years, then yearly or every other year after five years. At each visit, the parameters to perform for monitoring are history and physical examination, urine and serum protein electrophoresis with immunofixation, complete blood count, serum creatinine and serum calcium. For patients with head and neck involvement, a fiberoptic endoscopy is performed at each

TABLE 1. Clinical characteristics, treatment and outcome of plasmacytomas in the patient

	2003	2014	July 2016	November 2016
Presentation	5-month-history of right nasal obstruction and intermittent epistaxis	Pathological fracture (sharp pain over left leg upon standing from the seat on the bus, then unable to walk)	2-month-history of right leg pain and swelling	Increasing in severity of pain in right leg. 2-month-history of progressive swelling in the area around right eye. double vision, headache
Physical examination	Nasal endoscopy: a friable, dark red mass arising from the roof of the nasopharynx, completely occluding the right choana	Tenderness and swelling in left leg	Tenderness in right leg	Swelling in right leg. proptosis of right eye
Imaging	CT paranasal sinus - a soft tissue mass (3.5 × 2 × 2.5 cm) in right posterior nasal space Skeletal survey XR - no lytic lesions	MRI leg -pathological fracture of left proximal tibia secondary to plasmacytoma (an well-defined lesion arising from the metadiaphyseal region of the left tibia, 10 × 6) with satellite lesions at femoral condyle and head of fibula PET/CT - active disease in left tibia (SUVmax:3.5) (liver SUVmax:3.4) lytic lesion at left frontal bone with no increased metabolic activity	XR (right leg) lytic lesion at diaphysis of right tibia	MRI brain - multicentric skull plasmacytoma [right frontal (5.6 × 4.9 × 5.3 cm), left frontal (1.1 × 1.4 × 1.4 cm), left high frontal, left high posterior parietal, right occipital bones] PET/CT - hypermetabolic extra-axial right frontal (SUVmax: 2.7) and left frontal lesions. hypermetabolic lytic lesions at both tibia (SUVmax: right 2.6, left 2.5) and 4th metatarsal bones (SUVmax: right 2.7, left 2.1)
Tissue biopsy and histopathological examination (HPE)	Biopsy of nasopharyngeal mass - extramedullary plasmacytoma. diffuse infiltration of plasma cells in submucosa; mature, eccentric nuclei, clock-face chromatin pattern. IHC: lambda restriction	Tru-cut biopsy of left tibia - osseous plasmacytoma. diffuse infiltration of sheets of plasma cells; eccentric nuclei, perinuclear halo. IHC: CD138+, lambda light chain restriction. ISH: lambda light chain restriction	Not performed	Biopsy of right tibia (bone, tissue) - osseous plasmacytoma. diffuse infiltration of neoplastic plasma cells; eccentric nuclei, perinuclear halo. IHC: CD138+, lambda light chain restriction
Diagnosis	Solitary extramedullary plasmacytoma, nasopharynx	Solitary osseous plasmacytoma, left tibia	Solitary osseous plasmacytoma, right tibia	Multiple osseous plasmacytomas (both frontal, multicentric skull, both tibia)
BMB aspirate plasma cell %	3%	3%	4%	3% (occasional plasma cells had abnormal morphology: flame shape, binuclearity)
BMB Trepine	Unsatisfactory specimen	No evidence of neoplastic plasma cell infiltration	No abnormal plasma cell infiltration	Suboptimal sample

continue

Continued (TABLE 1)

	2003	2014	July 2016	November 2016
Conventional cytogenetic analysis	46,XY [20], no clonal abnormality	Hypodiploidy (40-45 chromosomes) in 11 metaphase spreads	Not available	46,XY [17], no clonal abnormality
FISH	Not available	Not available	Not available	Not available
Hypercalcemia (Normal cCa: 2.10 - 2.55 mmol/L)	No	No	No	Hypercalcaemia (cCa 2.62 mmol/L)
Renal insufficiency (Normal creatinine: 63.6 - 110.5 µmol/L)	No	No	No	No
Anemia (Normal Hb: 13.5 - 17.4 g/dL)	No	No	No	No
SUEP	No paraproteinaemia	Monoclonal paraproteinaemia (IgG lambda)	Presence of monoclonal paraprotein (IgG lambda)	Presence of monoclonal paraprotein (IgG lambda)
SPP (g/L)	0	4.2 g/L	5.5 g/L	6.3 g/L
UPP (mg/L)	0	0	75 mg/L	104.7 mg/L
Treatment	Radical radiotherapy to the nasopharynx (56 Gy)	Radical radiotherapy to left tibia (50 Gy)	Radical radiotherapy to right tibia (45 Gy)	Bortezomib-based therapy (Bortezomib-Thalidomide-Dexamethasone) (financial constraint) Thalidomide-based therapy (Melphalan-Prednisolone-Thalidomide)
Outcome	Complete remission	Partial metabolic response	Progression	Clinical improvement

BMB: bone marrow biopsy, CT: computed tomography, cCa: corrected calcium, FISH: fluorescence *in-situ* hybridization, Hb: haemoglobin, IHC: immunohistochemistry, ISH: *in-situ* hybridization, MRI: magnetic resonance imaging, PET/CT: positron emission tomography/ computed tomography, SPP: serum paraprotein, SUEP: serum and urine protein electrophoresis, SUVmax: maximum standardized uptake value, UPP: urine paraprotein, XR: X-ray

visit. If the SEP was measurable by an imaging modality prior to therapy, the same modality (e.g. MRI) should be repeated three to four months after completing therapy, and periodically thereafter. For all patients, CT or CT/PET or MRI (whichever imaging modality was used for the initial evaluation) should be performed every 6 to 12 months for the first five years after therapy.

In our case, the patient was found to have multiple plasmacytomas involving critical sites and evolving into MM. It is crucial to be aware of timely intervention for complete diagnostic work-up in order to obtain the definitive diagnosis, especially for those with plasmacytoma involving critical sites such as eyes and central nervous system. Imaging technique like PET/CT scan plays an important role in timely detection of plasmacytoma with MM. This case report highlights the clinicians not to delay definitive treatment when plasmacytomas involves critical sites e.g. eyes, orbit, cranial nerves and spinal cord.

Bortezomib-based therapy followed by autologous haemopoietic stem cell transplantation (HSCT), whenever it is possible, is indicated for patients with solitary

plasmacytoma who progressed into overt MM. For our patient, in view of age and multiple comorbidities, he was not eligible for HSCT and opted for Bortezomib-based therapy.

CONCLUSION

The importance of multi-disciplinary approach (otorhinolaryngology, radiotherapy and oncology, orthopedic, ophthalmology, haematology teams) for managing the patients with plasmacytoma is highlighted in order to achieve the holistic approach of management in terms of: thorough evaluation at presentation to rule out MM, choice of appropriate management (radiotherapy or systemic therapy) and regular long-term follow-up to monitor recurrence of SP or progression into overt MM.

ACKNOWLEDGEMENTS

Acknowledgment was made to the patient who had given the informed written consent for publication of this case report. The authors have no conflict of interest to declare.

REFERENCES

- Cantone, E., Di Lullo, A.M., Marano, L., Guadagno, E., Mansueto, G., Capriglione, P., Catalano, L. & Iengo, M. 2017. Strategy for the treatment and follow-up of sinonasal solitary extramedullary plasmacytoma: A case series. *Journal of Medical Case Reports* 11(1): 219.
- Chang, Y.L., Chen, P.Y. & Hung, S.H. 2014. Extramedullary plasmacytoma of the nasopharynx: A case report and review of the literature. *Oncology Letters* 7(2): 458-460.
- Corvo, M.a.D.A., Granato, L., Ikeda, F. & Próspero, J.D.D. 2013. Extramedullary nasal plasmacytoma: Literature review and a rare case report. *International Archives of Otorhinolaryngology* 17(2): 213-217.
- Creach, K.M., Foote, R.L., Neben-Wittich, M.A. & Kyle, R.A. 2009. Radiotherapy for extramedullary plasmacytoma of the head and neck. *International Journal of Radiation Oncology 'Biology' Physics* 73(3): 789-794.
- Dores, G.M., Landgren, O., Mcglynn, K.A., Curtis, R.E., Linet, M.S. & Devesa, S.S. 2009. Plasmacytoma of bone, extramedullary plasmacytoma, and multiple myeloma: Incidence and survival in the United States, 1992-2004. *British Journal of Haematology* 144(1): 86-94.
- Frassica, D.A., Frassica, F.J., Schray, M.F., Sim, F.H. & Kyle, R.A. 1989. Solitary plasmacytoma of bone: Mayo clinic experience. *International Journal of Radiation Oncology 'Biology' Physics* 16(1): 43-48.
- Galièni, P., Cavo, M., Avvisati, G., Pulsoni, A., Falbo, R., Bonelli, M., Russo, D., Petrucci, M., Bucalossi, A. & Tura, S. 1995. Solitary plasmacytoma of bone and extramedullary plasmacytoma: Two different entities? *Annals of Oncology* 6(7): 687-691.
- Gerry, D. & Lentsch, E.J. 2013. Epidemiologic evidence of superior outcomes for extramedullary plasmacytoma of the head and neck. *Otolaryngology-Head and Neck Surgery* 148(6): 974-981.
- Guo, S.Q., Zhang, L., Wang, Y.F., Sun, B.C., Zhang, L.Y., Zhang, J., Wang, G. & Zhang, Y.Z. 2013. Prognostic factors associated with solitary plasmacytoma. *Oncotargets and Therapy* 6: 1659-1666.
- Jackson, A. & Scarffe, J.H. 1991. Upper humeral cortical thickness as an indicator of osteopenia: Diagnostic significance in solitary myeloma of bone. *Skeletal Radiology* 20(5): 363-367.
- Kumar, S., Fonseca, R., Dispenzieri, A., Lacy, M.Q., Lust, J.A., Wellik, L., Witzig, T.E., Gertz, M.A., Kyle, R.A. & Greipp, P.R. 2003. Prognostic value of angiogenesis in solitary bone plasmacytoma. *Blood* 101(5): 1715-1717.
- Oken, M.M., Creech, R.H., Tormey, D.C., Horton, J., Davis, T.E., Mcfadden, E.T. & Carbone, P.P. 1982. Toxicity and response criteria of the eastern cooperative oncology group. *American Journal Of Clinical Oncology* 5(6): 649-656.
- Rajkumar, S.V., Dispenzieri, A. & Kyle, R.A. 2006. Monoclonal gammopathy of undetermined significance, Waldenström macroglobulinemia, AL amyloidosis, and related plasma cell disorders: Diagnosis and treatment. *Mayo Clinic Proceedings* 81(5): 693-703.
- Reed, V., Shah, J., Medeiros, L.J., Ha, C.S., Mazloom, A., Weber, D.M., Arzu, I.Y., Orłowski, R.Z., Thomas, S.K. & Shihadeh, F. 2011. Solitary plasmacytomas. *Cancer* 117(19): 4468-4474.
- Shih, L., Dunn, P., Leung, W., Chen, W. & Wang, P. 1995. Localised plasmacytomas in Taiwan: Comparison between extramedullary plasmacytoma and solitary plasmacytoma of bone. *British Journal of Cancer* 71(1): 128.
- Soutar, R., Lucraft, H., Jackson, G., Reece, A., Bird, J., Low, E. & Samson, D. 2004. Guidelines on the diagnosis and management of solitary plasmacytoma of bone and solitary extramedullary plasmacytoma. *British Journal Of Haematology* 124(6): 717-726.
- Swerdlow, S.H., Campo, E., Pileri, S.A., Harris, N.L., Stein, H., Siebert, R., Advani, R., Ghielmini, M., Salles, G.A. & Zelenetz, A.D. 2016. The 2016 revision of the world health organization classification of lymphoid neoplasms. *Blood* 127(20): 2375-2390.
- Wint Wint Thu Nyunt, Noralisa Abdul Karim, Mohd Razif Mohd Idris, Noraimy Abdullah, Wan Fariza Wan Jamaludin & S Fadilah S Abdul Wahid*
Cell Therapy Centre, UKM Medical Centre (UKMMC)
Jalan Yaacob Latiff, Bandar Tun Razak
56000 Cheras Kuala Lumpur, Federal Territory
Malaysia
- Rahayu Draman, Tang Yee Loong & Noraidah Masir
Department of Pathology, UKM Medical Centre (UKMMC)
Jalan Yaacob Latiff, Bandar Tun Razak
56000 Cheras Kuala Lumpur, Federal Territory
Malaysia
- Aida Widure Mohd Mustapha
Department of Radiology, UKM Medical Centre (UKMMC)
Jalan Yaacob Latiff, Bandar Tun Razak
56000 Cheras Kuala Lumpur, Federal Territory
Malaysia

*Corresponding author; email: sfadilah@ppukm.ukm.edu.my

Received: 12 March 2018

Accepted: 4 May 2018