

## Case Report

# Hemospermia: An Unusual Cause of Urology Emergency

Muhammad Hilmi H<sup>1</sup>, Goh EH<sup>1</sup>, Tan GH<sup>1</sup>, Rozman Z<sup>2</sup>, Nik Azuan NI<sup>2</sup>, Fam XI<sup>1</sup>, Mohd Hafidzul J<sup>1</sup> (✉)

<sup>1</sup>Urology Unit, Department of Surgery, <sup>2</sup>Department of Radiology, Faculty of Medicine, Universiti Kebangsaan Malaysia Medical Centre, Jalan Yaacob Latif, Bandar Tun Razak, 56000 Cheras, Kuala Lumpur, Malaysia.

### Abstract

Hemospermia is a distressing disorder in sexually active men resulting in great concern to the patient. We report an unusual case of hemospermia with an atypical presentation, involving a 54-year-old man presented with acute urinary retention after sexual intercourse. Although the causes are widely known, arteriovenous malformation as the cause of this disorder has not much been reported in the literature. Transcatheter embolization of internal pudendal artery is a promising option for hemospermia caused by arterial fistula or bleeding.

**Keywords:** Arteriovenous fistula, digital subtraction angiography, embolization, hemospermia

### Correspondence:

Muhammad Hilmi Hashim. Urology Unit, Department of Surgery, Faculty of Medicine, Universiti Kebangsaan Malaysia Medical Centre, Jalan Yaacob Latif, Bandar Tun Razak, 56000 Cheras, Kuala Lumpur, Malaysia. Tel: +603-91456201 Fax: +603-91456684 Email: [hilmihashim.mhh@gmail.com](mailto:hilmihashim.mhh@gmail.com)

Date of submission: 17 March, 2017

Date of acceptance: 6 Apr, 2017

### Introduction

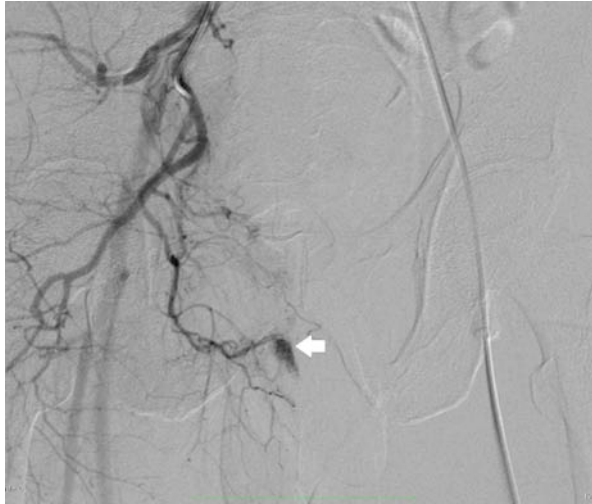
Hemospermia is defined by the appearance of the blood in the ejaculate (1). Although, the true incidence or prevalence of this condition is unknown, it is suggested to be 0.5% from population attending for prostate cancer screening (2). Despite the fact this disorder usually is not linked to serious condition, it may indicate significant underlying genitourinary pathology including prostate malignancy. Hence, thorough assessment and treatment is clearly needed.

### Case Report

A 54-year-old man presented with acute urinary retention to the emergency department requiring catheterisation and bed-side clot evacuation. Fortunately, the bleeding was self-limiting and no further intervention was needed after that. He was otherwise well and had no urinary symptoms. The patient claimed not to be a smoker and his occupation was largely office-based. Medically, he also was a case of ischemic heart disease and hypertension on

two antiplatelet medications, aspirin and clopidogrel. Only on further questioning, the patient revealed having sexual intercourse about ten hours prior to the presentation. In fact, he admitted to be having hemospermia with minimal hematuria for the last two years. The patient disclosed the hemospermia episodes only occurred a few months after he met an accident whereby he sustained cerebral concussion, multiple cervical injuries and fractured of the right fourth metatarsal bone. However, he was not able to remember whether there was any injury to the pelvic region.

Physical examination of the patient including the genitalia and prostate was unremarkable, so was the blood test, with PSA 0.49ng/ml. The International Index of Erectile Function (IIEF-5) was 23. Both cystoscopic examination and ultrasound did not detect any abnormality. The history of motor vehicular accident close to onset of hemospermia raised the suspicion of vascular abnormality hence computed tomography angiography was performed, revealing abnormal enhancement at the base of penis, potentially



**Figure 1:** Selective angiography revealed arterial fistula at the distal branches of right pudendal artery.

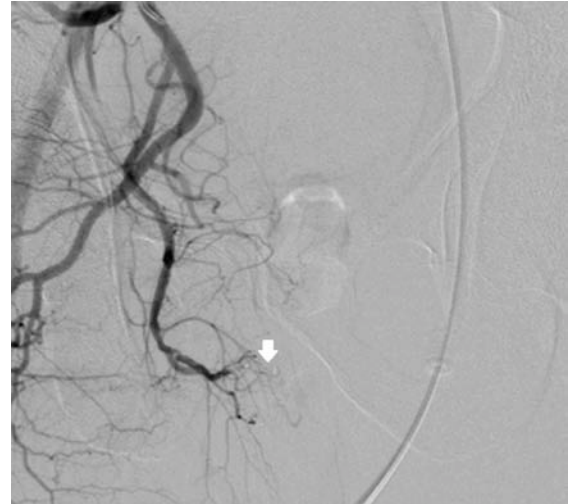an arteriovenous fistula. In the arterial phase, minimal enhancement was seen within the corpus spongiosum. On the portal venous phase, contrast pooling was seen within the corpus spongiosum and corpus cavernosum. Subsequently, the contrast pooling was thicker at the proximal penis and tapered towards the penile meatus. Digital subtraction angiography of penile artery demonstrated arteriovenous fistula at the distal branch of right internal pudendal artery (Fig. 1). Selective embolization was done at one of the distal branches of right pudendal artery, junctioning with right penile artery using histoacryl glue (Fig. 2).

Patient resumed sexual intercourse two weeks after that and he had no more hemospermia. This symptom had consistently been absent until his follow up four months later. Patient claimed that initially he had some difficulties to maintain erection during sexual intercourse after the procedure. The IIEF-5 was 6 at 3 weeks post-embolization but this had improved to 9 most recently, four months later.

## Discussion

Decades ago, the exact causes of up to 70% of the cases were not found and diagnosed as idiopathic (3). Hence, further investigations traditionally were not being pursued and patients were usually treated conservatively. With the advances in modern noninvasive imaging techniques and medical technology, idiopathic causes have reduced to 15%, as many other causes of hemospermia have been revealed (4).

Principally, the aim of the management of hemospermia was to exclude malignancy and treat any other underlying cause. Most patients would seek



**Figure 2:** Complete occlusion of the arteriovenous fistula post embolisation with histoacryl glue 30% over the distal branches of right internal pudendal artery.

for medical opinion promptly after noticing the first few episodes of hemospermia, as many of them were being concerned about risk of malignancy or sexually transmitted disease (5). Even though, commonly hemospermia followed a benign, self-limiting course, in male patient over 40 years old or those who with persistent or recurrent episodes, they subsequently required further investigations as more serious pathology may be underlying.

Alarming association between prostate cancer and hemospermia has been established with nearly 14% of men with prostate cancer presented with hemospermia (2). However, the risk of malignancy was low and considered benign for single episode of hemospermia (6). In younger patients below 40 years of age, the urogenital tract infection was the most common etiology (3).

Vascular abnormalities included arteriovenous malformations (AVM) and hemangioma have been associated to the causes of hemospermia (3). With direct blood vessel involvement, it could result in massive hemospermia leading to urinary retention due to blood clots. AVM mostly occurred in the brain, extremities, neck and kidney and it was uncommon to occur in the pelvis or genitalia area (7). The malformations may be congenital or acquired such as arteriovenous fistula as a result of trauma.

In the current era, experienced interventional radiologists may provide promising treatment option for AVM by performing transcatheter embolization of AVM. Selective arteriography was essential and has been proved useful in work up for AVM prior to surgical or radiological intervention as it was the best

method to determine the presence, extent and multiplicity of the lesions (7). In Wang et al. series, three out of five patients having arterial bleeding mainly from the internal pudendal artery stopped having hemospermia after transcatheter embolization. In the other two patients, hemospermia initially resolved but recurred after 12 and 23 months. Both of them underwent second embolization, after which the hemospermia disappeared. None of the five patients had sexual dysfunction at follow up (8). It was unfortunate that our subject developed sexual dysfunction after the procedure and it was hoped this would improve further over time.

### Conclusion

Hemospermia leading to urinary retention clearly was an unusual case of urological emergency and unless actively sought, the cause could remain a mystery. Transcatheter embolization of internal pudendal artery is a promising option for hemospermia caused by arterial fistula or bleeding. However, patient has to be informed and understand regarding the risk of impotence may still persist.

### References

1. Kumar P, Kapoor S, Nargund V. Haemospermia, a systemic review. *Ann R Coll Surg Engl* 2006; 88(4): 339-42.
2. Han M, Brannigan RE, Antenor JA, Roehl KA, Catalona WJ. Association of hemospermia with prostate cancer. *J Urol* 2004; 172(6 Pt 1): 2189-92.
3. Ahmad I, Krishna NS. Hemospermia. *J Urol* 2007; 177(5): 1613-8.
4. Papp GK, Kopa Z, Szabo F, Erdei E. Aetiology of haemospermia. *Andrologia* 2003; 35(5): 317-20.
5. Jones DJ. Hemospermia: a prospective study. *Br J Urol* 1991; 67(1): 88-90.
6. Wilson C, Boyd K, Mohammed A, Little B. A single episode of haemospermia can be safely managed in the community. *Int J Clin Pract* 2010; 64(10): 1436-9.
7. Suzuki K, Nishimi D, Morioka H, Takanami M. Hemospermia associated with congenital arteriovenous malformation of internal iliac vessels. *Int J Urol* 2007; 14(4): 370-2.
8. Wang LJ, Tsui KH, Wong YC, Huang ST, Chang PL. Arterial bleeding in patients with intractable hemospermia and concomitant hematuria: a preliminary report. *Urology* 2006; 68(5): 938-41.