

Case Report

Choroidal Metastasis from Renal Cell Carcinoma Presenting with Exudative Retinal Detachment

Hor SM, Mushawiahti M (✉)

Department of Ophthalmology, Faculty of Medicine, Universiti Kebangsaan Malaysia Medical Centre, Jalan Yaacob Latif, Bandar Tun Razak, 56000 Cheras, Kuala Lumpur, Malaysia.

Abstract

A 42-year-old Chinese man, known case of renal cell carcinoma with lung metastasis, was referred to Universiti Kebangsaan Malaysia Medical Centre for left eye blurring of vision for one month duration, which was worse upon waking up in the morning and cleared up after 1-2 hours. On examination, visual acuities were 6/6 in both eyes. No relative afferent pupillary defect. Left fundus showed inferonasal retinal detachment without macular involvement. No retina break, no retinitis and no choroidal lesion seen. Right eye examination was normal. Optical coherence tomography (OCT) of left eye showed subretinal fluid temporal and inferior to optic disc. Fundus fluorescein angiography (FFA) left eye showed hypofluorescence in early phase but hyperfluorescence with pin point leakage in late phase over inferonasal quadrant. Indocyanine green (ICG) showed early hypofluorescence with late pin point hyperfluorescence in the same quadrant. A clinical diagnosis of exudative retinal detachment due to choroidal metastasis secondary to renal cell carcinoma was made. The patient was planned for cyber-knife radiotherapy of his left eye but unfortunately we lost the follow up. High index of suspicion and relevant investigation are needed for patients with visual complaints and history of renal cell carcinoma to diagnose choroidal metastasis.

Keywords: Choroidal neoplasms, fluorescein angiography, indocyanine green, renal cell carcinoma, retinal detachment

Correspondence:

Hor Shi Mei. Department of Ophthalmology, Faculty of Medicine, Universiti Kebangsaan Malaysia Medical Centre, Jalan Yaacob Latif, Bandar Tun Razak, 56000 Cheras, Kuala Lumpur, Malaysia. Tel: +603-91457207 Fax: 03-91456733 Email: smhor5@yahoo.com

Date of submission: 9 Feb, 2017

Date of acceptance: 30 Mar, 2017

Introduction

The prevalence of uveal metastases from all forms of carcinoma is between 2.3% to 9.2% (1). The leading sites of primary cancer metastasis to uveal are breast (47%) and lung (21%), follow by gastrointestinal tract (4%), skin (2%), prostate (2%) and kidney (2%) (2). Renal cell carcinoma accounts for approximately 3% of adult malignancy (3) and frequently metastasizes via venous and lymphatic systems to lung, regional lymph nodes, liver, bone, and subcutaneous tissues. However, ocular metastasis from renal cell carcinoma have been reported to involve iris, ciliary body, choroids, eyelid, conjunctiva and lacrimal gland (4-7). In this paper, we describe a case of choroidal metastasis from renal cell carcinoma that presented

with exudative retinal detachment and the characteristic features in angiography.

Case Report

A 42-year-old man presented with one month history of blurring of vision over the left eye which was worse after waking up in the morning and resolved after one to two hours. He was diagnosed to have stage 4 renal cell carcinoma with lung metastasis just one month prior to the onset of his ocular symptom. He was commenced on oral Pazopanib as the primary was deemed inoperable. A brain and orbital magnetic resonance imaging (MRI) had done at a private center prior and it reported possible metastasis to the brain and the left orbit.

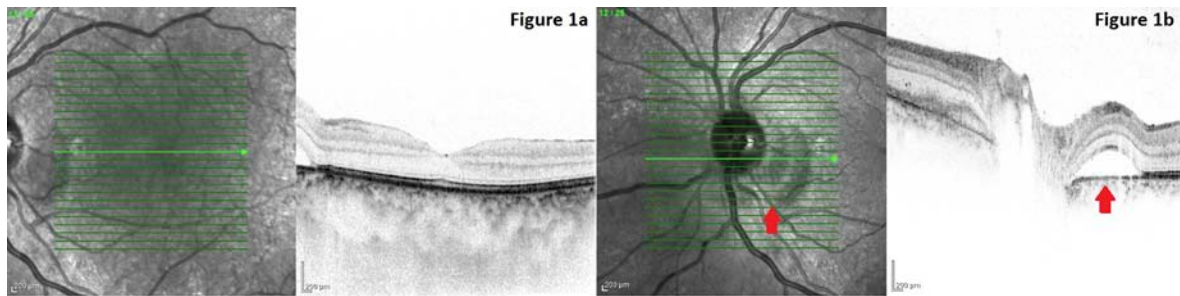


Figure 1: (a) OCT of left macula revealed normal contour which explained the good vision of patient, (b) OCT of left optic disc revealed subretinal fluid (arrow) nasal and inferior to the disc with normal retinal pigmented epithelium and choroid.

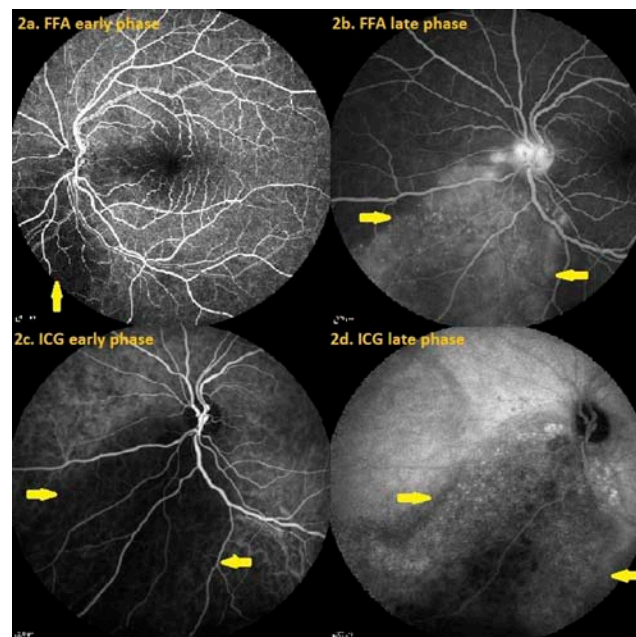


Figure 2: (a) and (b) FFA of left fundus in early phase showed hypofluorescence (arrow) in inferonasal quadrant and late phase pinpoint hyperfluorescence (arrow) in the same quadrant which was increasing in intensity, (c) and (d) ICG of left fundus showed early hypofluorescence (arrow) and late pinpoint hyperfluorescence (arrow) in the same quadrant.

On examination, visual acuities were 6/6 in both eyes. The pupillary reactions were normal. Left eye conjunctiva vessels appeared dilated infero-nasally. Left fundus showed inferonasal retinal detachment without macular involvement. Shifting fluid was demonstrated. There was no retinal break, retinitis, choroiditis or mass seen. Right eye examination was unremarkable.

Optical coherence tomography (OCT) analysis of the retinal layer revealed presence of subretinal fluid nasal and inferior to optic disc (Fig. 1a and 1b). Otherwise, there was no intraretinal oedema or thickening of retinal pigmented epithelium (RPE). Fundus fluorescein angiography (FFA) of left eye showed a lesion which was hypofluorescence in early phase but had diffuse pinpoint leakages in late phase at the inferonasal quadrant, underneath the retinal

detachment (Fig. 2a and 2b). Indocyanine green (ICG) also showed early hypofluorescence with late pinpoint hyperfluorescence in the same quadrant (Fig. 2c and 2d). These findings were commonly seen in choroidal metastatic tumour.

A clinical diagnosis of exudative retinal detachment due to choroidal metastasis secondary to renal cell carcinoma was made. The patient was planned for cyber-knife radiotherapy of his left eye. However, he defaulted subsequent follow ups.

Discussion

Uvea is the vascular middle layer of the eye and is divided into iris, ciliary body and choroid. Choroid is a highly vascularized structure which supply nutrient and provides gas exchange for the outer part of the

retina. In a survey of 950 uveal metastatic foci in 520 eyes, choroid was the most common site of metastasis (88%) followed by the iris (9%), and the ciliary body (2%) (2). Choroid is highly vascularized and thus easily accessible by neoplastic cells which travel as emboli. For a tumour to metastasize from a distant site to the eye, the tumour emboli needs to pass through the internal carotid artery, ophthalmic artery, ciliary arteries and eventually the uveal tract to reach the choroidal layer (8). Choroidal metastasis is usually located at the posterior pole as tumour emboli is likely to reach the eye via short posterior ciliary arteries than through the longer and less numerous anterior vessels (8). Choroidal metastasis could be asymptomatic (2) if the lesion is small and located at the periphery. It usually becomes symptomatic when the lesion involves the macula and optic nerve or produce exudative retinal detachment involving the macular (9) as in our case. The hallmark for exudative retinal detachment is shifting fluid, which means that when the patient is lying down, the subretinal fluid accumulates in the macular area which contributes to the blurring of vision upon waking up. In upright position, the subretinal fluid will shift inferior to macular resulting in clearing up of the vision.

Other ocular pathological conditions that may mimic choroidal metastasis are melanoma, lymphoma, choroidal haemangioma and choroidal osteoma. Investigations that aid in evaluation of these tumours include fluorescein angiography and indocyanine green angiography. Angiographic features for choroidal metastases are variable. The most commonly reported feature is hypofluorescence in the arterial and early venous phases in fluorescein angiography and becomes progressively hyperfluorescent with multiple pinpoint spot in the venous and late phases (9,10). Similar features were seen in our case. Other less common findings include normal fluorescence throughout the angiogram (9), hyperfluorescence in early phase which increases in late phase or early fluorescence in arteriovenous phase which further diminished in late phases (11). Pooling of dye occurs within the area of exudative retinal detachment in late phases (9,11). In our case, the fluorescein angiography revealed hypofluorescence in the early phase and pinpoint hyperfluorescence in the late phase within the area of exudative detachment (inferonasal quadrant). Neurosensory detachment together with localized area of metastatic tumour cells within the choroid surrounding the associated vasculature causing early hypofluorescence by blocking the light transmission. The pinpoint leakage seen in late phase was due to alteration in the overlying retinal pigment epithelium (12). It was postulated that abnormal vessels of tumours are more permeable and congested leading to

change of oncotic and hydrostatic pressure resulting in neurosensory detachment (9).

In a study of indocyanine green (ICG) videoangiographic findings in 5 cases of choroidal metastatic tumour, ICG is reported as a better modality in demonstrating the exact size of the tumour associated with serous retinal detachment as the infrared light can penetrate the detached retina and allow visualization of the choroidal lesion. Blocked fluorescent area seen in the early phase corresponded to the tumour. Late phase angiogram showed hyperfluorescence due to dye leakage through abnormal retinal pigment epithelium (12). Similar angiographic finding was noted in our patient. ICG in conjunction with fluorescein angiography are important in diagnosing and monitoring treatment response in cases of choroidal metastasis (12).

Treatment for choroidal metastasis include systemic chemotherapy and/or hormonal therapy, radiotherapy (external beam, plaque brachytherapy, Gamma knife, cyber-knife, proton beam), transpupillary thermotherapy, laser photocoagulation/photodynamic therapy, intravitreal injection, cryotherapy, resection or enucleation (1,13). Evidence-based analysis favours radiotherapy for the sight-threatening uveal metastasis (1). Cyber-knife radiotherapy is offered to this patient as the system incorporated a newer noninvasive eye fixation monitoring system which obviates the need for muscle sutures, implanted radio-opaque markers and retrobulbar anesthesia. Cyber-knife delivers fractionated radiotherapy that causes less radiation damage to surrounding structures such as lens and ciliary body.

The prognosis for choroidal metastasis is generally poor. The mean survival after onset of metastatic disease is 8 to 9 months (14).

Conclusion

Patient with renal cell carcinoma can present with exudative retinal detachment secondary to choroidal metastasis. This case highlights the angiographic features that can be seen in choroidal metastasis.

References

1. Kanthan GL, Jayamohan J, Yip D, Conway RM. Management of metastatic carcinoma of the uveal tract: an evidence-based analysis. *Clin Exp Ophthalmol* 2007; 35(6): 553-65.
2. Shields CL, Shields JA, Gross NE, Schwartz GP, Lally SE. Survey of 520 eyes with uveal

- metastases. *Ophthalmology* 1997; 104(8): 1265-76.
3. Siegel R, Ma J, Zou Z, Jemal A. Cancer statistics, 2014. *CA Cancer J Clin* 2014; 64(1): 9-29.
 4. Sabatini P, Ducic Y. Bilateral lacrimal gland masses: unusual case of metastatic renal cell carcinoma. *J Otolaryngol Head Neck Surg* 2009; 38(1): E1-2.
 5. Rodney AJ, Gombos DS, Fuller GN, Pagliaro LC, Tannir NM. Choroidal and conjunctival metastases from renal cell carcinoma. *Am J Clin Oncol* 2009; 32(4): 448-9.
 6. Shoaib KK, Haq IU, Ali K, Mukhtar MA, Nazir M. Choroidal metastasis from renal cell carcinoma presenting with cataract. *J Coll Physicians Surg Pak* 2008; 18(6): 380-1.
 7. Kurli M, Finger PT, Schneider S, Tena LB. Eyelid-sparing adjuvant radiation therapy for renal cell carcinoma. *Ophthalmologica* 2006; 220(3): 198-200.
 8. Cieplinski W, Ciesielski TE, Haine C, Nieh P. Choroid metastases from transitional cell carcinoma of the bladder. *Cancer* 1982; 50(8): 1596-1600.
 9. Spaide RF, Goldbaum M, Wong DW, Tang KC, Iida T. Serous detachment of the retina. *Retina* 2003; 23(6): 820-46; quiz 895-6.
 10. Chopdar A. *Fundus fluorescein angiography*. Oxford: Butterworth-Heinemann Ltd, 1996, pp-120-22.
 11. Davis DL, Robertson DM. Fluorescein angiography of metastatic choroidal tumors. *Arch Ophthalmol* 1973; 89(2): 97-9.
 12. Harino S, Miyamoto K, Okada M, et al. Indocyanine green videoangiographic findings in choroidal metastatic tumor. *Graefes Arch Clin Exp Ophthalmol* 1995; 233(6): 339-46.
 13. Chen CJ, McCoy AN, Brahmer J, Handa JT. Emerging treatments for choroidal metastases. *Surv Ophthalmol* 2011; 56(6): 511-21.
 14. Shields CL, Shields JA, De Potter P, et al. Plaque radiotherapy for the management of uveal metastasis. *Arch Ophthalmol* 1997; 115(2): 203-9.