

**Original Research Article****Identification of Lumbar Intervertebral Space: Palpation versus Ultrasound Technique among Obese Subjects**Selvakumar A<sup>1</sup>, Lee CY<sup>2</sup> (✉)<sup>1</sup>Department of Anaesthesiology, Universiti Putra Malaysia, 43400 Serdang, Selangor Darul Ehsan, Malaysia.<sup>2</sup>Department of Anaesthesiology and Critical Care, Faculty of Medicine, Universiti Kebangsaan Malaysia. Medical Centre, Jalan Yaacob Latif, Bandar Tun Razak, 56000 Cheras, Kuala Lumpur, Malaysia.**Abstract**

Accurate identification of the intervertebral space (IVS) is necessary during central neuraxial blockade, especially in spinal anaesthesia, to avoid untoward spinal cord injury. Ultrasound guided examination has been shown to be more accurate compared to palpation, but these studies were performed on subjects of various body weights. We conducted our prospective observational study on obese subjects and compared the performance by anaesthesiologists of various levels of anaesthetic experience. Obese subjects with body mass index (BMI)  $\geq 30$  kg/m<sup>2</sup> scheduled for elective surgery were recruited following explanation and written consent. With the subjects in the sitting position, an investigator located the L3-L4 IVS by ultrasound and used an invisible ultraviolet marker pen to mark the upper border, lower border and midpoint ("Point M") of the space. Two anaesthesiologists of varying levels of experience, categorized as Performer 1 and Performer 2, then located the L3-L4 IVS by palpation. The distance between this point and Point M was measured and recorded. Thirty-two subjects with mean BMI  $35.4 \pm 6.0$  kg/m<sup>2</sup> were recruited. The mean intervertebral distance at L3-L4 on ultrasound was 1.5 cm [range 1.2-1.8 cm]. By palpation, the L3-L4 IVS was correctly identified by 56.3%, while a higher IVS was mistaken to be L3-L4 by 23.4% of all performers. The space was correctly identified by 50% of junior anaesthesiologists and 62.5% of the senior counterparts. There was fair agreement between the two categories, with kappa = 0.375 and p = 0.028. In conclusion, there was a sizeable discrepancy between the anaesthesiologists' estimation by palpation and the actual location of the L3-L4 IVS by ultrasound among obese subjects. This observation was in fair agreement among anaesthesiologists of various levels of anaesthetic experience. The ultrasound-guided technique is useful for better identification of lumbar IVS especially in obese subjects.

**Keywords:** Body mass index, intervertebral space, obese, palpation, ultrasound

\*The abstract of this paper was submitted for poster presentation at the 16th World Congress of Anaesthesiologists in Hong Kong, 28<sup>th</sup> August – 3<sup>rd</sup> September 2016.

**Correspondence:**

Lee Choon Yee. Department of Anaesthesiology and Critical Care, Faculty of Medicine, Universiti Kebangsaan Malaysia Medical Centre, Jalan Yaacob Latif, Bandar Tun Razak, 56000 Cheras, Kuala Lumpur, Malaysia. Tel: +006-03-91455785 Fax: +006-03-91737826 Email: [lee@ppukm.ukm.edu.my](mailto:lee@ppukm.ukm.edu.my)

Date of submission: 20 Nov, 2016

Date of acceptance: 6 Apr, 2017

**Introduction**

Accurate identification of the intervertebral space (IVS) is necessary during central neuraxial blockade to locate a site below conus medullaris to avoid untoward spinal cord injury (1). The precise level of caudal

termination of the human spinal cord relative to the vertebral canal has been found to be anywhere between T12 and L3, though the great majority end opposite the L1 and L2 vertebrae (2-5). Magnetic resonance imaging (MRI) studies have demonstrated that the conus medullaris may extend as low as the

upper body of L3 (6), increasing the risk of spinal cord damage if the anaesthesiologist unwittingly selects a higher lumbar IVS for spinal anaesthesia (7,8).

Broadbent et al. demonstrated that identification of lumbar IVS by means of palpation was accurate in only 29% of cases, and one space higher than assumed in 51% (1). Accuracy was impaired by obesity and those with significant tissue oedema, particularly in the pregnant patients (9). This could lead to multiple punctures to locate the IVS, resulting in unbearable pain, discomfort and dissatisfaction to the patients. It could also be frustrating to the anaesthesiologist and might result in a failed block or other complications (10).

In the field of anaesthesia, ultrasound imaging is useful not only as a diagnostic tool but as a tool to localise the relevant anatomical structures and in so doing avoid multiple attempts and failure of procedure (11), be it regional anaesthesia or venepuncture. Furness et al. showed that ultrasound imaging identified the correct intervertebral level in up to 71% of cases, but palpation was only successful in 30% (12). Similarly, Whitty showed a poor agreement between palpation and ultrasound estimation of the specific lumbar IVS, with the ultrasound method achieving 55% accuracy (13). It should be noted that both Furness et al. (12) and Whitty et al. (13) investigated subjects with a range of body weights and not specifically on obese subjects. In a more recent study by de Figueiredo Locks et al., no significant differences were found when obese and non-obese obstetric patients were compared in terms of accuracy in locating the L3-L4 IVS (14).

In view of the above, our study was undertaken among obese non-obstetric subjects with body mass index (BMI) of  $30 \text{ kg/m}^2$ , and performed by anaesthesiologists of various levels of experience in our institution.

## Materials and Methods

This prospective observational study involved patients who were scheduled for surgery in the operating theatre in Universiti Kebangsaan Malaysia Medical Centre (UKMMC), Kuala Lumpur, Malaysia. Prior approval had been obtained from the Research Committee of the Department of Anaesthesiology and Intensive Care, UKMMC and by the Medical Research & Ethics Committee, UKMMC (Project code: FF2014-273).

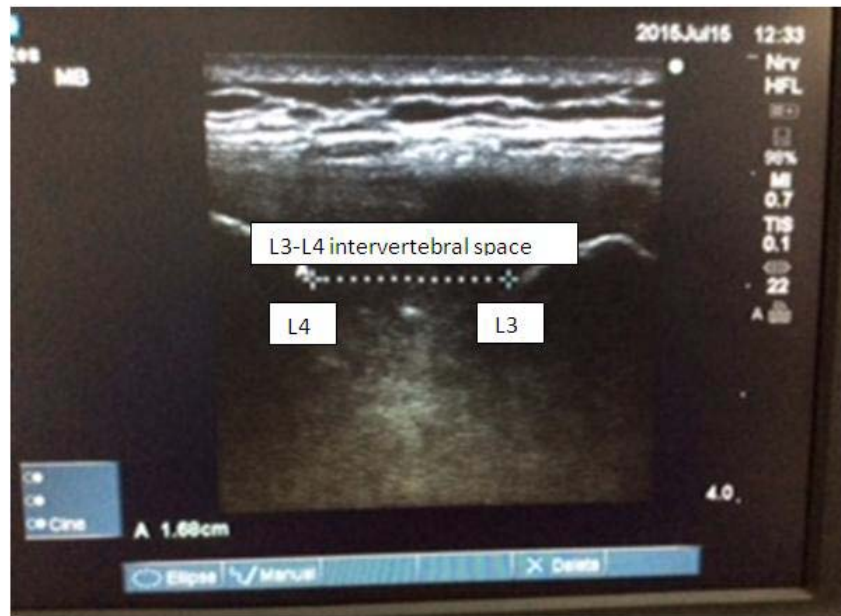Suitable subjects were identified during the premedication rounds the day prior to surgery. The

study included obese subjects (defined as  $\text{BMI} \geq 30 \text{ kg/m}^2$ ) aged between 18 to 70 years who were able to co-operate and to be placed in a sitting position during examination. Subjects who were pregnant, had abnormal spine anatomy or complained of pain at the lumbar region were excluded. Subjects were recruited after giving due explanation and obtaining informed written consent. Demographic data such as age, weight, height, BMI and ethnic group were recorded.

On the day of surgery, the study was conducted in the regional anaesthesia corner within the operation theatre complex. The subject was placed in the sitting position with the neck flexed and crouched over a pillow placed in front. The legs were placed at the edge of the trolley and supported by a stool. The height of the stool was adjusted to achieve a right angle between the thigh and the back.

Each subject was examined by three anaesthesiologists – an investigator and two performers. The investigator, S.A., identified the L3-L4 lumbar IVS by the ultrasound-guided technique, while the performers identified IVS by means of palpation. The investigator had more than five years of experience in ultrasound examination, and had performed ultrasound imaging at the lumbar IVS in more than 20 subjects. The performers comprised anaesthesiologists with varying levels of anaesthesia experience, namely junior trainee (First and Second Year in the postgraduate programme), senior trainee (Third and Fourth Year in the postgraduate programme), lecturer and consultant. The junior trainee was categorized as Performer 1 while the other three grades of anaesthesiologists as Performer 2.

The ultrasound scan of the lumbar intervertebral spaces was performed using Sonosite™ (M Turbo 2008-01, USA), a high frequency low penetration linear probe L25x/13-6MHz transducer. After application of ultrasound gel adequately for acoustic coupling in the lumbosacral region, the probe was placed in a transverse sagittal plane with adjustment of the depth and the gain manually to obtain the best possible image. The sacrum was identified as a flat hyper-echoic band with an acoustic shadow anterior to it. As the probe was moved cranially, the dip or the gap between the sacrum and the next hyper-echoic point at L5 vertebral spine was the L5-S1 IVS. The procedure was continued in a similar manner to identify the L4-L5 and the L3-L4 IVS. On reaching L3-L4, the probe was rotated 90° clockwise to the coronal plane to get both the L3 and L4 vertebral spines in the image. The distance between L3 and L4 vertebrae was measured and recorded (Fig. 1). The superior and inferior margins were marked on the skin



**Figure 1:** The ultrasound estimation of the intervertebral distance using Sonosite™ (M Turbo 2008-01, USA) showing the vertebral spines at L3-L4 vertebrae

by two horizontal lines using an invisible ultraviolet marker, and the L3-L4 IVS was defined as the distance between the marks. The midpoint of the two lines was taken as the reference point (“Point M”) from which the point identified by the palpation method was measured and compared.

Two performers, who were blinded to the ultrasound location procedure, identified the L3-L4 IVS by palpation for each subject. The anatomical landmark was the intercrystal (Tuffier’s) line, an imaginary line joining the highest palpable level of bilateral iliac crests and corresponding to the body of the L4 vertebra (15). The IVS above this is L3-L4 and the space below is L4-L5. The two horizontal lines marked by ultraviolet marker were then revealed by flashing the ultraviolet light to see whether the identified point was within the space. Its distance to Point M was measured in cm; denoted as positive when below Point M and negative when above Point M.

Sample size calculation, carried out using PS Sample Size Calculator 3.0.43 (16), was based on the study by Furness et al, in which the accuracy of palpation method was 29% (12). With the power of the study at 80% and assuming a dropout rate of 20%, the minimum sample size required was 30 giving a total of 60 readings. Data collected in the study was analysed using Statistical Package for Social Science version 22. Chi Square test was used to determine whether there was any significant difference between levels of experiences and Kappa Statistics was used to

determine the reliability of different anaesthetic category (17). A p value < 0.05 was regarded as statistically significant.

## Results

A total of 33 subjects were recruited in the study, one of whom was excluded due to violation of protocol. Of the remaining 32 subjects examined by two performers per subject, a total of 64 readings were recorded. Patients’ demographic data are shown in Table 1. The mean BMI of the subject was 35.4 kg/m<sup>2</sup>. The mean intervertebral distance at L3-L4 as measured by ultrasound was 1.5 cm [range 1.2-1.8 cm].

The accuracy in identifying the L3-L4 IVS by palpation is shown in Table 2. Collectively and regardless of anaesthetic experience, the L3-L4 IVS was correctly identified by 56.3% of the performers. Fifteen out of 64 readings (23.4%) were erroneously above and 13 readings (20.3%) below the actual L3-L4 IVS.

Taking levels of anaesthetic experience into consideration, the L3-L4 IVS was correctly identified by both performers in 13 of the 32 subjects (40.6%) and wrongly identified by both performers in 9 subjects (28.1%). Accuracy was lower in Performer 1 compared to Performer 2 (50% vs. 62.5%). Furthermore, a larger proportion of Performer 1 compared to Performer 2 (31.2% vs. 15.6%) erroneously identified IVS above L3-L4. The strength of agreement between Performer 1 and Performer 2,

**Table 1:** Demographic data, values expressed as mean ± standard deviation [range] and number (%) as appropriate

Characteristic	Value
Age (years)	32.0 ± 12.4 [21-63]
Height (cm)	163.0 ± 0.1 [150-180]
Weight (kg)	94.4 ± 21.2 [70-180]
BMI (kg/m <sup>2</sup> )	35.4 ± 6.0 [30.4-57.1]
Gender	
Male	17 (53%)
Female	15 (47%)
Race	
Malay	23 (72%)
Chinese	5 (16%)
Indian	4 (12%)

**Table 2:** Accuracy of identifying L3-L4 intervertebral space by palpation, values expressed as number (percentage)

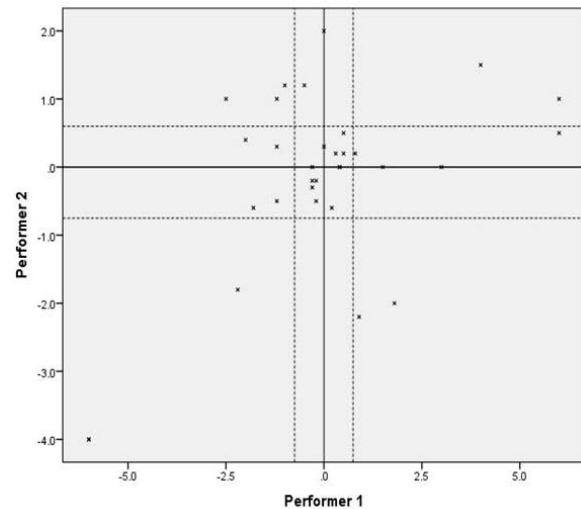
	Above L3-L4	Within L3-L4	Below L3-L4	Total
<b>Performer 1</b>	10 (31.2%)	16 (50.0%)	6 (18.8%)	32 (100%)
<b>Performer 2</b>	5 (15.6%)	20 (62.5%)	7 (21.9%)	32 (100%)
<b>Performer 1 and 2</b>	15 (23.4%)	36 (56.3%)	13 (20.3%)	64 (100%)

assessed by unweighted kappa statistic, was significant with kappa = 0.375 (fair agreement) and p = 0.028. The range of distance away from point M was between -6 cm (above) and +6 cm (below), as shown by the scatter plot in Figure 2.

Table 3 shows the subjects' BMI values arranged in ascending order and compared with accuracy of identifying the L3-L4 IVS by palpation. There was no correlation between the magnitude of BMI and success rate in identifying the IVS, either separately (Performer 1 only, Performer 2 only) or collectively (Performer 1 and Performer 2). Among the four extremely obese subjects on the upper end of the scale (BMI 39.65 kg/m<sup>2</sup> upwards), Performer 1 failed to localise the IVS while Performer 2 was successful in two of these subjects.

### Discussion

Obesity has been a great concern over the years because of the impact on health care system and has been a leading cause of death as per the World Health Organization statistics in 2014 (18). Various problems



**Figure 2:** The scatter plot for Performer 1 and Performer 2. The dotted lines represent the mean intervertebral distance at L3-L4 as measured by ultrasound

are encountered during neuraxial anaesthesia, such as difficulty in deciphering the midline and interspace, presence of fat pockets resulting in false positives when using loss-of-resistance techniques to locate the epidural space, altered drug distribution, increased risks of accidental dural puncture, epidural venous puncture as well as failure (19). In the study by Broadbent et al., the authors commented that accuracy was impaired in 20 out of 21 obese subjects in identifying the correct IVS (1). Furthermore, ultrasound-guided technique could be complicated by poor acoustic shadow which compromised image quality, especially during examination of deeper structures (9). We did not encounter this problem in our study since we were only concerned with identification of the lumbar IVS and not the depth of epidural space from the skin.

In our study on obese subjects, we found an accuracy of 56.3% with the palpation method as compared to the ultrasound-guided technique. We also found no correlation between the subjects' BMI values and the performers' success rate. The accuracy in our study was within the range of results by various investigators, namely 29% by Broadbent et al. (1), 30% by Furness et al. (12), 49-53% by de Figueiredo Locks et al. (14), 55% by Whitty et al. (13) and 67% by Tanaka et al. (20). This wide range of results could arise from differences in recruited subjects and methodology. While Broadbent et al. (1) and Furness et al. (12) investigated non-pregnant subjects of both genders and a range of body weights, studies by Whitty et al. (13) and Tanaka et al. (20) were confined to postpartum women who received central neuraxial blockade for labour or Caesarean delivery. De Figueiredo Locks et

**Table 3:** Accuracy of identifying L3-L4 intervertebral space by palpation, based on BMI

Subject Number	BMI (kg/m <sup>2</sup> )	Performer 1*	Performer 2*	Both Accurate	Both Inaccurate
14	30.40	1	1	§	
20	30.44	0	1		
32	31.11	1	1	§	
29	31.63	0	1		
16	31.88	0	0		¥
26	32.00	1	1	§	
30	32.05	0	0		¥
31	32.05	1	1	§	
11	32.17	1	1	§	
21	32.32	1	1	§	
7	32.83	0	0		¥
12	32.98	0	1		
5	33.02	1	1	§	
15	33.05	0	0		¥
13	33.53	0	0		¥
28	33.69	1	0		
4	34.28	1	0		
17	34.29	1	1	§	
19	34.45	1	0		
27	34.54	1	1	§	
23	34.85	0	1		
24	34.92	1	1	§	
10	35.00	0	0		¥
25	35.37	1	1	§	
22	35.74	1	1	§	
18	36.10	0	1		
9	38.05	0	0		¥
3	38.06	1	1	§	
6	39.65	0	1		
8	40.47	0	0		¥
2	55.09	0	1		
1	57.09	0	0		¥
			Total	13 (40.6%)	9 (28.1%)

0 = inaccurate (outside L3-L4 IVS), 1 = accurate (within L3-L4 IVS)

§ = both accurate (within L3-L4 IVS), ¥ = both inaccurate (outside L3-L4 IVS)

al. (14) also studied pregnant patients and compared the obese with non-obese individuals. In addition to the use of ultrasound, some studies used other confirmatory tests for verification, such as MRI by Broadbent et al. (1) as well as lumbar x-rays by Furness et al. (12) and Tanaka et al. (20). The recruited subjects, methodology and results of various studies are summarised in Table 4.

Our study was similar to Whitty et al. (13) and de Figueiredo Locks et al. (14) as we only compared palpation to ultrasound-guided technique without confirmatory tests by means of imaging techniques. The omission of radiological confirmation was in consideration of logistic reasons such as difficulty in scheduling due to long waiting list, increased workload to the radiology staff, increased length of hospital stay and additional cost of the investigation.

**Table 4:** Summary of studies – recruited subjects, methodology and results

Study Year	Number and Category of Subjects	Mode of Assessment	Accuracy
Broadbent et al. (1) 2000	100 General	P vs. M	P: 29%
Furness et al. (12) 2002	50 General	P vs. U vs. R	P: 30% U: 71%
Watson et al. (21) 2003	17 General	U vs. M	U: 76%
Whitty et al. (13) 2008	121 Obstetric	P vs. U	P: 55%
de Figueiredo Locks et al. (14) 2010	90 Obstetric	P vs. U	P: 53% (non-obese) P: 49% (obese) NS
Tanaka et al. (20) 2012	835 Obstetric	P vs. R	P: 67%

P = palpation, U = ultrasound, R = lumbar x-ray, M= MRI  
 NS = not significant

We also did not wish to subject our patients to the effects of radiation and its potential hazards.

The ability of the ultrasound-guided technique in locating the anatomical site quickly and reliably has been demonstrated in various studies, with accuracy in the range of 71-93.3% (10,12,21). In addition to accurate localisation of IVS, the ultrasound-guided technique was also demonstrated to be useful in estimation of the depth of epidural space from the skin and visualisation of adjacent structures at the lumbar region (9,10). Vallejo et al. showed that the ultrasound estimation prior to lumbar epidural reduced the failure rates and the number of attempts in placing the lumbar epidural catheters (11). Ultrasound has also been proven to be greatly useful in locating anatomical structures during peripheral nerve blocks and attaining arterial or venous access (9,22). The transducer used in our study was a linear probe with low penetration and high resolution properties. This yielded a high quality image and facilitated the examination without much difficulty. Other studies used transducers with curved probes, associated with higher penetration and yielded more information on deeper lying structures (9-11).

In our study, the level of experience among the anaesthesiologists ranged from 2 to 25 years. We found that the more experienced anaesthesiologists performed better compared to their junior counterparts (accuracy of 62.5% vs. 50%). Furthermore, identification of intervertebral levels higher than L3-L4 occurred more frequently in less experienced anaesthesiologists (31.2% vs. 15.6%), which could be a concern as the risk of injury to the conus medullaris

was higher. In view of this, it is pertinent that the use of ultrasound-guided technique should be promoted and used more extensively especially in obese subjects.

It must be remembered that there is a learning curve before competency in the ultrasound-guided technique is achieved. It was estimated that experience of at least 40 or more cases may be required to attain competency in ultrasound imaging of the lumbar spine (23). Other considerations include cost of acquiring the ultrasound equipment and availability in smaller hospitals. Even though it may appear to be time consuming, it can be argued that the time spent performing the procedure more than offsets the pain, discomfort and dissatisfaction of multiple attempts or a failed central neuraxial block (10).

There were few limitations in our study. We only located the L3 and L4 vertebrae and measured the L3-L4 IVS. As we could not assume this distance to be constant in other vertebral levels, we were unable to confirm the precise location for the markings outside L3-L4 IVS. For better accuracy, we should have marked all the lumbar intervertebral spaces from L1 to L5. It was also difficult to gauge the competency of the performers as the only criterion we used was the number of years of anaesthetic experience. This could have affected our results when we compared anaesthesiologists of various levels of experience. Lastly, in order to better appreciate the difficulties encountered in obese subjects, a “control” group of non-obese individuals could have been included in our study, as was done in the study by de Figueiredo Locks et al. (14).

## Conclusion

Our study showed a sizeable discrepancy between the anaesthesiologists' estimation by palpation and the actual location of the L3-L4 IVS by ultrasound among obese subjects. This observation was in fair agreement among anaesthesiologists of various levels of anaesthetic experience. The ultrasound-guided technique is useful for better identification of lumbar IVS especially in obese subjects.

## Acknowledgement

The authors acknowledge the help received from Mr. Muhamad Rahimi Che Hassan, formerly science officer in Department of Anaesthesiology and Intensive Care, UKMMC, for his statistical input.

## References

1. Broadbent CR, Maxwell WB, Ferrie R, Wilson DJ, Gawne-Cain M, Russel R. Ability of anesthetist to identify a marked lumbar interspace. *Anaesthesia* 2000; 55(11): 1122-6.
2. Thomson A. Fifth annual report of the Committee of Collective Investigation of the Anatomical Society of Great Britain and Ireland for the year 1893-94. *J Anat Physiol* 1894; 29(Pt 1): 35-60.
3. McCotter RE. Regarding the length and extent of the human medulla spinalis. *Anat Rec* 1916; 10(9): 559-64.
4. Needles JH. The caudal level of termination of the spinal cord in American whites and American Negroes. *Anat Rec* 1935; 63: 417-24.
5. Reimann AF, Anson BJ. Vertebral level of termination of the spinal cord with report of a case of sacral cord. *Anat Rec* 1944; 88: 127-38.
6. Saifuddin A, Burnett SJ, White J. The variation of position of the conus medullaris in an adult population. A magnetic resonance imaging study. *Spine (Phila Pa 1976)* 1998; 23(13): 1452-6.
7. Reynolds F. Damage to the conus medullaris following spinal anaesthesia. *Anaesthesia* 2001; 56(3): 238-47.
8. Rajakulendran Y, Rahman S, Venkat N. Long-term neurological complication following traumatic damage to the spinal cord with a 25 gauge whitacre spinal needle. *Int J Obstet Anesth* 1999; 8(1): 62-6.
9. Grau T, Leipold RW, Horter J, Conradi R, Martin E, Motsch J. The lumbar epidural space in pregnancy: visualization by ultrasonography. *Br J Anaesth* 2001; 86(6): 798-804.
10. Karmakar MK, Li X, Ho AM, Kwok WH, Chui PT. Real-time ultrasound-guided paramedian epidural access: evaluation of a novel in-plane technique. *Br J Anaesth* 2009; 102(6): 845-54.
11. Vallejo MC, Phelps AL, Singh S, Orebaugh SL, Sah N. Ultrasound decreases the failed labor epidural rate in resident trainees. *Int J Obstet Anesth* 2010; 19(4): 373-8.
12. Furness G, Reilly MP, Kuchi S. An evaluation of ultrasound imaging for identification of lumbar intervertebral level. *Anaesthesia* 2002; 57(3): 277-80.
13. Whitty R, Moore M, MacArthur A. Identification of lumbar interspinous spaces: palpation versus ultrasound. *Anesth Analg* 2008; 106(2): 538-40.
14. Locks Gde F, Almeida MC, Pereira AA. Use of ultrasound to determine the level of lumbar puncture in pregnant women. *Rev Bras Anesthesiol* 2010; 60(1): 16-9.
15. Pysyk CL, Persaud D, Bryson GL, Lui A. Ultrasound assessment of the vertebral level of the palpated intercrystal line. *Can J Anesth* 2010; 57(1): 46-9.
16. Dupont WD. *Statistical Modeling for Biomedical Researchers: A Simple Introduction to the Analysis of Complex Data*. 2nd ed. Cambridge, U.K.: Cambridge University Press, 2009, pp.485-9.
17. Viera AJ, Garrett JM. Understanding interobserver agreement: the Kappa statistics. *Fam Med* 2005; 37(5): 360-3.
18. WHO. *Global status report on noncommunicable diseases 2014*. World Health Organization: Geneva, 2015.
19. Whitty RJ, Maxwell CV, Carvalho JC. Complications of neuraxial anesthesia in an extreme morbidly obese patient for Cesarean section. *Int J Obstet Anesth* 2007; 16(2): 139-44.

20. Tanaka K, Irikoma S, Kokubo S. Identification of the lumbar interspinous spaces by palpation and verified by x-rays. *Rev Bras Anesthesiol* 2012; 63(3): 245-8.
21. Watson MJ, Evans S, Thorp JM. Could ultrasonography be used by an anaesthetist to identify a specified lumbar interspace before spinal anaesthesia? *Br J Anaesth* 2003; 90(4): 509-11.
22. Chin KJ, Perlas A. Ultrasonography of the lumbar spine for neuraxial and lumbar plexus block. *Curr Opin Anesthesiol* 2011; 24(5): 567-72.
23. Chin KJ, Perlas A, Chan V, Brown-Shreves D, Koshkin A, Vaishnav V. Ultrasound imaging facilitates spinal anesthesia in adults with difficult surface anatomy landmarks. *Anesthesiology* 2011; 115(1): 94-101.