

# Safety Issues and Neurological Improvement following C1-C2 Fusion using C1 Lateral Mass and C2 Pedicle Screw in Atlantoaxial Instability

**MK Kwan**, MS Ortho, **CYW Chan**, MS Ortho, **TCC Kwan**, **YN Gashi\***, MD, **LB Saw**, MS Ortho

Department of Orthopaedic Surgery, University Malaya Medical Centre, Kuala Lumpur, Malaysia

\*Department of Orthopaedic Surgery, University of Khartoum, Khartoum, Sudan

## ABSTRACT

The evolution of instrumentation methods for C1-C2 fusion from the use of posterior wiring methods to transarticular screws and C1 lateral mass with C2 pedicle screw construct have improved fusion rates to almost 100%. However, the C1 lateral mass and C2 pedicle screw technique is technically demanding. This is a prospective review of a series of ten patients who was planned for C1-C2 fusion using C1 lateral mass and C2 pedicle screw technique between January 2007 and June 2009. The procedure was converted to occipital cervical fusion due to a fracture of a hypoplastic lateral mass-posterior arch complex in one patient and Gallie fusion due to a vertebral artery injury in another. Eight patients underwent the C1-C2 fusion using C1 lateral mass and C2 pedicle screw successfully without any complications. The union rate was 100% with an average union time of 5.3 months (range from 3 to 8 months). Postoperatively, the patients achieved an average of one Frankel grade neurological improvement. In conclusion, this technique provides an excellent union rate and good neurological recovery.

### Key Words:

*C1 Lateral Mass, C2 Pedicle Screw, C1-C2 Instability, Outcome*

## INTRODUCTION

Cervical instability at the level of C1-C2 may be caused by congenital deformity or acquired abnormalities such as trauma, inflammatory disease, infection and tumour. Traditionally, there are several surgical management techniques used to manage C1-C2 instability such as the Gallie, Brooks-Jenkins, or interspinous methods<sup>1,2,3</sup>. Unfortunately, studies have shown that the non-union rates for these techniques are as high as 80% (range, 3 -80%) even with the use of post-operative immobilization such as the halo vest<sup>4</sup>. These unsatisfactory outcomes led to the development of newer techniques for C1-C2 fusion instrumentation including the use of C1-C2 transarticular screws<sup>5</sup>. Although biomechanically superior to the wiring

techniques, this technique is contraindicated in obese patient and in patients with increased thoracic kyphosis<sup>6</sup>. Further, this technique also requires pre-instrumentation reduction of any subluxation. In 1994, Goel and Laheri reported the use of plates and C1 lateral mass and C2 pars interarticularis screws<sup>7</sup>. In 2001, Harms and Melcher further popularized the technique of posterior C1-C2 fusion with C1 lateral mass screw and C2 pedicle screw<sup>8</sup>. Although this technique is technically demanding, it has been shown to lead to superior biomechanical and clinical results. The advantages of this new technique are safer trajectory of the screws, potential for post instrumentation reduction and avoidance of damage to the C1-C2 facet joint<sup>8</sup>. Nevertheless, the feasibility of this technique in our population has not been fully investigated in both the paediatric and adult population. This aim of this study is to report our clinical experience for the first ten cases of posterior C1-C2 instability that were planned for this method of C1-C2 fusion using the C1 lateral mass screw and C2 pedicle screw technique.

## MATERIALS AND METHODS

Ten patients with C1-C2 instability were scheduled for C1-C2 fusion using C1 lateral mass screw and C2 pedicle screw technique between January 2007 and June 2009. Two patients were converted to other modes of fixation due to intra-operative failure of C1 lateral mass screw or C2 pedicle screw insertion. Eight patients successfully underwent C1-C2 fusion using the C1 lateral mass screw and C2 pedicle screw technique.

The following outcome measures were assessed for these patients: 1) Neurological outcome graded using Frankel classification pre and post-operatively, 2) Radiological assessment of union using plain radiographs and computed tomography (CT) scan. 3) Complications/ difficulties that occurred intra- or post-operatively.

### Surgical technique

The patient was intubated using fibre-optic technique and positioned prone onto a radiolucent Jackson table with the

use of the Mayfield clamp. The position of the C1-C2 complex was verified using an image intensifier and a closed reduction was performed if required. A midline incision was used and the cervical spine was exposed subperiosteally from the occiput to the C3-4 junction. Care was exercised so as not to violate the C2-C3 and C3-C4 facet capsules. The posterior arch of C1 was exposed to visualize the edge of the vertebral artery groove and the inferior surface of the posterior arch up to the C1 lateral mass. The C1-C2 joint was not exposed. Bleeding typically will occur during dissection at this point and usually arises from the epidural venous plexus along the C2 nerve root. This was effectively controlled with a combination of bipolar electrocautery, gelfoam or cotton infused with thrombin. The entry point for the C1 screw was at the middle of the junction where the inferior aspect of the C1 posterior arch merges with the lateral mass. This entry point was described as a hybrid technique by Currier and Yaszemski<sup>6</sup>. It lies over the dense cortical bone region, therefore a thin layer of the inferior surface of the posterior arch (approximately 2mm) was removed to facilitate the creation of this entry point. Once the entry point was located with a burr, a pilot hole was then drilled in a medial convergent trajectory (10-15 degrees) [9] and the tip of the drill was directed toward the central of the anterior arch of C1, but stopped short before the posterior border of the anterior arch of C1. Integrity of the pilot hole was confirmed with a blunt probe. The hole was tapped, and a 3.5-mm polyaxial screw (Axon System, Synthes) of an appropriate length was inserted into the lateral mass of C1.

For the C2 pedicle screw, a small dissector was used to define the medial border of the C2 pars interarticularis. The entry point was burred and the isthmus of the pedicle was identified using the funnel technique as defined by Gaines<sup>10</sup>. The direction of the screw was approximately 20° to 30° in a convergent and cephalad direction toward the base of the odontoid process. Integrity of the pilot hole was confirmed with a blunt probe. The hole was tapped, and a 3.5-mm polyaxial screw (Axon System, Synthes) of the appropriate length was inserted.

Further intraoperative, reduction of C1-C2 can be achieved by using a persuader to reduce the C1 vertebrae in relation to the C2 vertebrae. (Figure 1) At this point, close observation of the blood pressure and heart rate is of utmost importance, as these changes in these two parameters would indicate compromise to the spinal cord at this level.

For fusion purposes, the posterior arch of C1 and the lamina of C2 were decorticated with a burr to prepare the raw bed for bone grafting. A large piece of corticocancellous graft was harvested from the posterior iliac crest and secured to the posterior surface of C1-C2 using Vicryl 0 suture tied to the rods. (Figure 2) Post-operatively, patients were protected using a cervical collar for a duration of 6 to 12 weeks until union was confirmed by CT scan.

## RESULTS

Out of ten patients with C1-C2 instability in this cohort, only eight patients underwent the C1 lateral mass and C2 pedicle screw procedure. There were two patients with intra-operative complications or difficulties, which resulted in conversion to other techniques of stabilization. The two excluded patients suffered from C1-C2 instability secondary to Cerebral Palsy and Rheumatoid Arthritis respectively. The procedure had to be abandoned due to a hypoplastic lateral mass and posterior arch of C1 which fractured during the procedure in one patient and a vertebral artery injury in the other. Due to these complicating factors, the procedure was eventually changed to occipital-cervical fusion (Gallie fusion not feasible in this case due of the fractured posterior arch) and Gallie fusion respectively.

Eight patients with C1-C2 instability who underwent the posterior C1-C2 fusion using C1 lateral mass screw and C2 pedicle screw were identified and evaluated. The demographic information of these eight patients and the underlying causes for C1-C2 instability are presented in Table I. The mean follow up duration was 12.5 months (range, 3m-24m). The mean age was 49.3 years (range, 10-82y) while the mean weight and height were 54.7 kg (range, 18- 75kgs) and 156.2 cm (range, 120 -178cm) respectively. None were smokers. The mean duration of hospital stay was 7.1 days (range, 3- 22d).

The pre-operative neurological status of all the eight patients who underwent this procedure and their improvement of neurological status at final follow up are illustrated in Figure 3. Neurological deficit was noted in seven patients at presentation; Frankel D (two patients), Frankel C (four patients), Frankel B (one patients). Of these seven patients, six (85.7%) showed at least one Frankel grade improvement in their neurological status at the final follow up.

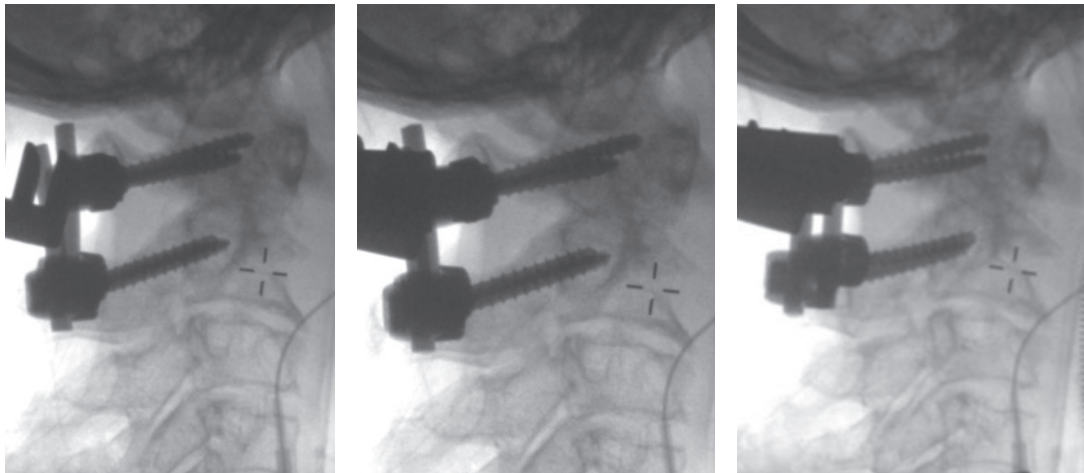
Intraoperative blood loss was less than 500mls in all patients. There were no surgical site infections, implant failures, nonunions or neurological deficits/injuries. Union was achieved in all seven patients with the average union time of 5.3 months (range, 3- 8m). (Figure 4)

## DISCUSSION

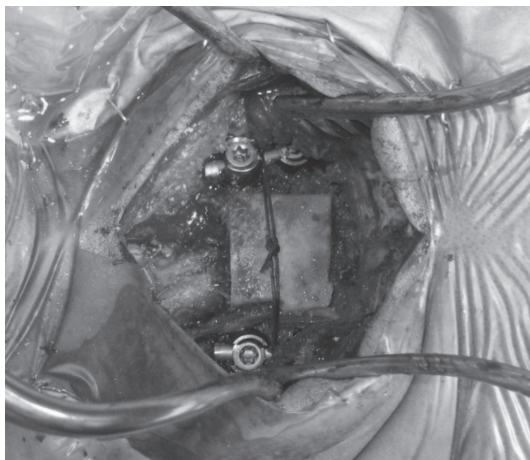
A multitude of causes can lead to instability of the C1-C2 joint such as: trauma (e.g. transverse ligament disruption and odontoid fractures); inflammatory disease (e.g. rheumatoid arthritis); infection; tumour; and congenital defects (e.g. os odontoideum)<sup>4,8,11,12,13</sup>. Failure to recognize this clinical problem can lead to progressive narrowing of the spinal canal resulting in myelopathy. This can manifest as gait instability, frank weakness or in patients who already have physical impairment, regression of motor skills.

**Table I:** Demographic information of patients whom undergone C1-C2 fusion using C1 lateral mass and C2 pedicle screw technique.

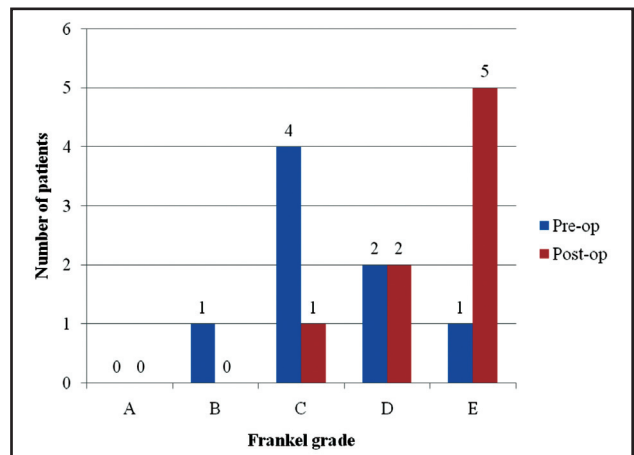
No	Age	Race	Underlying Cause for C1-C2	Follow-up	Pre Op Frankel	Post Op Frankel	Pre-operative Co-morbidities	Complications or Difficulties
1	75	Chinese	Metastases	3 days	C	C	Carcinoma of tongue and Pneumonia	Patient died on Day 3 post op due to severe pneumonia
2	60	Malay	Rheumatoid Arthritis	12 months	B	E	Nil	Nil
3	67	Chinese	Tuberculosis C1-2	24 months	D	E	Diabetes, Addison's disease, Hypertension and Urinary tract infection	Vital signs i.e. BP and PR collapsed during positioning and resolved after repositioning of the head.
4	65	Malay	Rheumatoid Arthritis	12 months	D	E	Bilateral polyarthropathies of large joints	Nil
5	10	Malay	Down Syndrome	20 months	C	D	Laxity of joints	Nil
6	85	Chinese	Degenerative	12 months	C	E	Diabetes, Hypertension	Nil
7	10	Malay	Os Odontoideum	8 months	C	D	Nil	Nil
8	25	Indian	C1-2 fracture dislocation.	12 months	E	E	Nil	Nil



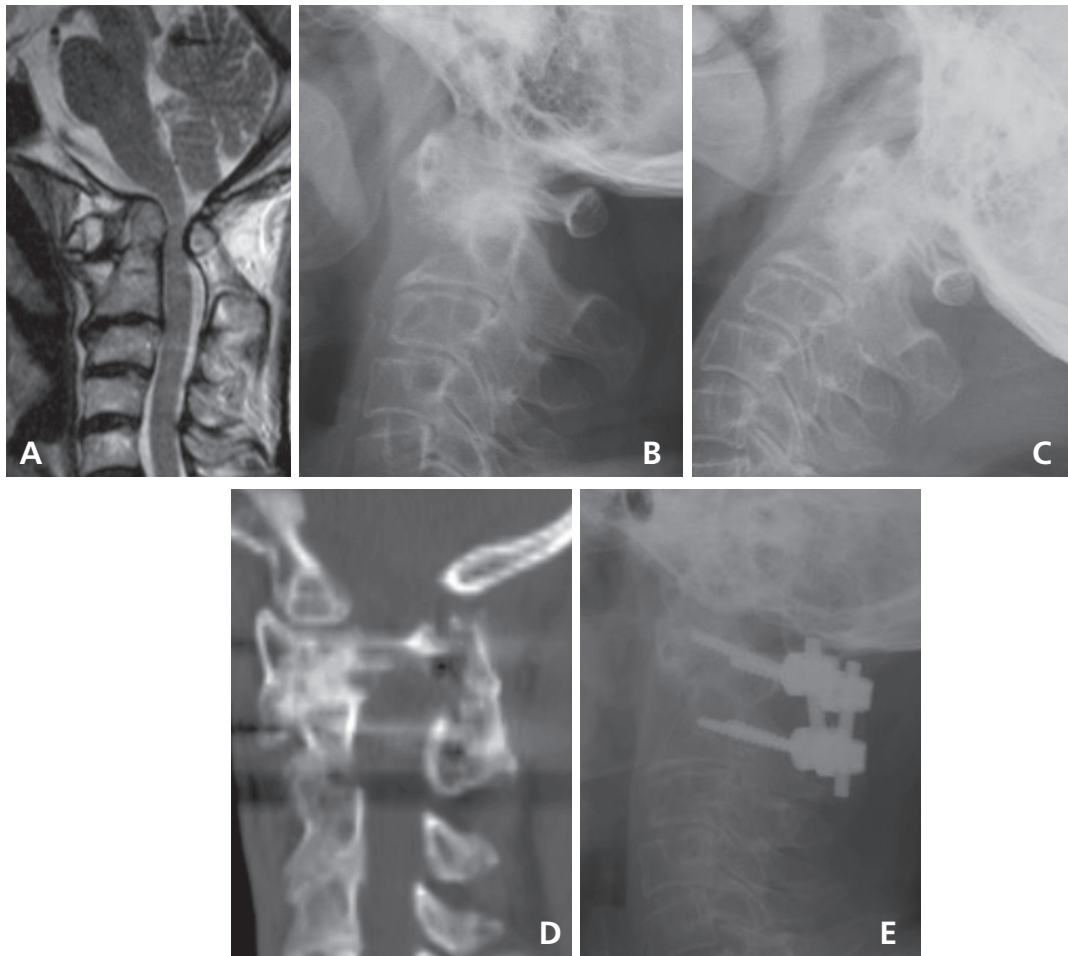
**Fig. 1:** Reduction of C1 vertebra intra-operatively was first performed manually by extending the head during positioning. The final part of reduction was performed by using the persuader as shown. A shows the pre reduction image with the reduction rods locked onto C2 first. B shows the reduction on the left side and C shows the reduction on the right side.



**Fig. 2:** shows the cotiocancellus bone graft in-situ tied with vicryl suture.



**Fig. 3:** Pre-operative and post-operative neurological status using Frankel classification.



**Fig. 4:** shows a 60 year- old female diagnosed as rheumatoid arthritis with C1-C2 instability which was treated with C1-C2 fusion using C1 lateral mass screw and C2 pedicle screws technique. A: preoperative MRI showing spinal cord compression, B and C: preoperative flexion and extension views show C1-C2 instability, D and E: final post operative radiograph and CT scan showed C1-C2 union.

Traditional surgical management of C1-C2 instability consisted of C1-C2 posterior wiring constructs and bone grafting, such as in the Gallie, Brooks-Jenkins, or interspinous methods<sup>1,2,3</sup>. The Gallie technique, although rather simple to perform, does not provide sufficient stability of the fixation site. Brooks posterior fixation of the atlantoaxial vertebrae is more complicated, but it yields a more stable repair compared to the Gallie technique<sup>14</sup>. However, these techniques require an intact lamina for the wire to hold as well as postoperative immobilization using halo vest<sup>4</sup>.

Magerl and Seemann described C1-C2 transarticular screws in 1987<sup>5</sup>. Although this technique is biomechanically stronger and has a higher union rate, the transarticular screw technique has several drawbacks. First, it requires a preliminary reduction of the C1-C2 joint before definitive fusion. Secondly, approximately 20% of patient needing C1-C2 fusions are not suitable for transarticular screws due to anatomical variations of the vertebral artery<sup>4</sup>. The distance

from the exiting screw to the vertebral artery is less than 2.5 mm in 7% of cases. Injury to the vertebral artery during this procedure has been reported in 4% of patients, whereas stroke occurs in 0.2% of patients with a mortality rate of 0.1%. The hypoglossal nerve is also at risk when this technique is used, as it lies 2 to 3 mm lateral to the anterior aspect of the C1 lateral mass<sup>15,16,17</sup>.

Harms and Melcher has popularized the technique of C1-C2 fusion using C1 lateral mass and C2 pedicle screw in 2001, and reported a 100% fusion rate. The complications reported in his study were deep wound infection, which occurred in 2.7% of cases. No vertebral artery injury or neurological complications were reported<sup>8</sup>. However, Gunnarsson *et al.* reported 12% incidence of temporary C2 neuralgia and 4.0% incidence of medial breach of the C1 lateral mass although this did not lead to any neurological events<sup>18</sup>. Other studies also reported significant rates of perforation during C1 lateral mass and C2 pedicle screw insertion. Yeom JS *et al.* showed that 8 of the 39 (20.5%) C2 pedicle screws caused

vertebral artery groove violation and 2 of the 39 (5.1%) C1 lateral mass screws showed evidence of cortical violation at C1 with one undetected vertebral artery injury<sup>9</sup>.

In the Asian population, Tan *et al.* also studied the morphometry of 50 dried atlas specimens to develop a modification of the Harms technique for placing of a C1 lateral mass screw. They found that the thickness of the posterior arch at the thinnest part of the groove was  $4.58 \pm 0.64$  mm on the left and  $4.72 \pm 0.68$  mm on the right. The thickness was less than 4 mm in 4 cases (8%). This suggested that a 3.5-mm or 4.0-mm screw would cut out of the inferior surface of the posterior arch or the superior surface (into the groove for the vertebral artery) in some cases<sup>19</sup>.

Our study was aimed at investigating the clinical outcomes and safety of this technique in our local population. In general, use of this technique led to significant improvement in neurological recovery in 85.7% of cases that presented with neurological deficit preoperatively. This could be due to the superiority of this method in terms of reduction of the C1-C2 subluxation that therefore leads to improved indirect decompression of the spinal cord. Excellent outcome was also noted in terms of fusion rate, which was 100%. All the seven follow up cases achieved union with the average union time of 5.3 months. Cervical collar was used for post-operative immobilization for a duration of 6 to 12 weeks in these seven patients. It is imperative that good preparation of the bed for the bone graft is performed and a good quality corticocancellous iliac bone graft is used. In all cases the surface of the posterior arch of atlas and the C2 lamina was decorticated using a burr and good quality corticocancellous bone graft harvested from the iliac crest was applied to the graft bed to promote union.

In two cases, conversion to an alternative procedure was needed. This was due to vertebral artery injury in one case and hypoplastic lateral mass and posterior arch of C1, which fractured during the procedure in another. In the case of vertebral artery injury, the patient did not experience any clinical deficit post-operatively. Anatomical variations of the vertebral artery and osseous anatomy should be assessed properly before performing this procedure to minimize this complication. A preoperative CT angiogram is compulsory prior to embarking on this technically demanding procedure. Knowledge and technical ability to convert to other methods of fusion (i.e., Gallie fusion and Occipital-cervical fusion) are also necessary in the event of encountering intra-operative complications or difficulties as noted in these two cases.

## CONCLUSION

C1-C2 fusion using C1 lateral mass and C2 pedicle screw provide excellent union rates and neurological recovery. However, meticulous pre-operative evaluation of the vertebral artery and the osseous anatomy are mandatory in planning this procedure to avoid complications during the procedure.

## ACKNOWLEDGEMENT

We would like to take this opportunity to express my appreciation to Miss Hew Yook Ping, Shirley Wong Kueng Chii and Pong Xiang Yinn for their invaluable help in data collection and manuscript preparation.

## REFERENCES

1. Brooks AL, Jenkins EB. Atlanto-axial arthrodesis by the wedge compression method. *J Bone Joint Surg (Am)* 1978; 60(3): 279-84.
2. Gallie WE. Fractures and dislocations of the cervical spine. *Am J Surg* 1939; 46: 495-9.
3. Dickman CA, Sonntag VK, Papadopoulos SM, Hadley MN. The interspinous method of posterior atlantoaxial arthrodesis. *J Neurosurg* 1991; 74(2): 190-8.
4. Reilly TM, Sasso RC, Hall PV. Atlantoaxial stabilization: clinical comparison of posterior cervical wiring technique with transarticular screw fixation. *J Spinal Disord Tech* 2003; 16(3): 248-53.
5. Magerl F, Seemann PS. Stable posterior fusion of the atlas and axis by transarticular screw fixation. In: Kehr P, Weiner A, eds. *Cervical Spine I*. New York: Springer-Verlag, 1987: 327-32.
6. Currier BL, Yaszemski MJ. The use of C1 lateral mass fixation in the cervical spine. *Curr Opin Orthop* 2004; 15(3): 184-91.
7. Goel A, Laheri V. Plate and screw fixation for atlanto-axial subluxation. *Acta Neurochir (Wien)* 1994; 129(1-2): 47-53.
8. Harms J, Melcher RP. Posterior C1-C2 fusion with polyaxial screw and rod fixation. *Spine* 2001; 26(22): 2467-71.
9. Yeom JS, Buchowski JM, Kun WP, Chang BS, Lee CK, Riew KD. Undetected vertebral artery groove and foramen violations during C1 lateral mass and C2 pedicle screw placement. *Spine* 2008; 33(25): 942-9.
10. Karaikovic EE, Yingsakmongkol W, Gaines RW Jr. Accuracy of cervical pedicle screw placement using the funnel technique. *Spine* 2001; 26(22): 2456-62.
11. Puschak TJ, Anderson PA. Posterior C1-C2 transarticular screws. *Tech Orthop* 2003; 17(3): 296-305.
12. Haid RW Jr, Subach BR, McLaughlin MR, Rodts GE, Wahlig JB Jr. C1-C2 transarticular screw fixation for atlantoaxial instability: a 6-year experience. *Neurosurgery* 2001; 49(1): 65-70.
13. Currier BL, Maus TP, Eck JC, Larson DR, Yaszemski MJ. Relationship of the internal carotid artery to the anterior aspect of the C1 vertebra: implications for C1-C2 transarticular and C1 lateral mass fixation. *Spine* 2008; 33(6): 635-9.
14. Saito R, Hase H, Mikami Y, Tsuji Y, Ikeda T, Osawa T, et al. Clinical study of a modified Brooks technique for atlanto-axial subluxation using polyethylene tape. *J Spinal Disord Tech* 2006; 19(1): 11-7.
15. Nogueira-Barbosa MH, Defino HL. Multiplanar reconstructions of helical computed tomography in planning of atlanto-axial transarticular fixation. *Eur Spine J* 2005; 14: 493-500.
16. Wright NM, Laurysen C. Vertebral artery injury in C1-2 transarticular screw fixation: results of a survey of the AANS/CNS section on disorders of the spin and peripheral nerves. *J Neurosurg* 1998; 4(2): 634-40.
17. Ebraheim NA, Misson JR, Xu R, Yeasting RA. The optimal transarticular C1-2 screw length and the location of the hypoglossal nerve. *Surg Neurol* 2000; 53(3): 208-10.
18. Gunnarsson T, Massicotte EM, Govender PV, Raja Rampersaud Y, Fehlings MG. The use of C1 lateral mass screws in complex cervical spine surgery: indications, techniques, and outcome in a prospective consecutive series of 25 cases. *J Spinal Disord Tech* 2007; 20(4): 308-16.
19. Tan M, Wang H, Wang Y, Zhang G, Yi P, Li Z, et al. Morphometric evaluation of screw fixation in atlas via posterior arch and lateral mass. *Spine* 2003; 28(9): 888-95.