

DOI: <http://dx.doi.org/10.22122/johoe.v7i2.245>

Published by Vesnu Publications

Received: 27 July 2016

Accepted: 05 Oct. 2017

## Incidence, location, and type of isthmus in mandibular second molars among individuals of an Iranian population

Nahid Mohammadzadeh-Akhlaghi DDS, MDS<sup>1</sup>, Payman Mehrvarzfar DDS, MDS<sup>2</sup>,  
Mohammad Hossein Zarei DDS<sup>3</sup>, Pooneh Mohebbi DDS, MDS<sup>4</sup>,  
Mohammad Ali Sabeti DDS, MSc<sup>5</sup>

### Original Article

#### Abstract

**BACKGROUND AND AIM:** Isthmuses are narrow and strip shaped connections between two canals containing pulpal tissue that may encompass bacteria as well. They are hardly accessible for cleaning; therefore, success and failure of root canal treatments could be affected by their presence. The present study was carried out aiming to evaluate the incidence, location, and type of isthmus in mandibular second molars (MSMs) among individuals of an Iranian population.

**METHODS:** 80 MSMs with inclusion criteria, belonging to individuals of an Iranian population were collected and disinfected. After embedding the samples' roots in the acrylic resin, teeth were sectioned horizontally at 2, 4, and 6 mm distances from the apices. Then they were viewed and recorded by a stereomicroscope under  $\times 30$  magnification. According to Kim classification, two endodontists recorded the number of canals, incidence, and type of the isthmuses. In cases of disagreement, a third endodontist was involved to judge on the right opinion between the two. The acquired data were analysed using chi-square test.

**RESULTS:** The results showed that 96.3% and 3.75% of MSMs had two and three roots, respectively. Type V (described in the following) was the most frequent type of isthmus at mesial and distal roots. C-shaped canals composed 3.7% of the samples and showed isthmus at all the three sections. There was a significant difference in the distribution of isthmuses ( $P < 0.001$ ).

**CONCLUSION:** According to this study, different types of isthmuses prevail in high rate of mesial and about half of the distal roots of MSMs, which are important for root canal cleaning and shaping.

**KEYWORDS:** Anatomy; Molar; Tooth; Root Canal

**Citation:** Mohammadzadeh-Akhlaghi N, Mehrvarzfar P, Zarei MH, Mohebbi P, Sabeti MA. **Incidence, location, and type of isthmus in mandibular second molars among individuals of an Iranian population.** *J Oral Health Oral Epidemiol* 2018; 7(2): 59-63.

Detection and debridement of the isthmuses are one of the most important factors affect the success of endodontic treatments of posterior teeth.<sup>1</sup> Isthmuses are narrow and strip shaped connections between two canals containing pulpal tissue, which are hardly accessible by routine root canal instruments.<sup>2</sup> Left remnants of untouched pulpal tissue are

of utmost significance while encountering the necrotic teeth accumulated by bacteria.<sup>3</sup>

Isthmuses could be found in C-shaped and two-canal roots.<sup>4</sup> The incidence of isthmus in mesial roots of mandibular molars has been reported to be 54%-89%, most of which occurring at 4-6 mm distances from the apex.<sup>4,8</sup> In a study conducted on mandibular second molars (MSMs) among Chinese population,

1- Associate Professor, Craniomaxillofacial Research Center and Department of Endodontics, Dental Branch, Islamic Azad University, Tehran, Iran

2- Associate Professor, Department of Endodontics, Dental Branch, Islamic Azad University, Tehran, Iran

3- Private Practice, Tehran, Iran

4- Assistant Professor, Department of Endodontics, Dental Branch, Islamic Azad University, Tehran, Iran

5- Associate Professor, Department of Endodontics/Periodontics, School of Dentistry, Loma Linda University, California, USA

Correspondence to: Pooneh Mohebbi DDS, MDS

Email: [pooneh.mohebbi@gmail.com](mailto:pooneh.mohebbi@gmail.com)

85% of isthmuses were detected at 5 mm distance from the apex.<sup>5</sup> In a similar study carried out in Brazil, it was revealed that the most common location for isthmus was at 5.5 mm from the apex with complete type being the most incident.<sup>9</sup> Evaluation of the location and type of isthmuses present in mesial roots of mandibular first molars has been documented among the individuals of an Iranian population.<sup>10</sup> To the best of our knowledge, there was no study regarding the investigation of the characteristics of this anatomical feature in MSMs of Iranian population. Therefore, in order to improve our knowledge with respect to the internal anatomy of teeth and to decrease the failure rate in root canal treatments, this study was conducted with the aim to assess the incidence, location, and type of the isthmuses existing in MSMs among individuals of an Iranian population according to Kim classification.<sup>6</sup>

### Methods

This cross-sectional descriptive study was approved and registered by the ethics committee of Tehran Dental School, Islamic Azad University, Tehran, Iran, under the number 24617. In this study, 80 MSM belonging to Iranian population, which have been extracted due to periodontal problems, were collected randomly from different clinics and dental offices in Tehran. Initially the total of 150 samples were kept in 5.25% sodium hypochlorite solution for an hour to be disinfected. After taking a radiography image, exposed bucco-lingually, teeth samples having internal or external resorption, open apex, crack or fracture, calcification, or previous root treatments were excluded from the study. Root surfaces were debrided from any calculus or remaining organic tissue by a scaler. Afterwards, the teeth were placed in an acrylic resin from their cervical to apical parts and horizontal sections were prepared at 2, 4, and 6 mm distances from the apex perpendicular to the long axis of the root, using a low-speed handpiece with a thin

metallic disk (0.17 mm long, 2.0 mm wide, D and Z, Germany).<sup>10</sup> The sections were fixed onto a lam, viewed and recorded by a stereomicroscope (Nikon UFX-DX, Tokyo, Japan) connected to a camera, under  $\times 30$  magnification. Two endodontists who calibrated the teeth samples regarding the types of isthmuses according to Kim classification prior to the study, marked the number of canals, incidence, and type of the isthmuses. In cases of disagreement, a third endodontist was involved to judge on the right opinion between the two.

The Kim classification consisted of 5 types [Figure 1]:

Type I: Presence of two canals without a noticeable communication

Type II: Presence of two canals without a definite communication

Type III: Similar to type II but with three canals instead of two canals

Type IV: Extension of the main canal into the isthmus

Type V: Presence of a complete communication or corridor between the two canals

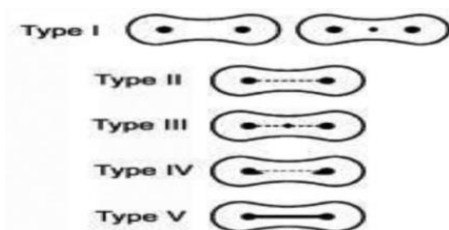


Figure 1. Isthmus classification<sup>6</sup>

When the root had one canal, it was called type 0. The acquired data regarding the relationship between the incidence and types of isthmuses with canal location were analysed using chi-square test after determining the incidence and confidence intervals. The statistical significance level was set at 0.05.

### Results

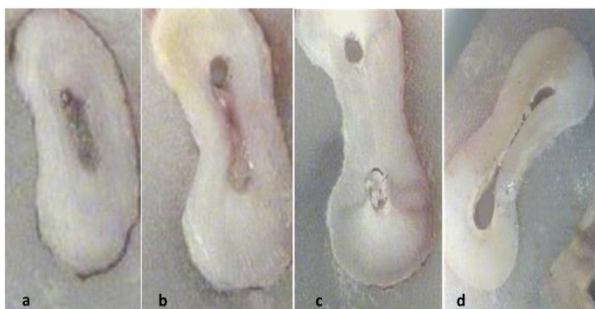
Of all the 80 evaluated MSMs, 96.3% and 3.7% were two and three rooted, respectively. 95.0% of mesial and 36.3% of distal roots were reported to have two canals.

**Table 1.** Incidence and types of isthmuses at mesial and distal roots of mandibular second molars (MSMs) along with C-shaped canals at different levels from the apex

Type	2 mm			4 mm			6 mm		
	Mesial	Distal	C-shape	Mesial	Distal	C-shape	Mesial	Distal	C-shape
I [n (%)]	21 (26.25)	2 (2.50)	-	15 (18.75)	1 (1.25)	-	12 (15.00)	-	-
II [n (%)]	14 (17.50)	1 (1.25)	-	25 (31.25)	1 (1.25)	-	26 (32.50)	1 (1.25)	-
III [n (%)]	-	-	-	-	-	-	1 (1.25)	1 (1.25)	-
IV [n (%)]	6 (7.50)	1 (1.25)	-	10 (12.50)	1 (1.25)	-	10 (12.50)	2 (2.50)	-
V [n (%)]	29 (36.25)	3 (3.75)	3 (100)	25 (31.25)	15 (18.75)	3 (100)	27 (33.75)	25 (31.25)	3 (100)
0* [n (%)]	10 (12.50)	73 (91.25)	-	5 (6.25)	62 (77.50)	-	4 (5.00)	51 (63.75)	-
%	100	100		100	100		100	100	
P	< 0.001	< 0.001	< 0.001	< 0.001	< 0.001	< 0.001	< 0.001	< 0.001	< 0.001

\*One-canal root

C-shaped canals composed 3.7% of the samples and showed isthmus at all the 3 sections. Table 1 lists the comparison of the incidence and type of isthmuses at mesial and distal roots and C-shaped canals at different levels of tooth sectioning. In addition, figure 2 shows various types of isthmuses at different sections. The incidence of isthmus at mesial roots' sections from the apex was as 61.3%, 75.1%, and 80.1% at 2, 4, and 6 mm, respectively. Similarly, the incidence of isthmus at two canal distal roots was, 6.4%, 21.2%, and 36.4% at 2, 4, and 6 mm, respectively from the apex; with complete connections being the most common type (type V). Moreover, there was a significant difference in the distribution of isthmuses ( $P < 0.001$ ).



**Figure 2.** Types of isthmus, sections, and distances from the apex respectively in mesial root of mandibular second molars (MSMs): (a) Type V, first section, 2 mm; (b) Type V, second section, 4 mm; (c) Type II, third section, 6 mm; (d) Type IV, third section, 6 mm

## Discussion

A methodology to study the internal anatomy of a tooth is a primary tool when

searching for isthmuses. In this study, 80 MSMs were used to evaluate incidence, location, and type of isthmus among individuals of an Iranian population using stereomicroscope at levels of 2, 4, and 6 mm from the apex according to Kim classification.

The results obtained in the present study indicated that 96.3% and 3.7% of MSMs were two and three-rooted, respectively. 95.0% of mesial and 36.3% of distal roots were reported to have two canals. C-shaped canals comprised 3.7% of the samples, with an isthmus being present at all three levels.

Different evaluation methods have been used in various investigations studying isthmuses, including, sectioning, staining, and clearing, sectioning and viewing under stereomicroscope, using micro-computed tomography, and cone beam computed tomography (CBCT).<sup>4,5,9,11</sup>

In the present study, MSMs were evaluated; in contrast to other studies that assessed mandibular first and second molars as a whole,<sup>5,12</sup> or used a smaller sample size when studying one type of tooth.<sup>2,6</sup>

In this study, the incidence of an isthmus being present at 6 mm from the apex in mesial roots was found to be 80.1%, which about half of them had complete connections. This finding was in accordance with a study by Fan et al. in China, who utilized CBCT to evaluate the incidence of an isthmus being present in MSMs at 5 mm distance from the apex.<sup>5</sup> In addition, they reported that the samples, which had complete connections, accounted for 76%, which was much higher

than the present study. In some studies, assessing mandibular molars as a whole, not distinguishing between first and second molars, the incidence of isthmuses in mesial roots was reported to be 54%-80% at 4-5 mm from the apex.<sup>10,13</sup>

IN the present study, an isthmus was found at 4 mm from the apex of mesial roots in 75.1% of cases, 43.8% of which were of the complete type. Hsu and Kim, in a study conducted in North America using sectioning technique, reported the incidence of isthmuses in MSMs at the 4 mm level from the apex to be 80.0%.<sup>6</sup> Some other studies announced this rate as 33%-83% at the 4 mm level in mesial roots of mandibular molars.<sup>3,7</sup>

In the present study, the rate of an isthmus being present at 2 mm from the apex of mesial roots was 61.3%, 43.8% of which were of the complete type. In some studies on the evaluation of mandibular molars, the total incidence of an isthmus in mesial roots at 2 mm distance from the apex was reported as 30%-70%.<sup>6,10</sup>

The dissimilarity noted in different studies could be due to variations in the number of samples, ethnicity, or the evaluation techniques.

Mehrvarzfar et al. used a sectioning technique and observed the samples under a stereomicroscope.<sup>10</sup> In this study, the incidence of isthmuses in mesial roots of mandibular first molars, at 2, 4, and 6 mm from the apex, was 91.7%, 88.3%, and 70.0%, respectively. The rates reported in this study were higher at all three levels when compared to the findings of the present study. However, the incidence rate of a complete isthmus at 4 mm from the apex was similar in both studies. In conclusion, the presence of isthmuses among samples from an Iranian population was higher in more

coronal sections in comparison with more apical sections. Nevertheless, both mandibular first and second molars showed a high rate of isthmuses in all three sections.

In the present study, 36.00% of distal roots were found to contain two canals, which is in contrast to the findings of the study by Lima et al. who reported that 65.40% of the lower second molars contained two canals.<sup>9</sup> C-shaped canals comprised 3.75% of the samples and always showed an isthmus of complete type at all the three sections. However, in a systematic review pertaining to the Iranian population, the total incidence of C-shaped canals was 6.96%, which is much less than Asian populations but closer to Middle Eastern countries.<sup>14</sup>

The mesial roots of human MSMs have a high incidence of isthmuses, which may be along with clinical implications, especially with regard to root canal debridement and surgical endodontics being performed on the mesial roots of these molars.

### Conclusion

Within the limits and conditions of this study, a high rate of mesial roots were found, and almost half of the distal roots of Iranian MSMs present different types of isthmuses, which could be a reservoir for accumulating bacteria and therefore, endangering the success rate of surgical and non-surgical endodontic treatments.

### Conflict of Interests

Authors have no conflict of interest.

### Acknowledgments

The authors thank Ms. Nasrin Akhondi for her helps in statistical analysis.

### References

1. Rubinstein RA, Kim S. Long-term follow-up of cases considered healed one year after apical microsurgery. *J Endod* 2002; 28(5): 378-83.
2. Teixeira FB, Sano CL, Gomes BP, Zaia AA, Ferraz CC, Souza-Filho FJ. A preliminary in vitro study of the incidence and position of the root canal isthmus in maxillary and mandibular first molars. *Int Endod J* 2003; 36(4): 276-80.
3. von Arx T. Frequency and type of canal isthmuses in first molars detected by endoscopic inspection during

- periradicular surgery. *Int Endod J* 2005; 38(3): 160-8.
4. Weller RN, Niemczyk SP, Kim S. Incidence and position of the canal isthmus. Part 1. Mesiobuccal root of the maxillary first molar. *J Endod* 1995; 21(7): 380-3.
  5. Fan B, Pan Y, Gao Y, Fang F, Wu Q, Gutmann JL. Three-dimensional morphologic analysis of isthmuses in the mesial roots of mandibular molars. *J Endod* 2010; 36(11): 1866-9.
  6. Hsu YY, Kim S. The resected root surface. The issue of canal isthmuses. *Dent Clin North Am* 1997; 41(3): 529-40.
  7. Mannocci F, Peru M, Sherriff M, Cook R, Pitt Ford TR. The isthmuses of the mesial root of mandibular molars: A micro-computed tomographic study. *Int Endod J* 2005; 38(8): 558-63.
  8. Vertucci FJ. Root canal anatomy of the human permanent teeth. *Oral Surg Oral Med Oral Pathol* 1984; 58(5): 589-99.
  9. Lima FJ, Montagner F, Jacinto RC, Ambrosano GM, Gomes BP. An in vitro assessment of type, position and incidence of isthmus in human permanent molars. *J Appl Oral Sci* 2014; 22(4): 274-81.
  10. Mehrvarzfar P, Akhlagi NM, Khodaei F, Shojaee G, Shirazi S. Evaluation of isthmus prevalence, location, and types in mesial roots of mandibular molars in the Iranian Population. *Dent Res J (Isfahan)* 2014; 11(2): 251-6.
  11. Silva EJ, Nejaim Y, Silva AV, Haiter-Neto F, Cohenca N. Evaluation of root canal configuration of mandibular molars in a Brazilian population by using cone-beam computed tomography: An in vivo study. *J Endod* 2013; 39(7): 849-52.
  12. de Pablo OV, Estevez R, Peix Sanchez M, Heilborn C, Cohenca N. Root anatomy and canal configuration of the permanent mandibular first molar: A systematic review. *J Endod* 2010; 36(12): 1919-31.
  13. Pecora JD, Estrela C, Bueno MR, Porto OC, Alencar AH, Sousa-Neto MD, et al. Detection of root canal isthmuses in molars by map-reading dynamic using CBCT images. *Braz Dent J* 2013; 24(6): 569-74.
  14. Naseri M, Haghghi AK, Kharazifard MJ, Khavid A. Prevalence of C-shaped root canals in Iranian population: A systematic review. *J Dent (Tehran)* 2013; 10(2): 186-96.