

Received: 11 Apr. 2015

Accepted: 22 July. 2015

## The use of re-surgery in the treatment of teeth with severe sensitivity in the buccal mucous membrane: A case report with 75 months follow-up

Sara Amanpour MSc, DDS<sup>1</sup>, Maryam Raof MSc, DDS<sup>2</sup>,  
Jahangir Haghani MSc, DDS<sup>3</sup>, Sorena Fardisi DDS<sup>4</sup>,  
Saeedeh Sadr<sup>5</sup>, Farahnaz Nazari DDS<sup>6</sup>

### Case Report

#### Abstract

**BACKGROUND AND AIM:** A periapical endodontic surgery is an alternative treatment when teeth are not responding to conventional treatment and endodontic re-treatment.

**CASE REPORT:** The following case report presents a clinical case of maxillary right and left central incisors with unsatisfying endodontic surgery and severe sensitivity in the buccal mucous membrane. Radiographic examination revealed several fragments of amalgam as root-end filling material, surrounded by a periapical radiolucent area. The chosen treatment plan was to perform endodontic retreatment. Symptoms persisted in spite of the gutta-percha removal and calcium hydroxide intracanal medication. Hence, periradicular re-surgery was performed. However, deep tissue penetrated amalgam particles were difficult to explore and could not be removed completely. The root-end filling was done with mineral trioxide aggregate (MTA), and the lesion was subjected to histologic analyses. The treatment was successful due to the absence of painful symptoms and due to periapical bone repair after 75 months follow-up.

**CONCLUSION:** MTA can be used successfully in the situations with failed previous periradicular surgery with amalgam.

**KEYWORDS:** Amalgam; Apicectomy; Mineral Trioxide Aggregate; Periapical Re-surgery; Root End Filling Material

**Citation:** Amanpour S, Raof M, Haghani J, Fardisi S, Sadr S, Nazari F. **The use of re-surgery in the treatment of teeth with severe sensitivity in the buccal mucous membrane: A case report with 75 months follow-up.** J Oral Health Oral Epidemiol 2016; 5(2): 114-9.

The goal of endodontic treatments is to remove bacteria and their products from root canal system and to seal the apical foramen.<sup>1</sup> Periradicular surgery is a treatment for teeth with previous unsuccessful endodontic therapy, when non-surgical re-treatment is not practical.<sup>1-3</sup> Successful outcomes of periapical surgeries vary from 25.0 to 99.0%.<sup>4</sup> Among the many factors contributing to the success of endodontic surgery, the obturation

material plays a critical role. The ideal root-end filling material should possess properties such as biocompatibility, ability to set in a wet environment, adequate sealing ability, antimicrobial activity, and ability to induce bone repair. Several root-end filling materials are available including amalgam, zinc oxide-eugenol based cement, glass ionomer, mineral trioxide aggregate (MTA), and biodentine.<sup>5,6</sup>

MTA has shown many favorable

1- Assistant Professor, Department of Oral and Maxillofacial Pathology, School of Dentistry, Oral and Dental Diseases Research Center AND Kerman Social Determinants on Oral Health Research Center, Kerman University of Medical Sciences, Kerman, Iran

2- Assistant Professor, Laboratory of Molecular Neuroscience, Neuroscience Research Center, Institute of Neuropharmacology, Kerman University of Medical Sciences, Kerman, Iran

3- Associate Professor, Department of Oral and Maxillofacial Radiology, School of Dentistry, Oral and Dental Diseases Research Center AND Kerman Social Determinants on Oral Health Research Center, Kerman University of Medical Sciences, Kerman, Iran

4- Assistant Professor, Department of Oral and Maxillofacial Surgery, School of Dentistry, Shiraz University of Medical Sciences, Shiraz, Iran

5- Assistant Professor, Persian Gulf Oral and Dental Diseases Research Center, Hormozgan University of Medical Sciences, Bandar Abbas, Iran

6- MSc Student, Department of Endodontics, School of Dentistry, Kerman University of Medical Sciences, Kerman, Iran

Correspondence to: Farahnaz Nazari DDS

Email: dr.fnazari474@gmail.com

properties including a good sealing ability and biocompatibility.<sup>7,8</sup> However, there are several drawbacks to its use such as its difficult handling properties and its long setting time which explains why many clinicians favor amalgam.<sup>3,9</sup> Many clinicians have encountered the problem of incomplete healing of the periapical tissues around some of the teeth that have been treated with amalgam as a root-end filling material. Healing is often retarded by persistent leakage from the root canal.<sup>10</sup>

In a study using alternative root-end filling materials, the success rate with intermediate restorative material was 74% compared with 57% when amalgam was used.<sup>11</sup> In a systematic review, Peterson and Gutmann<sup>12</sup> reported that healing associated with a surgical retreatment was approximately 36%. In the study by Gagliani et al.,<sup>13</sup> root-end re-surgery had a worse radiological outcome compared with primary root surgery. However, most of the literature available on repeated surgical procedures is old and includes data from procedures using materials and techniques that are no longer suggested today. The aim of this study is to report a clinical case of surgical retreatment of teeth with failed previous apicoectomy as an alternative to extraction.

### Case Report

A 35-year-old female in good health (American Society of Anaesthesiologists' Classification 1) admitted to an endodontic office complaining of severe sensitivity in the buccal mucous associated with the maxillary central incisors. The teeth were also tender on percussion. No periodontal pocket was identified, and the pattern of mobility was normal. Radiographic examination revealed a slightly porous root canal obturation. Several fragments of the root-end filling material, surrounded by a periapical radiolucent area were visible (Figure 1).

Based on the patient's reports, the first endodontic treatment had been performed nearly 21 years before her admission. About 2

years later, a sinus tract appeared on the buccal mucosa and apical surgery was performed by a general dental practitioner. After 13 years, strong pain and tenderness were associated with these teeth.

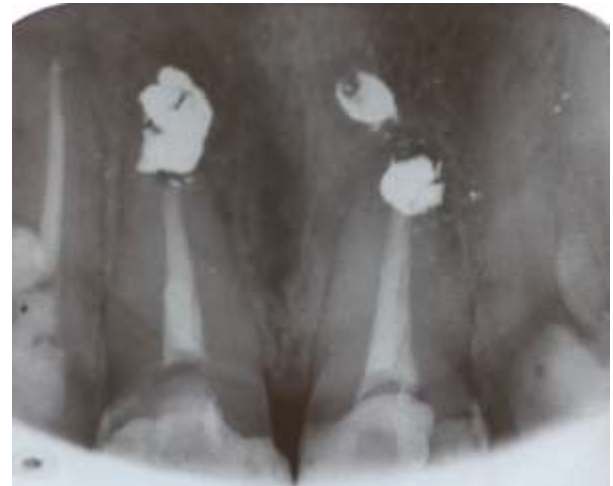

Figure 1. Periapical view before re-surgery

The clinician explained different treatment options such as implants and other dental prosthetics to the patient. However, the patient preferred to try to save her natural teeth. Hence, the recommendation was to perform a second endodontic re-treatment aimed at improving the quality of the biomechanical preparation, followed by complementary antiseptics with calcium hydroxide root canal dressing and obturation. If the periapical lesion persisted, a further periapical surgery would be performed. The patient agreed with the treatment plan and signed an informed consent form.

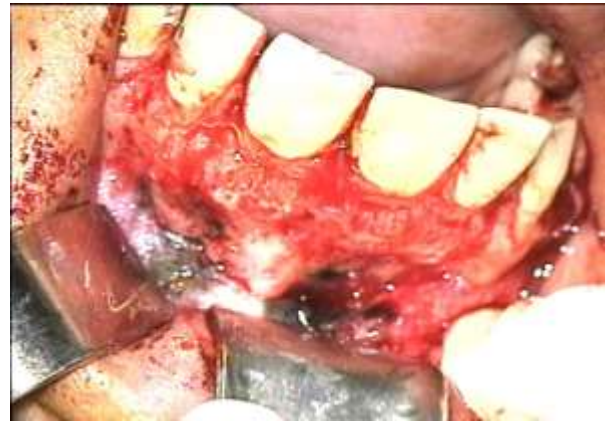During retreatment, Hedstrom files #30 and 35 (Mani, Japan) and chloroform (Kimia Co., Tehran, Iran) were used to remove the gutta-percha until the root-end filling material had been reached. Root canals were irrigated with 5.2% sodium hypochlorite solution. The smear layer was removed by irrigation with a 17.0% ethylenediaminetetraacetic acid (Asia Chimi-Teb, Tehran, Iran) solution, followed by further irrigation with sodium hypochlorite. Calcium hydroxide (Golchai, Iran) and saline solution were put in place for

10 days, during which no healing of the symptoms occurred. The obturation of the root canal was, therefore, performed, and the periapical re-surgery was scheduled for the next dentist's visit. Gutta-percha (Ariadent, Iran) and AH26 sealer (Dentsply, Konstanz, Germany) were used with the lateral condensation technique, and the teeth were restored with composite resin.

After endodontic re-treatment, the patient still suffered from sensitivity in the buccal mucous. She then was referred to Endodontic Department of Kerman Dental School (Iran) for periradicular surgery. Immediately before surgery, the teeth and mucosa were washed with 0.2% chlorhexidine gluconate followed by a local anesthetic injection of 2% lidocaine with 1:100000 epinephrine (Darou Pakhsh Pharmaceutical Co., Iran). After reflecting a triangular flap, it was possible to view the buccal plate destruction of the affected tooth; this allowed easy location of the apex. An osteotomy was performed (Figure 2). Periapical curettage was then conducted to remove granulation tissue as well as amalgam particles. However, deep tissue penetrated particles were difficult to explore and could not be removed completely. Resection of approximately 3 mm of the apical part of the root was performed perpendicular to the root axis with magnification and illumination using an operating microscope,  $\times 4$  (Carl Zeiss, Germany). The retro preparation was performed ultrasonically (NSK Varios 750, Nakanishi, Tochigi, Japan) to a depth of 3-4 mm and the root-end filling was done with White Pro Root MTA (Dentsply Tulsa Dental). A radiograph was taken to check the root-end filling level, its adaptation to the root canal walls, and its density. Finally, the flap was repositioned and the wound was sutured with 5.0 black silk.

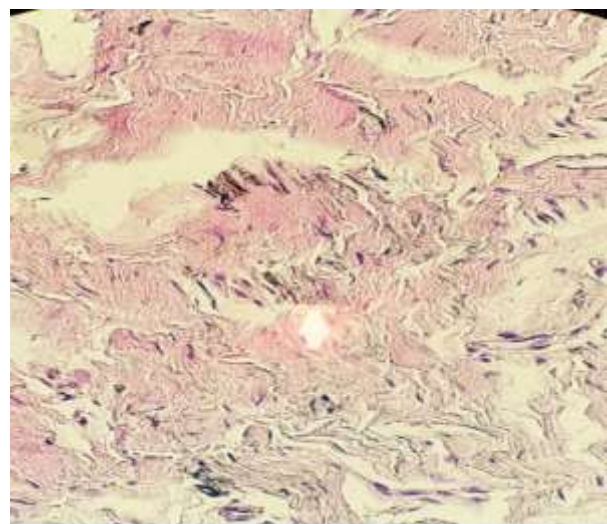
The patient was given post-operative instruction, and antibiotics and analgesics were prescribed. A review appointment was scheduled after 1 week for suture removal and soft tissue healing assessment. The

patient was told to return for the first follow-up visit after 6 months, but she did not, because of distance from the medical center.



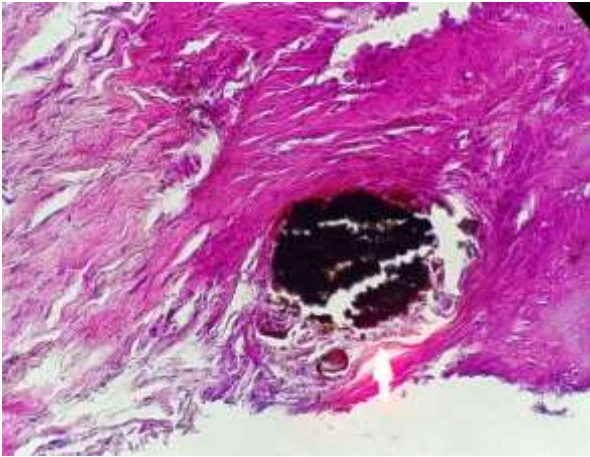
**Figure 2.** Destruction of buccal plate

The specimen with a total size of  $0.5 \text{ cm}^2 \times 0.5 \text{ cm}^2 \times 0.5 \text{ cm}^2$  was sent to the Department of Oral Pathology in formalin solution. Paraffin-embedded blocks of tissue were prepared. Sections were cut, stained with hematoxylin and eosin and were examined with light microscopy. Amalgam was found in two forms in microscopic examination, as numerous fine black granules scattered within the connective tissue associated with a mixture of lymphocytes and plasma cells (Figure 3).

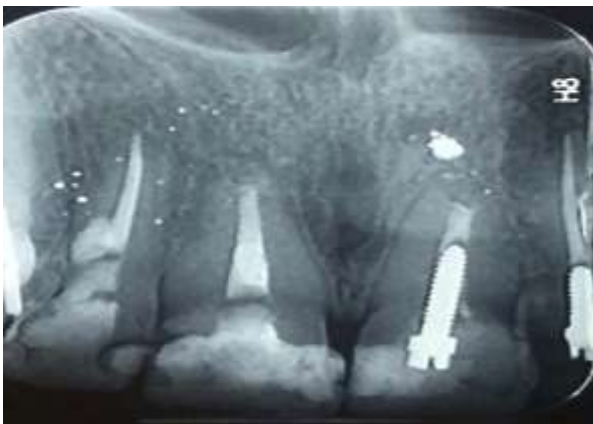

**Figure 3.** Microscopic examination; white arrow shows numerous fine black granules scattered within the connective tissue (hematoxylin-eosin, original magnification  $\times 400$ )

The amalgam particles tend to stain encircling vascular channels (white arrows in Figure 4). Large dark solid fragments of amalgam were also found in a space which was surrounded by dense fibrous connective tissue (Figure 5-white arrows).



**Figure 5.** Microscopic examination; white arrow shows large solid fragments of amalgam in a space surrounded by dense fibrous connective tissue (hematoxylin-eosin, original magnification  $\times 400$ )



**Figure 6.** Periapical radiograph 75 months after treatment

After 75 months from the surgery, the patient returned to Endodontic Department of Kerman Dental School for the treatment of another tooth. A clinical examination of central incisors (including percussion and palpation) showed no pain, no periodontal defect, and no gingival discoloration. The restoration was intact with no signs of compromise in integrity or marginal adaptation. Radiographic examination

showed complete healing of the previous periapical radiolucency (Figure 6). The case was then considered to be completely healed. However, the patient was advised to attend for future follow-ups.

## Discussion

Successful outcomes of periapical surgeries vary from 25 to 99%.<sup>4</sup> This percentage can be affected by several variables such as marginal microleakage and biocompatibility of the material.<sup>4,14,15</sup> However, there is little information available regarding the outcome of surgical operations performed on teeth that had previously undergone periapical surgery.

Amalgam has been and still is to some extent a widely used material.<sup>9</sup> The studies have shown that the outcome of apicectomy with amalgam on the efficacy of the procedure on anterior and premolar teeth is only 50-70%.<sup>16-18</sup> It seems that disadvantages of amalgam, including creep or electrochemical corrosion, should also be considered as reasons for failures. Gaps of up to 150  $\mu\text{m}$  between the root-end cavity margin and amalgam are reported in the literature.<sup>19</sup> Moreover, marginal adaptation and biocompatibility of amalgam have been shown to be considerable negative points.<sup>20</sup> In cases of poor endodontic re-treatment associated with periapical surgery, root-end filling with amalgam may influence the success of endodontic re-treatment.<sup>21</sup>

More recently, MTA has been suggested as having many of the properties of the ideal root-end filling material such as being capable of hermetically seal the apical portion of the root canal and promotes periapical tissue healing due to its low toxicity.<sup>22,23</sup> MTA is able to induce cementum formation and make a biologic seal. It has been suggested that MTA stimulates osteo- and odontogenic cell proliferation via intra- and extra-cellular Ca<sup>2+</sup>- and Erk-dependent pathways and that MTA promotes cell survival via the PI3K/Akt signaling pathway.<sup>22</sup> In addition, the sealing properties of MTA are not affected by moisture during treatment.<sup>24</sup>

In this case, we were not able to remove all amalgam particles, despite our use of illumination and magnification. However, complete healing could be seen. We believe that in the present case, poor endodontic treatment associated with microleakage of the root-end filling material contributed to bacterial colonization of this segment. Orthograde endodontic retreatment along with the application of calcium hydroxide, making a good apical seal via periapical repeated surgery and proper coronal filling and restoration were the most important factors of successful treatment. Molven et al.<sup>25</sup> also found that the efficacy of the apical seal was the most important factor for a successful apicoectomy.

From the endodontic perspective, retreatment should always be considered before surgical treatment since there is evidence of greater healing rate in cases where re-treatment was performed before apical surgery.<sup>26</sup> Hence, we managed the root canal system non-surgically before the surgery.

Long-term follow-up of endodontic treatment is important. Healing tends to occur more quickly with surgical compared with non-surgical retreatment.<sup>27</sup> The literature has implied 4 years is a suitable follow-up period.<sup>28</sup> Therefore, the results after more than 6 years were a good predictor

of the successful treatment. However, a classic study by Frank et al.<sup>29</sup> reported that 42.3% of the cases, that had been documented successful initially, failed after 11-15 years.

### Conclusions

Radiographs taken 75 months after surgery showed complete healing of the previous periapical radiolucency. In clinical examination, both of the maxillary central incisors were asymptomatic and also the soft tissue was healthy. These findings suggest that the use of amalgam as the reverse-filling material of choices should be re-evaluated. MTA can be used successfully in the situations with failed previous periradicular surgery with amalgam. It is important to remember from this case report that high success rate for endodontic treatment can be achieved when both the intraradicular, and the extraradicular causes of failure of endodontic treatment are well managed.

### Conflict of Interests

Authors have no conflict of interest.

### Acknowledgments

The authors wish to thank the Research Committee of Kerman University of Medical Sciences for financial support.

### References

1. Pedroche LO, Barbieri N, Fagundes Tomazinho FS, Ulbrich LM, Leonardi DP. Apicoectomy after conventional endodontic treatment failure: Case report. *RSBO* 2013; 10(2): 182-7.
2. Tsesis I, Rosen E, Schwartz-Arad D, Fuss Z. Retrospective evaluation of surgical endodontic treatment: traditional versus modern technique. *J Endod* 2006; 32(5): 412-6.
3. Johnson BR. Considerations in the selection of a root-end filling material. *Oral Surg Oral Med Oral Pathol Oral Radiol Endod* 1999; 87(4): 398-404.
4. Testori T, Capelli M, Milani S, Weinstein RL. Success and failure in periradicular surgery: a longitudinal retrospective analysis. *Oral Surg Oral Med Oral Pathol Oral Radiol Endod* 1999; 87(4): 493-8.
5. Chong BS, Pitt Ford TR. Root-end filling materials: rationale and tissue response. *Endod Topics* 2005; 11(1): 114-30.
6. Soundappan S, Sundaramurthy JL, Raghu S, Natanasabapathy V. Biodentine versus Mineral Trioxide Aggregate versus Intermediate Restorative Material for Retrograde Root End Filling: An Invitro Study. *J Dent (Tehran)* 2014; 11(2): 143-9.
7. Torabinejad M, Parirokh M. Mineral trioxide aggregate: A comprehensive literature review--part II: leakage and biocompatibility investigations. *J Endod* 2010; 36(2): 190-202.
8. Parirokh M, Torabinejad M. Mineral trioxide aggregate: A comprehensive literature review--Part III: Clinical applications, drawbacks, and mechanism of action. *J Endod* 2010; 36(3): 400-13.
9. Grossman I, Abu el NA, Peled M. Root-end filling materials in apicoectomy-a review. *Refuat Hapeh Vehashinayim*

- (1993) 2003; 20(2): 49-54, 80.
10. Hohenfeldt PR, Aurelio JA, Gerstein H. Electrochemical corrosion in the failure of apical amalgam. Report of two cases. *Oral Surg Oral Med Oral Pathol* 1985; 60(6): 658-60.
  11. Dorn SO, Gartner AH. Retrograde filling materials: a retrospective success-failure study of amalgam, EBA, and IRM. *J Endod* 1990; 16(8): 391-3.
  12. Peterson J, Gutmann JL. The outcome of endodontic resurgery: A systematic review. *Int Endod J* 2001; 34(3): 169-75.
  13. Gagliani MM, Gorni FG, Strohmenger L. Periapical resurgery versus periapical surgery: A 5-year longitudinal comparison. *Int Endod J* 2005; 38(5): 320-7.
  14. Torabinejad M, Pitt Ford TR, McKendry DJ, Abedi HR, Miller DA, Kariyawasam SP. Histologic assessment of mineral trioxide aggregate as a root-end filling in monkeys. *J Endod* 1997; 23(4): 225-8.
  15. Yaltirik M, Ozbas H, Bilgic B, Issever H. Reactions of connective tissue to mineral trioxide aggregate and amalgam. *J Endod* 2004; 30(2): 95-9.
  16. Rud J, Andreasen JO, Jensen JE. A follow-up study of 1,000 cases treated by endodontic surgery. *Int J Oral Surg* 1972; 1(4): 215-28.
  17. Andreasen JO, Pitt Ford TR. A radiographic study of the effect of various retrograde fillings on periapical healing after replantation. *Endod Dent Traumatol* 1994; 10(6): 276-81.
  18. Siqueira JF. Aetiology of root canal treatment failure: Why well-treated teeth can fail. *Int Endod J* 2001; 34(1): 1-10.
  19. Moodnik RM, Levey MH, Besen MA, Borden BG. Retrograde amalgam filling: a scanning electron microscopic study. *J Endod* 1975; 1(1): 28-31.
  20. Schwartz-Arad D, Yarom N, Lustig JP, Kaffe I. A retrospective radiographic study of root-end surgery with amalgam and intermediate restorative material. *Oral Surg Oral Med Oral Pathol Oral Radiol Endod* 2003; 96(4): 472-7.
  21. Soares JA, Nunes E, Silveira FF, Santos SM, Oliveira MT. Endodontic re-treatment associated with the elimination of amalgam root-end filling through sinus tracts: a report of two cases. *Aust Endod J* 2009; 35(2): 59-64.
  22. Kim S, Kratchman S. Modern endodontic surgery concepts and practice: A review. *J Endod* 2006; 32(7): 601-23.
  23. Damas BA, Wheeler MA, Bringas JS, Hoen MM. Cytotoxicity comparison of mineral trioxide aggregates and EndoSequence bioceramic root repair materials. *J Endod* 2011; 37(3): 372-5.
  24. Torabinejad M, Chivian N. Clinical applications of mineral trioxide aggregate. *J Endod* 1999; 25(3): 197-205.
  25. Molven O, Halse A, Grung B. Surgical management of endodontic failures: Indications and treatment results. *Int Dent J* 1991; 41(1): 33-42.
  26. von Arx T, Penarrocha M, Jensen S. Prognostic factors in apical surgery with root-end filling: a meta-analysis. *J Endod* 2010; 36(6): 957-73.
  27. Kvist T, Reit C. Results of endodontic retreatment: a randomized clinical study comparing surgical and nonsurgical procedures. *J Endod* 1999; 25(12): 814-7.
  28. Zuolo ML, Ferreira MO, Gutmann JL. Prognosis in periradicular surgery: A clinical prospective study. *Int Endod J* 2000; 33(2): 91-8.
  29. Frank AL, Glick DH, Patterson SS, Weine FS. Long-term evaluation of surgically placed amalgam fillings. *J Endod* 1992; 18(8): 391-8.