

PDF hosted at the Radboud Repository of the Radboud University Nijmegen

The following full text is a publisher's version.

For additional information about this publication click this link.

<http://hdl.handle.net/2066/108179>

Please be advised that this information was generated on 2017-12-06 and may be subject to change.

Available at www.sciencedirect.com

SciVerse ScienceDirect

journal homepage: www.elsevier.com/locate/IJMYCO

Case Report

Hypersensitivity pneumonitis caused by *Mycobacterium avium* subsp. *hominissuis* in a hot tub, as proven by IS1245 RFLP and rep-PCR typing [☆]

Rianne J.C. van der Zanden ^{a,*}, Cecile Magis-Escurra ^{b,c}, Wiel C.M. de Lange ^d,
Wouter Hoefsloot ^b, Martin J. Boeree ^{b,c}, Jakko van Ingen ^e, Dick van Soolingen ^{a,b,e}

^a National Mycobacteria Reference Laboratory, Laboratories for Infectious Diseases and Perinatal Screening, National Institute for Public Health and the Environment, Bilthoven, The Netherlands

^b Department of Pulmonary Diseases, Radboud University Nijmegen Medical Center, Nijmegen, The Netherlands

^c University Lung Centre Dekkerswald, Radboud University Nijmegen Medical Center, Nijmegen, The Netherlands

^d Beatrixoord, Tuberculosis Center, University Medical Center Groningen, Haren, The Netherlands

^e Department of Clinical Microbiology, Radboud University Nijmegen Medical Center, Nijmegen, The Netherlands

ARTICLE INFO

Article history:

Received 28 July 2012

Accepted 31 July 2012

Available online 24 August 2012

Keywords:

Hot tub lung

Hypersensitivity pneumonitis

M. avium subsp. *hominissuis*

rep-PCR

IS1245 RFLP

ABSTRACT

A symptomatic patient had repeatedly positive cultures of *Mycobacterium avium* subsp. *hominissuis* after exposure to a hot tub contaminated with *M. avium* subsp. *hominissuis*. The pulmonary and tub water isolates were indistinguishable by IS1245 RFLP as well as rep-PCR typing. Discontinued use of the hot tub resulted in culture conversion.

© 2012 Published by Elsevier Ltd. on behalf of Asian-African Society for Mycobacteriology.

Case report

A 65-year-old Dutch Caucasian woman presented at the department of pulmonary diseases in a peripheral hospital with fever, fatigue and dyspnea. There were dense airspace opacities in both lungs visible on chest radiographs after a

2-month-period of recurrent pneumonias of various lobes. The patient had a 30-year history of rheumatoid factor positive rheumatoid arthritis for which she had received for 3 years the tumor necrosis factor α neutralizing agent infliximab. Infliximab suppresses the immune system and predisposes to opportunistic infections, including mycobacterial

[☆] The work was performed at the National Mycobacteria Reference Laboratory, Laboratories for Infectious Diseases and Perinatal Screening, National Institute for Public Health and the Environment, in Bilthoven, The Netherlands.

* Corresponding author. Address: Mycobacteria Department (LIS;pb22), National Institute for Public Health and the Environment (RIVM), P.O. Box 1, 3720 BA Bilthoven, The Netherlands. Tel.: +31 30 2742363; fax: +31 30 2744418.

E-mail address: riannezanden@gmail.com (R.J.C. van der Zanden).

2212-5531/\$ - see front matter © 2012 Published by Elsevier Ltd. on behalf of Asian-African Society for Mycobacteriology.

<http://dx.doi.org/10.1016/j.ijmyco.2012.07.006>

disease [1]. The patient reported no additional risk factors for mycobacterial disease, but she had visited Zimbabwe during the previous year.

In the first month after initial presentation she received the broad-spectrum antibiotics amoxicillin/clavulanic acid and doxycycline because of the recurrent pneumonias. Thereafter infliximab was replaced by methotrexate. This led initially to clinical improvement, however, later the patient experienced relapses of fever up to 38.0 °C, dry cough, malaise and fatigue. After 2 months, a chest radiograph showed infiltrative abnormalities of the right middle lobe. A computed tomography (CT)-scan and a high-resolution-CT-scan (HCRT) revealed some atypical fibrosis, especially in the lower zones of the lungs; also visible on the CT-scan was a small, localized dense nodule in the anterobasal segment of the right lower lobe (Figs. 1A and 1B). A sputum culture grew *Mycobacterium avium*, as identified by Inno-LiPA Mycobacteria v2 assay (Innogenetics, Ghent, Belgium).

Four months after initial presentation, the patient was admitted to the rheumatology outpatient clinic because of right middle lobe (RML) pneumonia. She presented with an acute, continued pain in the right hemithorax, a stinging pain under her right breast, and fever up to 39.8 °C. Her symptoms also included cough without sputum, weight loss and night sweats. Auscultation of the chest revealed bilateral basal coarse crepitations and no rhonchi. A chest radiograph revealed dense airspace opacities in the RML. Culture of a bronchoalveolar lavage (BAL) also grew *M. avium*. Empirical therapy was started with thrice daily amoxicillin/clavulanic acid 1200 mg intravenous and ciproxin 400 mg intravenous twice daily. Thereafter, the patient improved clinically. Follow-up chest radiographs showed improvement, but incomplete resolution of the lesions.

Six months after initial presentation, the symptoms – fever and fatigue – continued. A renewed interview revealed that 4 months before initial presentation, the patient had an indoor hot tub installed. A water sample of the hot tub was collected for culture. Ziehl-Neelsen stain of a sediment was reported [2] and corresponding cultures grew *M. avium*. The

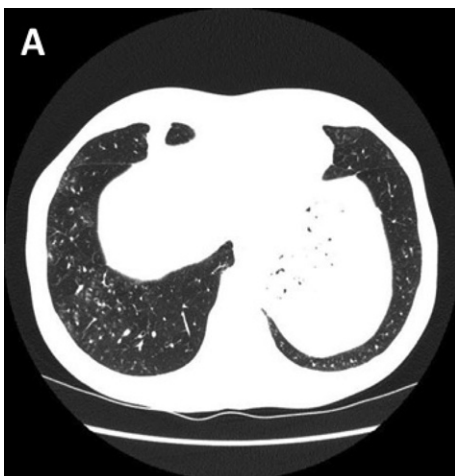

Fig. 1A – CT-scan; basal section showing bronchiolitis and a diffuse mild micronodular pattern.

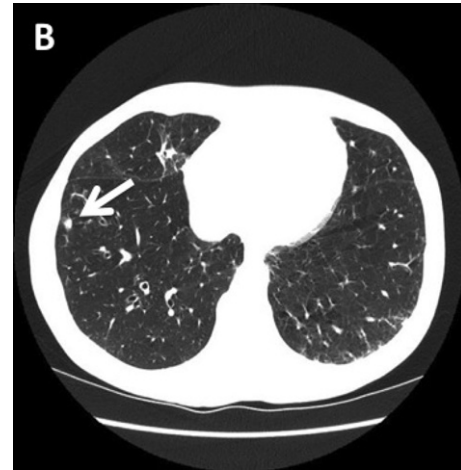

Fig. 1B – CT-scan; the arrow shows a nodular lesion in the right lower lobe, with mild bronchiectasis; “tree-in-bud” aspect of bronchiolitis in the left lower lobe.

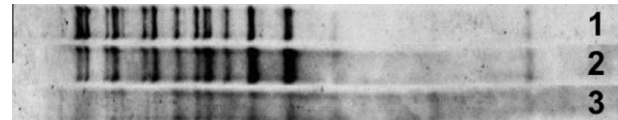


Fig. 2A – Identical IS1245 RFLP patterns of *M. avium* subsp. *hominissuis* isolates from (1) sputum cultured 2 months after initial presentation; (2) BAL cultured 5 months after initial presentation; and (3) hot tub water cultured 7 months after initial presentation.

patient was advised to discontinue hot tub use and this led after 4 and 9 months to negative cultures of *M. avium*.

Genotyping was performed on all three *M. avium* isolates using IS1245 restriction fragment length polymorphism (RFLP) typing, as previously described [3]. IS1245 RFLP revealed that all three isolates belong to a single *M. avium* subsp. *hominissuis* strain (Fig. 2A). The secondary genotyping method applied to the three isolates was rep-PCR, a commercially available system (DiversiLab®, bioMérieux). For *M. avium* subsp. *hominissuis*, the discriminative power of rep-PCR was previously found to equal or exceed that of RFLP typing [4]. Rep-PCR confirmed that all three isolates belong to a single strain (Fig. 2B).

Kahana et al. [5] also described a case of *M. avium* infection in an immunocompetent patient in relation to *M. avium* cultured from a hot tub. Both strains revealed a high degree of similarity in multilocus enzyme electrophoresis and IS1245 RFLP analysis, although the IS1245 RFLP of the hot tub isolate revealed three additional bands compared with the isolate from an open-lung biopsy specimen.

In the current study, on the basis of two typing methods, indistinguishable *M. avium* subsp. *hominissuis* isolates from the patient and the hot tub were found, and this contrasts the study of Kahana et al. The patient also directly improved after discontinuing the hot tub use. Antibacterial therapy was provided, but not focused on treatment of an *M. avium* infection. The diagnosis of hypersensitivity pneumonitis was




Fig. 2B – Dendrogram and similarity matrix for three *M. avium* subsp. *hominissuis* isolates analyzed using the DiversiLab® system showing three identical patterns. Reference strains *M. avium* subsp. *avium* R19 and *M. avium* subsp. *hominissuis* IWGMT49 were used as controls.

initially based on the clinical and radiological presentation, but because typing of the *M. avium* cultures from the patient and the hot tub yielded identical profiles and the patient directly improved when she discontinued the use of the hot tub, it is conceivable these bacteria were indeed the cause of her infection.

The ATS/IDSA guidelines for nontuberculous mycobacterial disease [6] state that “[without histological evidence], a diagnosis of *M. avium*-associated hypersensitivity-like lung disease can be established by the following: subacute onset of respiratory symptoms; hot-tub exposure; characteristic radiographic findings; and *M. avium* isolates in sputum, BAL, tissue, and hot-tub water.” Our patient matches this case definition.

The treatment of a case of hypersensitivity pneumonitis is the subject of debate. The disease results either from inflammation, infection, or both; as a result, treatment can consist of steroids or antimycobacterial treatment. For the latter, the ATS/IDSA statement [6] recommends rifampicin, ethambutol and a macrolide antibiotic, for *M. avium*. Neither antimycobacterial treatment, nor steroids were given.

In summary, a case of *M. avium* subsp. *hominissuis* hypersensitivity pneumonitis is described in a patient with rheumatoid arthritis treated with infliximab, related to hot tub exposure. Genotyping revealed that the isolates from sputum, lung lavage and hot tub water belonged to a single strain of *M. avium* subsp. *hominissuis*. Discontinuation of the use of the hot tub led to significant improvement.

REFERENCES

- [1] J. van Ingen, M.J. Boeree, P.N. Dekhuijzen, D. van Soolingen, Mycobacterial disease in patients with rheumatic disease, *Nat. Clin. Pract. Rheumatol.* 4 (2008) 649–656.
- [2] N. Selvakumar, F. Rahman, S. Rajasekaran, P.R. Narayanan, T.R. Frieden, Inefficiency of 0.3% carbol fuchsin in Ziehl-Neelsen staining for detecting acid-fast bacilli, *J. Clin. Microbiol.* 40 (2002) 3041–3043.
- [3] D. van Soolingen, J. Bauer, V. Ritacco, S.C. Leao, I. Pavlik, V. Vincent, et al, IS1245 restriction fragment length polymorphism typing of *Mycobacterium avium* isolates: Proposal for standardization, *J. Clin. Microbiol.* 36 (1998) 3051–3054.
- [4] G.A. Cangelosi, R.J. Freeman, K.N. Lewis, D. Livingston-Rosanoff, K.S. Shah, S.J. Milan, et al, Evaluation of a high-throughput repetitive-sequence-based PCR system for DNA fingerprinting of *Mycobacterium tuberculosis* and *Mycobacterium avium* complex strains, *J. Clin. Microbiol.* 42 (2004) 2685–2693.
- [5] L.M. Kahana, J.M. Kay, M.A. Yakrus, S. Wasserman, *Mycobacterium avium* complex infection in an immunocompetent young adult related to hot tub exposure, *Chest* 111 (1997) 242–245.
- [6] D.E. Griffith, T. Aksamit, B.A. Brown-Elliott, A. Catanzaro, C. Daley, F. Gordin, et al, ATS Mycobacterial Diseases Subcommittee, American Thoracic Society, and Infectious Disease Society of America. 2007. An official ATS/IDSA statement: Diagnosis, treatment, and prevention of nontuberculous mycobacterial diseases, *Am. J. Respir. Crit. Care Med.* 175 (2007) 367–416.