

## PDF hosted at the Radboud Repository of the Radboud University Nijmegen

The following full text is a publisher's version.

For additional information about this publication click this link.

<http://hdl.handle.net/2066/107729>

Please be advised that this information was generated on 2017-12-06 and may be subject to change.

## Elastoderma: An Uncommon Cause of Acquired Hyperextensible Skin

Anne C. de Waal<sup>1</sup>, Willeke A. M. Blokk<sup>2</sup>, Marieke M. B. Seyger<sup>1</sup> and Michelle M. van Rossum<sup>1</sup>

Departments of <sup>1</sup>Dermatology and <sup>2</sup>Pathology, Radboud University Nijmegen Medical Centre, Post 374, PO Box 9101, NL-6500 HB Nijmegen, The Netherlands. E-mail: a.dewaal@ebh.umcn.nl

Accepted September 12, 2011.

Elastoderma is an uncommon acquired skin disorder, which is characterized by increased laxity and a loss of recoil of affected skin. Unlike other elastolytic disorders that produce increased skin laxity, elastoderma is accompanied by an accumulation of elastin without calcification. We describe here a case of elastoderma, which, to our knowledge, is the fourth case described in the literature.

### CASE REPORT

A 25-year-old man presented to the outpatient department with increased laxity and hyperesthesia of the skin on both elbows and knees since puberty. The patient had a history of dyshidrotic eczema and erysipelas of the skin overlying the right knee, though at the time of presentation no other diseases of the skin existed. There was no history of severe weight loss. The patient had no history of cardiovascular, respiratory, gastrointestinal, urinary or ophthalmological complaints, and used no medication. The patient's family history showed no similar skin changes.

Physical examination revealed increased skin laxity on both elbows and knees. The surrounding skin was unaffected. Stretching the affected skin produced delayed recoil (Fig. 1A).

Examination of the joints revealed a Beighton hypermobility score of 0/9, thus excluding general Ehler-Danlos syndrome. Further physical examination showed no abnormalities. Specifically, the peripheral pulses were normal, and no hypertension or other evidence of cardiovascular disease existed.

A differential diagnosis was made, which included localized cutis laxa, anetoderma, granulomatous slack skin disease, localized Ehlers-Danlos syndrome, and elastoderma.

A 4-mm biopsy specimen was taken from the skin overlying the right elbow. Histopathological examination with routine haematoxylin-eosin staining and elastica van Gieson staining revealed an increase in elastic tissue fibres in the reticular dermis with clumping and fragmentation (Fig. 1B and C). The von Kossa staining showed no evidence of calcification. A histological diagnosis of elastoderma was suggested. To confirm this, two additional 4-mm punch biopsies were performed: one from unaffected skin on the left upper arm and one from affected skin on the left elbow. Histopathology of the unaffected skin showed no abnormalities. Transmission electron microscopy of the affected skin showed irregular elastic tissue fibres, with electronic dense extensions, and fibroblasts with prominent and widened rough endoplasmic reticulum (Fig. 1D). These findings confirmed the diagnosis of elastoderma.

The patient requested surgical removal of the excess skin, which was performed by a plastic surgeon.

### DISCUSSION

Elastoderma is a rare condition first described by Kornberg et al. (1) in a 33-year-old white woman with a 2-year history of progressive skin laxity overlying her right elbow (Table SI; available from: <http://www.medicaljournals.se/acta/content/?doi=10.2340/00015555-5-1272>). In 1995, Yen et al. (2) reported a similar case in

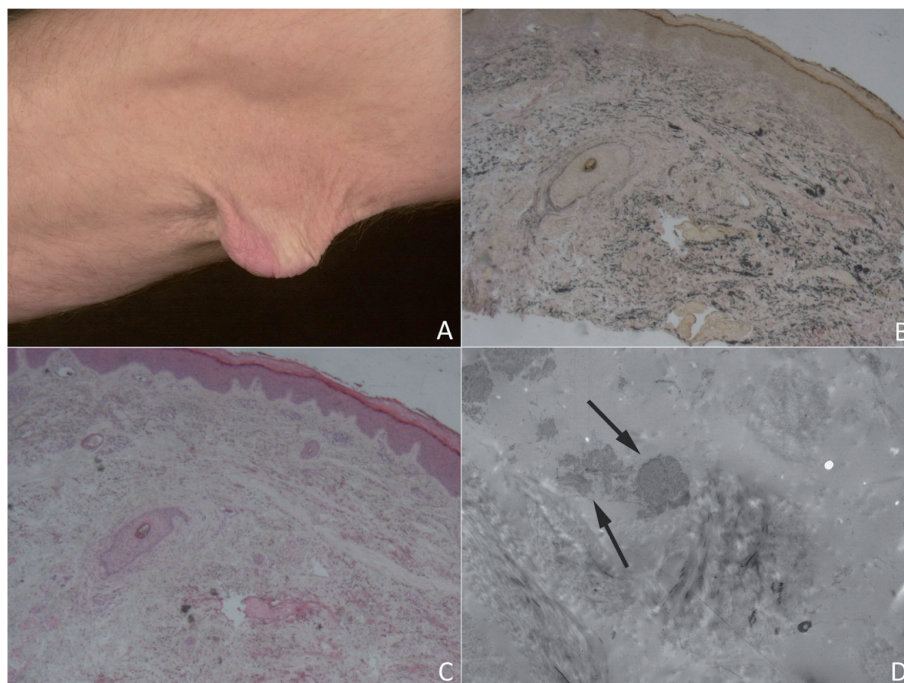


Fig. 1. (A) Clinical picture showing delayed recoil after stretching the skin overlying the left elbow. (B) Elastica van Gieson staining, and (C) haematoxylin-eosin staining revealing an increase in elastic tissue fibres in the reticular dermis with clumping and fragmentation. (D) Transmission electron microscopy revealing irregular elastic tissue fibres (arrows), with electronic dense extensions, and fibroblasts.

a 27-year-old white man with lax, extensible, wrinkled skin with areas of protrusion and ulceration localized to the anterior and posterior aspect of the neck. Vieira et al. (3) described a third case of a 16-year-old white man in 2005 with progressive laxity, extensibility and wrinkling of the skin localized to the anterior aspect of the neck after a folliculitis episode. In all three cases stretching of the affected skin produced delayed recoil.

Kornberg et al. (1) found an accumulation of pleomorphic elastic fibres in the dermis, further characterized by grape-like globular structures and a higher desmosine content, as determined by transmission electron microscopy and radioimmunoassay. Also, fibroblast-like cells with prominent rough endoplasmic reticulum were observed in transmission electron microscopy, suggesting increased elastin synthesis. Yen et al. (2) and Vieira et al. (3) both reported similar findings (Table SI).

Scanning electron microscopy was not performed in the presented case, but the comparable clinical features and identical histopathological findings under light microscopy and transmission electron microscopy, to those described by other authors in elastoderma enabled us to establish this diagnosis.

When elastoderma is considered, a distinction must be made from other disorders accompanied by inelasticity or laxity of the skin, such as acquired cutis laxa, mid-dermal elastolysis or post-inflammatory elastolysis, anetoderma, granulomatous slack skin, and cutis laxa. However, these conditions are all characterized by a decrease in elastic tissue on histopathological examination, rather than an increase, as is seen in elastoderma (4).

A large number of acquired disorders in which elastin accumulation in the skin is accompanied by clinical features have been described. They include late-onset focal dermal elastosis, linear focal elastosis, elastofibroma, elastosis perforans serpiginosa, acquired pseudoxanthoma elasticum (PXE), elastoma, solar elastotic dermatoses and elastoderma (5).

Late-onset focal dermal elastosis and linear focal elastosis both have a clinical presentation that is different from elastoderma, with presence of asymptomatic, yellow papules or yellow to red linear plaques, respectively. Elastofibroma and elastoma also have a different clinical presentation, with presence of firm well-demarcated papules or nodules. Acquired PXE and elastosis perforans serpiginosa both show calcified elastic tissue, while calcification is absent in elastoderma. In solar elastosis, dense aggregates of elastic tissue are present in the papillary and mid-reticular dermis histopathologically, and clinically a diffuse thickening of the skin, predominantly in sun-exposed areas, can be seen (5).

Ehlers-Danlos syndrome can mimic the clinical aspects of elastoderma, but can easily be distinguished from it by histological examination, and by revealing

changes in the biochemical structure and synthesis of collagen fibres, resulting in a relative increase in normal elastin fibres.

Elastic tissue physiology is a complex balance between synthesis and degradation of elastic fibres; processes that are influenced by enzymes such as lysyl oxidase, serine-type elastases and metalloproteinases. The role of these enzymes in the pathogenesis of elastotic or elastolytic disorders is not completely understood. As the enzyme lysyl oxidase is copper-dependent, copper deficiency may cause changes in skin elasticity. It has been reported that usage of the copper-chelating agent D-penicillamine in the treatment of Wilson's disease is associated with several acquired elastic tissue disorders (5).

Kornberg et al. (1) proposed that the accumulation of elastic fibres in elastoderma is caused by an increased synthesis rather than a decreased degradation. The presence of fibroblasts with prominent rough endoplasmic reticulum supported this theory. Inflammatory processes may be responsible for this process. Our patient had a history of erysipelas of the left leg and dyshidrotic eczema, and the patient presented by Vieira et al. (3) had a folliculitis episode preceding the elastoderma, which supported this theory. However, in post-inflammatory cutis laxa a degradation of elastic fibres occurs, and elastic fibres are absent in the upper and middle dermis. This suggests that inflammatory processes can cause both an increase and a decrease in elastic tissue within the skin.

Furthermore, the localization of the disorder on areas of the skin that often stretch and move suggests that this could influence the pathogenesis. The relatively young age of all subjects, however, suggests that a certain predisposition is needed to develop elastoderma.

No standard therapy is available for elastoderma and similar disorders. Our patient requested surgical removal of the affected skin. The hyperlaxity of the skin eventually returned, although to a lesser extent than before surgery.

## REFERENCES

1. Kornberg RL, Hendler SS, Oikarinen AI, Matsuoka LY, Uitto J. Elastoderma – disease of elastin accumulation within the skin. *N Engl J Med* 1985; 312: 771–774.
2. Yen A, Wen J, Grau M, Sanchez RL, Smith EB. Elastoderma. *J Am Acad Dermatol* 1995; 33: 389–392.
3. Vieira AC, Vieira WT, Michalany N, Enokihara M, Freymuller E, Cestari SC. Elastoderma of the neck in a teenage boy. *J Am Acad Dermatol* 2005; 53: S147–149.
4. Lewis KG, Bercovitch L, Dill SW, Robinson-Bostom L. Acquired disorders of elastic tissue: Part II. Decreased elastic tissue. *J Am Acad Dermatol* 2004; 51:165–185.
5. Lewis KG, Bercovitch L, Dill SW, Robinson-Bostom L. Acquired disorders of elastic tissue: Part I. Increased elastic tissue and solar elastotic syndromes. *J Am Acad Dermatol* 2004; 51: 1–21.