



Citation for published version:

Grammatopoulos, G, Alvand, A, Monk, AP, Mellon, SJ, Pandit, H, Rees, J, Gill, H & Murray, D 2016, 'Surgeons' accuracy in achieving their desired acetabular component orientation', *Journal of Bone and Joint Surgery, American Volume*, vol. 98, no. 17, e72. <https://doi.org/10.2106/JBJS.15.01080>

DOI:

[10.2106/JBJS.15.01080](https://doi.org/10.2106/JBJS.15.01080)

Publication date:

2016

Document Version

Publisher's PDF, also known as Version of record

[Link to publication](#)

University of Bath

General rights

Copyright and moral rights for the publications made accessible in the public portal are retained by the authors and/or other copyright owners and it is a condition of accessing publications that users recognise and abide by the legal requirements associated with these rights.

Take down policy

If you believe that this document breaches copyright please contact us providing details, and we will remove access to the work immediately and investigate your claim.

TOPICS IN TRAINING

Surgeons' Accuracy in Achieving Their Desired Acetabular Component Orientation

George Grammatopoulos, FRCS(T&O), DPhil, Abtin Alvand, FRCS(T&O), DPhil, A. Paul Monk, FRCS(T&O), DPhil, Stephen Mellon, BSc(Hons), PhD, Hemant Pandit, FRCS(T&O), DPhil, Jonathan Rees, FRCS(T&O), MD, Harinderjit S. Gill, BEng, DPhil, and David W. Murray, FRCS

Investigation performed at the Nuffield Orthopaedic Centre, Oxford, United Kingdom

Background: Wide variability in cup orientation has been reported. The aims of this study were to determine how accurate surgeons are at orientating the acetabular component and whether factors such as visual cues and the side of operating table improved accuracy.

Methods: A pelvic model was positioned in neutral alignment on an operating table and was prepared as in a posterior approach. Twenty-one surgeons (9 trainers and 12 trainees) were tasked with positioning an acetabular component in a series of target orientations. The orientation of the component was measured using stereophotogrammetry, and the difference between the achieved orientation and the target orientation was calculated. Tasks included stating the surgeon's preferred orientation and thereafter placing the cup in that orientation, reproducing visual cues (transverse acetabular ligament and alignment guide), altering orientation by 10°, and estimating orientation while on the assistant's side.

Results: The preferred inclination was 42° and the preferred anteversion was 21°. On average, surgeons decreased the inclination by 4° and increased the anteversion by 11° when tasked with replicating their desired orientation. The variability (defined as 2 standard deviations) in achieving a target orientation was 14°. The use of visual cues, such as the transverse acetabular ligament or the alignment guide, significantly improved accuracy to 1° for anteversion ($p < 0.001$) and -3° for inclination ($p = 0.003$). In addition, the use of an alignment guide reduced the variability by one-third. Trainees and trainers had similar accuracy and variability. There was greater variability in assessing cup inclination when standing on the assistant's side compared with the surgeon's side of the table, which has implications for training.

Conclusions: Surgeons overestimate operative inclination and underestimate anteversion, which is of benefit, as this, on average, helps to achieve the desired radiographic cup orientation. Although the use of visual cues helps, conventional techniques result in a large variability in acetabular component orientation. New and better guides and methods for training need to be developed.

Peer review: This article was reviewed by the Editor-in-Chief and one Deputy Editor, and it underwent blinded review by two or more outside experts. It was also reviewed by an expert in methodology and statistics. The Deputy Editor reviewed each revision of the article, and it underwent a final review by the Editor-in-Chief prior to publication. Final corrections and clarifications occurred during one or more exchanges between the author(s) and copyeditors.

Disclosure: One author (D.W.M.) received a grant from Stryker for this study; funds were used to pay for supplies. On the **Disclosure of Potential Conflicts of Interest** forms, which are provided with the online version of the article, one or more of the authors checked "yes" to indicate that the author had a relevant financial relationship in the biomedical arena outside the submitted work and "yes" to indicate that the author had other relationships or activities that could be perceived to influence, or have the potential to influence, what was written in this work.

Acetabular component (cup) orientation is an important determinant of outcome following hip arthroplasty. It can influence range of movement¹, dislocation², wear³, functional outcome⁴, and implant survival⁵. Although surgeons aim to achieve optimal cup orientation, many studies demonstrate their inability to consistently achieve this. Evidence suggests that there is $\pm 15^\circ$ of variability in cup orientations, even by experienced surgeons^{6,7}. It is generally thought that $\pm 10^\circ$ is acceptable⁸. More recent evidence suggests that to decrease the dislocation rate, $\pm 15^\circ$ is required, whereas to optimize clinical outcome, a zone as small as $\pm 5^\circ$ may be necessary⁴.

Factors that may contribute to this large variability include patient anatomy, positioning, and movement during the surgical procedure⁹. An important factor is the surgeon's ability to correctly orient the cup at implantation⁷. Although some surgeons aim for a given cup orientation, others utilize anatomical cues, such as the transverse acetabular ligament, aiming to reproduce native acetabular version¹⁰⁻¹².

The ability of surgeons to estimate uniplanar angles has been tested in spinal and deformity surgical procedures, with reported errors of around 5° and a variability of 10° ^{13,14}. However, cup orientation angles are complex, three-dimensional angles that are measured in different ways depending on whether the angles are assessed operatively, radiographically, or anatomically¹⁵. The accuracy with which surgeons can achieve specific cup inclination and anteversion angles and the accuracy to which surgeons can assess these angles have not previously been studied, to our knowledge.

The study's primary aim was to determine the accuracy with which surgeons can achieve cup orientation angles. The secondary aims were to investigate whether anatomical and visual cues influence the accuracy, to evaluate whether trainees or trainers are more accurate, and to determine whether standing on the assistant's side of the table affected the ability to estimate cup orientation.

Materials and Methods

Setting and Subjects

This in vitro study was undertaken in an operating suite of a university teaching hospital. Institutional review board approval was obtained, and all participants gave informed consent. The participants ($n = 21$) included arthroplasty attending surgeons and orthopaedic trainees or residents. Consultants had been appointed for at least 5 years and had performed between 800 and 6,000 hip arthroplasties to date, with a current annual rate of at least 30 cases. Post-fellowship surgeons had performed over 150 arthroplasties. To be eligible for inclusion, each trainee had to have completed at least an arthroplasty placement and to have performed (as the primary surgeon) at least 20 hip arthroplasties; evidence suggests that the learning curve for cup orientation stabilizes after 20 procedures^{16,17}. Consultants ($n = 7$) and post-fellowship participants ($n = 2$) were considered as trainers, but residents were considered as trainees ($n = 12$).

Measurement Technique

Measurements of cup orientation were made using a validated stereophotogrammetry protocol⁷ with an accuracy of 1° (see Appendix). Stereophotogrammetry allows the spatial measurement of three-dimensional objects from a stereopair set of images¹⁸⁻²⁰. Common points are identified on each image, and if the location of each camera relative to the image plane is known, the three-dimensional coordinates and hence location can be determined. A custom

application, Fotop, written in MATLAB (R2011; The MathWorks) was developed to perform the measurements.

The object of interest was the cup introducer, and its three-dimensional location was captured. The resulting measurements allowed determination of cup orientation. A stereopair of images were captured following each of the tasks, with the introducer still attached to measure the three-dimensional location of the cup introducer. Knowledge of the three-dimensional location of the cup introducer relative to the operating table enabled calculation of the operative cup inclination and anteversion¹⁵.

Benchmark Hip Model

A SAWBONES hemipelvis model of the Encapsulated Hip with Proximal Femur (ERP 1174) was used. The model has a hemipelvis articulating with the proximal part of a femur and includes the articular capsule, acetabular labrum, and simulated gluteus maximus and medius muscles. The acetabular size of the model used was 48 mm. The model was prepared with a posterior approach to the hip as this is the most commonly performed approach in our institution. The approach was performed by two of the coauthors; the distal insertion of the gluteus maximus was released to expose the capsule (there are no external rotators in the model), and a T-capsulotomy was performed. The hip was then dislocated and the femoral neck was cut as per standard practice. The exposure allowed 360° visualization of the acetabulum without any soft-tissue impingement during the tasks. Furthermore, it allowed visualization of the whole osseous rim and the transverse acetabular ligament, which was represented by a different colored tape.

Cup Orientation Tasks

A standard operating table (Schaerer) was used and was placed in the center of the laminar flow enclosure of the operating suite. The hemipelvic model was secured to the operating table in a neutral position with all three planes of the

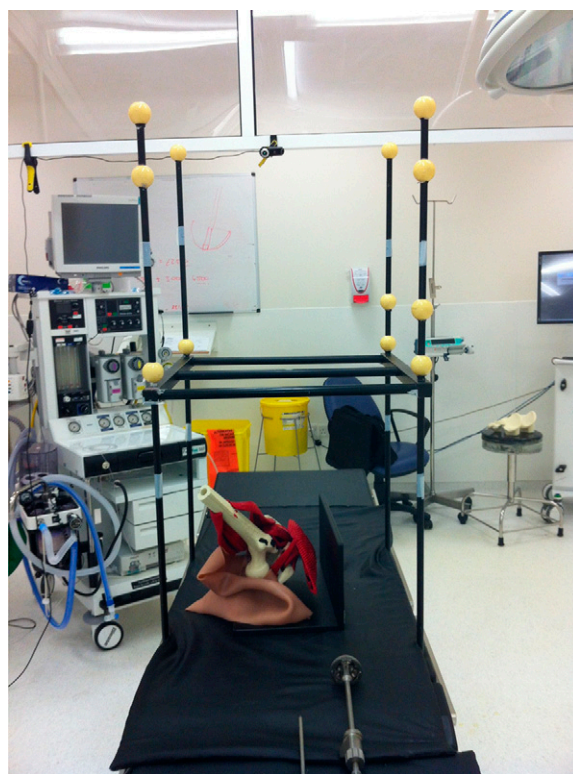

Fig. 1

A photograph showing the setup including the model, calibration object, and operating room enclosure.

TABLE I Orientation Measurements for Tasks 1 and 5

	Measurements*			
	Intended or Estimated	Measured or Operative	Difference†	Radiographic
Task 1 (lead‡)				
Inclination	42 ± 3 (40 to 50)	38 ± 6 (29 to 52)	-4 ± 4 (-11 to 7)	43 ± 7 (33 to 62)
Anteversión	21 ± 5 (15 to 30)	33 ± 7 (17 to 47)	11 ± 5 (2 to 20)	23 ± 4 (14 to 28)
Task 5 (assistant‡)				
Inclination	43 ± 9 (33 to 70)	37 ± 6 (24 to 50)	-6 ± 7 (-20 to 6)	41 ± 7 (25 to 54)
Anteversión	22 ± 7 (10 to 40)	30 ± 10 (12 to 46)	8 ± 6 (-2 to 19)	21 ± 6 (8 to 30)

*The values are given as the mean and the standard deviation, with the range in parentheses, in degrees. †These were the differences in orientation measurement. ‡Lead refers to the lead's side of the table and assistant refers to the assistant's side of the table.

model positioned orthogonal to the operating table and suite (Fig. 1). The anterior superior iliac spine and the pubic symphysis were equidistant from the edge of the operating table; therefore, the anterior pelvic plane relative to the operating table was 0°. The model was then draped and the table was set at the desired height for each subject. The operating space was calibrated and subjects were asked to perform several tasks. All tasks involved placing a 48-mm Trilogy cup (Zimmer), mounted on its introducer, in the requested operative orientation within the model's unreamed acetabulum. Prior to the tasks, the subjects were informed of the hemipelvis' neutral position relative to the table and operating room enclosure and identified all anatomical features required for acetabular preparation and cup implantation. Thereafter, they stood where the operating surgeon stands, an assistant provided good exposure of the field, and they were provided with the cup on its introducer. During the tasks, subjects were photographed when they were satisfied that they had achieved the desired

cup orientation for that particular task. The stereopair of images obtained was used to capture the cup's introducer, enabling calculation of the operative cup orientation (Fig. 2).

Five tasks were performed: four tested subjects as the primary surgeon and one tested them as the assistant (standing on the opposite side of table, that is, the anterior surface of the hemipelvis). In between successive tasks, subjects were asked to remove the cup from within the hemipelvis. The tasks were the following.

Task 1: Preferred Compared with Measured Cup Orientation

The subject states what his or her preferred cup inclination and anteversion are; the subject then positions the cup in this orientation and a stereopair of photographs is captured. Thereafter, the intended, preferred orientation was compared with the measured (actual) orientation.

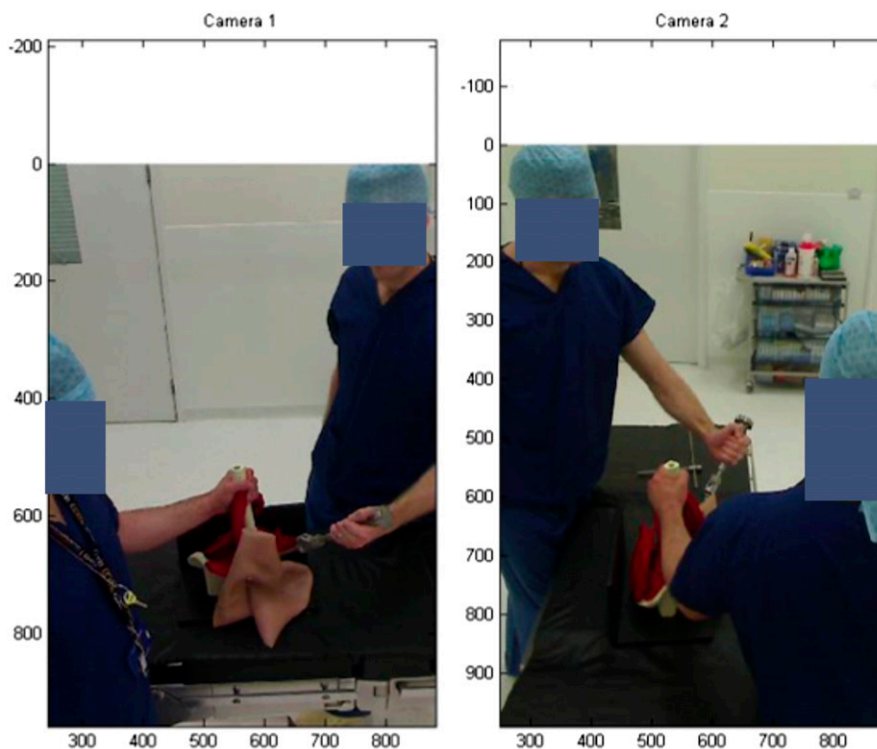


Fig. 2

Stereopair photographs of a trainee surgeon, simulating the component at the desired cup orientation.

TABLE II Orientation Measurements for Tasks 2 to 4

Measurement	Intended or Estimated*	Measured or Operative†	Difference†
Task 2			
Anteversion	36	34 ± 7 (17 to 45)	0 ± 7 (-17 to 11)
Task 3a			
Inclination	40	35 ± 6 (18 to 44)	-5 ± 6 (-22 to 4)
Anteversion	15	27 ± 7 (12 to 36)	12 ± 7 (-4 to 21)
Task 3b			
Inclination	40	35 ± 5 (24 to 43)	-5 ± 5 (-16 to 3)
Anteversion	25	36 ± 9 (16 to 53)	11 ± 9 (-9 to 28)
Task 3c			
Inclination	50	43 ± 5 (33 to 51)	-7 ± 5 (-17 to 1)
Anteversion	25	36 ± 8 (21 to 53)	11 ± 8 (-4 to 28)
Task 4			
Inclination	45	42 ± 5 (24 to 49)	-3 ± 5 (-21 to 4)
Anteversion	20	23 ± 5 (13 to 35)	3 ± 5 (-7 to 15)

*The values are given as the mean in degrees. †The values are given as the mean and the standard deviation, with the range in parentheses, in degrees.

Task 2: Effect of Anatomical Cues on Actual Compared with Intended Inclination

This task orients the cup parallel to the model's transverse acetabular ligament with an inclination of the subject's preference.

Task 3: Ability to Achieve a Given Orientation and Alter It by Small Amounts

This task orients the cup (freehand) at an estimated angle of 40° inclination and 15° anteversion (Task 3a) and then increases the anteversion by 10° to achieve an orientation of 40° inclination and 25° anteversion (Task 3b) and then also increases the inclination by 10° to achieve an orientation of 50° inclination and 25° anteversion (Task 3c).

Task 4: Instrumented Cup Placement (Replicating Alignment Guide)

This task uses the alignment device with the impactor to achieve the predetermined orientation of the device relative to the pelvic plane and axis of the table. The alignment guide is an X-bar type with a predetermined angle of 45° inclination and 20° anteversion^{21,22}.

Task 5: Effect of Operator Compared with Assistant Perspective

In this task (assistant task), the operator positions himself or herself on the assistant's side and estimates the cup angle when held in position by another surgeon.

Analyses

Each task was analyzed separately. Variability was defined as 2 standard deviations. The measurements obtained were the operative inclination and anteversion¹⁵. These measurements were converted to radiographic measurements using the Murray equations¹⁵. The optimum cup orientation zone was defined as having a radiographic angle of 45° inclination and 15° anteversion and a size of ±10°.

The differences between the measured operative values and intended (as per task) orientation values were defined as Δ orientation and were calculated as: Δ inclination = Measured operative inclination - Intended inclination and Δ anteversion = Measured operative anteversion - Intended anteversion.

The differences between calculated radiographic values and intended values were defined as Δ Radiographic (Δ R) and were calculated as: Δ Rinclination = Calculated radiographic inclination - Intended inclination and Δ Ranteversion = Calculated radiographic anteversion - Intended anteversion.

Subanalyses

To identify whether reproducing visual cues aided surgical accuracy, Δ inclination of Task 4 (reproducing alignment guide inclination) was compared with all other tasks and Δ anteversion of Tasks 2 and 4 (use of transverse acetabular ligament and alignment guide) was compared with all other tasks. To assess whether surgical experience affected accuracy, the ability of trainers was

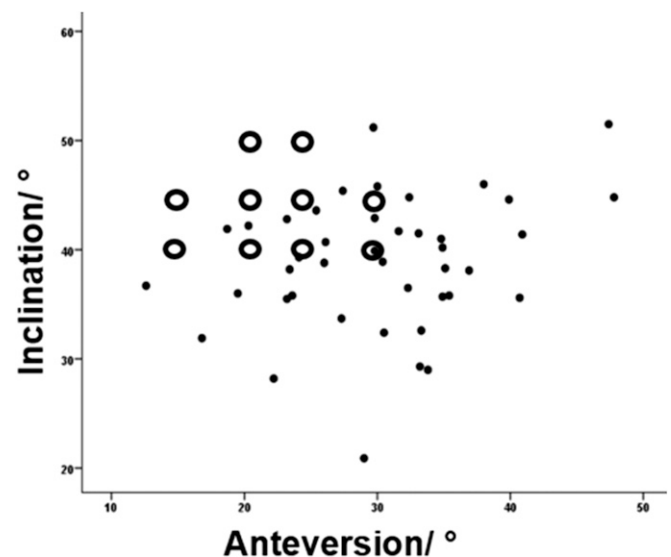


Fig. 3
Scatterplot of inclination versus anteversion coded for preferred orientations (hollow, bigger circles) and achieved orientations (black dots).

TABLE III Orientation Measurements According to Visual Cue Groups

Angle and Groups	Intended or Estimated*	Measured or Operative*	Difference*	P Value
Inclination				0.003
Visual cue (alignment guide)	45	42 ± 5 (24 to 49)	-3 ± 5 (-21 to 4)	
No visual cue	45	38 ± 6 (18 to 53)	-6 ± 5 (-24 to 7)	
Anteversion				<0.001
Visual cue (transverse acetabular ligament and alignment guide)	28 ± 8 (20 to 36)	29 ± 8 (13 to 45)	1 ± 6 (-19 to 15)	
No visual cue	22 ± 5 (10 to 40)	32 ± 9 (12 to 54)	11 ± 7 (-9 to 28)	

*The values are given as the mean, with or without the standard deviation, with the range in parentheses, in degrees.

compared with that of trainees. Lastly, the influence of surgeon location relative to the operating table on the ability to estimate angles was tested by comparing findings between Tasks 1 and 5.

Statistical Analysis

Statistical analyses were performed with use of SPSS Statistics version 19 (IBM). Nonparametric statistical tests (Mann-Whitney U, Kruskal Wallis) were used. The chi-square test was used for cross-tabulated data; significance was defined as $p \leq 0.05$.

Results

Task 1: Preferred Compared with Measured Cup Orientations

The preferred orientation had a mean inclination (and standard deviation) of $42^\circ \pm 3^\circ$ (range, 40° to 50°) and a mean anteversion of $21^\circ \pm 5^\circ$ (range, 5° to 30°) (Table I). The measured operative orientation had a mean inclination of $38^\circ \pm 6^\circ$ (range, 29° to 52°) and a mean anteversion of $33^\circ \pm 7^\circ$ (range, 17° to 47°) (Fig. 3). Mean Δ inclination was $-4^\circ \pm 4^\circ$ (range, -11° to 7°) and mean Δ anteversion was $11^\circ \pm 5^\circ$ (range, 2° to 20°). The calculated radiographic orientation had a mean inclination of $43^\circ \pm 7^\circ$ (range, 33° to 62°) and a mean anteversion of $23^\circ \pm 4^\circ$ (range, 14° to 28°). Mean Δ Radiographic was $1^\circ \pm 6^\circ$ (range, -7° to 17°) for inclination and $1^\circ \pm 4^\circ$ (range, -7° to 8°) for anteversion. Fifteen cups (71%) were within the target orientation zone.

Task 2: Cup Anteversion Relative to Transverse Acetabular Ligament

When surgeons were asked to reproduce the transverse acetabular ligament's anteversion, the mean operative anteversion was 34° (range, 17° to 45°) (Table II). Mean Δ anteversion was 0° , but variability was 14° .

Task 3: Ability to Increase Orientation by Small Amounts

When asked to increase anteversion by 10° , the mean increase achieved was $9^\circ \pm 4^\circ$ (range, 1° to 17°) (Fig. 4). Similarly, when asked to increase inclination by 10° , the mean increase achieved was $9^\circ \pm 3^\circ$ (range, 3° to 17°).

Task 4: Ability to Achieve Orientation of 45° Inclination and 20° Anteversion with Alignment Guide

Use of the alignment device improved both accuracy and variability; the mean operative inclination was $42^\circ \pm 5^\circ$ (range, 24°

to 49°) and the mean operative anteversion was $24^\circ \pm 5^\circ$ (range, 13° to 35°). Using the alignment device, the mean calculated radiographic inclination was $45^\circ \pm 5^\circ$ (range, 28° to 51°) and the mean calculated anteversion was $16^\circ \pm 4^\circ$ (range, 10° to 25°). Twenty cups (95%) were within the orientation zone (Fig. 5).

Task 5: Ability to Estimate Orientation When on the Assistant's Side

When asked to estimate cup orientation while standing on the assistant's side, mean Δ inclination was $-6^\circ \pm 7^\circ$ (range, -20° to 6°) and mean Δ anteversion was $8^\circ \pm 6^\circ$ (range, -2° to 19°). Subject position relative to the operating table bore no significant influence on the mean ability to estimate cup

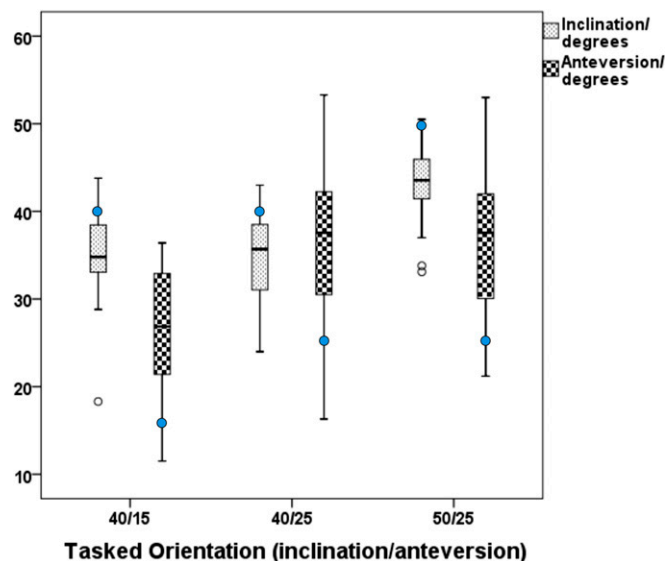


Fig. 4

Box-and-whisker plots illustrating cup orientation angles (y axis) for the different orientations in Task 3 (x axis). The blue dots represent the target orientation as per the task. The figure shows the ability to increase either inclination or anteversion by 10° . The box indicates the 25 and 75 percentiles, the line within the box represents the median, the whiskers indicate the data with 1.5 standard deviation of the box, and the clear circles indicate outliers.

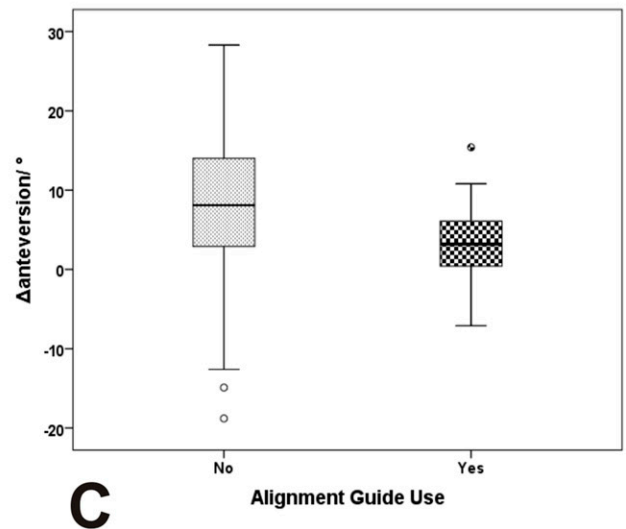
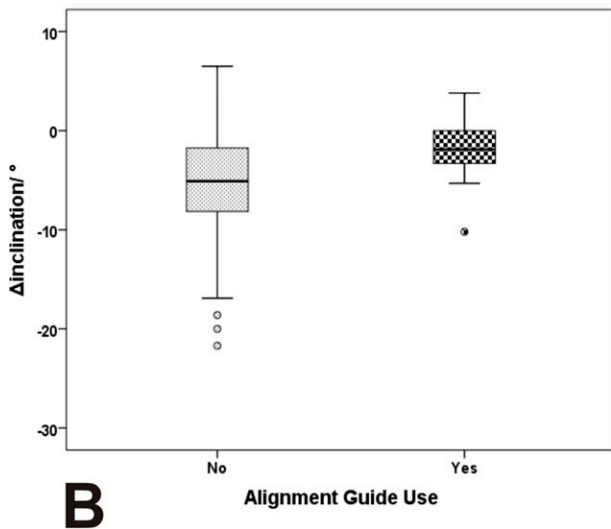
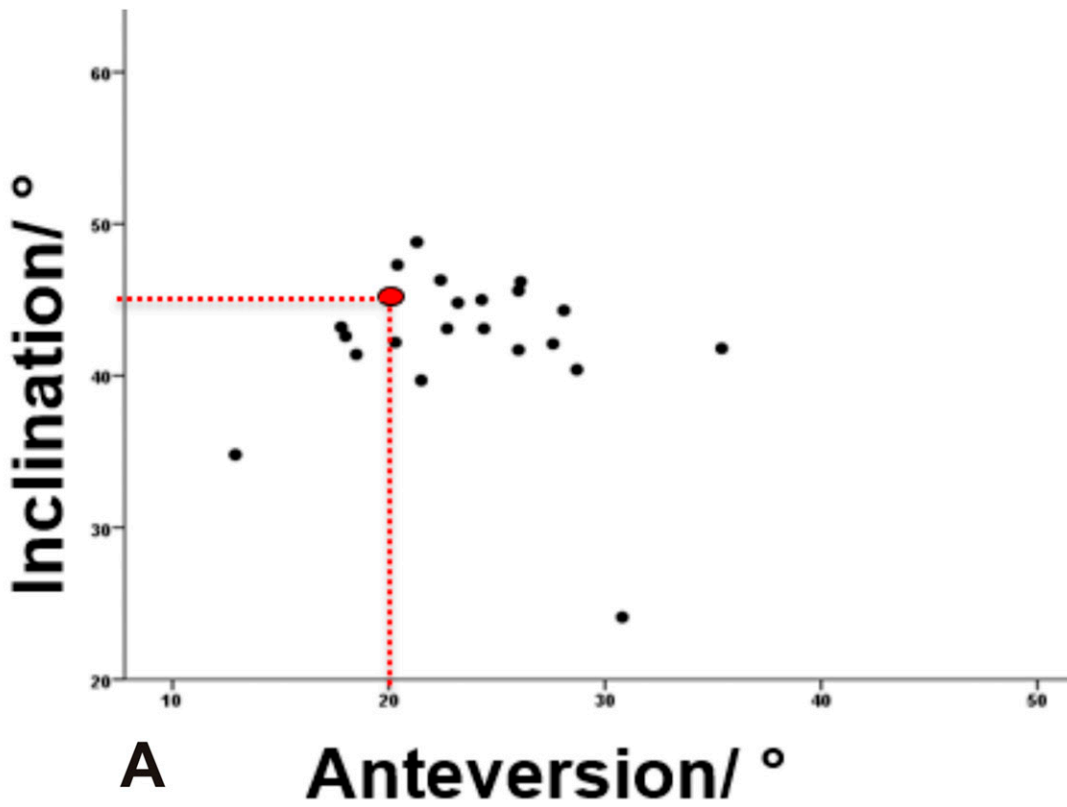


Fig. 5

Fig. 5-A Scatterplot of inclination versus anteversion illustrating orientations achieved with Task 4 (replicating alignment guide orientation of 45° inclination and 20° anteversion, as indicated by the red dotted lines). **Fig. 5-B** Box-and-whisker plot of Δ inclination according to the use of an alignment guide or not.

Fig. 5-C Box-and-whisker plot of Δ anteversion according to the use of an alignment guide or not. In Figures 5-B and 5-C, the box indicates the 25 and 75 percentiles, the line within the box represents the median, the whiskers indicate the data with 1.5 standard deviation of the box, and the clear circles indicate outliers.

inclination ($p = 0.6$); however, when subjects were on the assistant's side, they were better in determining anteversion by 3° ($p = 0.03$), which is probably not clinically important.

The variability in estimating cup inclination was 14° on the assistant's side compared with 8° on the surgeon's side (Task 1) (Fig. 6).

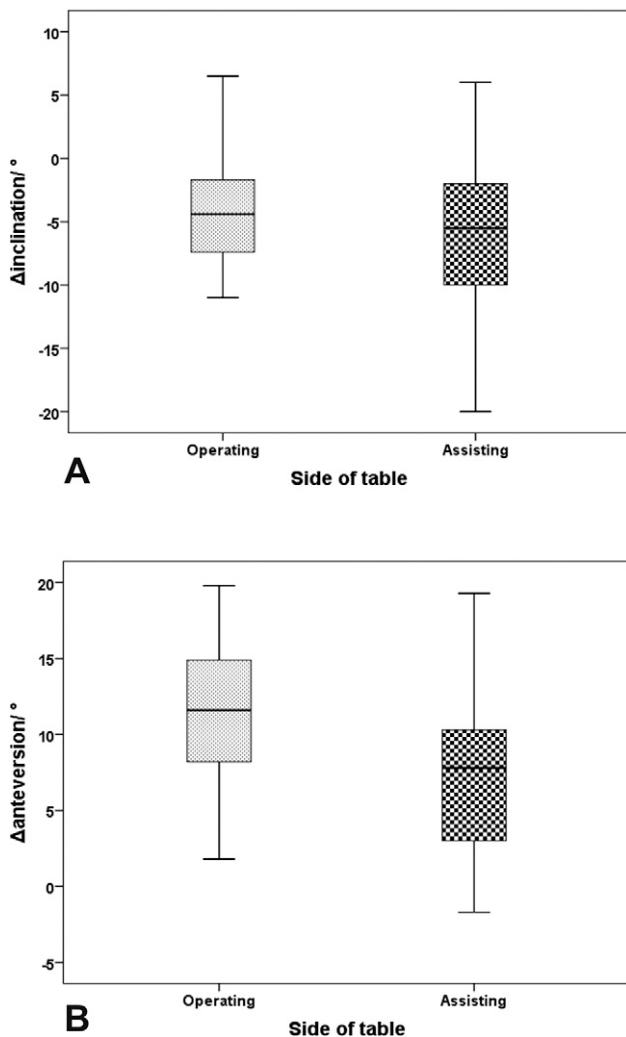


Fig. 6
Box-and-whisker plots of Δ inclination (Fig. 6-A) and Δ anteversion (Fig. 6-B) according to the subject's position relative to the operating table. The box indicates the 25 and 75 percentiles, the line within the box represents the median, and the whiskers indicate the data with 1.5 standard deviation of the box.

Subanalyses

Use of the alignment guide significantly reduced ($p = 0.007$) Δ inclination (mean, $-3^\circ \pm 5^\circ$ [range, -21° to 4°]) compared with all other tasks (mean, $-6^\circ \pm 5^\circ$ [range, -24° to 7°]) (Table III and Fig. 5). It similarly reduced Δ anteversion (mean, $3^\circ \pm 5^\circ$ [range, -7° to 15°]) compared with all other tasks (mean, $8^\circ \pm 8^\circ$ [range, -17° to 28°]) ($p < 0.001$). Use of the transverse acetabular ligament and alignment guide significantly reduced Δ anteversion (mean, $1^\circ \pm 6^\circ$ [range, -19° to 15°]) compared with all other tasks (mean, $11^\circ \pm 7^\circ$ [range, -9° to 28°]) ($p < 0.001$). There were no significant differences in any Δ orientation results between trainers and trainees, except for Tasks 3 and 5 (Table IV). Trainees showed greater accuracy in reproducing the orientation using the guide and in estimating operative anteversion when on the assistant's side.

Discussion

To our knowledge, this is the first study to investigate the ability of surgeons to estimate cup orientation angles. This was assessed in terms of both Δ orientation and variability, with the Δ orientation being the mean difference between the orientation angle the surgeons aimed to achieve and the actual angle they achieved and the variability being 2 standard deviations of this measurement (i.e., about 95% of times orientations were within the quoted variability). We confirmed that surgeons were inaccurate, despite them knowing that their accuracy was being assessed. The Δ orientation was commonly about 10° for anteversion and 5° for inclination. The variability was also large, being about $\pm 15^\circ$ for anteversion and $\pm 10^\circ$ for inclination. The errors are large and need to be understood so that they can be addressed.

The final position of the acetabular component depends on many factors⁶, not just the cup orientation at implantation⁷. Surgeons may at times adjust cup orientation to account for pelvic position at the time of impaction. Furthermore, factors such as body habitus, the appearance of the acetabulum and its edges (surgical exposure), and the presence of a patient's thigh can all affect a surgeon's estimation of cup orientation⁶. A standardized pelvic model was used to eliminate the above factors that potentially influence accuracy. Therefore, this study showed the best accuracy possible in estimating cup orientation.

We measured cup orientation using the surgeons' reference system (operative definitions). Clinically, cup orientation is assessed on postoperative radiographs using a different reference system (radiographic definitions). Interestingly, although the Δ orientation using the operative definitions was large (Δ inclination of approximately -5° and Δ anteversion of approximately 10°), there was no Δ orientation using the radiographic definitions for Tasks 1 and 5 (Δ Rinclination of 1° and Δ Ranteversion of 1°). The radiographic definitions are what matter, as the target orientation is assessed with these definitions. It is difficult to explain why there is no Δ orientation with the radiographic definitions: it may be that surgeons have, through trial and error, appreciated that, to achieve a given radiographic orientation target, they should reduce operative inclination and should increase operative anteversion. Whatever the reason, as there is no Δ orientation relative to the radiographic definition, we do not necessarily need to develop methods to alter the Δ orientation. What really matters is the variability.

Use of an alignment guide improved variability in anteversion by one-third (Fig. 5). It would therefore seem sensible to routinely use alignment guides. However, it was surprising that, even with the alignment guide, variability was still about $\pm 10^\circ$. The alignment guide is a mechanical device and it would seem likely that the design could be improved to reduce variability. With the guide, there was minimal Δ orientation in achieving the required operative angles (Δ inclination was -3° and Δ anteversion was 3°), but what is needed is the appropriate radiographic angles. As previously highlighted, most current cup

TABLE IV Difference in Orientations for Trainers and Trainees According to Task

	Orientations*		P Value
	Trainer*	Trainee*	
Task 1			
Δ inclination	-6 ± 4 (-11 to 1)	-3 ± 4 (-8 to 7)	0.15
Δ anteversion	12 ± 5 (2 to 20)	11 ± 4 (4 to 17)	0.46
Task 2			
Δ anteversion	1 ± 4 (-4 to 7)	-1 ± 9 (-17 to 11)	0.9
Task 3			
Δ inclination	-8 ± 6 (-22 to 2)	-4 ± 4 (-13 to 4)	0.01
Δ anteversion	14 ± 8 (-4 to 23)	10 ± 8 (-9 to 25)	0.04
Task 4			
Δ inclination	-5 ± 7 (-21 to 4)	-1 ± 2 (-5 to 3)	0.2
Δ anteversion	3 ± 7 (-7 to 15)	-2 ± 3 (-7 to 4)	0.7
Task 5			
Δ inclination	-5 ± 5 (-13 to 2)	-7 ± 9 (-20 to 6)	0.7
Δ anteversion	11 ± 6 (1 to 19)	6 ± 6 (-2 to 18)	0.04

*The values are given as the mean and the standard deviation, with the range in parentheses, in degrees.

alignment guides have too high an operative inclination and perhaps not enough anteversion to achieve radiographic targets²⁰.

Aiming to reproduce transverse acetabular ligament anteversion resulted in the same variability as freehand implantation. If an alignment guide is used, the variability in pelvic orientation at impaction increases the variability in subsequent cup orientation, whereas if the transverse acetabular ligament is used, the variability is such that the pelvic orientation has less effect on cup orientation (especially version).

Comparing the different surgeons (Tasks 1 to 4), we found that, although they were aiming for the same target, they implanted the cups in significantly different orientations (Fig. 7). In addition, we found that there was no clinically relevant difference between trainees and trainers. This suggests that the current method of training is not very good and that accuracy could possibly be improved by new teaching methods and reference guides. There was greater variability in the ability to estimate inclination while on the assistant's side, and we therefore suggest caution for trainers when on the assistant's side of the table helping an inexperienced surgeon on the surgeon's side.

This study had a number of limitations. First, it was an in vitro study with the use of a hemipelvic model, which does not accurately simulate in vivo situations. However, this model allowed for accurate positioning and maintenance of neutral pelvic alignment and enabled testing in the surgical environment without introducing undesired increases in surgical time. Assuming that the in vivo setting introduces more variables (orientation or hemisphericity of the reaming sur-

face, maintenance of the desired orientation when impacting component, bleeding, compromised visibility, soft-tissue exposure or impingement, osteophyte presence), it is likely that variability would be even higher during the actual surgical procedure; this agrees with findings of previous reports⁶. Second, orientations were captured without the cup being impacted. However, it is arguable that, although cup impaction would have improved stability of the cup within the model, it may have affected the desired measurements; occasionally, after impaction, the cup angle is different from the desired one as the cup may catch on one side when impacted. Third, we only tested one alignment guide and hence results may not be generalizable to other guides. However, Minoda et al.²¹ showed comparable ability of the tested guide compared with other guides in the market. Fourth, this study tested the ability of surgeons to estimate angles, not necessarily the ability to obtain the ideal cup position. Lastly, we were unable to provide rapid feedback regarding the measurements or to repeat the task at an interval of time to establish repeatability. However, the critical role of feedback has previously been highlighted by Gofton et al.²³, who demonstrated that real-time feedback using computer navigation can result in improvement of cup positioning by surgical trainees in a simulated in vitro environment.

In summary, surgeons overestimate operative inclination and underestimate anteversion, which is of benefit as this, on average, helps to achieve the desired radiographic cup orientation. However, there was large variability in cup orientation angles, which was helped slightly with alignment guides. New and better guides and methods for training need to be developed.

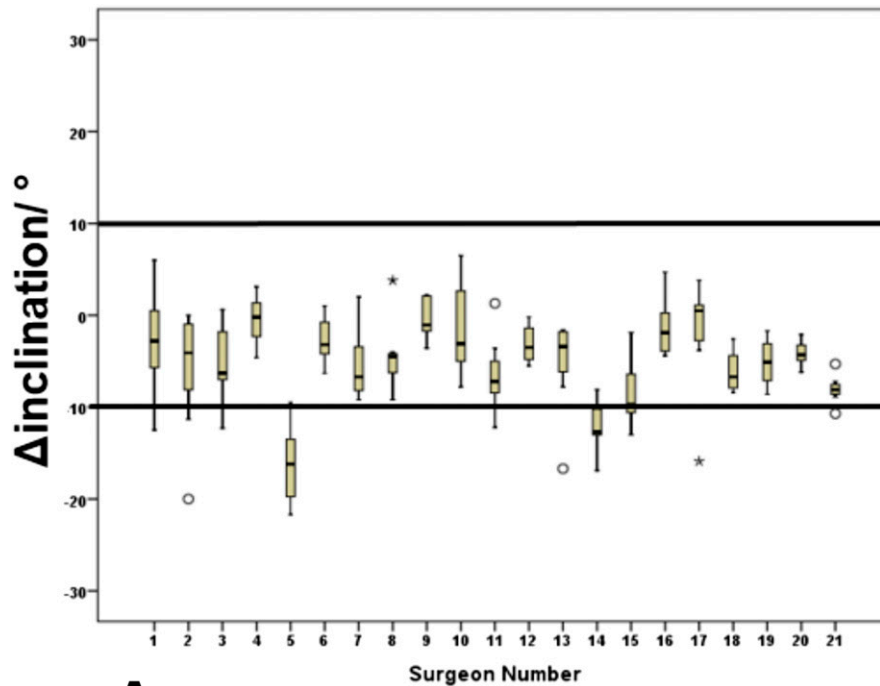
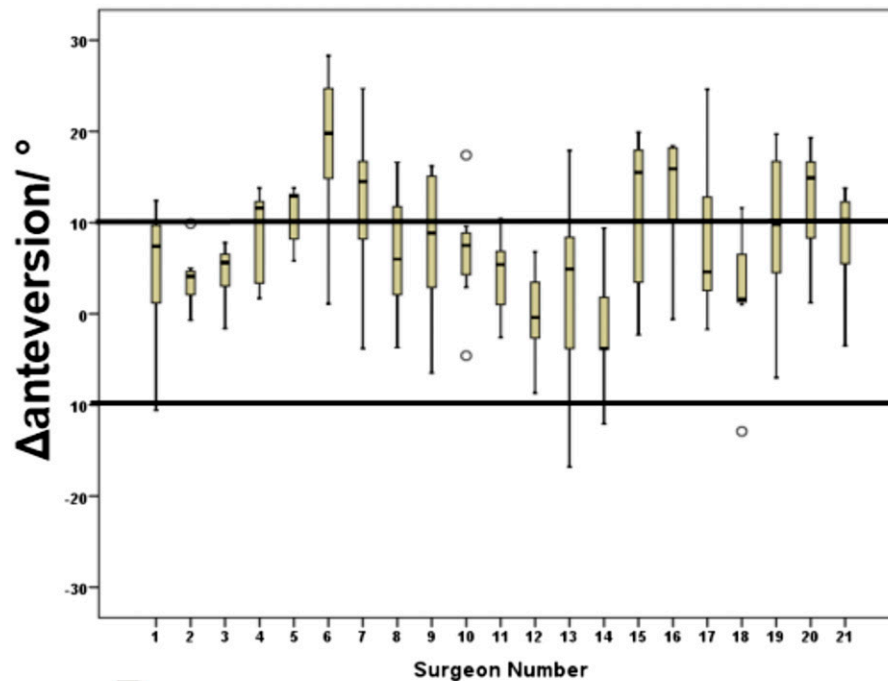
**A****B**

Fig. 7

Box-and-whisker plots showing variability of Δ orientation for the different surgeons for inclination (**Fig. 7-A**) and anteversion (**Fig. 7-B**). Note that 14 of 21 surgeons had variability of 10° (i.e., within the target) for inclination target, but 4 of 21 surgeons had variability of 10° (within the target) for anteversion. The box indicates the 25 and 75 percentiles, the line within the box represents the median, the whiskers indicate the data with 1.5 standard deviation of the box, and the clear circles indicate outliers.

Appendix

eA Text describing the technique validation and figures showing the calibration object used for the manufacturing process, the object during the measurements performed, and the technique validation demonstrating the calibration object and the testing wand in the Oxford Gait Laboratory are available with the online version of this article as a data supplement at jbjs.org. ■

George Grammatopoulos, FRCS(T&O), DPhil^{1,2}
Abtin Alvand, FRCS(T&O), DPhil^{1,2}
A. Paul Monk, FRCS(T&O), DPhil^{1,2}

Stephen Mellon, BSc(Hons), PhD²
Hemant Pandit, FRCS(T&O), DPhil^{1,2}
Jonathan Rees, FRCS(T&O), MD^{1,2}
Harinderjit S. Gill, BEng, DPhil³
David W. Murray, FRCS^{1,2}

¹Nuffield Orthopaedic Centre, Oxford, United Kingdom

²Nuffield Department of Orthopaedics, Rheumatology & Musculoskeletal Sciences, Headington, Oxford, United Kingdom

³Department of Mechanical Engineering, University of Bath, Bath, United Kingdom

E-mail address for G. Grammatopoulos:
george.grammatopoulos@ndorms.ox.ac.uk

References

- Williams D, Royle M, Norton M. Metal-on-metal hip resurfacing: the effect of cup position and component size on range of motion to impingement. *J Arthroplasty*. 2009 Jan;24(1):144-51. Epub 2008 Sep 27.
- Biedermann R, Tonin A, Krismer M, Rachbauer F, Eibl G, Stöckl B. Reducing the risk of dislocation after total hip arthroplasty: the effect of orientation of the acetabular component. *J Bone Joint Surg Br*. 2005 Jun;87(6):762-9.
- Langton DJ, Joyce TJ, Jameson SS, Lord J, Van Orsouw M, Holland JP, Nargol AV, De Smet KA. Adverse reaction to metal debris following hip resurfacing: the influence of component type, orientation and volumetric wear. *J Bone Joint Surg Br*. 2011 Feb;93(2):164-71.
- Grammatopoulos G, Thomas GE, Pandit H, Beard DJ, Gill HS, Murray DW. The effect of orientation of the acetabular component on outcome following total hip arthroplasty with small diameter hard-on-soft bearings. *Bone Joint J*. 2015 Feb;97-B(2):164-72.
- Grammatopoulos G, Pandit H, Glyn-Jones S, McLardy-Smith P, Gundle R, Whitwell D, Gill HS, Murray DW. Optimal acetabular orientation for hip resurfacing. *J Bone Joint Surg Br*. 2010 Aug;92(8):1072-8.
- Callanan MC, Jarrett B, Bragdon CR, Zurakowski D, Rubash HE, Freiberg AA, Malchau H. The John Charnley Award: risk factors for cup malpositioning: quality improvement through a joint registry at a tertiary hospital. *Clin Orthop Relat Res*. 2011 Feb;469(2):319-29.
- Grammatopoulos G, Pandit HG, da Assunção R, McLardy-Smith P, De Smet KA, Gill HS, Murray DW. The relationship between operative and radiographic acetabular component orientation: which factors influence resultant cup orientation? *Bone Joint J*. 2014 Oct;96-B(10):1290-7.
- Lewinnek GE, Lewis JL, Tarr R, Compere CL, Zimmerman JR. Dislocations after total hip-replacement arthroplasties. *J Bone Joint Surg Am*. 1978 Mar;60(2):217-20.
- Grammatopoulos G, Pandit HG, da Assunção R, Taylor A, McLardy-Smith P, De Smet KA, Murray DW, Gill HS. Pelvic position and movement during hip replacement. *Bone Joint J*. 2014 Jul;96-B(7):876-83.
- Meermans G, Van Doorn WJ, Koenraadt K, Kats J. The use of the transverse acetabular ligament for determining the orientation of the components in total hip replacement: a randomised controlled trial. *Bone Joint J*. 2014 Mar;96-B(3):312-8.
- Kumar V, Sharma S, James J, Hodgkinson JP, Hemmady MV. Total hip replacement through a posterior approach using a 22 mm diameter femoral head: the role of the transverse acetabular ligament and capsular repair in reducing the rate of dislocation. *Bone Joint J*. 2014 Sep;96-B(9):1202-6.
- Archbold HA, Mockford B, Molloy D, McConway J, Ogonda L, Beverland D. The transverse acetabular ligament: an aid to orientation of the acetabular component during primary total hip replacement: a preliminary study of 1000 cases investigating postoperative stability. *J Bone Joint Surg Br*. 2006 Jul;88(7):883-6.
- Graham D, Suzuki A, Reitz C, Saxena A, Kuo J, Tetsworth K. Measurement of rotational deformity: using a smartphone application is more accurate than conventional methods. *ANZ J Surg*. 2013 Dec;83(12):937-41. Epub 2013 Aug 30.
- Pal D, Bayley E, Magaji SA, Boszczyk BM. Freehand determination of the trajectory angle for cervical lateral mass screws: how accurate is it? *Eur Spine J*. 2011 Jun;20(6):972-6. Epub 2011 Jan 29.
- Murray DW. The definition and measurement of acetabular orientation. *J Bone Joint Surg Br*. 1993 Mar;75(2):228-32.
- Flamme CH, Stukenborg-Colsman C, Wirth CJ. Evaluation of the learning curves associated with uncemented primary total hip arthroplasty depending on the experience of the surgeon. *Hip Int*. 2006 Jul-Sep;16(3):191-7.
- Witjes S, Smolders JM, Beaulé PE, Pasker P, Van Susante JL. Learning from the learning curve in total hip resurfacing: a radiographic analysis. *Arch Orthop Trauma Surg*. 2009 Oct;129(10):1293-9. Epub 2009 Apr 21.
- Gangoiti G, Gutierrez Canas C, Albizuri A, Millan MM. Double-camera measurements of plumes, applied to wind field characterization and dispersion studies. *Boundary-Layer Meteorol*. 1996;79(1-2):1-21.
- Linder W. *Digital photogrammetry: a practical course*. Dusseldorf: Springer; 2009.
- Thomas H, Cantre S. Applications of low-budget photogrammetry in the Geotechnical Laboratory. *Photogramm Rec*. 2009;24(128):332-50.
- Minoda Y, Ohzono K, Aihara M, Umeda N, Tomita M, Hayakawa K. Are acetabular component alignment guides for total hip arthroplasty accurate? *J Arthroplasty*. 2010 Sep;25(6):986-9. Epub 2009 Oct 17.
- Zimmer. Zimmer Trilogy IT Acetabular System - surgical technique. 2013 Sep 12. <http://www.zimmer.com/content/dam/zimmer-web/documents/en-US/pdf/surgical-techniques/hip/zimmer-trilogy-it-acetabular-system-surgical-technique.pdf>. Accessed 2016 Apr 26.
- Gofton W, Dubrowski A, Tabloie F, Backstein D. The effect of computer navigation on trainee learning of surgical skills. *J Bone Joint Surg Am*. 2007 Dec;89(12):2819-27.